



# Facial Fractures: Independent Prediction of Neurosurgical Intervention

Brandon Lucke-Wold<sup>1</sup> Kevin Pierre<sup>2</sup> Sina Aghili-Mehrizi<sup>2</sup> Gregory Joseph Anatol Murad<sup>1</sup>

<sup>1</sup>Department of Neurosurgery, University of Florida, Gainesville, Florida, United States

<sup>2</sup>University of Florida College of Medicine, Gainesville, Florida, United States

Address for correspondence Brandon Lucke-Wold, MD, PhD, Department of Neurosurgery, University of Florida, 1505 SW Archer Rd, Gainesville, FL 32608, United States (e-mail: Brandon.Lucke-Wold@neurosurgery.ufl.edu).

AJNS 2022;17:17–22.

## Abstract

**Context** Over half of patients with facial fractures have associated traumatic brain injury (TBI). Based on force dynamic cadaveric studies, Le Fort type 2 and 3 fractures are associated with severe injury. Correlation to neurosurgical intervention is not well characterized.

**Aims** This study characterizes fracture pattern types in patients requiring neurosurgical intervention and assesses whether this is different from those not requiring intervention.

**Settings and Design** Retrospective data was collected from the trauma registry from 2010 to 2019.

**Methods and Materials** Patients over 18 years, with confirmed facial fracture, reported TBI, available neuroimaging, and hospital admission were included.

**Statistical Analysis** Retrospective contingency analysis with fraction of total comparison was used with chi-square analysis for demographic and injury characteristic data.

**Results** Note that 1,001 patients required no neurosurgical intervention and 171 required intervention. The intervention group had a significantly greater number of patients with Glasgow Coma Scale (GCS) < 8 compared with the nonintervention group. Subset analysis revealed a twofold increase in Le Fort type 2 fractures and notable increase in Le Fort type 3 and panfacial fractures in the intervention group. Patients requiring craniectomy, craniotomy, or burr holes were much more likely to have Le Fort type 2 or 3 fractures compared with those only requiring external ventricular drains or intracranial pressure monitoring. Subset analysis accounting for GCS supported these results.

**Conclusion** Le Fort type 2 and type 3 fractures are significantly associated with requiring neurosurgical intervention. An improved algorithm for managing these patients has been proposed in the discussion. Ongoing work will focus on validating and refining the algorithm to improve patient care.

## Keywords

- ▶ traumatic brain injury
- ▶ Le Fort type 2 and 3 fractures
- ▶ neurosurgical intervention

published online  
June 1, 2022

DOI <https://doi.org/10.1055/s-0042-1749068>.  
ISSN 2248-9614.

© 2022. Asian Congress of Neurological Surgeons. All rights reserved.

This is an open access article published by Thieme under the terms of the Creative Commons Attribution-NonDerivative-NonCommercial-License, permitting copying and reproduction so long as the original work is given appropriate credit. Contents may not be used for commercial purposes, or adapted, remixed, transformed or built upon. (<https://creativecommons.org/licenses/by-nc-nd/4.0/>)

Thieme Medical and Scientific Publishers Pvt. Ltd., A-12, 2nd Floor, Sector 2, Noida-201301 UP, India

## Introduction

Roughly one of seven trauma patients admitted to the emergency room had maxillofacial fractures.<sup>1,2</sup> Studies have suggested an association between maxillofacial fractures and traumatic brain injury (TBI).<sup>2–20</sup> Depending on the severity, TBI may be difficult to detect using current technology, potentially delaying treatment and worsening prognosis for patients.<sup>4</sup>

A recent study suggested an association between Le Fort type fractures and more severe TBI.<sup>4,21</sup> This is likely due to diffuse axonal injury, epidural, and subdural hematomas secondary to the high-velocity facial trauma required to produce these fractures.<sup>4,22</sup> Despite these findings, little is known about how fracture types predict TBI severity and which patients eventually require neurosurgical intervention. Thus, the present study is designed to develop an improved algorithm for the management of TBI in the context of known facial fractures with a hypothesis that patients with midface fractures are at increased risk for severe TBI warranting more aggressive neurosurgical intervention. Furthermore, we grouped by Glasgow Coma Scale (GCS) to look at trends warranting improved management strategies.

## Subjects and Methods

The study was submitted for institutional board review at University of Florida and abided by the highest international ethical research standards. Retrospective analysis of patients from 2010 to 2019 obtained through our trauma registry. Inclusion criteria: adults over 18 years, confirmed facial fracture with available neuroimaging, reported TBI, and admission to intensive care unit or floor bed. Exclusion criteria: patients less than 18 years old, patients with no neuroimaging, and patients who were deceased prior to initiation of neurosurgical intervention.

In addition to basic demographic data, data collected included presenting GCS score, mechanism of injury, facial

fracture type, TBI type, and type of neurosurgical intervention. Age was grouped into seven categories: 1 (18–24 years old), 2 (25–34 years old), 3 (35–44 years old), 4 (45–54 years old), 5 (55–64 years old), 6 (65–74 years old), and 7 (> 75 years old). Race was grouped into 5 categories: 1 (Caucasian), 2 (black), 3 (Asian), 4 (Hispanic), and 5 (other). Sex was classified as male or female. GCS score was arranged: mild (14–15), moderate (9–13), or severe (8 or less). Mechanism of injury was grouped into 7 categories: 1 (assault), 2 (all-terrain vehicle or dirt bike accident), 3 (gunshot wound or knife injury), 4 (bicycle or moped accident), 5 (motorcycle collision or motor vehicle collision), 6 (fall), and 7 (other). Type of TBI: 1 (contusion), 2 (diffuse axonal injury), 3 (epidural hematoma), 4 (subdural hematoma), 5 (traumatic subarachnoid hemorrhage), 6 (intracranial hemorrhage or intraventricular hemorrhage), and 7 (penetrating injury). Additional radiographic findings: 1 (edema), 2 (herniation), 3 (pneumocephalus), and 4 (cerebral/cerebellar laceration).

Patients were divided into those with facial fracture and TBI without neurosurgical intervention and into those with facial fracture and TBI with neurosurgical intervention. GraphPad Prism 8.0 software was used for analysis. Retrospective contingency analysis with fraction of total comparison was used with chi-square analysis for demographic and injury characteristic data. A *p*-value of < 0.05 was considered statistically significant.

## Results

Based on the above inclusion/exclusion criteria 1,985 patients were pooled from the overall trauma registry. On further review, 316 were too young, 403 had no TBI, and 94 had no facial fracture. Note that 1,172 therefore met the criteria for inclusion into the study. A total of 1,001 patients had facial fracture and TBI with no neurosurgical intervention, while 171 had facial fracture and TBI with neurosurgical intervention. ►**Table 1** has baseline demographic data. No significant difference was seen between groups for age

**Table 1** Demographics

Age in years	Nonintervention ( <i>n</i> = 1,001)	Intervention ( <i>n</i> = 171)	<i>p</i> > 0.05
1. 18–24	1. (176) 17%	1. (36) 21%	
2. 25–34	2. (165) 17%	2. (39) 23%	
3. 35–44	3. (151) 15%	3. (21) 12%	
4. 45–54	4. (169) 17%	4. (33) 19%	
5. 55–64	5. (128) 13%	5. (28) 16%	
6. 65–74	6. (94) 9%	6. (10) 6%	
7. 75+	7. (118) 12%	7. (4) 3%	
Race			<i>p</i> > 0.05
1. Caucasian	1. 826 (83%)	1. 135 (79%)	
2. Black	2. 118 (11%)	2. 24 (14%)	
3. Asian	3. 5 (1%)	3. 1 (1%)	
4. Hispanic	4. 34 (3%)	4. 7 (4%)	
5. Other	5. 18 (2%)	5. 4 (2%)	
Gender			<i>p</i> > 0.05
1. Male	1. 723 (72%)	1. 136 (79%)	
2. Female	2. 278 (28%)	2. 35 (21%)	

**Table 2** Injury characteristics

	Nonintervention (n = 1,001)	Intervention (n = 171)	p < 0.001
Glasgow Coma Scale 1. Mild (14–15) 2. Moderate (9–13) 3. Severe (3–8)	1. (636) 64% 2. (140) 14% 3. (226) 22%	1. (17) 10% 2. (27) 16% 3. (127) 74%	
Mechanism of Injury 1. Assault 2. ATV/Dirt bike 3. GSW/Knife 4. Bicycle/Moped 5. MCC/MVC 6. Fall 7. Other	1. 160 (16%) 2. 44 (4%) 3. 46 (5%) 4. 74 (7%) 5. 381 (38%) 6. 212 (22%) 7. 84 (8%)	1. 16 (9%) 2. 11 (6%) 3. 9 (5%) 4. 18 (11%) 5. 77 (45%) 6. 19 (12%) 7. 21 (12%)	p > 0.05
Types of TBI 1. Contusion 2. DAI 3. EDH 4. SDH 5. tSAH 6. ICH/IVH 7. Penetrating injury	1. 61 (6%) 2. 31 (3%) 3. 49 (5%) 4. 201 (20%) 5. 295 (29%) 6. 66 (7%) 7. 11 (1%)	1. 21 (12%) 2. 23 (13%) 3. 22 (13%) 4. 63 (37%) 5. 79 (46%) 6. 27 (16%) 7. 1 (1%)	p > 0.05
Additional radiographic findings 1. Edema 2. Herniation 3. Pneumocephalus 4. Cerebral/Cerebellar laceration	1. 25 (2%) 2. 32 (3%) 3. 34 (3%) 4. 5 (1%)	1. 20 (12%) 2. 25 (15%) 3. 10 (6%) 4. 4 (2%)	p > 0.05

Abbreviations: ATV, all-terrain vehicle; DAI, diffuse axonal injury; EDH, epidural hematoma; GSW, gunshot wound; ICH, intracranial hemorrhage; IVH, intraventricular hemorrhage; MCC, motorcycle collision; MVC, motor vehicle collision; SDH, subdural hematoma; TBI, traumatic brain injury; tSAH, traumatic subarachnoid hemorrhage.

(chi-square = 8.08, p = 0.23), race (chi-square = 0.6, p = 0.96), or gender (chi-square = 1.33, p = 0.25).

Injury characteristics were compared in ►Table 2. A significant difference was seen between groups for presenting GCS (chi-square = 67.71, p < 0.001). Of note, in the non-intervention group 64% had mild GCS score (14–15) compared with 10% of the intervention group. Conversely, 74% of the intervention group had severe GCS score (3–8) compared with 22% of the nonintervention group. No significant difference was seen between groups for mechanism of injury (chi-square = 7.58, p = 0.27), type of TBI (chi-square = 3.09, p = 0.8), or additional radiographic findings (chi-square = 1.71, p = 0.63).

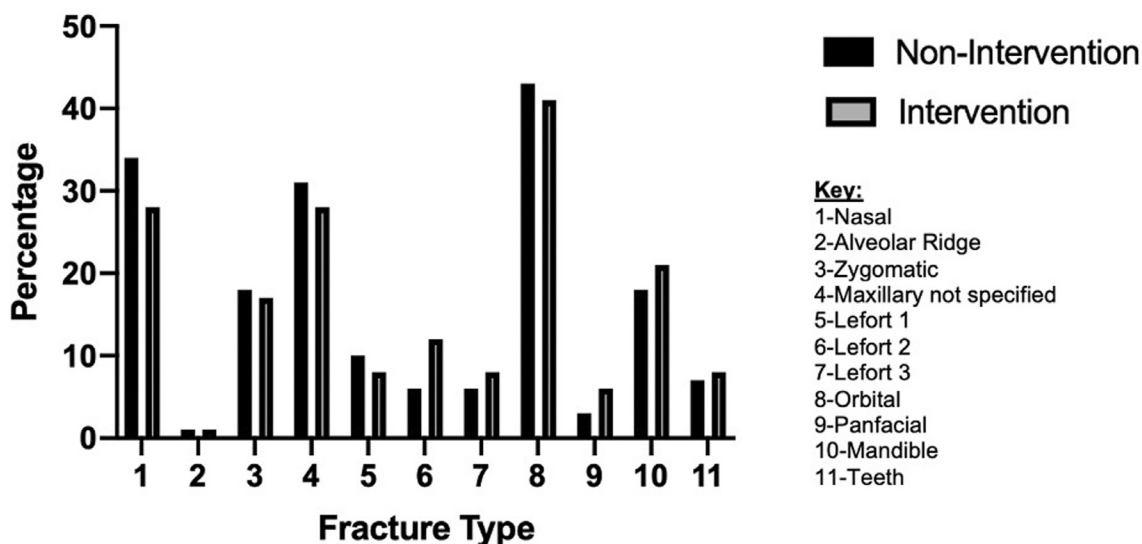
Fracture type patterns were similar between the non-intervention and intervention group (chi-square = 4.518, p = 0.92) as seen in ►Fig. 1. Subset analysis did, however, reveal a twofold increase in Le Fort type 2 and panfacial fractures in the intervention group compared with the nonintervention group. In the intervention group, 136/171 required an intracranial pressure (ICP) monitor or external ventricular drain (EVD) only, 12/171 required a craniotomy, craniectomy, or burr holes only, and 23/171 required a craniotomy, craniectomy, or burr holes with EVD or ICP monitor (►Fig. 2). A significant difference was seen in type of intervention depending on presenting facial fracture pattern (chi-square = 20.02, p = 0.03). Of note, 24% of the craniotomy, craniectomy, and burr hole group had Le Fort type 2 fracture compared with only 9% in the ICP monitor-only group. Fifteen percent of the craniotomy, craniectomy,

and burr hole group had Le Fort type 3 fracture compared with only 7% in the ICP monitor-only group. Also, 29% of the craniotomy/burr hole group had panfacial fractures compared with 7% of the ICP monitor-only group (►Fig. 3).

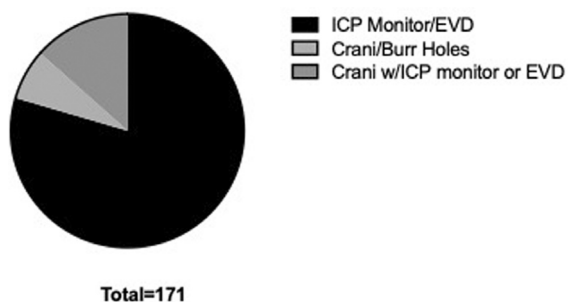
Further subset analysis was done to compare Le Fort type 2 and 3 fractures based on GCS score for each group. A significant difference was seen (chi-square = 8.44, p = 0.01). Of patients with GCS 14 to 15, 7% of the nonintervention group had Le Fort type 2 and 3 fractures compared with 6% of the intervention group. A notable difference, however, was seen for patients presenting with GCS 9 to 13 with only 11% of patients in the nonintervention group having Le Fort type 2 and 3 fractures compared with 40% in the intervention group. Additionally, for patients with GCS less or equal to 8, 17% of the nonintervention group had Le Fort type 2 and 3 fractures compared with 19% of the intervention group (►Fig. 4).

## Discussion

Traumatic injury is a leading cause of death and disability worldwide.<sup>23</sup> A significant number of trauma victims present with maxillofacial fractures, with roughly half of these patients presenting with TBI.<sup>1,2,24</sup> There is a growing body of literature suggesting that maxillofacial fractures serve as predictors for the presence and severity of TBI.<sup>4,7,9,10,13,17,21</sup> This study aimed to determine whether certain types of maxillofacial fractures can predict the need for neurosurgical interventions in an effort to produce an algorithm for the



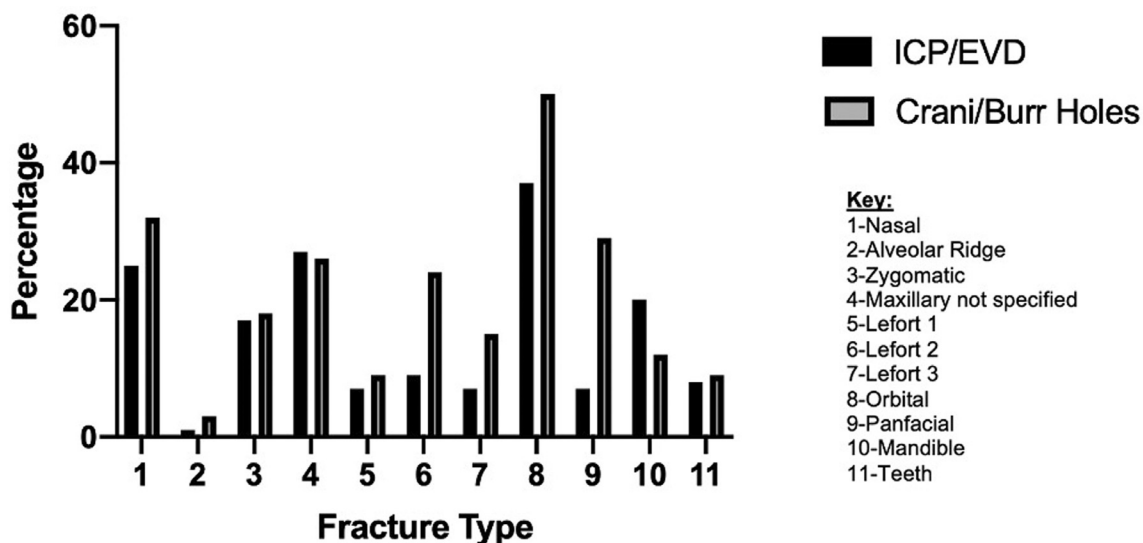
**Fig. 1** Patients in intervention vs. nonintervention group by type of facial fracture. No overall significant difference in aggregate fracture pattern between groups. However, there were more Le Fort type 2, Le Fort type 3, and panfacial fractures in the intervention group.



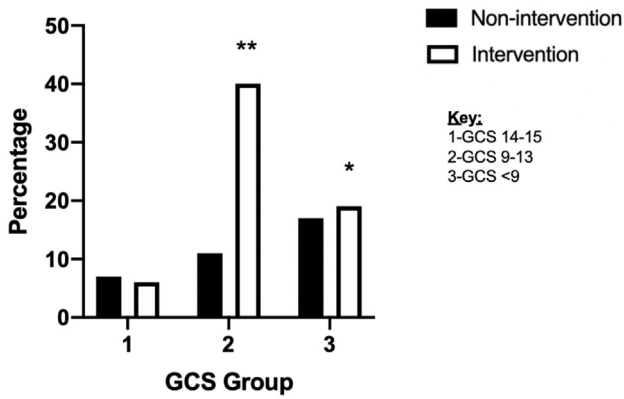
**Fig. 2** Type of neurosurgical intervention for trauma patients with facial fractures. ICP, intracranial pressure; EVD, external ventricular drain; Crani, decompressive craniectomy, craniotomy, or burr holes.

management of TBI patients presenting with known facial fractures.

A retrospective analysis of patients admitted to a major academic hospital trauma center between 2010 and 2019 with known facial fractures and concurrent TBI was performed. Most patients were victims of motor vehicle collisions, motorcycle accidents, and falls. Most suffered orbital, nasal, and maxillary fractures in a distribution similar to the study done by Menon et al with patients sharing similar demographics.<sup>25</sup> Patients were not more likely to require intervention based on age, race, gender, mechanism of injury, or specific radiologic findings of edema, herniation,



**Fig. 3** Le Fort type 2, and panfacial fractures, and 3 fractures were common in the craniotomy, craniectomy, and burr hole group compared to the intracranial pressure (ICP) monitor-only group. These results were statistically significant.



**Fig. 4** A significant difference was seen between the nonintervention and intervention groups in regards to Le Fort type 2 and 3 fractures when subanalysis was done based on Glasgow Coma Scale (GCS). 1 = GCS 14–15, 2 = GCS 9–13, 3 = GCS <9. \*\* $p < 0.01$ , \* $p < 0.05$ .

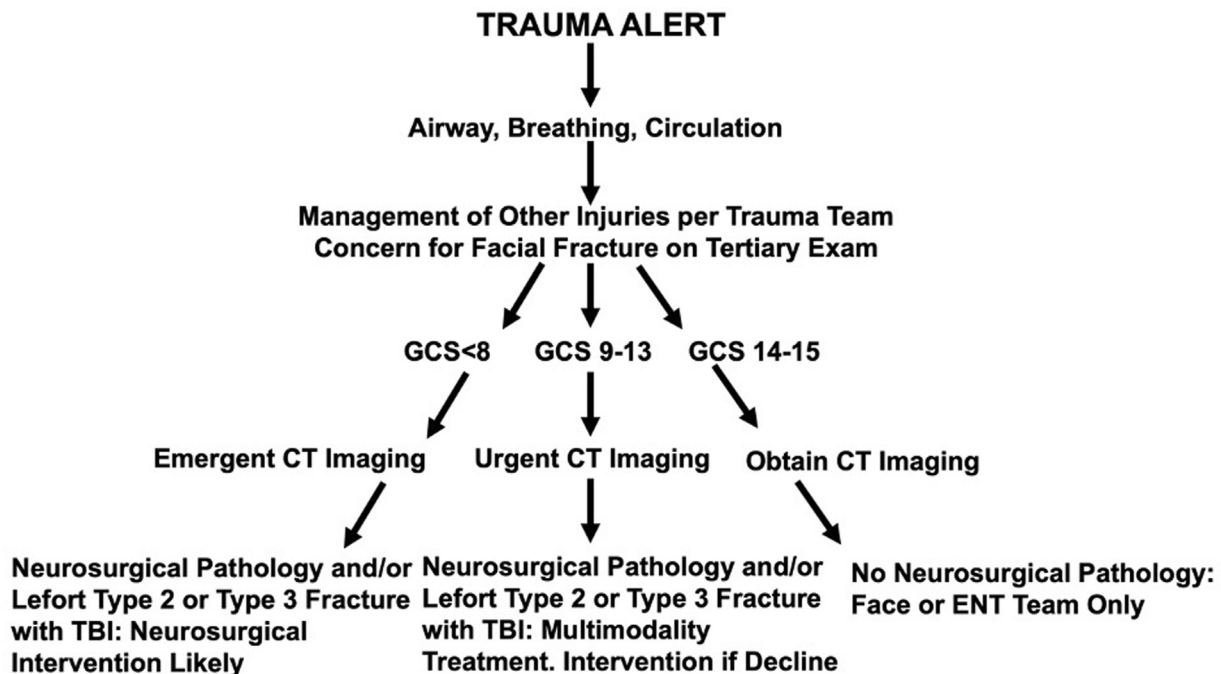
pneumocephalus, or laceration. As anticipated, those taken for intervention had higher GCS scores. When a subset analysis was performed however, even patients with GCS scores 9 to 13 were more likely to require subsequent intervention if they had Le Fort type 2 and 3 fractures lending credence to the individual predictive indication of these fracture types.

Patients with Le Fort type 2, type 3, and panfacial fractures were more likely to undergo neurosurgical intervention. Further, those presenting with these severe fractures were more likely to receive higher levels of neurosurgical intervention involving craniotomies, craniectomy, and burr holes compared with only EVDs or ICP monitors. This is consistent with the initial hypothesis that the high-velocity

impacts required to produce the more severe type 2 and 3 Le Fort type fractures<sup>22,26</sup> are also more likely to lead to more severe neurologic injury. These results also support previous investigations that showed associations between midface fractures and more severe TBI.<sup>21</sup>

Improved algorithms to identify and triage patients with facial fractures that are more likely to require neurosurgical interventions are being designed in collaboration with the hospital trauma, plastic, and oral and maxillofacial surgeon colleagues. **Fig. 5** shows an improved decision tree algorithm for managing patients with severe TBI and to have greater clinical suspicion for decline in moderate TBI patients with Le Fort type 2 and 3 facial fractures. This algorithm is influenced by this study's findings and Czerwinski et al's proposition for mandatory early computed tomography head to rule out TBI in patients presenting with facial fractures. This argument was also supported by Shibuya et al's study which showed that 11% of patients who underwent facial fracture repair had worsened GCS score following intervention due to underlying TBI.<sup>27,28</sup> Early surgical interventions improve outcomes.<sup>29</sup> The hope is that through initiation of the improved algorithm early imaging can be obtained, improved interactions between specialties can enhance patient care, and ultimately allow providers to quickly intervene when indicated.

This study's retrospective nature serves as a limitation. The study was also limited by the trauma registry. For example, it was not possible to separately consider the use of EVDs versus other ICP monitoring devices because providers sometimes did not use specific International Classification of Diseases (ICD) coding. ICD coding also sometimes did not specify fracture types, only indicating the presence of a facial fracture. These injuries were successfully categorized



**Fig. 5** Improved algorithm for managing patients with suspected traumatic brain injury (TBI) and facial fractures. Patients with Le Fort type 2 or 3 fractures are at greater likelihood for requiring neurosurgical intervention and should be grouped accordingly.

by chart review. However, it is possible that some facial fractures for patients within this group were not recorded.

We hope that the data and results from this initial study will serve as a catalyst for prospective investigations. Subsequent study will look at the prospective implementation of the algorithm for patients with facial fractures and TBI. This will allow direct evaluation of effectiveness. Future studies can also implement the finite element head models reviewed and developed by Tse et al to further determine fracture patterns more likely to be associated with severe TBI.<sup>30,31</sup>

#### Conflict of Interest

None declared.

#### Acknowledgment

We would like to thank Tabettha Harris for her help in obtaining and interpreting the data from the trauma registry.

#### References

- Hwang K, You SH. Analysis of facial bone fractures: an 11-year study of 2,094 patients. *Indian J Plast Surg* 2010;43(01):42–48
- Martin RC II, Spain DA, Richardson JD. Do facial fractures protect the brain or are they a marker for severe head injury? *Am Surg* 2002;68(05):477–481
- Pham TT, Lester E, Grigorian A, Roditi RE, Nahmias JT. National analysis of risk factors for nasal fractures and associated injuries in trauma. *Craniofacial Trauma Reconstr* 2019;12(03):221–227
- McCarty JC, Kiwanuka E, Gadkaree S, Siu JM, Caterson EJ. Traumatic brain injury in trauma patients with isolated facial fractures. *J Craniofac Surg* 2020;31(05):1182–1185
- Keenan HT, Brundage SI, Thompson DC, Maier RV, Rivara FP. Does the face protect the brain? A case-control study of traumatic brain injury and facial fractures. *Arch Surg* 1999;134(01):14–17
- Rajandram RK, Syed Omar SN, Rashdi MFN, Abdul Jabbar MN. Maxillofacial injuries and traumatic brain injury—a pilot study. *Dent Traumatol* 2014;30(02):128–132
- You N, Choi MS, Roh TH, Jeong D, Kim SH. Severe facial fracture is related to severe traumatic brain injury. *World Neurosurg* 2018;111:e47–e52
- Joshi UM, Ramdurg S, Saikar S, Patil S, Shah K. Brain injuries and facial fractures: a prospective study of incidence of head injury associated with maxillofacial trauma. *J Maxillofac Oral Surg* 2018;17(04):531–537
- Zandi M, Seyed Hoseini SR. The relationship between head injury and facial trauma: a case-control study. *Oral Maxillofac Surg* 2013;17(03):201–207
- Kraus JF, Rice TM, Peek-Asa C, McArthur DL. Facial trauma and the risk of intracranial injury in motorcycle riders. *Ann Emerg Med* 2003;41(01):18–26
- Carlin CB, Ruff G, Mansfeld CP, Clinton MS. Facial fractures and related injuries: a ten-year retrospective analysis. *J Craniofacial Trauma* 1998;4(02):44–48, discussion 43
- Salentijn EG, Peerdeman SM, Boffano P, van den Bergh B, Forouzanfar T. A ten-year analysis of the traumatic maxillofacial and brain injury patient in Amsterdam: incidence and aetiology. *J Craniofacial Surg* 2014;42(06):705–710
- Luce EA, Tubb TD, Moore AM. Review of 1,000 major facial fractures and associated injuries. *Plast Reconstr Surg* 1979;63(01):26–30
- Lee KF, Wagner LK, Lee YE, Suh JH, Lee SR. The impact-absorbing effects of facial fractures in closed-head injuries. An analysis of 210 patients. *J Neurosurg* 1987;66(04):542–547
- Lim LH, Lam LK, Moore MH, Trott JA, David DJ. Associated injuries in facial fractures: review of 839 patients. *Br J Plast Surg* 1993;46(08):635–638
- Pappachan B, Alexander M. Correlating facial fractures and cranial injuries. *J Oral Maxillofac Surg* 2006;64(07):1023–1029
- Lee HJ, Kim YJ, Seo DW, et al. Incidence of intracranial injury in orbital wall fracture patients not classified as traumatic brain injury. *Injury* 2018;49(05):963–968
- Alvi A, Doherty T, Lewen G. Facial fractures and concomitant injuries in trauma patients. *Laryngoscope* 2003;113(01):102–106
- Suri YV, Qasba KK, Mahajan TR. Militancy trauma: maxillofacial injury, anaesthesia and critical care. *Med J Armed Forces India* 1996;52(01):23–26
- Davidoff G, Jakubowski M, Thomas D, Alpert M. The spectrum of closed-head injuries in facial trauma victims: incidence and impact. *Ann Emerg Med* 1988;17(01):6–9
- Elbaih AH, El-Sayed DA, Abou-Zeid AE, Elhadary GK. Patterns of brain injuries associated with maxillofacial fractures and its fate in emergency Egyptian polytrauma patients. *Chin J Traumatol* 2018;21(05):287–292
- Roumeliotis G, Ahluwalia R, Jenkyn T, Yazdani A. The Le Fort system revisited: trauma velocity predicts the path of Le Fort I fractures through the lateral buttress. *Plast Surg (Oakv)* 2015;23(01):40–42
- Søreide K. Epidemiology of major trauma. *Br J Surg* 2009;96(07):697–698
- Scheyerer MJ, Döring R, Fuchs N, et al. Maxillofacial injuries in severely injured patients. *J Trauma Manag Outcomes* 2015;9:4–4
- Menon S, Sham ME, Kumar V, et al. Maxillofacial fracture patterns in road traffic accidents. *Ann Maxillofac Surg* 2019;9(02):345–348
- Phillips BJ, Turco LM. Le Fort fractures: a collective review. *Bull Emerg Trauma* 2017;5(04):221–230
- Czerwinski M, Parker WL, Williams HB. Algorithm for head computed tomography imaging in patients with mandible fractures. *J Oral Maxillofac Surg* 2008;66(10):2093–2097
- Shibuya TY, Karam AM, Doerr T, et al. Facial fracture repair in the traumatic brain injury patient. *J Oral Maxillofac Surg* 2007;65(09):1693–1699
- Giuliani G, Anile C, Massarelli M, Maira G. Management of complex craniofacial traumas. *Rev Stomatol Chir Maxillofac* 1997;98(Suppl 1):100–102
- Tse KM, Lim S, Tan VBC, Lee H. A review of head injury and finite element head models. *Am J Eng Technol Soc* 2014;1:28–52
- Yang B, Tse K-M, Chen N, et al. Development of a finite element head model for the study of impact head injury. *BioMed Res Int* 2014;2014:408278–408278