

Case Report

A Solitary Intestinal Myofibroma: A Rare Cause of Neonatal Anemia

Janna S.E. Ottenhoff^a Peter G.J. Nikkels^b
C.E.J. Terwisscha van Scheltinga^c L. Naeije^d

^aDepartment of Pediatrics, Wilhelmina Children's Hospital, University Medical Center Utrecht, Utrecht, The Netherlands; ^bDepartment of Pathology, University Medical Center Utrecht, Utrecht, The Netherlands; ^cPrincess Máxima Center for Pediatric Oncology, Utrecht, The Netherlands; ^dDepartment of Pediatric Oncology, Hematology and BMT, BC Children's Hospital, Vancouver, BC, Canada

Keywords

Myofibroma · Gastrointestinal surgery · Neonatal anemia · Intestinal obstruction

Abstract

Solitary infantile myofibroma with visceral involvement is very rare. We present an unusual case of a solitary myofibroma with abdominal localization in a 1-day-old female neonate who presented with severe anemia and rectal bleeding. A bleeding myofibroma was found, located in the wall of the jejunum, and totally resected. In case of a solitary lesion, treatment is relatively easy and effective, with excellent prognosis after total resection. The multiple form (myofibromatosis) has a poor prognosis with low survival rates. We therefore recommend total body MRI for all patients diagnosed with myofibroma to rule out other lesions.

© 2017 The Author(s)
Published by S. Karger AG, Basel

Introduction

A female neonate, born at term, presented with paleness, single rectal bleeding, and severe anemia (Hb 10.6 g/dL, MCV 110 fL) on day 1 after birth. Besides pallor, pediatric examination revealed no other abnormalities. An erythrocyte transfusion was given and Hb levels increased to 14.7 g/dL. However, Hb levels declined rapidly to 11.0 g/dL within 6 days. Perinatal infection was considered as potential cause for the anemia, and intravenous antibiotics were given for 7 days. Diagnostic anemia workup was initiated but revealed no hematological laboratory abnormalities. Abdominal ultrasound revealed a solid mass measuring 6.2 × 5.2 × 2.5 cm on the right side of the abdomen (Fig. 1). On the following ultrasound though, the mass was located on the left side of the abdomen. Due to the apparent mobility of the lesion, a solid tumor arising from the ovaries was considered. Other differential diagnostic possibilities considered were an intestinal duplication cyst; immature teratoma; germ cell tumor; and neuroblastoma stadium 4S. The subsequent MRI was not sufficient due to the movement of the patient. On an exploratory laparoscopy, no abnormalities of the ovaries were seen. Laparoscopy was therefore converted to laparotomy for further inspection.

During the laparotomy, a solid, easily bleeding mass on the mesenterial side of the jejunum was found. Resection of the 4-cm jejunum – including the lesion – and end-to-end anastomosis were performed. Pathological examination of the resected specimen showed a solid spindle cell lesion within the intestinal wall with superficial ulceration and infiltrative borders in the muscle layers of the intestinal wall and in the mesentery (Fig. 2a, b). The cells were arranged in small irregular bundles with ovoid shape and nuclei without atypia. There were irregular vessels with a hemangiopericytoma like appearance. There was some necrosis and hemorrhage within the tumor. Calcification or hyalinization was not present. Immunohistochemical analysis revealed positive staining for vimentin, alpha-SMA, and CD34 and a negative staining for calretinin, caldesmon, and desmin (Fig. 2c, d). The histology and immunohistological markers were characteristic of infantile myofibroma. The postoperative course was uneventful and the patient recovered well with normal and stable Hb levels. A total body MRI was made postoperatively to rule out multiple lesions. Further follow-up was performed through abdominal ultrasound. No recurrence of the lesion and no other lesions were seen, confirming the diagnosis of an infantile solitary abdominal myofibroma.

Discussion

In this neonatal case, we report a solitary abdominal myofibroma as the cause of neonatal anemia. Although infantile myofibroma is rare, it is one of the most common fibrotic tumors in children, first described in 1951 [1]. A solitary lesion in the abdomen though is very rare. A literature search revealed only 20 other reported cases of a solitary infantile abdominal myofibroma (Table 1); however, it is the first case in which anemia is the primary presentation of the underlying disease [2–18]. The typical presentation of an intestinal myofibroma is associated with bowel perforation or obstruction, accompanied by obstructive symptoms such as vomiting and abdominal distention [18]. Infantile myofibromas are classified into two forms: the single and the multiple form. The multiple form – also known as myofibromatosis with or without visceral involvement – is more common in girls and can

present in a great variety of symptoms, depending on location, such as subcutaneous muscular or bones. Visceral involvement is seen in 30%. In contrast to solitary lesions, the prognosis of the multiple form is poor, with mortality rates up to 76%, mostly caused by cardiopulmonary or gastrointestinal complications [19]. New findings show that there might be a genetic component in the familiar form of infantile myofibromatosis due to mutations in the *PDGFRB* gene [20, 21]. In contrast to the multiple form, the single form presents most often with a lesion of the subcutis. Visceral involvement is rare and found in less than 4% of the solitary lesions [1]. The prognosis of this form is excellent when totally resected. No recurrence or metastasis has been reported [15, 18].

Conclusion

An intestinal myofibroma can be the cause of unexplained neonatal anemia and should therefore be considered in the differential diagnosis. Treatment is surgical and the prognosis is excellent. The existence of additional lesions which complicate prognosis and treatment should be ruled out by a total body MRI.

Statement of Ethics

Informed consent for publication was obtained from the parents of the participant. For this type of study formal consent is not required because this is a case report.

Disclosure Statement

The authors declare that they have no conflicts of interest.

Funding Sources

There is no funding to report for this paper.

References

- 1 Schurr P, Moulds W: Infantile myofibroma: a case report and review of the literature. *Adv Neonatal Care* 2008;8:13–20.
- 2 Numanoglu A, Davies J, Millar AJ, Rode H: Congenital solitary intestinal fibromatosis. *Eur J Pediatr Surg* 2002;12:337–340.
- 3 Kauffman SL, Stout AP: Congenital mesenchymal tumours. *Cancer* 1965;18:460–476.
- 4 Walts AE, et al: Solitary lesion of congenital fibromatosis: a rare cause of neonatal intestinal obstruction. *Am J Surg Pathol* 1982;6:255–260.
- 5 Srigley JR, Mancer K: Solitary intestinal fibromatosis with perinatal bowel obstruction. *Pediatr Pathol* 1984;2:249–258.

- 6 Gonzales-Crussi F, Noronha R: Solitary intestinal fibromatosis in the newborn. *Arch Pathol Lab Med* 1985;109:97–100.
- 7 Canioni D, et al: Solitary intestinal fibromatosis: a rare cause of neonatal obstruction. *Pediatr Pathol* 1989;9:719–724.
- 8 Saguem MH, et al: La forme intestinale isolée des myofibromatosis infantiles. *Ann Pathol* 1990;10:126–129.
- 9 Chang WL, Griffith KM: Solitary intestinal fibromatosis: a rare cause of intestinal obstruction in neonate and infant. *J Pediatr Surg* 1991;26:1406–1408.
- 10 Vazquez Rueda F, et al: Fibromatosis intestinal solitaria: una causa rara de obstruction intestinal neonatal. *Cir Pediatr* 1993;6:95–97.
- 11 Türken A, et al: Solitary intestinal fibromatosis mimicking malabsorption syndromes. *J Pediatr Surg* 1995;30:1387–1389.
- 12 Al-Salem AH, Al-Hayek R, Qureshi SS: Solitary intestinal fibromatosis: a rare cause of intestinal perforation in neonates. *Pediatr Surg Int* 1997;12:437–440.
- 13 Lacson AG, et al: Pathological case of the month. *Arch Pediatr Adolesc* 2000;154:203–204.
- 14 Arets HGM, Borzi PA, Mortimore RJ: Solitary intestinal fibromatosis as a cause of bile vomiting in a neonate. *J Pediatr Surg* 2000;35:643–645.
- 15 Choo KL, Borzi PA, Mortimore RJ: Neonatal intestinal obstruction from solitary intestinal fibromatosis. *Pediatr Surg Int* 2001;17:467–469.
- 16 Menéndez-Arzac R, Valdez-Méndez D, Landa R, Guzmán S, Cárdenas E, Cano AM: Solitary infantile gastrointestinal myofibroma: case report. *J Pediatr Surg* 2005;40:1361–1363.
- 17 Coulon A, McHeik J, Milin S, Levard G, Levillain P, Fromont G: Solitary intestinal fibromatosis associated with congenital ileal atresia. *J Pediatr Surg* 2007;42:1942–1945.
- 18 Eid HA, Abusrir H, Almowasher F, Nasrhullah R, Alkhater M, Almarhoon Z: Solitary intestinal myofibroma – an unusual cause of neonatal intestinal obstruction. *Ann Saudi Med* 2014;34:544–547.
- 19 Wiswell TE, Sakas EL, Stephenson SR, Lesica JJ, Reddoch SR: Infantile myofibromatosis. *Pediatrics* 1985;76:981–984.
- 20 Cheung YH, Gayden T, Campeau PM, LeDuc CA, Russo D, Nguyen VH, et al: A recurrent PDGFRB mutation causes familial infantile myofibromatosis. *Am J Hum Genet* 2013;92:996–1000.
- 21 Agaimy A, Bieg M, Michal M, Geddert H, Märkl B, Seitz J, et al: Recurrent somatic PDGFRB mutations in sporadic Infantile/solitary adult myofibromas but not in angioleiomyomas and myopericytomas. *Am J Surg Pathol* 2017;41:195–203.

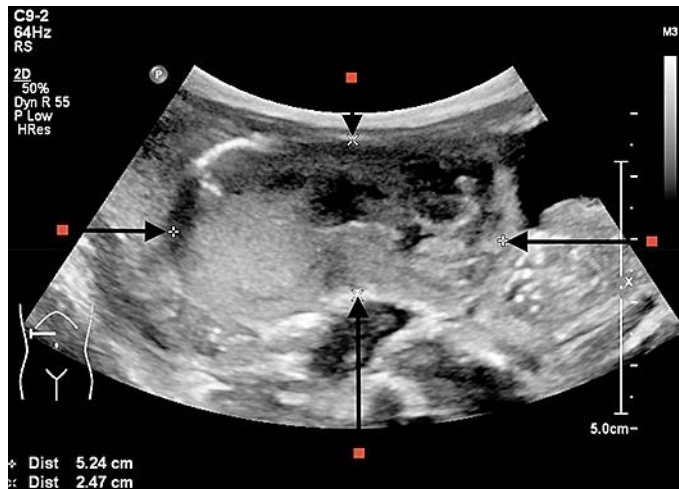


Fig. 1. A solid inhomogeneous mass on the right side of the abdomen, measuring 6.2 × 5.2 × 2.5 cm (CC × LR × AP).

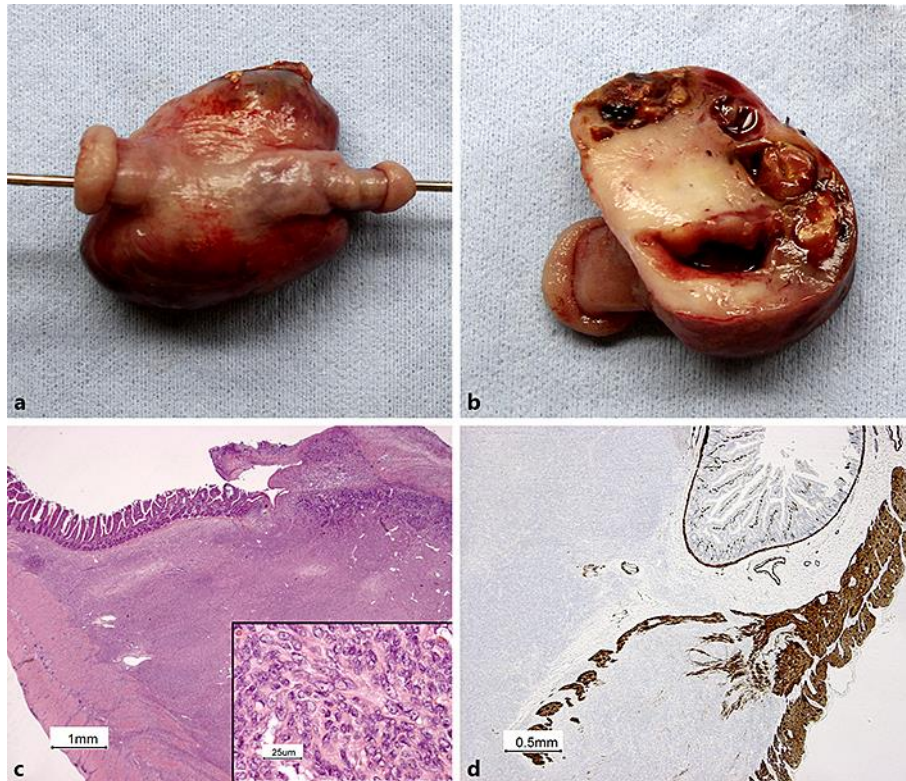


Fig. 2. **a** Macroscopical picture of the resection specimen with a probe in the lumen of the 6-cm long resected fragment of the small intestine. The tumorous mass ($5 \times 4 \times 3$ cm) is oriented on the mesenteric side of the specimen and on cut surface (**b**) and shows a partly solid white and partly hemorrhagic cystic appearance. **c** Histological aspect with focal ulceration of the intestinal mucosa and infiltration of the tunica muscularis. HE stain. **Inset** Higher power of the cells of the lesion with ovoid nuclei with small nucleoli and some eosinophil cytoplasm. HE stain. **d** Immunohistological stain with caldesmon, highlighting the infiltrative pattern of the negative tumor cells in the smooth muscle layer of the muscularis propria.

Table 1. Overview of congenital solitary intestinal myofibromas

Year	Authors [Ref.]	Age	Sex	Clinical presentation	Location	Operation	Follow-up	Outcome
1965	Kauffman and Stout [3]	Neonate	M	Intestinal obstruction	Jejunum	Resection, anastomosis	9 months	Good
1965	Kauffman and Stout [3]	Neonate	M	Intestinal obstruction	Jejunum	Resection, anastomosis	5 years	Good
1982	Walts et al. [4]	2 days	M	Intestinal obstruction	Ileum	Resection, anastomosis	18 months	Good
1984	Srigley and Mancer [5]	2 days	M	Obstruction, prenatal perforation	Transverse colon	Resection, colostomy	10 years	Good
1984	Srigley and Mancer [5]	2 days	M	Obstruction, prenatal perforation	Ileum	Resection, anastomosis	5 years	Good
1984	Srigley and Mancer [5]	1 day	M	Intestinal obstruction	Jejunum	Resection, anastomosis	26 months	Good
1985	Gonzales-Crussi and Noronha [6]	4 months	F	GI bleeding and obstruction	Mid small bowel	Resection anastomosis	9 years	Good
1989	Canioni et al. [7]	6 years	M	Pyloric obstruction	Pyloroduodenal junction	Resection anastomosis	2 years	Good
1990	Saguem et al. [8]	1 day	F	Intestinal obstruction	Jejunum	Resection anastomosis	25 months	Good
1991	Chang and Griffith [9]	5 months	M	Intestinal obstruction	Ileum	Resection, anastomosis	5 years	Good
1993	Vazquez Rueda et al. [10]	1 day	?	Intestinal obstruction	Jejunum	Resection, anastomosis		Good
1995	Türken et al. [11]	17 months	F	Hematemesis, malabsorption, obstruction	Jejunum	Resection, anastomosis	2 years	Good
1997	Al-Salem et al. [12]	4 days	F	Intestinal perforation	Descending colon	Resection, colostomy	8 months	Good
2000	Lacson et al. [13]	5 months	M	Intestinal obstruction	Splenic flexure colon	Resection, anastomosis	6 months	Good
2000	Arets et al. [14]	3 days	M	Intestinal obstruction	Mid small bowel	Resection, anastomosis	3 years	Good
2001	Choo et al. [15]	4 days	M	Intestinal obstruction	Jejunum	Resection, anastomosis	9 months	Good
2001	Numanoglu et al. [2]	6 days	M	Intestinal obstruction	Transverse colon	Resection, colostomy	12 months	Good
2005	Menéndez-Arzac et al. [16]	7 years	F	Intestinal obstruction	Ileum	Resection, anastomosis		Good
2007	Coulon et al. [17]	1 day	F	Intestinal obstruction	Ileum (atresia) ¹	Resection, anastomosis	28 months	Good
2014	Eid et al. [18]	17 days	F	Intestinal obstruction	Ileum	Resection, anastomosis		Good
2016	Present case	1 day	F	Anemia, rectal blood loss	Jejunum	Resection, anastomosis	6 months	Good

GI, gastrointestinal. ¹ Strong suspicion of spontaneous recurrence of a myofibroma, which caused the atresia.