




# Taibah University

## Journal of Taibah University Medical Sciences

www.sciencedirect.com



Original Article

## Podoplanin expression in various types of oral dysplasia and oral squamous cell carcinoma

Fatemeh Mashhadiabbas, BDS, DDS<sup>a</sup>, Maryam M. Chafjiri, BDS, DDS<sup>a,\*</sup>,  
Mahmood Dashti, BDS, DDS<sup>b</sup>, Muhammad A. Mudasser, BDS, DDS<sup>c</sup> and  
Sanaz Gholami, BDS, DDS<sup>a</sup>

<sup>a</sup> Shahid Beheshti University of Medical Sciences, Faculty of Dentistry, Department of Oral & Maxillofacial Pathology, Tehran, Iran

<sup>b</sup> Dentofacial Deformities Research Center, Research Institute of Dental Sciences, Shahid Beheshti University of Medical Sciences, Tehran, Iran

<sup>c</sup> Department of Orthodontics, Dr. Ishrat Ul Ibad Khan Institute of Oral Health Sciences, Dow University of Health Sciences, Karachi, Pakistan

Received 13 May 2024; revised 15 October 2024; accepted 17 November 2024; Available online 24 November 2024



### المخلص

**أهداف البحث:** تبحث هذه الدراسة دور البودوبلانين كواسم مرتبط بالتطور الخبيث والتقدم وضعف التكهن في طلاوة الفم وأشكال مختلفة من سرطان الخلايا الحشوية الفموية، خاصة فيما يتعلق بمستوى الغزو.

**طرق البحث:** أجري تحليل كيميائي نسيجي مناعي للبودوبلانين على سبع وسبعين عينة مؤكدة نسيجياً، محفوظة في الفورمالين ومطمورة في البارافين، تمثل مستويات مختلفة من غزو سرطان الخلايا الحشوية الفموية ودرجات خلل التنسج.

**النتائج:** تم تحليل العينات باستخدام اختبار فيشر الدقيق واختبار كروسكال-واليس. وجدت علاقة مهمة بين أنواع العينات وشدة وكمية وتوزيع وموقع والتهاب وتورط الأوعية اللمفية في التلويين. ازدادت درجة تلويين البودوبلانين تدريجياً من خلل التنسج الخفيف إلى السرطان الموضعي ضمن تصنيف خلل التنسج، بينما في تصنيف سرطان الخلايا الحشوية الفموية، لوحظ أعلى فطر تعبير في المجموعة جيدة التمايز.

**الاستنتاجات:** أظهر سرطان الخلايا الحشوية الفموية المبكر الغازي سلوكاً أكثر عدوانية مقارنة بالسرطان الدقيق الغازي، رغم أن كليهما كان أقل عدوانية من

السرطان الغازي. قد تساعد هذه النتائج في تحسين دقة التكهن وتوجيه استراتيجيات العلاج.

**الكلمات المفتاحية:** البودوبلانين؛ سرطان الخلايا الحشوية الفموية؛ الخباثة؛ خلل التنسج؛ دي ٢-٤٠

### Abstract

**Objective:** This study was aimed at investigating the roles of podoplanin (PDPN) as a marker associated with malignant development, progression, and poor prognosis in oral leukoplakia and various forms of oral squamous cell carcinoma (OSCC), particularly in relation to the extent of invasion.

**Methods:** Immunohistochemical analysis of PDPN was conducted on 77 histologically confirmed, formalin-fixed, paraffin-embedded samples representing various degrees of OSCC invasion and dysplasia grades.

**Results:** The samples were analyzed with Fisher's exact test and the Kruskal–Wallis test. Significant associations between sample type and the intensity, percentage, distribution, location, inflammation, and lymphatic vessel involvement according to staining were observed ( $p < 0.05$ ). The PDPN staining score progressively increased from mild dysplasia to carcinoma in situ within the dysplasia classification, whereas in the OSCC classification, the highest overexpression was observed in the well-differentiated group.

\* Corresponding address: Shahid Beheshti University of Medical Sciences, Faculty of Dentistry, Department of Oral & Maxillofacial Pathology, Tehran, Iran.

E-mail: [dr.maryam.mohammadalizadeh@gmail.com](mailto:dr.maryam.mohammadalizadeh@gmail.com) (M. M. Chafjiri)

Peer review under responsibility of Taibah University.



Production and hosting by Elsevier

**Conclusion:** Early invasive OSCC exhibited more aggressive behavior than micro-invasive OSCC, although both were less aggressive than invasive OSCC. These findings may aid in improving prognostic accuracy and informing treatment strategies.

**Keywords:** D2-40; Dysplasia; Malignancy; Oral SCC; PDPN

© 2024 The Authors. Published by Elsevier B.V. This is an open access article under the CC BY-NC-ND license (<http://creativecommons.org/licenses/by-nc-nd/4.0/>).

## Introduction

Squamous cell carcinoma of the oral cavity (OSCC) accounts for more than 90% of all head and neck cancers.<sup>1</sup> The clinical and biological behavior of these tumors significantly varies according to their location, such as in the larynx, oropharynx, or oral cavity.<sup>2</sup> Most OSCCs are preceded by visible clinical changes in the oral mucosa, often manifesting as oral potentially malignant disorders (OPMDs).<sup>3</sup> Dysplastic alterations in OPMDs have been found to be the most significant predictors of malignant progression.<sup>4</sup> The clinical appearance of a dysplastic lesion is not a reliable indicator of its severity, and the grade of dysplasia and potential for malignancy can be accurately determined only through biopsy and histopathological assessment. However, the classification of the histological grade of dysplasia can vary among pathologists. Epithelial dysplasia is typically classified as mild, moderate, or severe, according to the degree of atypia in the oral mucosa. Full-thickness dysplasia is considered carcinoma in situ (CIS), and may progress to primary invasive OSCC when tumor cells breach the basement membrane and invade the connective tissue.<sup>5–8</sup> The current World Health Organization (WHO) oral system recommends incorporating a three-tiered assessment into the diagnostic criteria.<sup>9</sup>

Although several studies have evaluated the characteristics of invasive OSCCs, few have focused on micro-invasive OSCC (MiOSCC) and early invasive OSCC (EiOSCC). MiOSCC is a malignant disease affecting primarily the oral mucosa. Various terms have been proposed to describe the early stages of OSCC, including superficially invasive OSCC,<sup>10</sup> and small and thin OSCC.<sup>11</sup> MiOSCC refers to invasion extending beyond the epithelial basement membrane into the surrounding stroma through nests or small islands.<sup>12</sup> Numerous studies have highlighted the challenges in diagnosing micro-invasive tumors in various parts of the body.<sup>13</sup> In 2002, a study described micro-invasive carcinoma in detail in locations such as the larynx, cervix, and breast.<sup>14</sup> Abbe et al. have defined MiOSCC as OSCC with an invasion depth as high as 5 mm,<sup>15</sup> whereas Pentenero et al. have defined it as stage I OSCC with a tumor thickness less than 4 mm.<sup>16</sup>

Histopathological criteria for diagnosing MiOSCC have not been clearly defined, thus resulting in a lack of standardized guidelines. The microscopic characteristics of this condition are currently under-documented and exhibit significant heterogeneity. In 1963, Shedd et al. identified structural and cytological features, such as prominent

growth of epithelial rete ridges and ductal modifications, as indicative—although not definitive—histopathological differences between CIS and micro-invasive carcinoma.<sup>17</sup>

Podoplanin (PDPN) is a 38-kDa transmembrane glycoprotein characterized by its mucin-type structure, extensive O-linked glycosylation, and high concentration of sialic acid.<sup>18,19</sup> This protein has been associated with tumor progression, and is frequently used as a specific marker for lymphatic endothelial cells and lymphangiogenesis, because it is expressed on the lymphatic endothelium but not on blood vessels.<sup>20,21</sup> PDPN has been detected in various types of human malignancies, including lung, cervix, esophagus, and oral cavity cancers.<sup>22</sup> The presence of PDPN in human malignancies can serve as a valuable biomarker for both diagnosis and prognostication of these cancers.<sup>23</sup> PDPN expression plays crucial roles in both inflammation and cancer progression across multiple cell types, such as T helper cells, macrophages, epithelial cells, and fibroblasts.<sup>24</sup> In vitro, PDPN has been found to enhance migration and invasion capability, whereas in vivo, it promotes lymph node metastasis.<sup>25</sup>

Although numerous studies have examined PDPN expression in the oral cavity, none have investigated its expression in OSCC according to the degree of invasion. The precise definitions of MiOSCC and EiOSCC remain unclear. Moreover, information regarding the progression of dysplasia to OSCC, and the roles of PDPN in various types of dysplasias, is insufficient. Therefore, this study was aimed at examining the roles of PDPN in all types of dysplastic changes and OSCC types according to local invasion.

## Materials and Methods

### Sample selection

The current investigation was conducted at the Department of Oral and Maxillofacial Pathology at Shahid Beheshti University of Medical Sciences, after ethical approval was obtained from the Institutional Ethical Committee (reference number: IR.SBMU.DRC.REC.1401.026). A total of 77 formalin-fixed, paraffin-embedded tissue sections were selected from the department's archives, including 22 samples of well-differentiated oral squamous cell carcinoma (WDOSCC), 4 samples of moderately differentiated oral squamous cell carcinoma (MDOSCC), 7 samples of EiOSCC, 8 samples of MiOSCC, 5 samples of CIS, 9 samples of severe dysplasia, 11 samples of moderate dysplasia, and 11 samples of mild dysplasia, all of which had been histologically identified.

### Grading of OSCC and dysplasia

The 2022 edition of the WHO guidelines was used as the entry criteria for dysplasia classification,<sup>26</sup> whereas a study by Kalele et al.<sup>27</sup> was referenced for the OSCC criteria according to the degree of invasion. MiOSCC was defined as a relatively thin tumor limited to the papillary lamina propria, with a depth of 0.5–2 mm from the surface of the non-neoplastic epithelium. Although few studies have provided clear definitions for early invasion OSCC, Muller et al.<sup>28</sup> have introduced several guidelines. We adopted the

criteria established by Kalele et al., in 2023, in which invasion is defined as 2 mm for pT1 and 4 mm for T2<sup>27</sup> (schematic in Figure 1).

#### *Immunohistochemical procedures*

Samples fixed in paraffin blocks were first sectioned with a microtome to a thickness of 2–3  $\mu$ m, then placed on charged slides. The slides were kept in an oven at 60 °C for 24 h, set, and passed through a xylene solution for deparaffinization. The deparaffinized slides were hydrated with 96% and 70% alcohol, then washed with distilled water. To inhibit intracellular peroxidase activity and prevent false positives, tissue sections were incubated with 3% hydrogen peroxide (H<sub>2</sub>O<sub>2</sub>) for 15 min in a dark environment, then washed with distilled water. In the next step, antigen retrieval was performed with microwave heat in citrate buffer for 20 min. After cooling, primary antibodies to PDPN (clone D2-40, mouse monoclonal, DBS American) were applied to stain cell membranes, and the samples were incubated for 1 h. The Master Diagnosis secondary antibody was applied and incubated for 15 min; this was followed by washing and the application of horseradish peroxidase (HRP) primer for 30 min, after which the slides were washed again.

To reveal the possible antigen–antibody complexes formed in the previous steps, we applied the chromogen solution diaminobenzidine and the substrate to the slides, thus resulting in the formation of a brown deposit. After washing, hematoxylin was used to counterstain the background. The slides were then washed and hydrated by passage through 70%, 80%, and 90% alcohol solutions, then placed in a xylene solution. Finally, the slides were prepared for analysis.

#### *Semi-quantitative analysis of PDPN immunohistochemistry*

Two independent observers (F. M. and M. M.), who were blinded to the participants' clinical information, assessed PDPN-positive cells under a compound light microscope (Leica DM 50) at magnifications of  $\times 10$ ,  $\times 20$ , and  $\times 40$ . Inter-examiner test results indicated acceptable reliability for all variables, with an intraclass correlation coefficient of 0.972 for the percentage variable.

#### *Interpretation and counting*

The lymphatic endothelium, which exhibited strong PDPN positivity, served as the internal positive control, whereas colon tissue was used as the external positive control (Figure 2). The negative control did not include primary antibodies. PDPN expression was determined by observation of cell membrane immunoreactivity, which was considered indicative of positive expression.<sup>29</sup> The pathologists evaluated both the percentages of positive tumor cells and the intensity of staining. The percentage of positive cells was graded as follows: 0 = no positive cells, 1 = 1–10% positive cells, 2 = 11–30% positive cells, 3 = 31–50% positive cells, 4 = 51–80% positive cells, and 5 = 80–100% positive cells.<sup>24</sup> Staining intensity was graded as follows: 0 = negative, 1 = weak, 2 = moderate, 3 = strong. The immunoreactivity score (IRS) was

classified as follows: 0–3 = weak, 4–7 = moderate, >8 = strong.<sup>24,30</sup>

The mean quantitative score for podoplanin expression in the epithelium was assessed with the scoring system outlined by Kawaguchi et al.,<sup>31</sup> as follows:

- 0: no expression detected in any part of the epithelium
- 1: expression limited to the basal layer of the epithelium
- 2: expression observed in both the basal and suprabasal layers in one area
- 3: suprabasal layer expression observed in two or three areas
- 4: suprabasal layer expression observed in more than three focal areas

The level of inflammation was categorized into four groups: none, mild, moderate, or severe.

Microvessel density was evaluated by identification and counting of the three areas with the highest vessel count under  $\times 100$  magnification, and the average value from these hotspots was used in the analysis. For lymphatic vessel density, PDPN-positive lymphatic vessels were manually counted throughout the tissue section, thus ensuring accuracy, given their lower density than blood vessels. Both peritumoral and intratumoral regions were assessed for vessel density. The lymphovascular density was graded as mild, moderate, or severe to enable detailed evaluation.

#### *Statistical analysis*

Depending on the type, role, and distribution of variables, Fisher's exact test, Dunn test, and Kruskal–Wallis test were used to evaluate the relationships between variables. Results with  $p < 0.05$  were considered statistically significant.

## **Results**

#### *Demographic and clinical characteristics*

The average patient age for the investigated samples was 58.91 years, and the standard deviation was 13.831 years. The youngest and oldest samples were from patients 31 and 85 years old, respectively (Table 1). Of the 77 samples, 41 (53.2%) were from women, and the remaining samples were from men. Fisher's exact test ( $p = 0.282$ ) indicated a consistent sex distribution across sample groups (Table 1).

The most common lesion locations were the tongue (29 samples; 6.37%), buccal mucosa (23 samples; 8.29%), and gingiva (15 samples; 4.19%). Other locations included the palate (four samples; 5%), the floor of the mouth (four samples; 5%), the lip (three samples; 3%), and the vestibular mucosa of the mandible (one sample; 1.2%). Fisher's exact test ( $p = 0.191$ ) confirmed that the relationship between lesion location and sample groups was not statistically significant. The location distribution according to sample type is presented in Table 1.

#### *Histopathologic findings*

PDPN was expressed in all samples (Figures 3–10). The expression intensity and percentages are presented in Table 2,

the IRS score is shown in Table 3, and the distribution and expression in epithelial layers are detailed in Table 4.

The Kruskal–Wallis test indicated a significant statistical association ( $p < 0.0001$ ) between the distribution of PDPN staining percentage and the pathology sample type. Dunn's test was used to perform pairwise comparisons and revealed significant relationships between the mild dysplasia and early invasive SCC groups, as well as between the moderate dysplasia and early invasive SCC groups (Table 2).

The Kruskal–Wallis test also showed a statistically significant relationship ( $p < 0.0001$ ) between the distribution of PDPN staining intensity and the pathology sample type. Pairwise comparisons with Dunn's test revealed significant differences between the following groups: (1) mild dysplasia and well-differentiated SCC, (2) mild dysplasia and moderately differentiated SCC, (3) mild dysplasia and CIS, and (4) moderate dysplasia and WDOSCC (Table 2). The IRS score is illustrated in Graph 1.

According to Fisher's exact test, significant relationships were found for the distribution of PDPN across groups ( $p < 0.002$ ) (Table 3) and the site of IHC staining across groups ( $p < 0.009$ ) (Table 3).

The tumor histopathological features, such as inflammation and lymphatic vessel density, are detailed in Table 4. The Kruskal–Wallis test demonstrated a statistically significant relationship ( $p < 0.003$ ) between inflammation distribution and pathology sample type. Dunn's test revealed significant correlations between the moderate SCC and early invasive SCC groups, as well as between the moderate SCC and CIS groups ( $p < 0.005$ ) (Table 4). The most severe inflammation was observed in the WDOSCC group (45.50%).

The exact Kruskal Wallis test indicated a statistically significant relationship ( $p < 0.003$ ) between inflammation distribution and pathology sample type. Dunn's test was used to examine pairs of samples, and indicated a significant correlation between the moderate SCC and early invasive

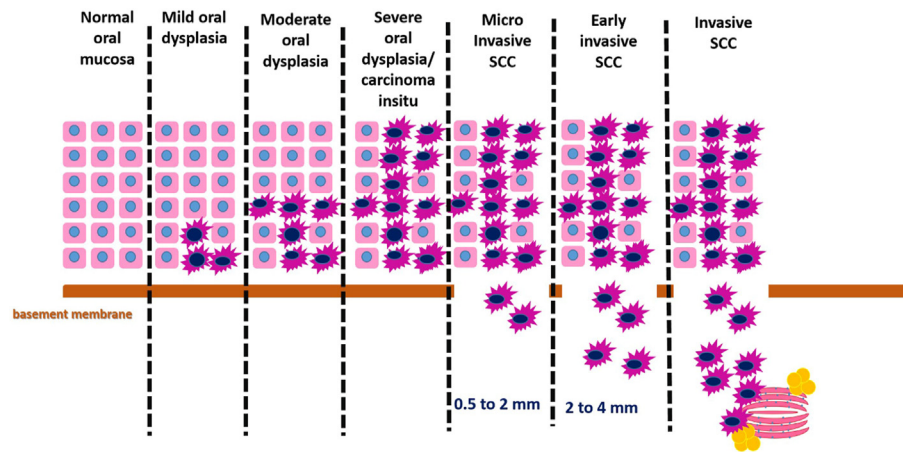
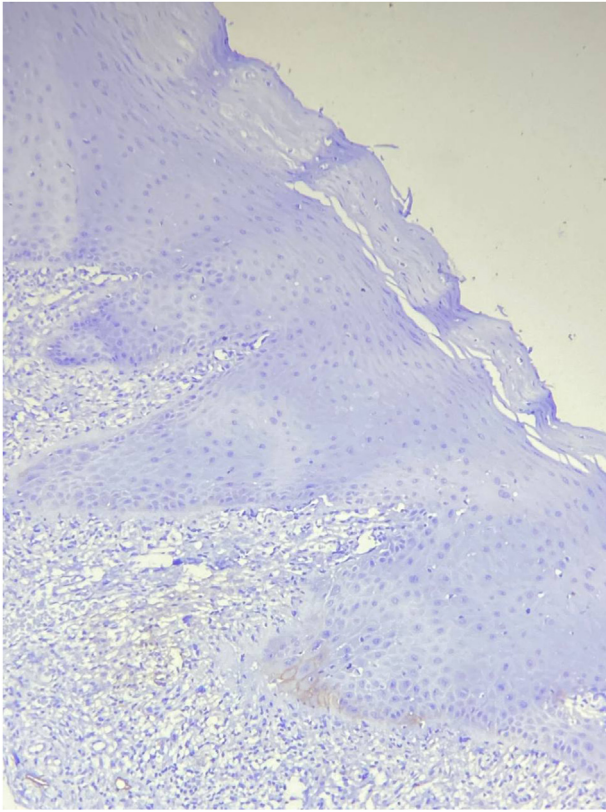


Figure 1: Schematic of dysplasia, carcinoma in situ, MiOSCC, EiOSCC, and invasive OSCC.

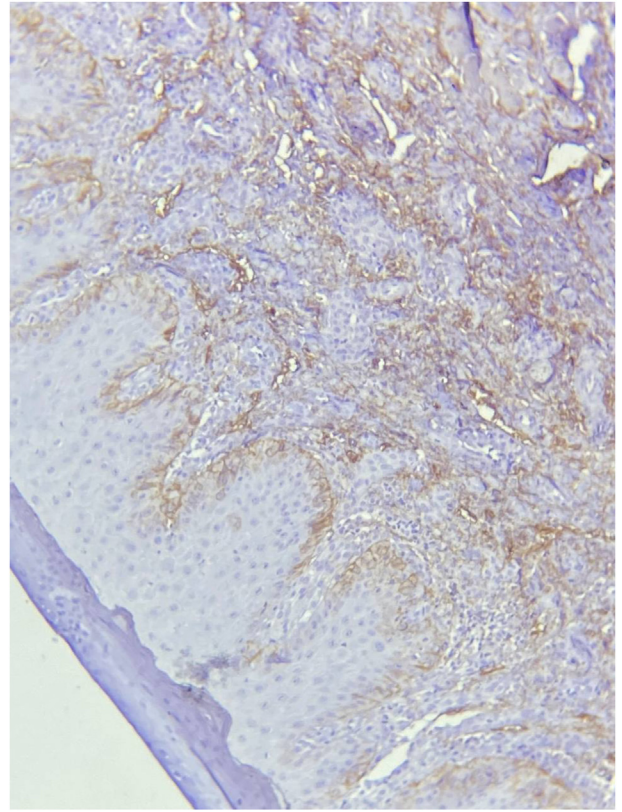
Table 1: Distribution of samples according to age, sex, and location.

Group	Mean age	Standard deviation of age	Sex		Specimen site						
			Female	Male	Tongue	Buccal mucosa	Gingiva	Lip	Palate	Vestibular mucosa of mandible	Floor of mouth
WDOSCC	64.73	12.310	8 19.50%	14 38.90%	8 32.00%	5 21.70%	7 46.70%	1 33.30%	1 25.00%	0 0.00%	0 0.00%
MDSCC	66.25	14.975	4 9.80%	0 0.00%	1 4.00%	0 0.00%	1 6.70%	1 33.30%	0 0.00%	1 100.00%	0 0.00%
Early invasive SCC	63.29	9.196	3 7.30%	4 11.10%	3 12.00%	1 4.30%	2 13.30%	0 0.00%	0 0.00%	0 0.00%	1 25.00%
Micro-invasive SCC	62.13	11.993	6 14.60%	2 5.60%	3 12.00%	2 8.70%	1 6.70%	0 0.00%	2 50.00%	0 0.00%	0 0.00%
Carcinoma in situ	56	14.440	2 4.90%	3 8.30%	1 4.00%	3 13.00%	0 0.00%	1 33.30%	0 0.00%	0 0.00%	0 0.00%
Severe dysplasia	51.89	17.596	6 14.60%	3 8.30%	5 20.00%	2 8.70%	0 0.00%	0 0.00%	0 0.00%	0 0.00%	0 0.00%
Moderate dysplasia	54.36	10.405	6 14.60%	5 13.90%	2 8.00%	6 26.10%	1 6.70%	0 0.00%	0 0.00%	0 0.00%	2 50.00%
Mild dysplasia	51.09	14.876	6 14.60%	5 13.90%	2 8.00%	4 17.40%	3 20.00%	0 0.00%	1 25.00%	0 0.00%	1 25.00%
Total	58.94	13.831	41 100.00%	36 100.00%	25 100.00%	23 100.00%	15 100.00%	3 100.00%	4 100.00%	1 100.00%	4 100.00%

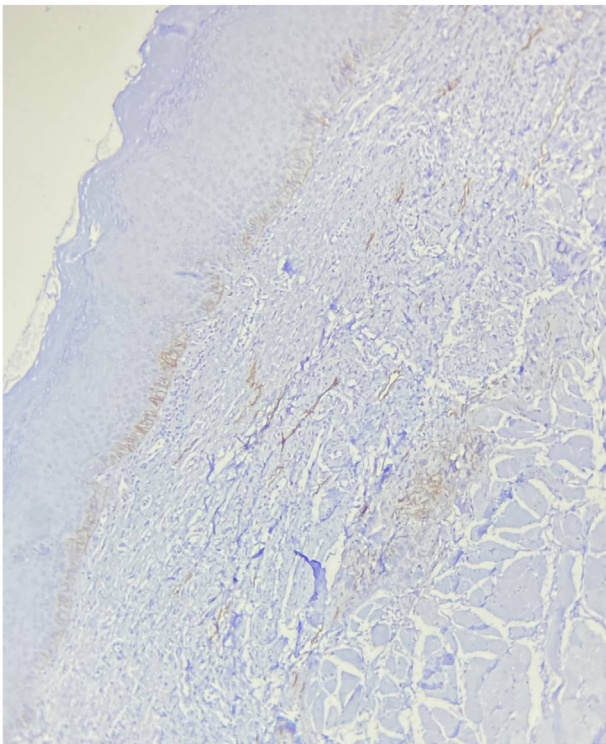




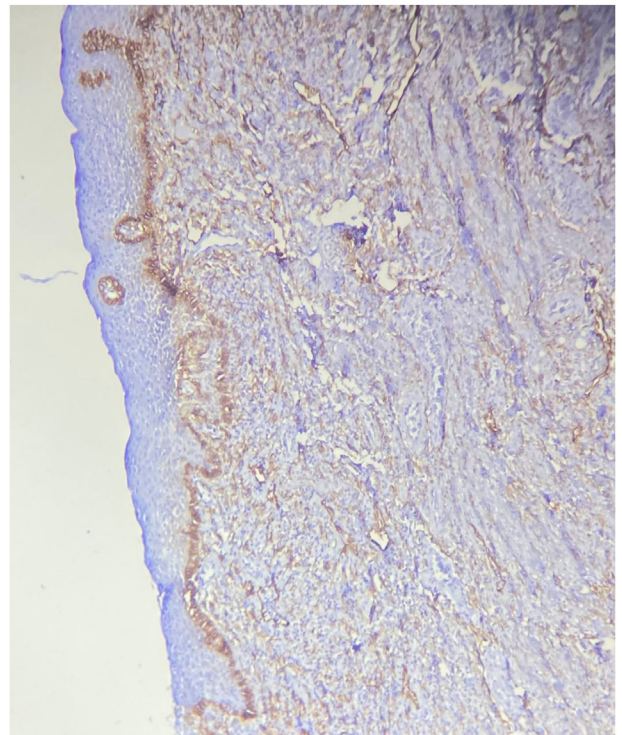
**Figure 2:** Photomicrograph showing colon tissue as a control sample (H&E stain,  $\times 100$ ).



**Figure 4:** Photomicrograph showing moderate dysplasia (H&E stain,  $\times 100$ ).

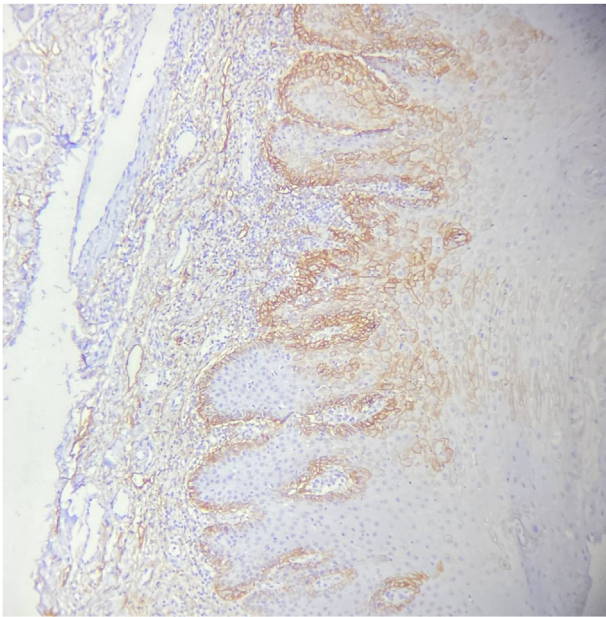


**Figure 3:** Photomicrograph showing mild dysplasia (H&E stain,  $\times 400$ ).



**Figure 5:** Photomicrograph showing severe dysplasia (H&E stain,  $\times 400$ ).





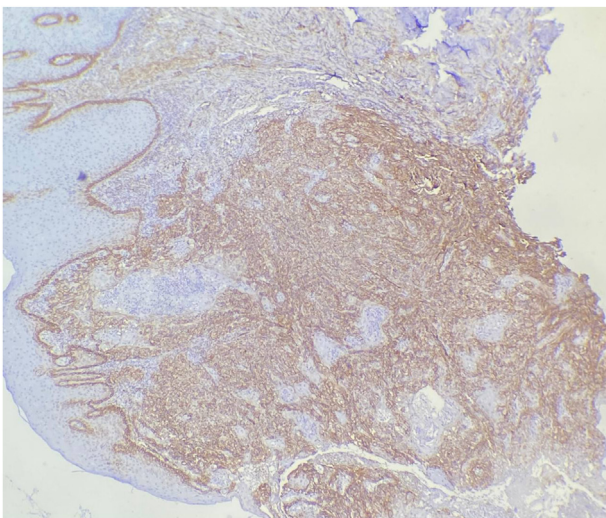
**Figure 6:** Photomicrograph showing carcinoma in situ (H&E stain,  $\times 100$ ).

SCC groups, as well as between the moderate SCC and CIS groups ( $p < 0.005$ ) (Table 4). More severe inflammation was observed in the WDOSCC group (45.50%).

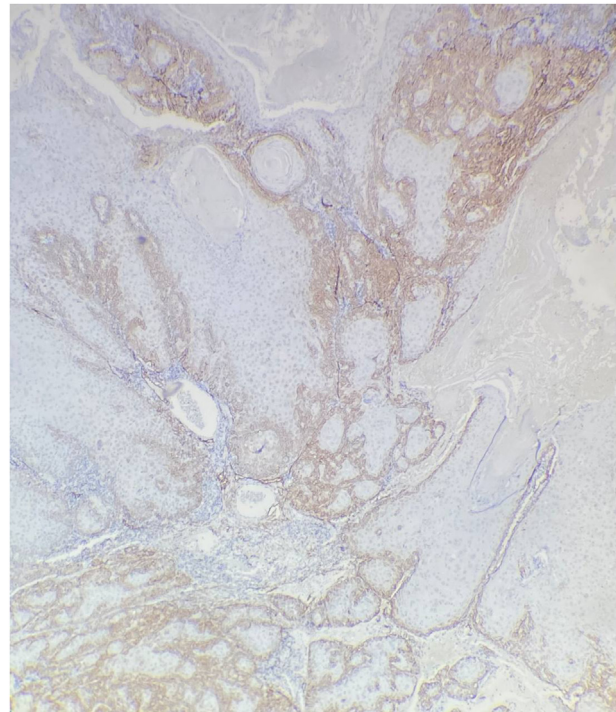
The exact Kruskal–Wallis test demonstrated a statistically significant relationship ( $p < 0.002$ ) between the distribution of lymphatic vessels and pathology specimen type. Pairwise analysis with Dunn’s test revealed a significant relationship between the mild dysplasia and well-differentiated SCC groups (Table 4).

## Discussion

OSCC is the most common form of oral cancer, accounting for 90% of cases and typically manifesting on the oral mucosal surface.<sup>32</sup> By 2035, the global prevalence of OSCC

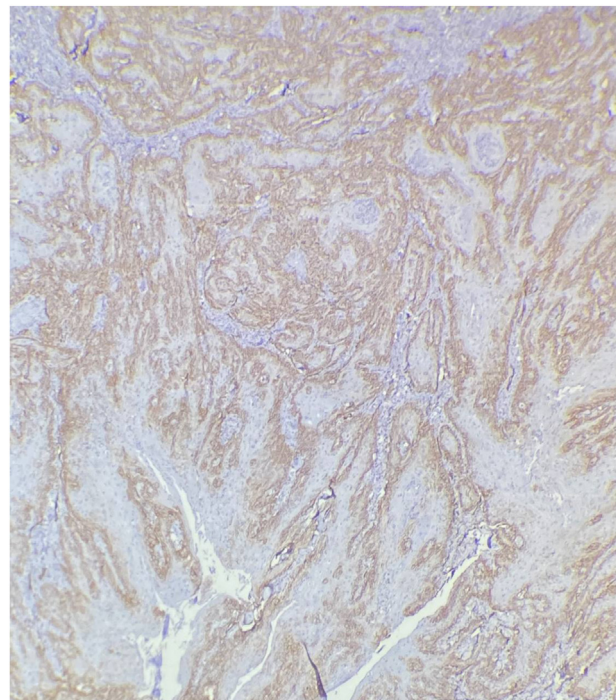


**Figure 7:** Photomicrograph showing micro-invasive OSCC (H&E stain,  $\times 100$ ).



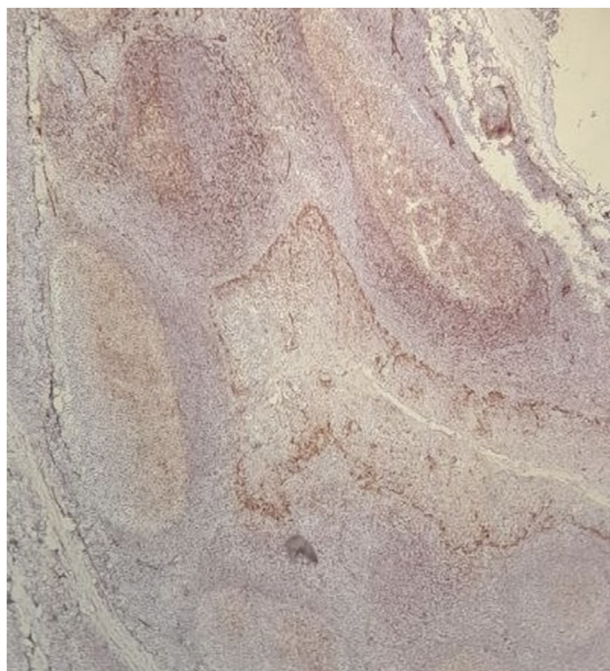
**Figure 8:** Photomicrograph showing early invasive OSCC (H&E stain,  $\times 100$ ).

has been projected to reach 856,000 cases.<sup>33</sup> This monoclonal genetic disease results from the accumulation of multiple sequential mutations.<sup>34–36</sup> The transformation of OPMDs into carcinomas has been well documented,



**Figure 9:** Photomicrograph showing well differentiated OSCC (H&E stain,  $\times 100$ ).





**Figure 10:** Photomicrograph showing moderately differentiated OSCC (H&E stain,  $\times 100$ ).

particularly in cases of oral epithelial dysplasia, in which these malignant lesions often appear in the mucosa surrounding invasive OSCC.<sup>37,38</sup> Therefore, this study was aimed at proposing a comprehensive classification of OSCC and oral dysplasia, and evaluating PDPN expression as a diagnostic marker for the invasive behavior of these lesions.

#### Demographic and clinical characteristics

In this study, the average patient age was 58.91 years. The average patient age for all SCC samples was 64.1 years,

in agreement with the findings of Melo and colleagues, in which the average age ranged from 51.4 to 60.4 years.<sup>39</sup> The average patient age for the eight MiOSCC samples was 61.75 years, which was older than the 53-year average reported by Haberland et al. in a study on MiOSCC.<sup>10</sup> This discrepancy is likely to be due to differences in the defining characteristics of MiOSCC between studies. Of the total samples in our study, 41 (53.2%) were from women, whereas the rest were from men. In the OSCC group, the sex distribution was nearly equal, whereas Melo et al. have reported a higher prevalence of OSCC in men than women.<sup>39</sup>

Overall, the tongue and buccal mucosa were the most common lesion locations. OSCCs were primarily observed on the tongue, whereas dysplastic lesions were most frequently found on the buccal mucosa. In a study by Deepa et al., an equal prevalence of OSCC was observed on the tongue and buccal mucosa, and dysplastic lesions were found to frequently affect the buccal mucosa.<sup>40</sup> The differences in findings might be associated with the prevalence of use of the tobacco product "nass" in the buccal mucosa area in the population in India.<sup>41,42</sup>

#### Staining percentage of IHC PDPN

Our research revealed a notable increase in the average percentage of positive PDPN cells with the level of dysplasia and OSCC. The average staining percentage was higher in MDOSCC than WDOSCC, and EiOSCC exhibited a higher average staining percentage than MiOSCC. In contrast, a study by Aiswarya et al., in 2019 demonstrated significantly lower percentages of positive cells in PDOSCC than WDOSCC.<sup>43</sup> PDPN has been suggested to play roles in tumor cell differentiation and the neoplastic progression of OSCC.<sup>44</sup>

In the present study, 97% of the 35 dysplasia samples showed positive PDPN expression, thus indicating more aggressive behavior than observed in a study by Kawaguchi et al.,<sup>31</sup> in which only 49% of patients with dysplasia had

**Table 2: Staining percentage and intensity of IHC PDPN.**

Group	Percentage positive cells		Standard deviation	Staining intensity			
	Mean	N		None	Weak	Moderate	Strong
WDSCC	22	62.5	31.872	0 0.00%	1 6.70%	3 18.80%	18 40.00%
MDSCC	4	80	11.547	0 0.00%	0 0.00%	0 0.00%	4 8.90%
Early invasive SCC	7	90	0.00	0 0.00%	0 0.00%	2 12.50%	5 11.10%
Micro-invasive SCC	8	53.75	34.512	0 0.00%	3 20.00%	2 12.50%	3 6.70%
Carcinoma in situ	5	62	37.683	0 0.00%	0 0.00%	0 0.00%	5 11.10%
Severe dysplasia	9	67.78	32.318	0 0.00%	1 6.70%	1 6.20%	7 15.60%
Moderate dysplasia	11	26.9	23.856	1 100.00%	4 26.70%	4 25.00%	2 4.40%
Mild dysplasia	11	25	23.130	0 0.00%	6 40.00%	4 25.00%	1 2.20%
Total	77	54.9	34.054	1 100.00%	15 100.00%	16 100.00%	45 100.00%

**Table 3: Distribution of IHC PDPN staining and expression in various epithelial layers.**

Group	PDPN	Distribution	Epithelial layers		
	Focal	Diffuse	Basal layer	Basal and supra basal layer	More than three focal areas
WDSCC	10 25.60%	12 31.60%	12 27.90%	10 30.30%	0 0.00%
MDSCC	0 0.00%	4 10.50%	0 0.00%	3 9.10%	1 100.00%
Early invasive SCC	0 0.00%	7 18.40%	1 2.30%	6 18.20%	0 0.00%
Micro-invasive SCC	4 10.30%	4 10.50%	6 14.00%	2 6.10%	0 0.00%
Carcinoma in situ	3 7.70%	2 5.30%	2 4.70%	3 9.10%	0 0.00%
Severe dysplasia	4 10.30%	5 13.20%	5 11.60%	4 12.10%	0 0.00%
Moderate dysplasia	9 23.10%	2 5.30%	7 16.30%	4 12.10%	0 0.00%
Mild dysplasia	9 23.10%	2 5.30%	10 23.30%	1 3.00%	0 0.00%
Total	39 100.00%	38 100.00%	43 100.00%	33 100.00%	1 100.00%

positive PDPN expression. The average staining percentage increased with the severity of dysplastic changes. Notably, the average staining rates in CIS (62%) and severe dysplasia (67%) were similar, in agreement with the WHO 2017 classification.<sup>45</sup> These findings are also consistent with those from studies by Logeswari et al., Deepa et al., and Vaishnavi Srinivasan et al..<sup>40,46,47</sup>

#### Staining intensity of IHC PDPN

In this study, a comparison of PDPN IHC staining intensity in OSCCs according to differentiation indicated that 100% of moderately differentiated OSCC samples and 85% of well-

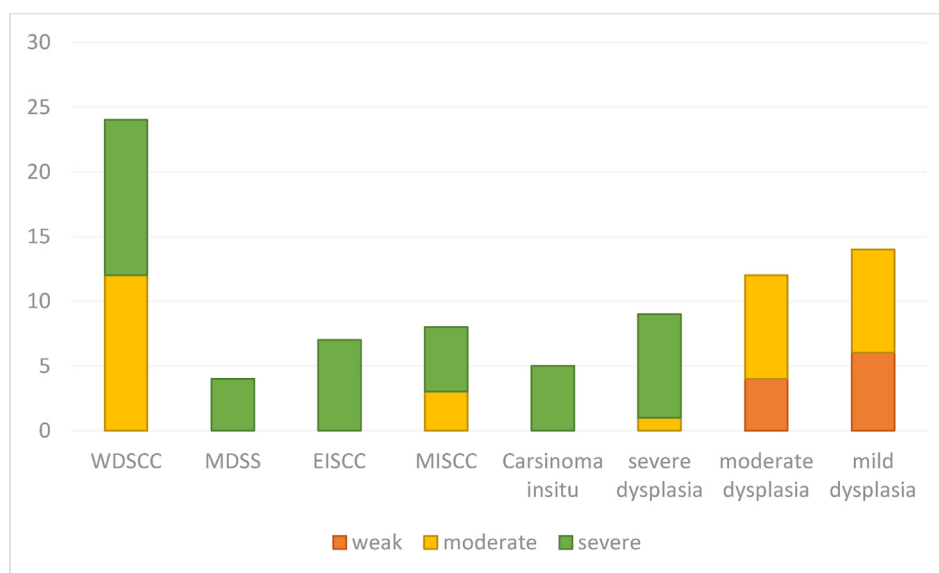
differentiated OSCC samples showed strong staining indicating similar behavior between these lesions. In research by Racula et al. (2015), a higher level of PDPN expression was observed in MDOSCC and PDOSCC than WDOSCC. The researchers also observed a gradual transition in staining intensity, from mild to severe patterns, from WDOSCC to PDOSCC.<sup>48</sup> The limited occurrence of MDOSCC and the absence of PDOSCC in our study support these conclusions. In contrast, Aiswarya et al. have demonstrated a significant presence of PDPN in WDOSCC and less pronounced severity in MDOSCC.<sup>29</sup>

Comparison of PDPN staining intensity between MiOSCC and EiOSCC indicated that 71% of EiOSCC

**Table 4: Distribution of inflammation and lymphoid vessels.**

Group	Inflammation				Lymphatic vessels		
	None	Mild	Moderate	Severe	Mild	Moderate	Severe
WDSCC	5 55.60%	6 20.70%	1 5.90%	10 45.50%	3 16.70%	3 13.60%	16 43.20%
MDSCC	4 44.40%	0 0.00%	0 0.00%	0 0.00%	0 0.00%	1 4.50%	3 8.10%
Early invasive SCC	0 0.00%	0 0.00%	4 23.50%	3 13.60%	0 0.00%	2 9.10%	5 13.50%
Micro-invasive SCC	0 0.00%	3 10.30%	4 23.50%	1 4.50%	1 5.60%	3 13.60%	4 10.80%
Carcinoma in situ	0 0.00%	0 0.00%	2 11.80%	3 13.60%	0 0.00%	2 9.10%	3 8.10%
Severe dysplasia	0 0.00%	4 13.80%	2 11.80%	3 13.60%	3 16.70%	3 13.60%	3 8.10%
Moderate dysplasia	0 0.00%	7 24.10%	3 17.60%	1 4.50%	4 22.20%	6 27.30%	1 2.70%
Mild dysplasia	0 0.00%	9 31.00%	1 5.90%	1 4.50%	7 38.90%	2 9.10%	2 5.40%
Total	9 100.00%	29 100.00%	17 100.00%	22 100.00%	18 100.00%	22 100.00%	37 100.00%





**Graph 1:** IRS scoring in oral dysplasia and squamous cell carcinoma.

samples and 37% of MiOSCC samples showed strong staining, thus highlighting the distinction between these entities. Therefore this difference in expression intensity indicates that two groups are distinct and can be associated with their differing aggressive behaviors.

In this study, comparison of PDPN IHC staining intensity in dysplastic lesions indicated that 100% of CIS samples, 77% of severe dysplasia samples, 11% of moderate dysplasia samples, and 9% of mild dysplasia samples showed strong staining, in agreement with findings by Patil et al.<sup>44</sup> Therefore, although the difference between CIS and severe dysplasia was not statistically significant, CIS should be considered distinct from severe dysplasia. Notably, the 2017 WHO classification groups severe dysplasia and CIS in the same category<sup>45</sup>; however, our findings suggest that the behavior of CIS differs from that of severe dysplasia.

#### *Distribution of IHC PDPN staining*

There was a significant association in the distribution of IHC staining across the groups. In SCC samples, the distribution of stained cells was predominantly diffuse, whereas in dysplastic lesions, it was mostly focal. This pattern was consistent with H&E staining findings, because of the variability in the affected areas where dysplastic changes occur. In this study, diffuse staining was observed in 54% of WDOSCC samples and 100% of MDOSCC samples, thus suggesting that lower OSCC differentiation is associated with more invasive behavior. Additionally, 50% of MiOSCC and 100% of EiOSCC samples exhibited diffuse staining; these findings indicated that invasive cells tend to spread more diffusely as the depth of tumoral cell invasion increases.

In dysplastic lesions, diffuse staining correlated primarily with the severity of dysplasia. Diffuse staining was observed in 40% of CIS samples and 55% of severe dysplasia samples, probably because of the varying degrees of dysplasia within

the affected areas, which could sometimes be observed in the H&E slides.

#### *PDPN expression in various layers of the epithelium*

Our study also analyzed PDPN expression in various layers of the epithelium. PDPN-positive cells were significantly present in most patients with dysplasia, predominantly in the basal and parabasal regions. The difference in PDPN expression between the basal and parabasal regions in OSCC samples was not significant, in agreement with the findings of Patil et al.,<sup>44</sup> Deepa et al.,<sup>40</sup> and Srinivasan et al.<sup>47</sup> In a study on cervical SCCs, PDPN expression has been observed in the basal layer, with gradual expression extending to the upper surface layers.<sup>49</sup> Therefore, PDPN expression reaching the suprabasal layers in some cases of oral dysplasia suggests a similarity between dysplastic suprabasal cells and basal or stem cells, and indicates upward clonal expansion of dysplastic cells. Cases of oral leukoplakia exhibiting clonal expansion during carcinogenesis may have a considerably elevated likelihood of malignant transformation.<sup>50</sup> PDPN has been proposed as a potential marker for cells with stem cell characteristics, which aid in colony formation in laboratory settings.<sup>51,52</sup> The distinct presence of PDPN in cells in the basal layer suggests its tendency to be expressed in primary and undeveloped cells.<sup>53</sup> Previous studies have noted an elevated risk of cancer in dysplastic lesions because of the upward clonal expansion of abnormal cells within the epithelial layers.<sup>44</sup> Identifying these cells beyond the basal layers might provide insight into the potential clonal expansion occurring during tumorigenesis. Tumorigenesis has been found to be driven primarily by a small group of clonogenic cells with unique characteristics, known as tumor-initiating cells or cancer stem cells. In squamous cell carcinoma, PDPN has abnormal expression and is considered a new marker for tumor-initiating cells in early stages of oral tumorigenesis.<sup>31,54</sup>

### Inflammation in IHC PDPN staining samples

Inflammation severity varied between dysplastic and OSCC lesions: dysplastic lesions exhibited primarily mild inflammation, whereas OSCC lesions showed severe inflammation. According to Quintanilla et al., PDPN plays roles in various physiological and pathological processes, including the immune response and cancer.<sup>55</sup> Recent evidence suggests that PDPN expression in immune cells is involved in the regulation of inflammation.<sup>56</sup> However, research by Gülseren et al. has indicated no association between PDPN presence in tumors and various histopathological factors such as tumor thickness, diameter, differentiation, tissue subtype, perineural extension, invasion depth, desmoplastic stromal reaction, or inflammatory response.<sup>57</sup> Although PDPN upregulation in inflamed tissues has been observed in various models of inflammatory tissue injury, the precise intracellular pathway of PDPN remains unclear.<sup>56</sup> Further studies are necessary to clarify PDPN's role in the immune response, particularly regarding macrophage polarization, the regulation of effector T cells, and the interaction between lymphocytes and mesenchymal cells.

### Lymphatic vessels in IHC PDPN staining samples

We observed a statistically significant relationship between the distribution of lymphatic vessels and the pathology sample type: a notably higher number of lymphatic vessels was observed in well-differentiated SCC than mild dysplasia. The number of lymphatic vessels increased with the progression of tumoral cell invasion; these vessels were observed in 50% of MiOSCCs, 71% of EiOSCCs, 72% of WDOSCC samples, and 75% of MDOSCC samples. Dysplasia severity correlated with lymphatic vessel number. Although more lymphatic vessels were present in CIS samples than in severe dysplasia, the difference was not statistically significant. In a study by Srinivasan et al., the mean lymphatic microvessel density (MLVD), was significantly higher in oral leukoplakia and various degrees of OSCC than in normal oral mucosa. Similarly, other studies have shown a substantially higher MLVD in PDOSCC than WDOSCC,<sup>47</sup> in agreement with findings from Aiswarya et al., in which MLVD was higher in oral leukoplakia and OSCC than normal mucosa,<sup>43</sup> as well as our findings.

### Conclusions

EiOSCC exhibits more progressive behavior than MiOSCC, although both are less aggressive than invasive OSCC. This distinction can aid in determining accurate prognosis and treatment options. Together, our data support the potential significance of PDPN in primary oral tumorigenesis and its role in assessing the risk of malignant transformation in patients with premalignant lesions.

### Recommendations

Future research is necessary to investigate the efficacy of PDPN in OSCC detection and of PDPN in the detection of other types of SCC.

### Source of funding

This research did not receive any specific grant from funding agencies in the public, commercial, or not-for-profit sectors.

### Conflict of interest

The authors have no conflict of interest to declare.

### Ethical approval

Ethical approval was obtained from the Institutional Ethical Committee (reference number: IR.SBMU.DRC.REC.1401.026).

### Authors contributions

FM: Conception and design of study, acquisition of data, drafting of article and/or critical revision, final approval of manuscript. M. M.: Conception and design of study, final approval of manuscript, analysis of data. MD: Acquisition of data, analysis of data, drafting of article and/or critical revision, final approval of manuscript. MAM: Conception and design of study, analysis of data, drafting of article and/or critical revision, final approval of manuscript. SG: Conception and design of study, acquisition of data, drafting of article and/or critical revision, final approval of manuscript. All authors have critically reviewed and approved the final draft, and are responsible for the content and similarity index of the manuscript.

### Acknowledgment

None.

### Declaration of generative AI and AI-assisted technologies in the writing process

During the preparation of this work, the authors used ChatGPT 4 from the OpenAI company to improve fluency and grammar. After using this tool, the authors reviewed and edited the content as needed, and take full responsibility for the content of the publication.

### References

1. Dikova V, Jantus-Lewintre E, Bagan J. Potential non-invasive biomarkers for early diagnosis of oral squamous cell carcinoma. *J Clin Med* 2021; 10(8): 1658.
2. Rodrigo JP, García-Carracedo D, González MV, Mancebo G, Fresno MF, García-Pedrero J. Podoplanin expression in the development and progression of laryngeal squamous cell carcinomas. *Mol Cancer* 2010; 9(1): 1–9.
3. Angadi VC, Angadi PV. GLUT-1 immunoexpression in oral epithelial dysplasia, oral squamous cell carcinoma, and verrucous carcinoma. *J Oral Sci* 2015; 57(2): 115–122.
4. Ranganathan K, Kavitha L. Oral epithelial dysplasia: classifications and clinical relevance in risk assessment of oral potentially malignant disorders. *J Oral Maxillofac Pathol* 2019; 23(1): 19–27.



5. Mao L, Papadimitrakopoulou V, Shin DM, Fan Y, Zhou X, Lee JS, et al. Phenotype and genotype of advanced premalignant head and neck lesions after chemopreventive therapy. **J Natl Cancer Inst** 1998; 90(20): 1545–1551.
6. Rudin CM, Cohen EE, Papadimitrakopoulou VA, Silverman Jr S, Recant W, El-Naggar AK, et al. An attenuated adenovirus, ONYX-015, as mouthwash therapy for premalignant oral dysplasia. **J Clin Oncol** 2003; 21(24): 4546.
7. Rhee JC, Khuri FR, Shin DM. Advances in chemoprevention of head and neck cancer. **Oncol** 2004; 9(3): 302–311.
8. Weller M, Nankivell P, McConkey C, Paleri V, Mehanna H. The risk and interval to malignancy of patients with laryngeal dysplasia; a systematic review of case series and meta-analysis. **Clin Otolaryngol** 2010; 35(5): 364–372.
9. Reibel J, Gale N, Hille J, Hunt J, Lingen M, Muller S, et al. Oral potentially malignant disorders and oral epithelial dysplasia. In: *WHO classification of head and neck tumours*; 2017. p. 112.
10. Haberland C, Sasaki C, Judson B, Virk R, Prasad M. Superficially invasive squamous cell carcinoma of the oral cavity. **Oral Surg Oral Med Oral Radiol Oral Pathol** 2012; e56.
11. Mohammed Nur M, Al Saadi M, O'Regan EM, Van Harten M, Toner M. Small and thin oral squamous cell carcinomas may exhibit adverse pathologic prognostic features. **Head Neck Pathol** 2021; 15: 461–468.
12. Wenig BM. Squamous cell carcinoma of the upper aerodigestive tract: dysplasia and select variants. **Mod Pathol** 2017; 30: S112–S128.
13. Sanjai K, Baker A, Reddy LP, Pandey B. Modified Cajal's trichrome stain as a diagnostic aid in the study of epithelial pathology. **Indian J Pathol Microbiol** 2017; 60(4): 528.
14. Wenig BM. Squamous cell carcinoma of the upper aerodigestive tract: precursors and problematic variants. **Mod Pathol** 2002; 15(3): 229–254.
15. Abe H. Clinical and pathological study of dysplasia, early invasive carcinoma and invasive carcinoma (the invasion 5mm deep) in oral cavity. **Ou Daigaku Shigakushi** 1990; 17(3): 372–394.
16. Pentenero M, Navone R, Motta F, Marino R, Gassino L, Broccoletti R, et al. Clinical features of microinvasive stage I oral carcinoma. **Oral Dis** 2011; 17(3): 298–303.
17. Shedd DP, Hukill PB, Kligerman MM, Gowen GF. A clinicopathologic study of oral carcinoma in situ. **Am J Surg** 1963; 106(5): 791–796.
18. Brockhausen I, Schutzbach J, Kuhns W. Glycoproteins and their relationship to human disease. **Cells Tissues Organs** 1998; 161(1–4): 36–78.
19. Zimmer G, Oeffner F, Messling VV, Tschernig T, Gröne H, Klenk H, et al. Cloning and characterization of gp36, a human mucin-type glycoprotein preferentially expressed in vascular endothelium. **Biochem J** 1999; 341(2): 277–284.
20. Ordóñez NG. Podoplanin: a novel diagnostic immunohistochemical marker. **Adv Anat Pathol** 2006; 13(2): 83–88.
21. Breiteneder-Geleff S, Soleiman A, Kowalski H, Horvat R, Amann G, Kriehuber E, et al. Angiosarcomas express mixed endothelial phenotypes of blood and lymphatic capillaries: podoplanin as a specific marker for lymphatic endothelium. **Am J Pathol** 1999; 154(2): 385–394.
22. Xu Y, Ogose A, Kawashima H, Hotta T, Ariizumi T, Li G, et al. High-level expression of podoplanin in benign and malignant soft tissue tumors: immunohistochemical and quantitative real-time RT-PCR analysis. **Oncol Rep** 2011; 25(3): 599–607.
23. Wang H, Hu C, Song X, Hu L, Li W, Yu H, et al. Expression of podoplanin in sinonasal squamous cell carcinoma and its clinical significance. **Am J Rhinol Allergy** 2020; 34(6): 800–809.
24. Prasad B, Kashyap B, Babu G, Kumar G, Manyam R. Expression of podoplanin in different grades of oral squamous cell carcinoma. **Ann Med Health Sci Res** 2015; 5(4): 299–304.
25. Matsui T, Maeda M, Doi Y, Yonemura S, Amano M, Kaibuchi K, et al. Rho-kinase phosphorylates COOH-terminal threonines of ezrin/radixin/moesin (ERM) proteins and regulates their head-to-tail association. **J Cell Biol** 1998; 140(3): 647–657.
26. Muller S, Tilakaratne WM. Update from the 5th edition of the World Health organization classification of head and neck tumors: tumours of the oral cavity and mobile tongue. **Head Neck Pathol** 2022; 16(1): 54–62.
27. Kalele K, Bhondekar V, Dongare S, Khan W, Shelotkar A, Badukale K, et al. Morphology of cells undergoing epithelial mesenchymal transition in microinvasive and early invasive oral squamous cell carcinoma - a light microscopic study. **Pol J Pathol** 2022; 73(3): 244–254.
28. Müller S, Boy SC, Day TA, Magliocca KR, Richardson MS, Sloan P, et al. Data set for the reporting of oral cavity carcinomas: explanations and recommendations of the guidelines from the international collaboration of cancer reporting. **Arch Pathol Lab Med** 2019 Apr; 143(4): 439–446. <https://doi.org/10.5858/arpa.2018-0411-SA>. Epub 2018 Nov 30. PMID: 30500296.
29. Aiswarya A, Suresh R, Janardhanan M, Savithri V, Aravind T, Mathew L. An immunohistochemical evaluation of podoplanin expression in oral leukoplakia and oral squamous cell carcinoma to explore its potential to be used as a predictor for malignant transformation. **J Oral Maxillofac Pathol** 2019; 23(1): 159.
30. Remmele W, Stegner HE. [Recommendation for uniform definition of an immunoreactive score (IRS) for immunohistochemical estrogen receptor detection (ER-ICA) in breast cancer tissue]. **Pathologe** 1987; 8(3): 138–140.
31. Kawaguchi H, El-Naggar AK, Papadimitrakopoulou V, Ren H, Fan Y-H, Feng L, et al. Podoplanin: a novel marker for oral cancer risk in patients with oral premalignancy. **J Clin Oncol** 2008; 26(3): 354–360.
32. Bagan J, Sarrion G, Jimenez Y. Oral cancer: clinical features. **Oral Oncol** 2010; 46(6): 414–417.
33. Shield KD, Ferlay J, Jemal A, Sankaranarayanan R, Chaturvedi AK, Bray F, et al. The global incidence of lip, oral cavity, and pharyngeal cancers by subsite in 2012. **CA A Cancer J Clin** 2017; 67(1): 51–64.
34. Barber LJ, Davies MN, Gerlinger M. Dissecting cancer evolution at the macro-heterogeneity and micro-heterogeneity scale. **Curr Opin Genet Dev** 2015; 30: 1–6.
35. Jolly C, Van Loo P. Timing somatic events in the evolution of cancer. **Genome Biol** 2018; 19(1): 1–9.
36. Wodarz D, Newell AC, Komarova NL. Passenger mutations can accelerate tumour suppressor gene inactivation in cancer evolution. **J R Soc Interface** 2018; 15(143): 20170967.
37. Chierici G. A tumor registry study of oral squamous cell carcinoma. **J Oral Med** 1968; 23: 91–98.
38. Wright A, Shear M. Epithelial dysplasia immediately adjacent to oral squamous cell carcinomas. **J Oral Pathol** 1985; 14(7): 559–564.
39. Melo BAdC, Vilar LG, Oliveira NRd, Lima POd, Pinheiro MdB, Domingueti CP, et al. Human papillomavirus infection and oral squamous cell carcinoma-a systematic review. **Brazilian J Otorhinol** 2021; 87: 346–352.
40. Deepa A, Janardanan-Nair B, Varun B. Podoplanin expression in oral potentially malignant disorders and oral squamous cell carcinoma. **J Clin Experi Dent** 2017; 9(12): e1418.
41. Yadav A, Singh PK, Yadav N, Kaushik R, Chandan K, Chandra A, et al. Smokeless tobacco control in India: policy review and lessons for high-burden countries. **BMJ Glob Health** 2020; 5(7).
42. Akbari ME, Moghadam SA, Moghadam FA, Bastani Z. Malignant tumors of tongue in Iranian population. **Iran J Cancer Prev** 2016; 9(4).
43. Aiswarya A, Suresh R, Janardhanan M, Savithri V, Aravind T, Mathew L. An immunohistochemical evaluation of podoplanin

- expression in oral leukoplakia and oral squamous cell carcinoma to explore its potential to be used as a predictor for malignant transformation. **J Oral Maxillofac Pathol: JOMFP** 2019; 23(1): 159.
44. Patil A, Patil K, Tupsakhare S, Gabhane M, Sonune S, Kandalgaonkar S. Evaluation of podoplanin in oral leukoplakia and oral squamous cell carcinoma. **Scientifica** 2015; 2015.
  45. El-Naggar AK. WHO classification of head and neck tumours. **Inter Agency** 2017.
  46. Logeswari J, Malathi N, Thamizhchelvan H, Sangeetha N, Nirmala SV. Expression of podoplanin in oral premalignant and malignant lesions and its potential as a biomarker. **Indian J Dent Res** 2014; 25(3): 305.
  47. Srinivasan V, Shyam N, Kumar GK, Narayan V, Konda P, Rani KS, et al. A comparison of podoplanin expression in oral leukoplakia and oral squamous cell carcinoma: an immunohistochemical study. **Cureus** 2023; 15(5).
  48. Ciurea RN, Stepan A, Simionescu C, Margaritescu C, Patrascu V, Ciurea M. The role of podoplanin in the lymphangiogenesis of oral squamous carcinomas. **Cur Health Sci J** 2015; 41(2): 126.
  49. Qiao X, Sun Y, Zou Y, Lin J, Xu W, Zong Y, et al. Immunohistochemical staining of podoplanin is helpful in determining the microinvasion of cervical squamous cell carcinoma. **Ann Diagn Pathol** 2020; 46:151493.
  50. Parhar S, Kaur H, Vashist A, Verma S. Role of podoplanin in potentially malignant disorders and oral squamous cell carcinoma and its correlation with lymphangiogenesis. **Indian J Cancer** 2015; 52(4): 617–622.
  51. Ugorski M, Dziegiel P, Suchanski J. Podoplanin-a small glycoprotein with many faces. **Am J Cancer Res** 2016; 6(2): 370.
  52. Atsumi N, Ishii G, Kojima M, Sanada M, Fujii S, Ochiai A. Podoplanin, a novel marker of tumor-initiating cells in human squamous cell carcinoma A431. **Biochem Biophys Res Commun** 2008; 373(1): 36–41.
  53. Mishima K, Kato Y, Kaneko MK, Nakazawa Y, Kunita A, Fujita N, et al. Podoplanin expression in primary central nervous system germ cell tumors: a useful histological marker for the diagnosis of germinoma. **Acta Neuropathol** 2006; 111: 563–568.
  54. de Vicente JC, Rodrigo JP, Rodriguez-Santamarta T, Lequerica-Fernández P, Allonca E, García-Pedrero JM. Podoplanin expression in oral leukoplakia: tumorigenic role. **Oral Oncol** 2013; 49(6): 598–603.
  55. Quintanilla M, Montero-Montero L, Renart J, Martín-Villar E. Podoplanin in inflammation and cancer. **Int J Mol Sci** 2019; 20(3): 707.
  56. Zhang Z, Zhang N, Yu J, Xu W, Gao J, Lv X, et al. The role of podoplanin in the immune system and inflammation. **J Inflamm Res** 2022; 3561–3572.
  57. Gülseren D, Gököz Ö, Karahan S, Karaduman A. Podoplanin expression in cutaneous squamous cell carcinomas and its relationship to histopathological prognostic factors. **J Histotechnol** 2020; 43(3): 147–152.

**How to cite this article:** Mashhadiabbas F, Chaffjiri MM, Dashti M, Mudasser MA, Gholami S. Podoplanin expression in various types of oral dysplasia and oral squamous cell carcinoma. *J Taibah Univ Med Sc* 2025;20(1):40–51.