

CCHF in which the patient died of complications following surgical intervention for cerebral hemorrhage (8).

Death from CCHF usually occurs after 5–14 days of illness (1,8,9). The basic pathogenesis of CCHF virus at the molecular level is complex and not well defined. Endothelial cells, immune response, virus load, and coagulation cascade play major roles in the disease pathogenesis. Blood and endothelium appear to be the target tissues of the disease (9). The coagulation cascade becomes activated over 24–48 hours; however, thrombin becomes activated and promotes edema formation and further disruption of the integrity of the blood–brain barrier. The edema formation starts when erythrocytes in the hematoma begin to lyse and its degradation products are deposited into the brain parenchyma, initiating a potent inflammatory reaction (10).

Although surgery remains the first choice for the treatment of acute subdural hematoma, some patients may benefit from conservative management with careful monitoring. This report highlights the value of an early diagnosis of CCHF and neuroimaging for severe cases when brain hemorrhage is suspected.

References

1. Karti SS, Odabasi Z, Korten V, Yilmaz M, Sonmez M, Caylan R, et al. Crimean-Congo hemorrhagic fever in Turkey. *Emerg Infect Dis*. 2004;10:1379–84. <http://dx.doi.org/10.3201/eid1008.030928>
2. Nabeth P, Cheikh DO, Lo B, Faye O, Vall IO, Niang M, et al. Crimean–Congo hemorrhagic fever, Mauritania. *Emerg Infect Dis*. 2004;10:2143–9. <http://dx.doi.org/10.3201/eid1012.040535>
3. Nabeth P, Thior M, Faye O, Simon F. Human Crimean–Congo hemorrhagic fever, Senegal. *Emerg Infect Dis*. 2004;10:1881–2. <http://dx.doi.org/10.3201/eid1010.040586>
4. Depreitere B, Van Calenbergh F, van Loon J. A clinical comparison of non-traumatic acute subdural haematomas either related to coagulopathy or of arterial origin without coagulopathy. *Acta Neurochir (Wien)*. 2003;145:541–6. <http://dx.doi.org/10.1007/s00701-003-0020-7>
5. Alavi-Naini R, Moghtaderi A, Metanat M. An unusual intracerebral hemorrhage. *Can J Infect Dis Med Microbiol*. 2004;15:175–7.
6. Elata AT, Karsany MS, Elageb RM, Hussain MA, Eltom KH, Elbashir MI, et al. A nosocomial transmission of Crimean-Congo hemorrhagic fever to an attending physician in North Kordufan, Sudan. *Viol J*. 2011;8:303. <http://dx.doi.org/10.1186/1743-422X-8-303>
7. Kumar R, Prakash O, Sharma BS. Intracranial hemorrhage in dengue fever: management and outcome: a series of 5 cases and review of literature. *Surg Neurol*. 2009;72:429–33. <http://dx.doi.org/10.1016/j.surneu.2009.01.021>
8. Swanepoel R, Shepherd AJ, Leman PA, Shepherd SP, Miller GB. A common-source outbreak of Crimean-Congo haemorrhagic fever on a dairy farm. *S Afr Med J*. 1985;68:635–7.
9. Duru F, Fisgin T. Hematological aspects of Crimean-Congo hemorrhagic fever. *Turk J Hematol*. 2009;26:161–6.
10. Thiex R, Tsirka SE. Brain edema after intracerebral hemorrhage: mechanisms, treatment options, management strategies, and operative indications. *Neurosurg Focus*. 2007;22:E6. <http://dx.doi.org/10.3171/foc.2007.22.5.7>

Address for correspondence: Ahmed S. Kleib, Department of Neurosurgery, Centre Hospitalier National, BP 612, Nouakchott, Mauritania; email: remyk@yahoo.fr

Use of Plasma Therapy for Severe Fever with Thrombocytopenia Syndrome Encephalopathy

Se Yoon Park,¹ WooYoung Choi,¹ Yong Pil Chong, Sun-Wan Park, Eun Byeol Wang, Won-Ja Lee, Youngmee Jee, Seog-Woon Kwon, Sung-Han Kim

Author affiliations: Asan Medical Center, University of Ulsan College of Medicine, Seoul, South Korea (S.Y. Park, Y.P. Chong, S.-W. Kwon, S.-H. Kim); Korea Centers for Disease Control and Prevention, Cheongju, South Korea (W. Choi, S.-W. Park, E.B. Wang, W.-J. Lee, Y. Jee)

DOI: <http://dx.doi.org/10.3201/eid2207.151791>

To the Editor: The central nervous system (CNS) manifestations of severe fever with thrombocytopenia syndrome (SFTS) include apathy, seizure, muscular tremor, and coma (1,2); however, the mechanism underlying CNS manifestations in SFTS is not clear. Deng et al. reported that illness of 15 (13%) of 115 patients with SFTS met the case definition for suspected encephalitis (1). However, they did not present any straightforward evidence of CNS invasion by SFTS virus (SFTSV). Cui et al. similarly reported that encephalitis developed in one fifth of 538 patients with SFTS (2). They found evidence of SFTSV by isolating the virus from the cerebrospinal fluid (CSF) in 1 of 2 patients with SFTS whose CSF was obtained, but they did not mention CSF pleocytosis (2). We report a case of SFTS-associated encephalopathy, without pleocytosis and with normal CSF protein and glucose levels, that was confirmed by real-time reverse transcription PCR of the CSF. The patient was treated with experimental plasma exchange followed by convalescent plasma therapy.

During 2015, a 62-year-old woman who had a history of treated tuberculous meningitis 10 years earlier was admitted to a tertiary hospital in Seoul, South Korea (Republic of Korea), with a 5-day fever, myalgia, and headache. On hospital day (HD) 2, CSF examination revealed 1 leukocyte/mm³, protein 35 mg/dL (reference 9–58 mg/dL), glucose 74 mg/dL (reference 45–80 mg/dL), and CSF/blood glucose ratio 0.66 (reference 0.50–0.80). No bacteria or fungi were isolated from CSF. On HD 4, her headache worsened, and she displayed confused verbal responses and lacked orientation of time and place. No focal neurologic signs were observed. On HD 5, magnetic resonance imaging of the brain indicated no additional abnormalities of the parenchyma and extra-axial structures except for a focal parenchymal defect in the right midbrain that had been discovered as a

¹These authors contributed equally to this article.

sequelae of tuberculous meningitis 10 years earlier. On HD 7, follow-up CSF examination revealed no leukocytes, protein 57 mg/dL, glucose 209 mg/dL, and CSF/blood glucose ratio 0.62. SFTSV was detected by real-time reverse transcription PCR (online Technical Appendix, <http://wwwnc.cdc.gov/EID/article/22/7/15-1791-Techapp1.pdf>) in plasma and CSF (Figure). On HD 8, the patient became comatose and had no eye, verbal, and motor responses to noxious stimuli (Glasgow coma scale 3). Bilateral exotropia was noted with spared light and corneal reflexes and oculocephalic responses. Experimental plasma exchange was performed, and her viral load declined slightly; however, consciousness and platelet count did not change. An ABO-identical nurse who had recovered from SFTS in September 2014 agreed to donate plasma; her indirect immunofluorescence antibody assay (IFA) for SFTSV IgG had been 1:1,024 in October 2014. On HD 17, the patient's titer of SFTSV IgG was 1:64 before the plasma therapy. We obtained ≈ 400 mL of convalescent plasma (IFA assay for SFTSV IgG 1:256 at the time of donation) from the donor and transfused it into the patient on HD 17. The viral load in the blood decreased steeply by a factor of 10 (6×10^2 to 6×10^1 copies/mL) during the first 7 hours (4–11 PM on HD 17); it then gradually decreased from 3×10^1 at 7 AM on HD 18 to 6×10^0 copies/mL on HD 20, by which time the patient's mental status had fully recovered (Figure).

This case is unique in that SFTS was detected in CSF in the absence of pleocytosis and with normal CSF protein and glucose levels, as in previous reports on influenza-associated acute encephalopathy (3). Although headache and encephalitis can occur in patients with SFTS (1,2), the pathophysiology of CNS manifestations in SFTS is unknown. As with influenza-associated acute encephalopathy, a possible hypothesis is direct invasion of SFTSV into the CNS; another hypothesis is that elevated cytokine levels or renal and hepatic dysfunction are associated with SFTS encephalopathy.

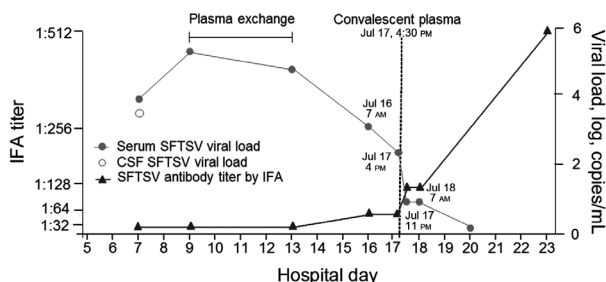


Figure. Changes in viral RNA load and immunofluorescence antibody titer and timing of therapies for a 62-year-old woman with SFTSV-associated encephalopathy in response to plasma exchange followed by convalescent plasma therapy, South Korea, 2015. CSF, cerebrospinal fluid; IFA, indirect immunofluorescence antibody assay; SFTSV, severe fever with thrombocytopenia syndrome virus.

We are aware of 1 report of a favorable outcome of plasma exchange and ribavirin in 2 patients with SFTS and multiorgan failure in South Korea (4). However, the patients' clinical condition did not substantially improve despite the 5-day plasma exchange therapy and viral load only slightly decreased. Use of convalescent plasma therapy in severe acute respiratory syndrome, influenza A(H1N1) and A(H5N1), and Ebola virus disease has been reported (5–7), but little evidence exists to support its use. However, given the lack of conclusive data, these potential experimental treatments for emerging infectious diseases warrant further study in a clinical trial. Response was favorable in a mouse model of SFTS treated postexposure with antiserum from a patient who had recovered from SFTS (8).

We do not know whether the convalescent plasma therapy given to the patient described here actually had a positive effect because her IFA titer was already increasing around the time she received the plasma therapy. At the time of this writing, 2 patients with SFTS who were treated with intravenous immunoglobulin and corticosteroid had been reported (9). Cautious interpretation of these experimental therapies is necessary because these therapies may not have had anything to do with the patients' recovery.

Acknowledgments

We thank Kye-Hyung Kim and Jongyoung Yi for performing initial work to demonstrate the evidence of CNS invasion with keen comments on the study.

This study was supported by grants from the Korea Health Technology Research & Development Project through the Korea Health Industry Development Institute, funded by the Ministry of Health and Welfare, Republic of Korea (grant no. HI15C2774) and the Korea Centers for Disease Control and Prevention (grant no. 4800-4837-301).

References

- Deng B, Zhou B, Zhang S, Zhu Y, Han L, Geng Y, et al. Clinical features and factors associated with severity and fatality among patients with severe fever with thrombocytopenia syndrome bunyavirus infection in northeast China. *PLoS One*. 2013;8:e80802. <http://dx.doi.org/10.1371/journal.pone.0080802>
- Cui N, Liu R, Lu QB, Wang LY, Qin SL, Yang ZD, et al. Severe fever with thrombocytopenia syndrome bunyavirus-related human encephalitis. *J Infect*. 2015;70:52–9. <http://dx.doi.org/10.1016/j.jinf.2014.08.001>
- Moon SM, Kim SH, Jeong MH, Lee EH, Ko TS. Acute encephalopathy and pandemic (H1N1) 2009. *Emerg Infect Dis*. 2010;16:1811–3. <http://dx.doi.org/10.3201/eid1611.100682>
- Oh WS, Heo ST, Kim SH, Choi WJ, Han MG, Kim JY. Plasma exchange and ribavirin for rapidly progressive severe fever with thrombocytopenia syndrome. *Int J Infect Dis*. 2014;18:84–6. <http://dx.doi.org/10.1016/j.ijid.2013.08.011>
- Mair-Jenkins J, Saavedra-Campos M, Baillie JK, Cleary P, Khaw FM, Lim WS, et al. The effectiveness of convalescent plasma and hyperimmune immunoglobulin for the treatment of severe acute respiratory infections of viral etiology: a systematic

- review and exploratory meta-analysis. *J Infect Dis.* 2015; 211:80–90. <http://dx.doi.org/10.1093/infdis/jiu396>
6. Zhou B, Zhong N, Guan Y. Treatment with convalescent plasma for influenza A (H5N1) infection. *N Engl J Med.* 2007;357:1450–1. <http://dx.doi.org/10.1056/NEJMc070359>
 7. van Griensven J, Edwards T, de Lamballerie X, Semple MG, Gallian P, Baize S, et al. Evaluation of convalescent plasma for Ebola virus disease in Guinea. *N Engl J Med.* 2016;374:33–42. <http://dx.doi.org/10.1056/NEJMoa1511812>
 8. Shimada S, Posadas-Herrera G, Aoki K, Morita K, Hayasaka D. Therapeutic effect of post-exposure treatment with antiserum on severe fever with thrombocytopenia syndrome (SFTS) in a mouse model of SFTS virus infection. *Virology.* 2015;482:19–27. <http://dx.doi.org/10.1016/j.virol.2015.03.010>
 9. Kim UJ, Kim DM, Ahn JH, Kang SJ, Jang HC, Park KH, et al. Successful treatment of rapidly progressing severe fever with thrombocytopenia syndrome with neurological complications using intravenous immunoglobulin and corticosteroid. *Antivir Ther.* 2016 Feb 17. Epub ahead of print. <http://dx.doi.org/10.3851/IMP3036>

Address for correspondence: Sung-Han Kim, Department of Infectious Diseases, Asan Medical Center, University of Ulsan College of Medicine, 86 Asanbyeongwon-Gil, Songpa-Gu, Seoul, 138-736, Republic of Korea; email: kimsunghanmd@hotmail.com

Naturally Circulating Hepatitis A Virus in Olive Baboons, Uganda

Andrew J. Bennett, Samuel D. Sibley, Michael Lauck, Geoffrey Weny, David Hyeroba, Alex Tumukunde, Thomas C. Friedrich, David H. O'Connor, Caley A. Johnson, Jessica M. Rothman, Tony L. Goldberg

Author affiliations: University of Wisconsin, Madison, Wisconsin, USA (A.J. Bennett, S.D. Sibley, T.L. Goldberg); Wisconsin National Primate Research Center, Madison (M. Lauck, T.C. Friedrich, D.H. O'Connor, T.L. Goldberg); Makerere University, Kampala, Uganda (G. Weny, D. Hyeroba, A. Tumukunde, J.M. Rothman, T.L. Goldberg); Graduate Center of City University of New York, New York, New York, USA (C.A. Johnson, J.M. Rothman); New York Consortium in Evolutionary Primatology, New York (C.A. Johnson, J.M. Rothman); Hunter College of the City University of New York, New York (J. Rothman).

DOI: <http://dx.doi.org/10.3201/eid2207.151837>

To the Editor: Hepatitis A (HAV; family *Picornaviridae*; genus *Hepatovirus*) is an ≈ 7.5 -kb single-stranded positive-sense RNA virus that causes acute inflammation of the liver in humans and nonhuman primates. Although HAV is most commonly transmitted by food and water contaminated with feces, humans have acquired HAV from handling infected nonhuman primates in captivity (1).

HAV has been detected in recently imported captive primates after spontaneous outbreaks of acute hepatitis in animal facilities, but the definitive hosts of this virus have remained obscure (2,3). We identified by next-generation sequencing HAV in the blood of a free-living olive baboon (*Papio anubis*) from Kibale National Park, Uganda, sampled in September 2010. Subsequent testing of a separate Kibale olive baboon troop in 2014 indicated the virus was prevalent and shed in feces.

As part of a long-term study of nonhuman primate health and ecology, 23 animals were immobilized and sampled in 2010 as previously described (4). All animal protocols received prior approval from the Uganda National Council for Science and Technology (Kampala, Uganda), the Uganda Wildlife Authority (Kampala, Uganda), and the University of Wisconsin–Madison Animal Care and Use Committee (Madison, WI, USA). All samples were shipped in accordance with international laws under Convention on International Trade in Endangered Species of Wild Fauna and Flora Ugandan permit no. 002290.

During May 2012, we subjected total RNA from 1 mL of blood plasma of each animal to next-generation sequencing as previously described (4); results showed HAV-like sequences in 1 of 23 baboons. De novo assembly of these reads yielded a nearly complete HAV genome, which we term KibOB-1. KibOB-1 is most similar (94.2% nt identity; Figure) to AGM-27, an HAV originally detected in an African green monkey (*Chlorocebus aethiops*) imported to a Russian primate facility from Kenya (3).

For 11 baboons, we also collected a paired fecal sample, which we analyzed for evidence of viral shedding. Samples were preserved in RNAlater (Ambion Inc., Austin, TX, USA) at -20°C , and viral RNA was isolated by using the ZR Soil/Fecal RNA Microprep kit (Zymo Research, Irvine, CA, USA) following manufacturer's protocols. Reverse transcription PCR (RT-PCR) of RNA was primed with random hexamers by using the RNA to cDNA Ecody Premix (Random Hexamers) (Clontech Laboratories, Inc., Mountain View, CA, USA), and diagnostic PCR was conducted with primers flanking the C-terminal extension of the HAV viral protein (VP) 1 gene (*pX*) by using the High Fidelity PCR Master Mix-Ecody Premix (Clontech Laboratories, Inc.). Five of 11 paired fecal samples tested positive for HAV by RT-PCR, indicating a higher prevalence of the virus in feces than in blood.

We then surveyed a second troop of habituated olive baboons at the same field site during February–April 2014 (5). From these baboons, 7 of 19 fecal samples tested positive by RT-PCR. Confirmatory Sanger sequencing of RT-PCR amplicons was successful for 3 of these 7 animals (GenBank accession nos. KT819576–KT819578). Phylogenetic analyses of these sequences demonstrate monophyly and a low degree of interhost variability ($\geq 94\%$ nt identity).