

Lens Densitometry after Corneal Cross-linking in Patients with Keratoconus Using a Scheimpflug Camera

Alireza Baradaran-Rafii¹, MD; Mohammad Aghazazeh Amiri², OD; Sahar Mohaghegh^{2,3}, MS
Mehran Zarei-Ghanavati⁴, MD

¹Ocular Tissue Engineering Research Center, Shahid Beheshti University of Medical Sciences, Tehran, Iran

²Department of Optometry, Shahid Beheshti University of Medical Sciences, Tehran, Iran

³Ophthalmic Research Center, Shahid Beheshti University of Medical Sciences, Tehran, Iran

⁴Eye Research Center, Farabi Eye Hospital, Tehran University of Medical Sciences, Tehran, Iran

Abstract

Purpose: To evaluate changes in crystalline lens densitometry following corneal cross-linking (CXL) in keratoconic patients.

Methods: In a quasi-experimental study, three-dimensional lens densitometry was performed using the Pentacam Scheimpflug camera (Oculus Optikgerate GmbH, Wetzlar, Germany) at baseline and six months after CXL. Densitometry was performed in a fixed area of 2 inch × 1 inch of the anterior capsule and anterior lens cortex. The subject group included patients with progressive keratoconus who underwent CXL ($n = 40$) and the control group was comprised of aged-matched patients with non-progressive keratoconus ($n = 36$).

Results: Mean age of the case and control groups was 25.8 ± 4.0 and 25.0 ± 4.1 years, respectively ($P = 0.392$). Mean lens density in the CXL group was $6.68\% \pm 0.58\%$ at baseline and $6.77\% \pm 0.53\%$ at the last visit ($P = 0.352$). Corresponding figures in the control group were $6.53\% \pm 0.27\%$ and $6.39\% \pm 0.31\%$, respectively ($P = 0.213$). There was no significant difference between the study groups at baseline or six months later ($P = 0.96$).

Conclusion: In this short term study with six months' follow-up, we observed no significant impact on lens density following exposure of the crystalline lens to ultraviolet A and riboflavin free radicals in the CXL procedure.

Keywords: Corneal Cross-linking; Free Radicals; Lens Clarity; Scheimpflug Camera

J Ophthalmic Vis Res 2015; 10 (2): 118-122.

INTRODUCTION

Collagen cross-linking (CXL) is a corneal tissue strengthening technique that halts the progression of

keratoconus^[1] and corneal ectasia following laser *in situ* keratomileusis (LASIK).^[2] It has also been used in poor candidates for laser refractive surgery,^[3] in corneal melting processes,^[4] pellucid marginal degeneration,^[5] corneal edema,^[6] bullous keratopathy,^[7] *in vitro* fungal keratitis^[8] and infectious keratitis not responding to treatment.^[9] Ultraviolet A (UVA) irradiation (370 nm wavelength) and a photosensitizer, i.e., riboflavin, are used during the CXL procedure.^[2]

The mechanism of CXL is not entirely understood. Following riboflavin exposure to UVA, these molecules

Correspondence to:

Sahar Mohaghegh, MS. Ophthalmic Research Center, Shahid Beheshti University of Medical Sciences, No. 23, Paidarfard Street, Boostan 9 Street, Pasdaran Avenue, Tehran 16666, Iran.

E-mail: mohaghegh_sahar@yahoo.com

Received: 07-10-2013

Accepted: 14-06-2014

Access this article online

Quick Response Code:



Website:
www.jovr.org

DOI:
10.4103/2008-322X.163776

This is an open access article distributed under the terms of the Creative Commons Attribution-NonCommercial-ShareAlike 3.0 License, which allows others to remix, tweak, and build upon the work non-commercially, as long as the author is credited and the new creations are licensed under the identical terms.

For reprints contact: reprints@medknow.com

How to cite this article: Baradaran-Rafii A, Amiri MA, Mohaghegh S, Zarei-Ghanavati M. Lens densitometry after corneal cross-linking in patients with keratoconus using a Scheimpflug camera. *J Ophthalmic Vis Res* 2015;10:118-22.

are excited into a triplet state, thereby generating reactive oxygen species. Current thinking is that interaction of reactive oxygen with available groups nearby leads to formation of additional covalent bonds between collagen molecules in the cornea.^[10] The consequence of these biomechanical reactions is stiffening of the corneal tissue.^[10]

Oxidative stress is apparent in pathologies associated with many aging diseases including atherosclerosis, diabetes mellitus, rheumatoid arthritis and neurodegenerative diseases.^[11] UV irradiation is one of the most important factors for inducing oxidative stress. The role of UVA irradiation in the pathogenesis of several eye diseases including pinguecula, pterygium, cataracts, glaucoma and retinopathies has been demonstrated.^[12] Epidemiological studies have indicated that UV radiation is one of the primary factors leading to senile cataract formation.^[13] The strongest hypothesis regarding the cataractogenic effect of UVA concerns photochemical generation of reactive oxygen species in the aqueous and lens.^[14-16]

During CXL, the eye and its important visual elements including the lens and retina are exposed to UVA irradiation. Although riboflavin acts as a photo-blocker and an insignificant amount of UVA directly reaches inner ocular tissues,^[17] it generates reactive oxygen species (free radicals) following UVA exposure that can cause cell damage. By diffusion through the cornea, free radicals may enter the anterior chamber and in this way come in contact with the crystalline lens.

Diffusion of free radicals may theoretically lead to adverse effects including endothelial damage and alteration in crystalline lens clarity. The detrimental effects of UVA irradiation on the corneal endothelium, especially in eyes with thin cornea (less than 400 μm), has already been established.^[18] Recently, there have been reports of endothelial damage after standard CXL procedures (corneal thickness $>400 \mu\text{m}$).^[19,20] To the best of our knowledge, there are no reports on the cataractogenic effect of UVA irradiation during CXL procedures. In two previous studies, it has been shown that there are no lens density changes following CXL treatment.^[21,22] Considering safety issues involved in CXL, more studies are needed in this area. The purpose of the current study was to evaluate changes in lens density six months after CXL using a Scheimpflug camera.

METHODS

Study Participants

This quasi-experimental study was conducted at Labbafinejad Medical Center, Shahid Beheshti Medical University, Tehran, Iran, from January 2012 to July 2012. Forty eyes of 25 patients and 36 eyes of 18 aged-matched patients were included in the subject and control groups,

respectively. All potential patients with keratoconus had been regularly followed-up in the cornea clinic. During each visit, a complete eye examination including uncorrected visual acuity (UCVA) and best spectacle-corrected visual acuity (BSCVA) measurements, as well as refraction and topography (Orbscan IIz, Bausch and Lomb, Rochester, NY, USA) were performed. Patients with progressive keratoconus and no evidence of corneal scarring were included in the subject group for CXL surgery, while patients with non-progressive keratoconus were included in the control group.

On topography, progression of keratoconus was defined as 1 diopter increase in maximum keratometry or at least a 50 μm decrease in corneal thickness over one year. Ultrasonic pachymetry (Nidek UP-1000, Nidek Technologies, Gamagori, Japan) was performed for all patients in the subject group prior to CXL. Patients with corneal thickness less than 400 μm at the thinnest point, evidence of crystalline lens opacity, severe dry eye, concurrent corneal infections, pregnancy, concomitant autoimmune diseases, any systemic collagen vascular diseases and prior incisional refractive surgery (radial keratotomomy or astigmatic keratotomomy) were excluded. All patients provided informed consent after receiving a detailed description of the nature of the treatment.

Corneal Collagen Cross-linking Procedure

The standard CXL procedure was performed including instillation of topical anesthesia (tetracaine 0.5%) and mechanical epithelial removal from the central 8 mm zone of the cornea with a surgical blade. Prior to UVA irradiation, riboflavin 0.1% solution (10 mg riboflavin in 10 mL dextran 20% solution) was instilled every three minutes for 30 min. Instillation was continued every three minutes for an additional 30 min during irradiation. A UV-X device (IROC, Zürich, Switzerland) was used to deliver UVA irradiation. The instrument was set at a safe working distance of 5 cm from the corneal surface with a medium size aperture at a wavelength of 370 nm and surface irradiance of 3 mW/cm^2 . A calibrated UVA meter (LaserMate-Q, LASER 2000, Wessling, Germany) was used to control the desired levels of irradiance prior to each treatment.

After treatment, the patient received topical ciprofloxacin 0.3% and betamethasone 0.1% with an extended-wear night and day bandage contact lens (CIBA Vision). Antibiotic drops, four times daily, were continued until complete re-epithelialization of the cornea. Steroid drops, twice daily, were continued for one month.

Scheimpflug Imaging

The Scheimpflug camera (Pentacam, Oculus Optikgerate GmbH, Wetzlar, Germany) is a non-invasive diagnostic system designed for analyzing the anterior segment of

the eye. The device collects 25,000 elevation data points that are processed to generate a three-dimensional representation of the anterior segment and crystalline lens. The camera rotates around the eye from 0 to 180 degrees and captures 25 single slit images in fewer than two seconds. The Pentacam can also be used as an objective method for the evaluation of crystalline lens density. Using the individual images, the program quantifies lens density on a scale of 0-100 (0 = no cloudiness; 100 = completely opaque lens). In addition, to determining point and linear density, the system provides three-dimensional density evaluation for a specific area drawn on the Scheimpflug image. Means density, maximum density and standard deviation in a specific area can be calculated.

For all patients, lens densitometry was performed in a room with dim illumination. The patient was seated with their chin on a chinrest and forehead against the forehead strap and asked to fixate their eyes ahead on a target. To reduce operator dependent variables, the Pentacam automatic release mode was used. In this mode, the instrument automatically determines when correct focus and alignment with the corneal apex have been achieved, and then performs a scan. The pupil was dilated 30 min prior to each Pentacam examination (at baseline and after six months) using tropicamide drops instilled twice, five minutes apart. The density threshold was set to 20%. Three-dimensional lens density of the anterior capsule and anterior cortex in a fixed area of 1 × 2 inches was measured in all patients. Lens densitometry was performed on the same segment of the Pentacam image, a segment from 98° to 237°, for all patients. If image quality was poor in this segment, a best image quality segment was chosen instead. The optical axis of the eye, which was marked by the Pentacam device, was considered as a reference point for guaranteeing evaluation of the same area in the second Pentacam examination. The measurement square was set in such a way that the optical axis was located in its middle for each examination [Figure 1].

Statistical Analysis

An independent paired *t*-test was used for continuous normally distributed variable (lens density). *P* values less than 0.05 were considered as statistically significant. Statistical analysis was performed with SPSS for Windows Software (version 17.0, SPSS, Inc., Chicago, Illinois, USA).

RESULTS

Forty eyes of 25 patients, including 17 male and 8 female patients with progressive keratoconus (subjects) and 36 eyes of 18 patients including 10 male and 8 female subjects with non-progressive keratoconus (controls) were evaluated. Mean age of the subject and control

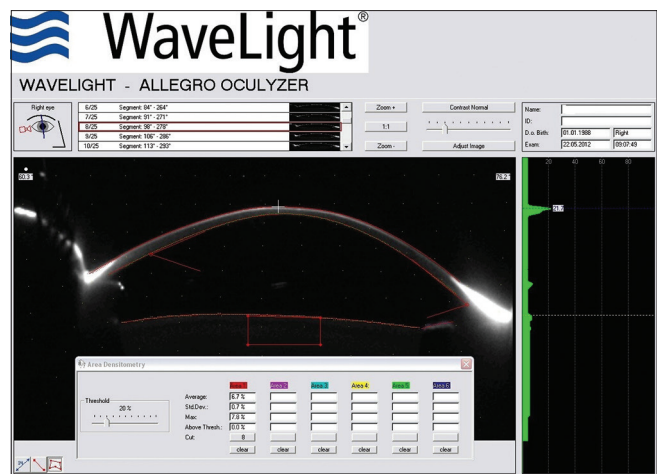


Figure 1. Galilei view of the anterior segment measuring corneal thickness.

groups was 25.8 ± 4 (range, 18-30) and 25 ± 4.1 (range, 20-30) years, respectively ($P = 0.392$).

In the subject group, mean lens density was $6.68\% \pm 0.58\%$ (range, 5.50% to 8.20%) at baseline and $6.77\% \pm 0.53\%$ (range, 5.90% to 8.20%) at the last visit ($P = 0.352$). In the control group, mean lens density was $6.53\% \pm 0.27\%$ (range, 6.30% to 7.10%) at baseline and $6.39\% \pm 0.31\%$ (range, 5.90% to 6.80%) at the last visit ($P = 0.213$). There was no statistically significant difference in terms of lens density assessed by Pentacam between the study groups at baseline or six month later ($P = 0.96$).

DISCUSSION

Collagen cross-linking is a therapeutic modality for progressive keratoconus and post-LASIK ectasia. As any other new treatment, safety concerns are of great importance. The published literature shows that with CXL, in combination with riboflavin and a minimal corneal thickness of 400 microns, insignificant amounts of UVA irradiance reach inner ocular tissues, including the lens and retina, and there is no evidence of UVA-induced damage in these tissues.^[17] *In vitro* studies have revealed that with corneal thickness less than 400 microns, endothelial damage due to UV exposure is a possible risk.^[18] Recently, some reports have raised concerns for corneal endothelial damage after standard CXL procedure.^[19,20]

During CXL, riboflavin in conjunction with UVA is excited to the triplet state, inducing reactive oxygen species which by diffusion through the cornea, may enter the anterior chamber and come in contact with the crystalline lens. Several studies have shown that reactive oxygen species accelerate cataract formation.^[14-16] The cataractogenic effect of excited riboflavin has been revealed *in vitro*.^[15] A minimal amount of UVA reaching the lens may also theoretically affect crystalline lens

transparency. Therefore, the crystalline lens may be prone to cataract formation or changes in density during this procedure.

In the current study we found that exposure of the crystalline lens to UVA and triplet state of riboflavin during CXL did not significantly impact lens density measured with a Scheimpflug camera. This is in line with the results of two other studies performed by Vinciguerra et al.^[21] and Grewal et al.^[22] Vinciguerra et al studied 12 eyes with a 36-month follow-up and evaluated a 1.2 mm diameter cylindrical-shaped central section of the lens.^[21] These authors did not find any deterioration of the crystalline lens transparency or permanent negative side-effects on the cornea and endothelium.^[21] Grewal et al also reported no change in crystalline lens density 12 months after CXL in 102 patients.^[22] In the current study we evaluated the density of the anterior capsule and anterior cortex of the lens, as these areas are more prone to riboflavin free radicals and UVA irradiation during CXL.

The Scheimpflug camera technology has been used for objective quantification of crystalline lens density in many research studies and its repeatability and sensitivity to lens change over time has been confirmed.^[23,24] The repeatability and validity of Pentacam measurements regarding lens densitometry has been confirmed by Kirkwood et al.^[25] The application of Pentacam densitometry for studies on cataracts and cataract prevention has been published in recent studies.^[26] Although the Scheimpflug camera is sensitive enough to determine lens density changes, a more precise method may be required to detect fine oxidative stress in the crystalline lens during CXL. In previous *in vitro* studies, a decrease in the active transport of ions across the crystalline lens indicates damage,^[15,16] however, there are limitations to this method where the human eye is concerned.

There are concerns pertaining to changes in corneal transparency following CXL and its effect on Pentacam accuracy. After CXL, there is a 12.2% increase in the diameter of corneal fibrils.^[27] To maintain corneal transparency, the collagen fibril diameter should not exceed one third of the wavelength of visible light (150 nm).^[28] The 12.2% increase in collagen fiber diameter in CXL does not approach this threshold and therefore does not seem to affect corneal transparency.^[27,28] As such, there should be no concern about alteration in the optical transparency of the cornea after CXL using Pentacam.

In summary, we observed no signs of cataractogenesis or any change in anterior lens capsule or anterior cortical density following CXL for progressive keratoconus with short term follow-up using the Pentacam. According to *in vitro* studies, although there may be some oxidative stress in the crystalline lens during CXL, it may not be significant enough to be measured by a Scheimpflug camera. Measuring free radical levels in the aqueous humour following CXL treatment and its comparison

with free radical levels in the normal eye may better elucidate this matter in later studies.

Acknowledgements

The authors thank Razi Eye Clinic, Tehran, Iran for their technical assistance.

Financial Support and Sponsorship

Nil.

Conflicts of Interest

There are no conflicts of interest.

REFERENCES

1. Wollensak G, Spoerl E, Seiler T. Riboflavin/ultraviolet-a-induced collagen crosslinking for the treatment of keratoconus. *Am J Ophthalmol* 2003;135:620-627.
2. Li G, Fan ZJ, Peng XJ. Corneal collagen crosslinking for corneal ectasia of post-LASIK: One-year results. *Int J Ophthalmol* 2012;5:190-195.
3. Lin DT, Holland S, Tan JC, Moloney G. Clinical results of topography-based customized ablations in highly aberrated eyes and keratoconus/ectasia with cross-linking. *J Refract Surg* 2012;28:S841-S848.
4. Al-Sabai N, Koppen C, Tassignon MJ. UVA/riboflavin crosslinking as treatment for corneal melting. *Bull Soc Belge Ophthalmol* 2010;315:13-17.
5. Spadea L. Corneal collagen cross-linking with riboflavin and UVA irradiation in pellucid marginal degeneration. *J Refract Surg* 2010;26:375-377.
6. Ehlers N, Hjortdal J, Nielsen K, Søndergaard A. Riboflavin-UVA treatment in the management of edema and nonhealing ulcers of the cornea. *J Refract Surg* 2009;25:S803-S806.
7. Ghanem RC, Santhiago MR, Berti TB, Thomaz S, Netto MV. Collagen crosslinking with riboflavin and ultraviolet-A in eyes with pseudophakic bullous keratopathy. *J Cataract Refract Surg* 2010;36:273-276.
8. Galperin G, Berra M, Tau J, Boscaro G, Zarate J, Berra A. Treatment of fungal keratitis from *Fusarium* infection by corneal cross-linking. *Cornea* 2012;31:176-180.
9. Morén H, Malmjö M, Mortensen J, Ohrström A. Riboflavin and ultraviolet a collagen crosslinking of the cornea for the treatment of keratitis. *Cornea* 2010;29:102-104.
10. McCall AS, Kraft S, Edelhauser HF, Kidder GW, Lundquist RR, Bradshaw HE, et al. Mechanisms of corneal tissue cross-linking in response to treatment with topical riboflavin and long-wavelength ultraviolet radiation (UVA). *Invest Ophthalmol Vis Sci* 2010;51:129-138.
11. Valko M, Leibfritz D, Moncol J, Cronin MT, Mazur M, Telser J. Free radicals and antioxidants in normal physiological functions and human disease. *Int J Biochem Cell Biol* 2007;39:44-84.
12. Saccà SC, Roszkowska AM, Izzotti A. Environmental light and endogenous antioxidants as the main determinants of non-cancer ocular diseases. *Mutat Res* 2013;752:153-171.
13. Azzam N, Levanon D, Dovrat A. Effects of UV-A irradiation on lens morphology and optics. *Exp Gerontol* 2004;39:139-146.
14. Zigman S. Lens UVA photobiology. *J Ocul Pharmacol Ther* 2000;16:161-165.
15. Hegde KR, Kovtun S, Varma SD. Induction of ultraviolet cataracts *in vitro*: Prevention by pyruvate. *J Ocul Pharmacol Ther* 2007;23:492-502.

16. Varma SD, Kovtun S, Hegde KR. Role of ultraviolet irradiation and oxidative stress in cataract formation-medical prevention by nutritional antioxidants and metabolic agonists. *Eye Contact Lens* 2011;37:233-245.
17. Spoerl E, Mrochen M, Sliney D, Trokel S, Seiler T. Safety of UVA-riboflavin cross-linking of the cornea. *Cornea* 2007;26:385-389.
18. Wollensak G, Spörl E, Reber F, Pillunat L, Funk R. Corneal endothelial cytotoxicity of riboflavin/UVA treatment *in vitro*. *Ophthalmic Res* 2003;35:324-328.
19. Sharma A, Nottage JM, Mirchia K, Sharma R, Mohan K, Nirankari VS. Persistent corneal edema after collagen cross-linking for keratoconus. *Am J Ophthalmol* 2012;154:922-926.e1.
20. Bagga B, Pahuja S, Murthy S, Sangwan VS. Endothelial failure after collagen cross-linking with riboflavin and UV-A: Case report with literature review. *Cornea* 2012;31:1197-1200.
21. Vinciguerra P, Camesasca FI, Romano MR. Corneal crosslinking and lens opacity. *Ophthalmology* 2011;118:2519.e1-2.
22. Grewal DS, Brar GS, Jain R, Sood V, Singla M, Grewal SP. Corneal collagen crosslinking using riboflavin and ultraviolet-A light for keratoconus: One-year analysis using Scheimpflug imaging. *J Cataract Refract Surg* 2009;35:425-432.
23. Datiles MB 3rd, Magno BV, Freidlin V. Study of nuclear cataract progression using the National Eye Institute Scheimpflug system. *Br J Ophthalmol* 1995;79:527-534.
24. Magno BV, Freidlin V, Datiles MB 3rd. Reproducibility of the NEI Scheimpflug Cataract Imaging System. *Invest Ophthalmol Vis Sci* 1994;35:3078-3084.
25. Kirkwood BJ, Hendicott PL, Read SA, Pesudovs K. Repeatability and validity of lens densitometry measured with Scheimpflug imaging. *J Cataract Refract Surg* 2009;35:1210-1215.
26. Polunin GS, Makarova IA, Bubnova IA. Efficacy of catalin eyed drops in age-related cataract agents. *Vestn Oftalmol* 2010;126:36-39.
27. Wollensak G, Wilsch M, Spoerl E, Seiler T. Collagen fiber diameter in the rabbit cornea after collagen crosslinking by riboflavin/UVA. *Cornea* 2004;23:503-507.
28. Goldman JN, Benedek GB, Dohlman CH, Kravitt B. Structural alterations affecting transparency in swollen human corneas. *Invest Ophthalmol* 1968;7:501-519.