

# The Effectiveness of Narrow Band Uvb (Nb-Uvb) In the Treatment of Pityriasis Lichenoides Chronica (PLC) In Vietnam

Doanh Le Huu<sup>1,2</sup>, Thao Ngo Minh<sup>1</sup>, Thuong Nguyen Van<sup>1,2</sup>, Phuong Pham Thi Minh<sup>1</sup>, Nghi Dinh Huu<sup>1,2</sup>, Van Tran Cam<sup>1</sup>, My Le Huyen<sup>1</sup>, Minh Vu Nguyet<sup>1,2</sup>, Mai Le Thi<sup>1</sup>, Hien Do Thi Thu<sup>1</sup>, Khang Tran Hau<sup>1,2</sup>, Marco Gandolfi<sup>3\*</sup>, Francesca Satolli<sup>3</sup>, Claudio Feliciani<sup>3</sup>, Michael Tirant<sup>4,5</sup>, Aleksandra Vojvodic<sup>6</sup>, Torello Lotti<sup>4</sup>

<sup>1</sup>National Hospital of Dermatology and Venereology, Hanoi, Vietnam; <sup>2</sup>Hanoi Medical University, Vietnam; <sup>3</sup>Unit of Dermatology, University of Parma, Parma, Italy; <sup>4</sup>University of Rome G. Marconi, Rome, Italy; <sup>5</sup>Psoriasis Eczema Clinic, Melbourne, Australia; <sup>6</sup>Department of Dermatology and Venereology Military Medical Academy, Belgrade, Serbia

## Abstract

**AIM:** This prospective clinical study presents the experiences with NB-UVB monotherapy in the treatment of PLC on Vietnamese patients.

**METHODS:** We enrolled at National Hospital of Dermatology and Venereology (NHDV), Vietnam, 29 PLC patients with generalised disease involving at least 60% of the total body surface (based on Nine's Rule) and/or failed to respond to other modalities of treatment. Patients were treated with NB-UVB followed the guideline of the psoriatic treatment of AAD-2010, three times weekly.

**RESULTS:** A complete response (CR) was seen in 24 out of 29 PLC patients (82.8%) with a mean cumulative dose of 9760.5 mJ/cm<sup>2</sup> after a mean treatment period of 4.6 weeks (13.8 ± 7.4 exposures). Mild side effects were observed: 69% erythema minimum, 55.2% irritation related to dry skin. No severe side effects were seen during the study. No relapses occurred in 24 CR patients within a mean period of 3 months after the last treatment.

**CONCLUSION:** NB-UVB therapy is an effective and safe option for the treatment and management of PLC.

**Citation:** Le Huu D, Ngo Minh T, Van TN, Thi Minh PP, Dinh Huu N, Tran Cam V, Le Huyen M, Vu Nguyet M, Le Thi M, Thi Thu HD, Tran Hau K, Gandolfi M, Satolli F, Feliciani C, Tirant M, Vojvodic A, Lotti T. The Effectiveness of Narrow Band Uvb (Nb-Uvb) In the Treatment of Pityriasis Lichenoides Chronica (Plc) In Vietnam. Open Access Maced J Med Sci. 2019 Jan 30; 7(2):221-223. <https://doi.org/10.3889/oamjms.2019.055>

**Keywords:** Phototherapy; NB-UVB; Pityriasis lichenoides chronica; Effectiveness; Safety

**\*Correspondence:** Marco Gandolfi, Unit of Dermatology, University of Parma, Parma, Italy. E-mail: marco.gandolfi5@gmail.com

**Received:** 02-Jan-2019; **Revised:** 16-Jan-2019; **Accepted:** 17-Jan-2019; **Online first:** 25-Jan-2019

**Copyright:** © 2019 Doanh Le Huu, Thao Ngo Minh, Thuong Nguyen Van, Phuong Pham Thi Minh, Nghi Dinh Huu, Van Tran Cam, My Le Huyen, Minh Vu Nguyet, Mai Le Thi, Hien Do Thi Thu, Khang Tran Hau, Marco Gandolfi, Francesca Satolli, Claudio Feliciani, Michael Tirant, Aleksandra Vojvodic, Torello Lotti. This is an open-access article distributed under the terms of the Creative Commons Attribution-NonCommercial 4.0 International License (CC BY-NC 4.0)

**Funding:** This research did not receive any financial support

**Competing Interests:** The authors have declared that no competing interests exist

## Introduction

Pityriasis lichenoides chronica (PLC) is a chronic papulosquamous disorder of unknown aetiology with remissions and exacerbations. Although being a self-limited condition, therapeutic approach is required based on cosmetic and symptomatic concerns. Many treatment options including topical or systemic corticosteroids, oral tetracycline, topical calcineurin inhibitors such as tacrolimus, and methotrexate have been used with different success rates. NB-UVB phototherapy has recently demonstrated high levels of efficacy and tolerability in the treatment of patients with PL. Despite the variety

of reports in the literature, no studies have been conducted to primarily evaluate the efficacy of such modality in PLC case series treatment.

This prospective clinical study presents the experiences with NB-UVB monotherapy in the treatment of PLC on Vietnamese patients.

## Methods

Twenty-nine Vietnamese patients, aged 3 to 75 years old (11 males, 18 females, the initial mean

age of disease  $25 \pm 16.8$  years old) were treated with NB-UVB mono-therapy. Treatment with NB-UVB (311 nm) was given three times weekly in a Daavlin cabinet (Daavlin, CA, USA) equipped with Philips TL-01/100 W fluorescent lamps (Philips Company, Eindhoven, the Netherlands). The initial and increasing treatment dose of NB-UVB in every treatment session depended on patients' skin type classified by Fitzpatrick (AAD-2010 guidelines). In the case of mild side-effects including mild to moderate erythema, burning sensation, the dose of NB-UVB was decreased by 20%. In case of severe side-effects such as severe erythema, burning or photosensitivity, the treatment was stopped, and the patient was applied topical corticosteroids with an oral non-steroidal anti-inflammatory drug (NSAID). If one to three sessions were missed, the dose was unchanged, and if more than four sessions were missed, the dose was decreased by 25% (within 7 sessions), 50% (from 8 to 11 sessions) or began again (over 12 sessions).

Complete response (CR) was defined as more than 90% resolution in skin lesions (papulosquamous and plaque lesions). Partial response (PR) was defined as the resolution of 50-90% in skin lesions. Poor response (NR) was taken as less than 50% reduction in lesions. Patients were assessed every 6 sessions until they cleared skin lesions or after completed 36 sessions. If the patient's skin lesions cleared before completing 36 treatment sessions, they were observed for at least 3 months to determine any recurrence. Detection of more than 10 new lesions was defined as recurrence.

Both thickness and scaling scores were assessed at the initial and at the end of treatment (PASI score). Patients also fulfilled a self-evaluation satisfaction questionnaire.

## Results

After one month treatment (4.6 weeks), 82.8% complete response was achieved with the mean number of treatment sessions was 13.8 (range: 4-30 sessions). The mean number of sessions required to achieve the first clinical response was 6.4 (range: 3-14 sessions).

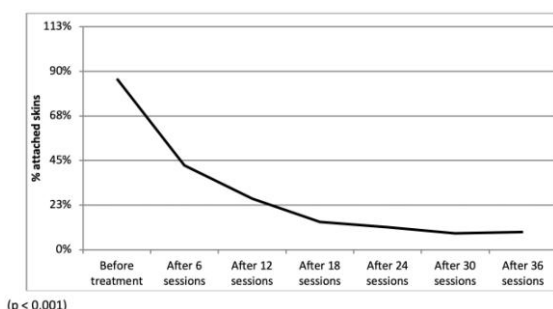


Figure 1: Improvement of the total body surface in skin lesions

Most patients had reduced the total body surface area (BSA) after 6 sessions ( $p < 0.001$ ). The improvement of skin had seen and maintained after 12 sessions ( $p < 0.001$ ) as shown in Figure 1.

Thickness, scale and pruritus of skin lesions had good improvement after the last session by NB-UVB mono-therapy ( $p < 0.001$ ) as shown in Figure 2.

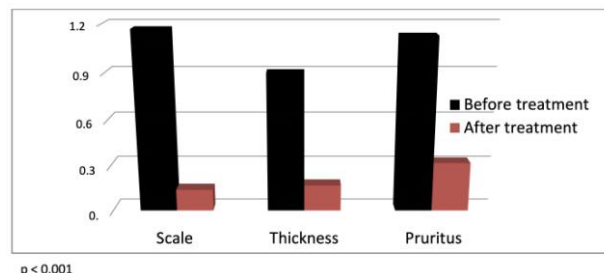


Figure 2: Improvement of thickness and scale of skin lesions

The mean cumulative dose was  $9760.5 \text{ mJ/cm}^2$ . All patients have remained relapse-free for at least 3 months.

A group of 27/29 patients treated with phototherapy reported minimal erythema (69%) and itchy (55.2%). These side effects have resolved quickly after topical emollients and irradiation dose reduction. None of the patients discontinued treatment as a result of side effects.

All patients were satisfied with the treatment; more than 80% of the patients would recommend the procedure.

## Discussion

In National Hospital of Dermatology and Venereology (NHDV), 29 patients with PLC (11 males and 18 females) with the initial mean age of disease was  $25 \pm 16.8$  years and mean disease duration was  $39.9 \pm 57.9$  months. This is convenient with criteria chronic and most commonly occurs in children and young adults of PLC. Responses to various treatment modalities, such as topical corticosteroids and oral antibiotics were extremely poor despite diffuse skin lesions. Topical corticosteroids are unable to affect the course of disease whereas systemic antibiotics, including erythromycin and tetracycline, have been used for their anti-inflammatory rather than antibiotic effects [1], [2].

The exact mechanism of NB-UVB for a phototherapeutic treatment modality for PL, including PLC is unknown. In the previous studies, NB-UVB has been shown to be the safe and effective treatment option for several inflammatory and neoplastic skin diseases characterised by epithelial and dermal infiltrates rich in T lymphocytes. In chronic plaque

psoriasis, NB-UVB mono-therapy could reduce the number of activated T cells by inducing T cells apoptosis [3]. Recent studies have revealed that UVB suppresses the all activating and antigen-presenting capacity of epidermal Langerhans cells and therefore UVB modulates the circulating cytokines accounts, such as IL-1, IL-6, IL-8, IL-12 and TNF- $\alpha$  production by human keratinocytes due to immunosuppression [4]. The expression of ICAM-1 has been suppressed in cultured human keratinocytes, and decreases the release of histamine from mast cells by systemic UVB-induced, in turn, decrease the itch response of skin lesions [5]. In the present study, 29 PLC patients were treated with NB-UVB monotherapy. 82.8% of patients achieved a CR within  $13.8 \pm 7.4$  sessions (4, 6 weeks) of their first therapy session. Thickness, scale and pruritus of skin lesions were reported reducing after finished treatment. No patients relapsed during the follow-up (for at least 3 months after the last treatment). These results, compared with the published data, demonstrated that NB-UVB therapy should be highly recommended for PLC treatment.

Similarly, several studies demonstrated the efficacy of NB-UVB phototherapy in PLC treatment. Farnaghi et al. described their experience with NB-UVB in eight PLC patients. CR was achieved by 87.5% (7/8) of the patients within a mean number of  $37 \pm 11$  treatments [6]. Fernandez et al. has reported on 8 adults diffuse PLC patients whose disease showed no response to topical therapy. A CR rate of 88% in a mean of 23 sessions (cumulative dose  $16,99 \text{ J/cm}^2$ ) was obtained [7]. Ersoy et al. reported on 25 PLC patients (14 male, 11 female). CR was achieved in 48% of the patients after 25 sessions (8 weeks) of the median number treatment [8]. Although the relapse-free rates after NB-UVB monotherapy varied from 42 to 73% in the literature, the discrepancy in relapse rates between previous studies and the present study may reflex differences both in the length of follow-up periods and in the choice of the initial and increasing dose in every session treatment. In the current study, NB-UVB phototherapy proved to be safe modality in the treatment of PLC patients. Short-term adverse effects showed minimal erythema and itch in most patients which could be quickly resolved while long-term adverse effects were unavailable.

In conclusion, NB-UVB therapy is an effective and safe option for the treatment and management of

PLC. It also has several advantages over treatment with BB-UVB and PUVA. So NB-UVB should be considered as the first line in generalised cases interested in treatment.

## References

1. Mark JL, Warren RH, John BJ, et al. Treatment of skin disease (3rd ed., pp. 565-567). UK: Elsevier Health Sciences, 2002.
2. Klaus W, Lowell AG, Stephen IK, et al. Fitz Patrick's Dermatology in General Medicine (7th ed., pp. 240-243). New York, NY: McGraw-Hill, 2008.
3. Valkova S. UVB phototherapeutic modalities. Comparison of two treatments for chronic plaque psoriasis. Acta Dermatovenerologica Alpina Panonica Et Adriatica. 2007; 16(1):26-30.
4. McLoone P, Man I, Yule S, Fluitman A, Van Loveren H, Norval M, Gibbs NK. Whole-body UVB (TL-01) or UVA-1 irradiation does not alter the levels of immunomodulatory cytokines in the serum of human volunteers. Photodermatology, photoimmunology & photomedicine. 2004; 20(2):76-80. <https://doi.org/10.1111/j.1600-0781.2004.00089.x> PMID:15030591
5. Norris DA, Lyons MB, Middleton MH, Yohn JJ, Kashihara-Sawami M. Ultraviolet radiation can either suppress or induce expression of intercellular adhesion molecule 1 (ICAM-1) on the surface of cultured human keratinocytes. Journal of investigative dermatology. 1990; 95(2):132-138. <https://doi.org/10.1111/1523-1747.ep12477877> PMID:1974276
6. Farnaghi F, Seirafi H, Ehsani AH, Agdari ME, Noormohammadpour P. Comparison of the therapeutic effects of narrow band UVB vs. PUVA in patients with pityriasis lichenoides. Journal of the European Academy of Dermatology and Venereology. 2011; 25(8):913-6. <https://doi.org/10.1111/j.1468-3083.2010.03879.x> PMID:21054568
7. Fernández-Guarino M, Aboin-Gonzalez S, Ciudad Blanco C, Velázquez Tarjuelo D, Lázaro Ochayta P. Treatment of adult diffuse pityriasis lichenoides chronica with narrowband ultraviolet B: experience and literature review. Clinical and experimental dermatology. 2017; 42(3):303-5. <https://doi.org/10.1111/ced.13035> PMID:28111789
8. Ersoy-Evans S, Greco MF, Mancini AJ, Subaşı N, Paller AS. Pityriasis lichenoides in childhood: a retrospective review of 124 patients. Journal of the American Academy of Dermatology. 2007; 56(2):205-10. <https://doi.org/10.1016/j.jaad.2006.08.023> PMID:17097385
9. Brazzini B, Ghersetich I, Urso C, Cianferoni L, Lotti T. Pityriasis lichenoides et varioliformis acuta during pregnancy. Journal of the European Academy of Dermatology and Venereology. 2001; 15(5):458-60. <https://doi.org/10.1046/j.1468-3083.2001.00341.x> PMID:11763391