

















# Clinicoradiologic Characteristics of Intradural Extramedullary Conventional Spinal Ependymoma

경막내 척수외 뇌실막세포종의 임상 영상의학적 특징

Seung Hyun Lee, MD<sup>1</sup> , Yoon Jin Cha, MD<sup>2</sup> , Yong Eun Cho, MD<sup>3</sup> ,  
Mina Park, MD<sup>1</sup> , Bio Joo, MD<sup>1</sup> ,  
Sang Hyun Suh, MD<sup>1</sup> , Sung Jun Ahn, MD<sup>1\*</sup> 

Departments of <sup>1</sup>Radiology, <sup>2</sup>Pathology, and <sup>3</sup>Neurosurgery, Gangnam Severance Hospital, Yonsei University College of Medicine, Seoul, Korea

## ORCID iDs

Seung Hyun Lee  <https://orcid.org/0000-0002-6549-4908>  
Yoon Jin Cha  <https://orcid.org/0000-0002-5967-4064>  
Yong Eun Cho  <https://orcid.org/0000-0001-9815-2720>  
Mina Park  <https://orcid.org/0000-0002-2005-7560>  
Bio Joo  <https://orcid.org/0000-0001-7460-1421>  
Sang Hyun Suh  <https://orcid.org/0000-0002-7098-4901>  
Sung Jun Ahn  <https://orcid.org/0000-0003-0075-2432>

**Purpose** Distinguishing intradural extramedullary (IDEM) spinal ependymoma from myxopapillary ependymoma is challenging due to the location of IDEM spinal ependymoma. This study aimed to investigate the utility of clinical and MR imaging features for differentiating between IDEM spinal and myxopapillary ependymomas.

**Materials and Methods** We compared tumor size, longitudinal/axial location, enhancement degree/pattern, tumor margin, signal intensity (SI) of the tumor on T2-weighted images and T1-weighted image (T1WI), increased cerebrospinal fluid (CSF) SI caudal to the tumor on T1WI, and CSF dissemination of pathologically confirmed 12 IDEM spinal and 10 myxopapillary ependymomas. Furthermore, classification and regression tree (CART) was performed to identify the clinical and MR features for differentiating between IDEM spinal and myxopapillary ependymomas.

**Results** Patients with IDEM spinal ependymomas were older than those with myxopapillary ependymomas (48 years vs. 29.5 years,  $p < 0.05$ ). A high SI of the tumor on T1WI was more frequently observed in IDEM spinal ependymomas than in myxopapillary ependymomas ( $p = 0.02$ ). Conversely, myxopapillary ependymomas show CSF dissemination. Increased CSF SI caudal to the tumor on T1WI was observed more frequently in myxopapillary ependymomas than in IDEM spinal ependymomas ( $p < 0.05$ ). Dissemination to the CSF space and increased CSF SI caudal to the tumor on T1WI were the most important variables in CART analysis.

**Conclusion** Clinical and radiological variables may help differentiate between IDEM spinal and myxo-

Received August 24, 2022  
Revised November 16, 2022  
Accepted January 10, 2023

\*Corresponding author  
Sung Jun Ahn, MD  
Department of Radiology,  
Gangnam Severance Hospital,  
Yonsei University  
College of Medicine,  
211 Eonju-ro, Gangnam-gu,  
Seoul 06273, Korea.

Tel 82-2-2019-3510  
Fax 82-2-3462-5472  
E-mail aahng77@yuhs.ac

This is an Open Access article distributed under the terms of the Creative Commons Attribution Non-Commercial License (<https://creativecommons.org/licenses/by-nc/4.0>) which permits unrestricted non-commercial use, distribution, and reproduction in any medium, provided the original work is properly cited.

papillary ependymomas.

**Index terms** Ependymoma; Myxopapillary Ependymoma; Spinal Cord Neoplasms; Magnetic Resonance Imaging

## INTRODUCTION

Spinal ependymomas are typically intramedullary (IM) tumors that account for 60% of adult spinal cord neoplasms and 30% of pediatric spinal cord neoplasms (1, 2). Spinal ependymomas occur most frequently in patients in their 30s and affects men and women equally (3). Ependymomas arise from ependymal cells lining the central canal or cell rests along the filum.

The 2021 WHO classification of ependymoma in the spinal compartment has significantly changed compared to past 2016 WHO classification. These changes can be summarized as follows; First, spinal ependymoma with MYCN amplification has been newly defined in the current classification as it shows a clinically aggressive behavior (4). Second, myxopapillary ependymoma is now considered CNS WHO grade 2 rather than 1, since its likelihood of recurrence is similar to conventional spinal ependymoma. Third, the term “anaplastic ependymoma” is no longer used, but WHO grade 2 or 3 can be assigned to spinal ependymoma according to its histopathological features (5). Fourth, papillary, clear cell, and tanycytic morphological variants are no longer listed. In summary, according to the 2021 WHO classification, ependymomas in the spinal compartment are classified as spinal ependymomas, spinal ependymomas with MYCN amplification, myxopapillary ependymomas, or subependymomas (6).

IDEM spinal ependymomas are rare and have only been previously reported as case series (4). Additionally, previous studies have reported malignant transformation and atypical imaging features (5, 6). However, we incidentally found that IDEM spinal ependymomas are not as rare as reported and favor lower spines. Myxopapillary ependymoma also commonly involve lower spine, manifesting as IDEM tumors. They are associated with a high recurrence rate, postoperative neurological deficit. Considering the IDEM location, the distinction from myxopapillary ependymoma can be a challenge. Therefore, the aim of our study was to analyze the clinical and imaging features of IDEM spinal ependymoma.

## MATERIALS AND METHODS

### PATIENT POPULATION

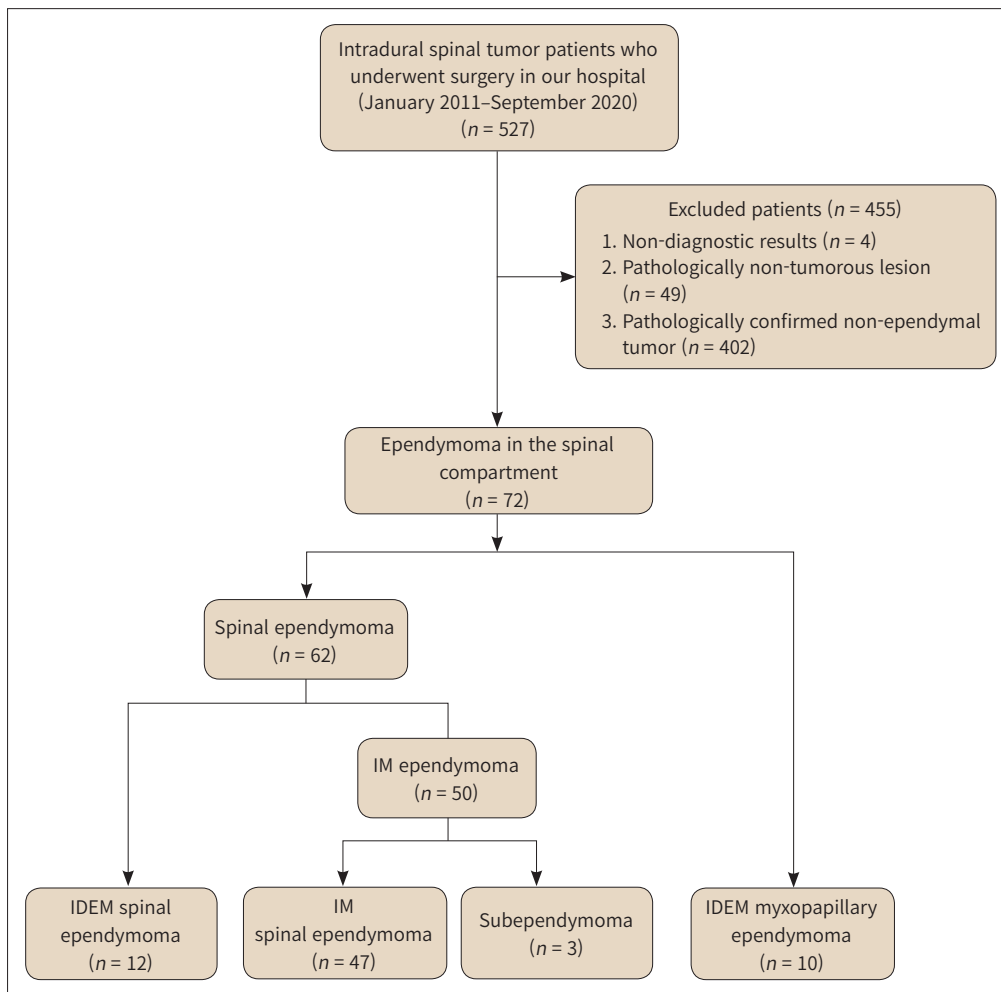
Our Institutional Review Board approved this retrospective study and waived the requirement for informed patient consent (IRB No. 2022-0209-001). We retrospectively searched the electronic medical records to identify patients who had undergone surgery for intradural spinal tumors between January 2011 and September 2020. A total of 527 patients with suspected intradural spinal tumors underwent surgery. Patients were excluded for the following reasons: pathologically confirmed non-ependymal tumor ( $n = 402$ ), non-tumorous lesion ( $n =$

55), and non-diagnostic results ( $n = 4$ ). Finally, 72 ependymomas in the spinal compartment were selected. They were classified with spinal ependymoma, not otherwise specified ( $n = 59$ ), subependymoma ( $n = 3$ ), and myxopapillary ependymoma ( $n = 10$ ). NOS suffix was added because molecular analysis such as MYCN amplification or NF2 mutation was not available. Based on the tumor location, spinal ependymoma NOS was further categorized into IDEM ( $n = 12$ ) and IM type ( $n = 47$ ). Fig. 1 includes a detailed flowchart of the patient selection process. Based on the tumor location, spinal ependymoma NOS was further categorized into IDEM ( $n = 12$ ) and IM type ( $n = 47$ ). Fig. 1 includes a detailed flowchart of the patient selection process.

### MRI ACQUISITION

MRI examinations were performed using a 1.5T scanner (Magnetom Avanto; Siemens Healthineers, Erlangen, Germany) and 3T scanner (Magnetom Vida; Siemens Healthineers). MRI sequences for the 1.5T scanner included sagittal T1-weighted image (T1WI) (repetition time [TR]/echo time [TE] = 450/9.8 ms; matrix = 314 × 448; field of view [FOV] = 35 cm; slice thickness = 3 mm), sagittal T2-weighted images (T2WI) (TR/TE = 3760/100 ms; matrix = 338 ×

Fig. 1. Flowchart of study population selection.



IDEM = intradural extramedullary, IM = intramedullary

512; FOV = 35 cm; slice thickness = 3 mm), axial T1WI (TR/TE = 520/9.3 ms; matrix = 202 × 384; FOV = 25 cm; slice thickness = 4 mm), and axial T2WI (TR/TE = 3430/120 ms; matrix = 202 × 448; FOV = 25 cm; slice thickness = 3 mm). Contrast-enhanced T1WI in the axial and sagittal planes were obtained after intravenous administration of 0.1 mmol/kg gadopentetate dimeglumine (Magnevist; Schering, Berlin, Germany). MRI sequences for the 3T scanner included sagittal T1WI (TR/TE = 460/9.2 ms; matrix = 314 × 448; FOV = 32 cm; slice thickness = 3 mm), sagittal T2-weighted images (T2WI) (TR/TE = 4160/93 ms; matrix = 314 × 448; FOV = 32 cm; slice thickness = 3 mm), axial T1WI (TR/TE = 762/10 ms; matrix = 265 × 384; FOV = 22 cm; slice thickness = 3 mm), and axial T2WI (TR/TE = 4340/94 ms; matrix = 265 × 384; FOV = 23 cm; slice thickness = 3 mm). Contrast-enhanced T1WI in the axial and sagittal planes were obtained.

## MRI ANALYSIS

Two radiologists with 3 years and 14 years of experience in reading spinal MRIs respectively were blinded to the patients' clinical and histopathologic findings, and they independently evaluated preoperative MR images with regards to the following characteristics: tumor size, longitudinal location, axial location, enhancement pattern, degree of enhancement, signal intensity (SI) of tumor on T1WI/T2WI, tumor margin, presence of dissemination to the subarachnoid space, vertebral scalloping, engorged vein and increased CSF SI caudal to tumor on T1WI. All disagreements between raters were resolved by consensus.

Tumor size was measured according to the number of segments involved. The longitudinal location was classified as cervical, thoracic, or lumbar. The axial location was categorized as central or peripheral. The enhancement pattern was classified as none, homogenous, or heterogeneous. The degree of enhancement was classified as none, weak, or strong. The SI of T1WI/T2WI was described as low, iso, or high, compared to the SI of the normal spinal cord. The tumor margin was classified as well-defined or irregular. We considered dissemination to the subarachnoid space as present when multiple enhancing nodules were observed along the subarachnoid space. Increased CSF SI caudal to tumor on T1WI was also recorded.

## STATISTICAL ANALYSIS

Age, sex, symptoms (pain, motor function, sensory change, and urinary symptoms), tumor size, longitudinal location, axial location, enhancement pattern, degree of enhancement, signal intensity of T1WI/T2WI, tumor margin, the presence of dissemination to the subarachnoid space, and high SI in tumor on T1WI were compared between IDEM spinal ependymomas and myxopapillary ependymomas. Mann-Whitney U test was applied for continuous variables, and chi-squared or Fisher's exact test was used for categorical variables. To gain a comprehensive understanding of the variables that could distinguish IDEM ependymoma from myxopapillary ependymoma, classification and regression tree (CART) analysis was used to determine variable importance scores (7). A  $p < 0.05$  was considered significant. The inter-rater reliability was assessed using the intra-class correlation coefficient with a two-way random model of absolute agreement. All data analyses were performed using R (version 3.5.3; <http://www.r-project.org>).

## RESULTS

The most common type of ependymoma in the spinal compartment were IM spinal ependymoma (50/72, 69.4%), followed by IDEM ependymoma (16.7%, 12/72), and myxopapillary

**Table 1.** Demographic and Clinical Findings of Patients with IDEM Spinal and Myxopapillary Ependymomas

Variables	Overall (n = 22)	IDEM Spinal Ependymoma (n = 12)	Myxopapillary Ependymoma (n = 10)	p-Value
Age, years	37 (15–75)	48 (31–75)	29.5 (15–57)	< 0.01*
Sex				0.39
Male	10 (45.45)	4 (33.33)	6 (60.00)	
Female	12 (54.55)	8 (66.67)	4 (40.00)	
Pain				0.45
No	1 (4.55)	0 (0.00)	1 (10.00)	
Yes	21 (95.45)	12 (100.00)	9 (90.00)	
Motor symptoms				0.38
No	15 (68.18)	7 (58.33)	8 (80.00)	
Yes	7 (31.82)	5 (41.67)	2 (20.00)	
Sensory symptoms				> 0.99
No	16 (72.73)	9 (75.00)	7 (70.00)	
Yes	6 (27.27)	3 (25.00)	3 (30.00)	
Urinary symptoms				0.67
No	13 (59.09)	8 (66.67)	5 (50.00)	
Yes	9 (40.91)	4 (33.33)	5 (50.00)	

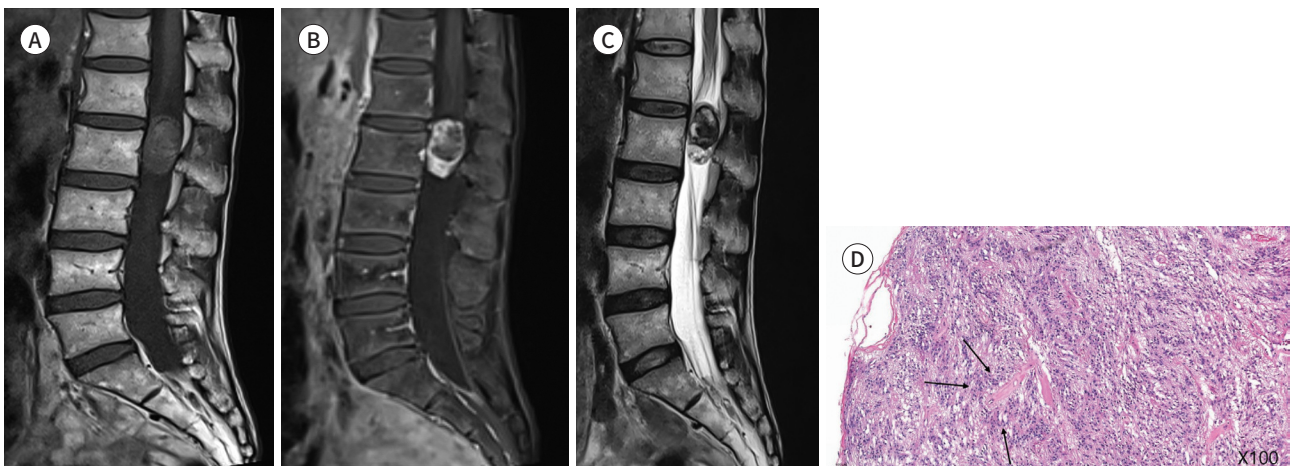
Data are presented as median (range) or n (%).

\* $p < 0.05$ .

IDEM = intradural extramedullary

**Fig. 2.** A 52-year-old female with pathologically confirmed IDEM spinal ependymoma.  
**A, B.** Well-circumscribed IDEM spinal ependymoma shows high signal intensity on T1WI and strong enhancement in conus medullaris on Gd-enhanced T1WI.  
**C.** Heterogeneously low signal intensity of tumor in conus medullaris on T2WI.  
**D.** Hematoxylin and eosin staining indicates typical perivascular pseudo rosettes, a sign of ependymoma (arrows).

IDEM = intradural extramedullary, WI = weighted image



ependymoma (13.9%, 10/72). Patients with IDEM ependymoma were significantly older than those with myxopapillary ependymoma (48 [31–75] years vs. 29.5 [15–57] years,  $p < 0.05$ ). There were no significant differences in sex, or initial presenting symptoms in patients with IDEM

**Fig. 3.** A 16-year-old girl with pathologically confirmed myxopapillary ependymoma.

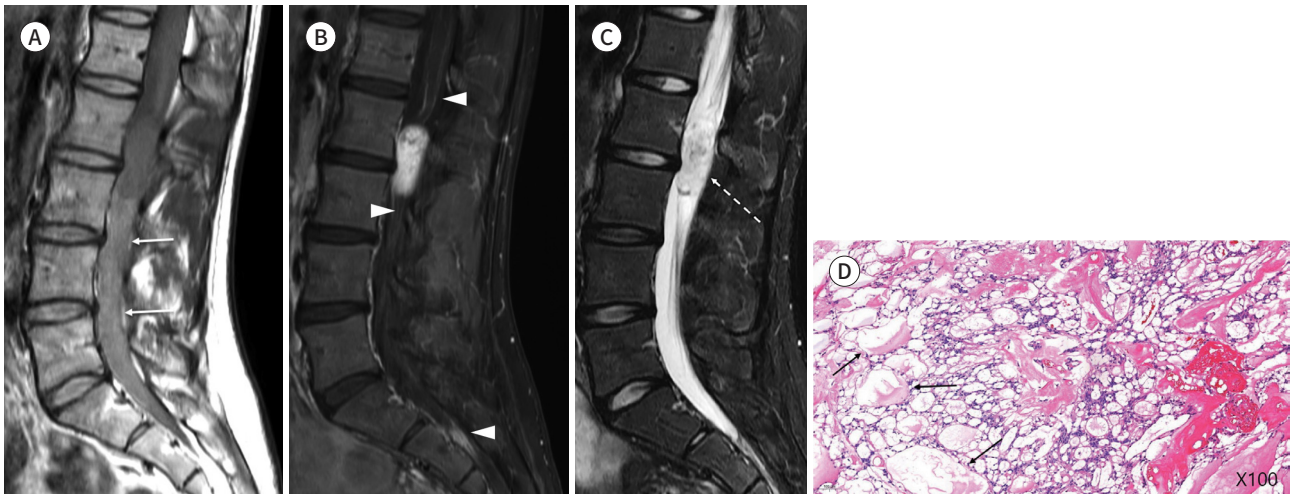
**A.** Well-circumscribed T1 iso SI tumor in conus medullaris, increased CSF intensities are seen below the tumor (arrows) on T1WI.

**B.** Dissemination to the subarachnoid space is noted on Gd-enhanced T1WI, suggesting tumor seeding (arrowheads).

**C.** Heterogeneously high SI of tumor in conus medullaris on T2WI image (dotted arrow).

**D.** Hematoxylin and eosin staining indicates characteristic myxoid materials surrounding blood vessels of myxopapillary ependymoma (arrows).

CSF = cerebrospinal fluid, SI = signal intensity, WI = weighted image



**Fig. 4.** A 30-year-old male with pathologically confirmed myxopapillary ependymoma.

**A.** Increased CSF intensities are similar to the signal intensity of the tumor (arrows) on T1WI.

**B.** Dissemination to the subarachnoid space (arrowheads) and vertebral scalloping of T12, L1, and L2 vertebral bodies (dotted arrows) on Gd-enhanced T1WI.

**C.** Engorged veins near myxopapillary ependymoma are noted on T2WI (arrows).

CSF = cerebrospinal fluid, WI = weighted image

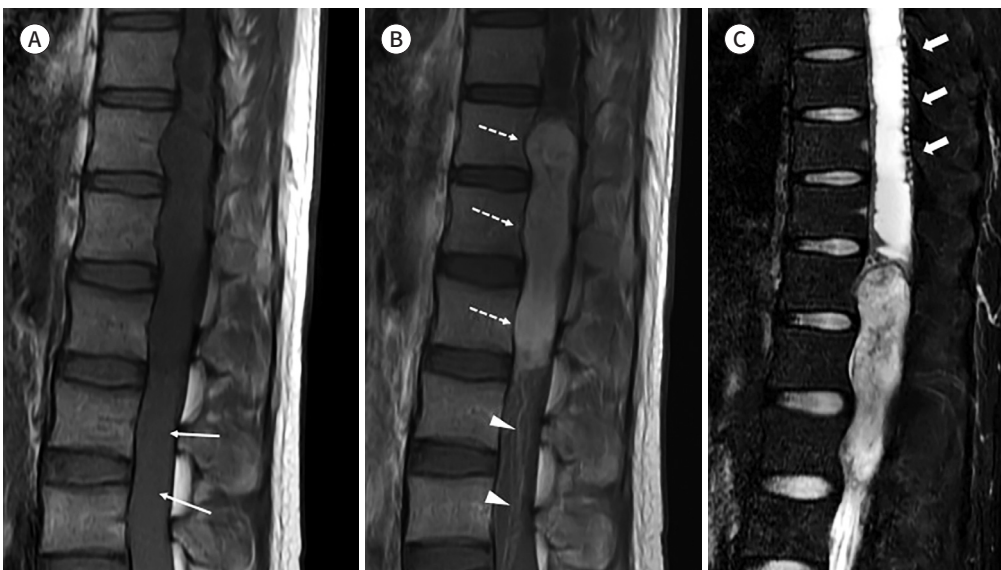


Table 2. MRI Findings of Patients with IDEM Spinal and Myxopapillary Ependymomas

Variables	Overall (n = 22)	IDEM Spinal Ependymoma (n = 12)	Myxopapillary Ependymoma (n = 10)	p-Value
MRI findings				
T1				0.02*
Low	2 (9.09)	0 (0.00)	2 (20.00)	
Iso	15 (68.18)	7 (58.33)	8 (80.00)	
High	5 (22.73)	5 (41.67)	0 (0.00)	
T2				0.54
Low	5 (22.73)	2 (16.67)	3 (30.00)	
Iso	5 (22.73)	4 (33.33)	1 (10.00)	
High	12 (54.55)	6 (50.00)	6 (60.00)	
Degree of enhancement				0.97
None/rare	2 (9.09)	1 (8.33)	1 (10.00)	
Weak	4 (18.18)	2 (16.67)	2 (20.00)	
Strong	16 (72.73)	9 (75.00)	7 (70.00)	
Enhancement pattern				0.83
None	2 (9.09)	1 (8.33)	1 (10.00)	
Homogenous	8 (36.36)	5 (45.45)	3 (33.33)	
Heterogeneous	12 (54.55)	6 (54.55)	6 (66.67)	
Tumor size, number of vertebral bodies	1 (1–6)	1 (1–6)	2 (1–3)	0.06
Longitudinal location				0.45
Cervical	0 (0.00)	0 (0.00)	0 (0.00)	
Thoracic	1 (4.55)	0 (0.00)	1 (10.00)	
Lumbar	21 (95.45)	12 (100.00)	9 (90.00)	
Axial location				> 0.99
Central	19 (86.36)	10 (83.33)	9 (90.00)	
Peripheral	3 (13.64)	2 (16.67)	1 (10.00)	
Conus medullaris				0.67
Near	14 (63.64)	7 (58.33)	7 (70.00)	
Distant	8 (36.36)	5 (41.67)	3 (30.00)	
Engorged vein				0.19
No	20	12 (100.00)	8 (80.00)	
Yes	2	0 (0.00)	2 (20.00)	
Margin				> 0.99
Well defined	21 (95.45)	11 (91.67)	10 (100.00)	
Irregular	1 (4.55)	1 (8.33)	0 (0.00)	
Vertebral scalloping				0.14
No	17 (77.27)	11 (91.67)	6 (60.00)	
Yes	5 (22.73)	1 (8.33)	4 (40.00)	
Dissemination to the CSF space				< 0.01*
No	16 (72.73)	12 (100.00)	4 (40.00)	
Yes	6 (27.27)	0 (0.00)	6 (60.00)	
Increased CSF SI caudal to tumor on T1WI				< 0.01*
No	16 (72.73)	12 (100.00)	4 (40.00)	
Yes	6 (27.27)	0 (0.00)	6 (60.00)	

Data are presented as median (range) or n (%).

\* $p < 0.05$ .

CSF = cerebrospinal fluid, IDEM = intradural extramedullary, SI = signal intensity, T1WI = T1 weighted image

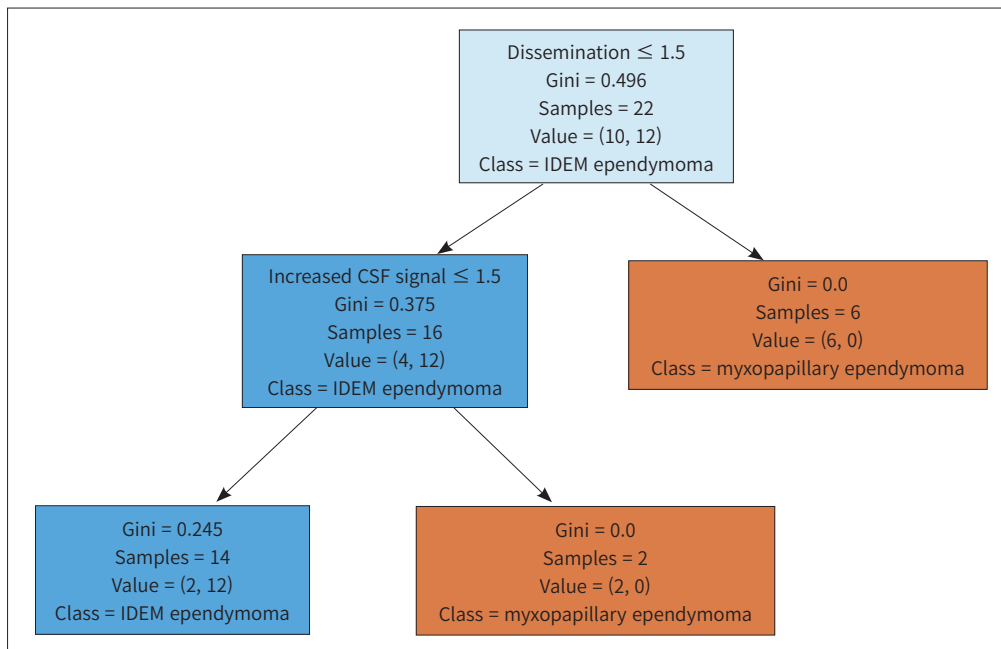
ependymoma and myxopapillary ependymoma (Table 1). Two IDEM ependymomas (2/12, 16.7%) and 3 myxopapillary ependymomas (3/10, 30.0%) were obtained by 3T scanner. 10 ependymomas (10/12, 83.3%) and 7 myxopapillary ependymomas (7/10, 70%) were taken by 1.5T scanner.

High signal intensity in tumor on T1WI was more common in IDEM spinal ependymoma than in myxopapillary ependymoma (41.67% vs. 0%,  $p < 0.01$ ) (Fig. 2). By contrast, tumor dissemination to the CSF space (60.0% vs. 0%,  $p < 0.01$ ) and Increased CSF SI caudal to tumor on T1WI (60.0% vs. 0%,  $p < 0.01$ ) were more common in myxopapillary ependymomas than in IDEM spinal ependymomas (Figs. 3, 4). SI of tumor on T2WI, degree of enhancement, enhancement pattern, tumor size, longitudinal location, axial location, tumor margin, vertebral scalloping, engorged vein, and proximity to the conus medullaris were not significantly different between IDEM spinal ependymomas and myxopapillary ependymomas (Table 2).

In CART analysis, 54.5% of patients (12/22) were IDEM spinal ependymoma. Dissemination to CSF space was the first partitioning predictor in the decision tree model. None of patients with dissemination to CSF space (0/6) demonstrated IDEM spinal ependymoma while 75% of patients without CSF dissemination (12/16) showed IDEM spinal ependymoma. None of patients without CSF dissemination showing increased CSF SI caudal to tumor demonstrated (0/2) IDEM spinal ependymoma while 86% of patients without CSF dissemination and increased CSF SI (12/14) showed IDEM spinal ependymoma. Fig. 5 includes a detailed decision tree of the CART analysis.

Additionally, we analyzed distribution of spinal IDEM tumor by histology. We found total 373 IDEM tumors out of 527 patients who underwent surgery. The most common type of IDEM tumor were schwannoma (63.8%, 238/373), followed by meningioma (22.8%, 85/373), IDEM ependymoma (3.2%, 12/373), myxopapillary ependymoma (2.7%, 10/373), metastasis (1.3%,

Fig. 5. Classification and regression tree analysis results.



CSF = cerebrospinal fluid, IDEM = intradural extramedullary



5/373), hemangioblastoma (1.1%, 4/373), lipoma (1.1%, 4/373), paraganglioma (0.8%, 3/373), cavernous malformation (0.5%, 2/373), hemangiopericytoma (0.5%, 2/373), nerve sheath myxoma (0.5%, 2/373), gangliomeuroma (0.3%, 1/373), capillary hemangioma (0.3%, 1/373), epithelioid tumor (0.3%, 1/373), chondrosarcoma (0.3%, 1/373), oligodendrocytoma (0.3%, 1/373) and myeloid sarcoma (0.3%, 1/373).

## DISCUSSION

In this study, we analyzed the clinical and imaging features of IDEM spinal ependymoma, particularly compared to those of myxopapillary ependymoma. Our results indicated that IDEM spinal ependymoma is likely to occur in the lumbar region, unlike conventional IM spinal ependymoma which has a cervical predominance. Furthermore, compared with myxopapillary ependymoma, IDEM spinal ependymoma occurs in older age, high signal intensity in tumor itself on T1WI was more frequently observed, and CSF dissemination and increased CSF SI caudal to tumor on T1WI were rarely found.

Spinal ependymomas are the most common IM spinal neoplasms, and account for up to 60% of all glial spinal cord tumors. Spinal ependymomas occur most commonly in the cervical region and have a central location (8-10). IDEM spinal ependymomas are rare, and only a few cases have been reported in the literature (6, 11-21).

Ependymomas usually arise from the ependymal cells that form the lining of the ventricles and central canal of the spinal cord. However, IDEM spinal ependymomas may arise from heterotopic ependymal cell rests that are pinched off from the neural tube during its closure (12, 14, 16, 17). This hypothesis is supported by the following descriptions by Cooper et al. (14) lack of an apparent attachment to the central nervous system and absence of signs of a primary neoplastic process within the brain or spinal cord, encapsulated appearance, location along the neuraxis, and frequent association with congenital anomalies.

In this study, IDEM ependymoma accounted for 16.7% (12/72) of the ependymomas in the spinal compartment, which suggested that it is more common than previously reported (4, 5). We found that IDEM spinal ependymoma demonstrated clinical characteristics similar to those described for IM spinal ependymomas in previous studies (3, 6, 11, 13-21). The median age at diagnosis of IDEM spinal ependymoma was 48 years, and we observed a female predominance. However, unlike IM spinal ependymoma, which occurs predominantly in the cervical region, IDEM spinal ependymomas occurred most commonly in the lumbar region. Previous case reports also reported lower spinal locations of IDEM spinal ependymomas, such as the thoracic and lumbar regions (22, 23). Although the exact mechanism for this preponderance of lower spinal location is uncertain, this may be because heterotopic ependymal cell rests are more likely to pinch off from the neural tube during its closure in the lower spine than in the upper spine.

Myxopapillary ependymomas also commonly involve lower spine, particularly conus-cauda equina region, manifesting as IDEM tumors. They are associated with a high local recurrence rate, less commonly distant metastasis along the neuraxis (24). Thus, it is necessary to distinguish IDEM spinal ependymoma from myxopapillary ependymoma before surgery.

We compared clinical and imaging features of IDEM ependymomas and IDEM myxopapil-

lary ependymomas. With regards to clinical features, we observed that patients with IDEM ependymoma were older than those with myxopapillary ependymoma. Although not statistically significant, IDEM spinal ependymoma demonstrated a female predominance, whereas myxopapillary ependymoma had a male predominance. MR findings such as High SI in tumor on T1WI, absence of dissemination to the subarachnoid space, and Increased CSF signal caudal to tumor on T1WI may aid in distinguishing IDEM ependymoma from IDEM myxopapillary ependymoma. According to previous studies, bulky tumors disturbing CSF flow are associated with high protein content of CSF that may theoretically shorten the T1 value of the CSF (25-27). In our results, myxopapillary ependymomas are likely to be larger and to have a vertebral scalloping than IDEM spinal ependymoma and it may also support the likelihood of CSF obstruction caudal to myxopapillary ependymoma.

A high incidence of CSF dissemination has been observed in adult and pediatric myxopapillary ependymoma in line with our result (28) However, CSF dissemination was not observed in IDEM spinal ependymoma. Few studies reported that WHO grade 3 IDEM spinal ependymoma or those with MYCN amplification may have CSF dissemination (29, 30). Unfortunately, our cases were WHO grade 2 and MYCN amplification was not studied.

Another distinctive imaging feature of IDEM spinal ependymoma, compared with myxopapillary ependymoma is high signal intensity of tumor itself on T1WI. Choi et al. reported that 5 % of IM spinal ependymomas (2/35) showed high signal intensity on T1WI (31). In our study, IDEM spinal ependymoma showed a high incidence of high signal intensity on T1WI (42%, 5/12). We may presume that higher incidence of high signal intensity of IDEM spinal ependymoma on T1WI is associated with intra-tumoral hemorrhage, but it needs a further study.

CART analysis also supported the results of our univariate analysis, and showed that older age, absence of abnormal CSF signal intensity, and dissemination to the CSF were the most important variables for distinguishing IDEM spinal ependymoma from myxopapillary ependymoma. Other MRI features of IDEM spinal ependymoma were consistent with those from previous studies, such as homogenous enhancement after gadolinium administration and well-defined margins (6, 11-21). Our results may be useful to distinguish IDEM ependymoma from myxopapillary ependymoma. Our observations have clinical significance because spinal ependymoma and myxopapillary ependymoma are clinicopathologically and genetically distinct variants of ependymoma (32, 33). However, they both commonly occur in the lower spine, which results in a diagnostic dilemma. Therefore, our results may help clinicians to make a more accurate differential diagnosis.

Another common IDEM spinal tumor located on conus medullaris is schwannoma. Unfortunately, schwannoma was not included in our study, but it has been well documented in previous studies. Thus, we may indirectly compare imaging features of schwannoma, myxopapillary ependymoma, and IDEM ependymoma. Schwannoma tended to be larger and more peripheral than myxopapillary ependymoma, Patterns of signal intensities on T1WI/T2WI are heterogeneous for both tumors. However, high signal intensity on T2WI in schwannoma representing cystic portion shows rare enhancement on post contrast T1WI. In contrast, high signal intensity on T2WI in myxopapillary ependymoma corresponding mucin showed homogeneous enhancement (34, 35). In previous few literatures, imaging findings of IDEM spinal

ependymoma are non-specific. They most commonly appear as T2 hyperintense/T1 hypointense lesions, and they are usually homogeneously enhanced after gadolinium administration, well delineated and can have a cystic component which can be confused with imaging features of schwannoma (36). However, based on our results, tendency of IDEM spinal ependymoma for central location, strong enhancement, occurrence near conus medullaris and high signal intensity of tumor on T1WI may aid their differentiation which needs further validation in future study.

The prognosis of IDEM spinal ependymoma is unknown, but it is presumed to have a relatively benign course after complete resection, based on the prognosis of IM spinal ependymoma. IM spinal ependymoma is encapsulated without apparent attachment to the central nervous system, and complete removal is possible in most cases to allow preservation of normal neural tissues (11, 18). However, IDEM spinal ependymoma can recur, undergo anaplastic transformation, or metastasize. In these cases, gross total resection may not always be possible, and the prognosis is poor. Early diagnosis and surgery are important contributors to better neurologic outcomes (6, 11, 12, 18, 19, 37).

Our study has some limitations. First, molecular analysis was not performed in our study. Thus, our cohort of spinal cord ependymoma may represent various molecular subtypes of spinal ependymomas. For example, spinal ependymoma with *MYCN* amplification shows an aggressive behavior. Spinal ependymoma has been known to be associated with *NF2* mutation but its features remain unclear (38). IDEM spinal ependymoma can be associated with a certain molecular subtype of ependymoma, which is required to be investigated in future study. Second, our cohort was too small to draw a robust conclusion. However, given the rarity of IDEM spinal ependymomas, our reports may be helpful for understanding clinico-radiological features of IDEM spinal ependymoma. Third, there was a lack of a long-term follow-up, due to which we could not assess patient's prognosis and tumor recurrence. Most of our patients did not return to the clinic after surgery. Further studies are required to clarify the long-term outcomes of IDEM spinal ependymomas. Lastly, most of our cases were taken on 1.5T MRI. 3T MR imaging is known to increase SNR or spatial resolution compared with 1.5T system at similar scanning times (39). Thus, future study with 3T system may provide more information.

In conclusion, our study demonstrated that IDEM spinal ependymomas are not rare. Frequent involvement of the lower spine and location of IDEM may cause a diagnostic dilemma, and these tumors must be differentiated from myxopapillary ependymomas. Older age, absence of abnormal CSF signal intensity, and comparatively lesser dissemination of the tumor to the CSF may aid in distinguishing IDEM spinal ependymomas from myxopapillary ependymomas.

### Author Contributions

Conceptualization, A.S.J.; data curation, L.S.H., C.Y.J., C.Y.E.; formal analysis, L.S.H., A.S.J.; project administration, A.S.J.; supervision, A.S.J.; writing—original draft, L.S.H., A.S.J.; and writing—review & editing, all authors.

### Conflicts of Interest

The authors have no potential conflicts of interest to disclose.

## Funding

This work was supported by a grant from the Central Medical Service Research Fund to SJA.

## REFERENCES

- Schwartz TH, McCormick PC. Intramedullary ependymomas: clinical presentation, surgical treatment strategies and prognosis. *J Neurooncol* 2000;47:211-218
- Huisman TA. Pediatric tumors of the spine. *Cancer Imaging* 2009;9 Spec No A:S45-S48
- Celano E, Salehani A, Malcolm JG, Reinertsen E, Hadjipanayis CG. Spinal cord ependymoma: a review of the literature and case series of ten patients. *J Neurooncol* 2016;128:377-386
- Kinsman MJ, Callahan JD, Hattab EM, Cohen-Gadol AA. Extramedullary spinal ependymoma: a diagnostic challenge and review of the literature. *Clin Neurol Neurosurg* 2011;113:661-664
- Moriwaki T, Iwatsuki K, Ohnishi Y, Umegaki M, Ishihara M, Yoshimine T. Intradural extramedullary spinal ependymoma: a case report of malignant transformation occurring. *Asian Spine J* 2013;7:139-142
- Graça J, Gültasli N, D'Haene N, Brotchi J, Salmon I, Balériaux D. Cystic extramedullary ependymoma. *AJNR Am J Neuroradiol* 2006;27:818-821
- Lewis RJ. An introduction to classification and regression tree (CART) analysis. Proceedings of the 2000 Annual Meeting of the Society for Academic Emergency Medicine; 2000 May 22-25; San Francisco, CA, USA: Society for Academic Emergency Medicine; 2000
- Koeller KK, Rosenblum RS, Morrison AL. Neoplasms of the spinal cord and filum terminale: radiologic-pathologic correlation. *Radiographics* 2000;20:1721-1749
- Hoshimaru M, Koyama T, Hashimoto N, Kikuchi H. Results of microsurgical treatment for intramedullary spinal cord ependymomas: analysis of 36 cases. *Neurosurgery* 1999;44:264-269
- Fine MJ, Kricheff II, Freed D, Epstein FJ. Spinal cord ependymomas: MR imaging features. *Radiology* 1995;197:655-658
- Benzagmout M, Boujraf S, Oulali N, Chbani L, Amarti A, Chakour K, et al. Intradural extramedullary ependymoma: is there constantly a hormonal relationship? *Surg Neurol* 2008;70:536-538; discussion 538
- Cerase A, Venturi C, Oliveri G, De Falco D, Miracco C. Intradural extramedullary spinal anaplastic ependymoma. Case illustration. *J Neurosurg Spine* 2006;5:476
- Cheng CH, Lee TC, Huang HY, Lui CC. Extramedullary thoracic myxopapillary ependymoma--a case report of a rare tumour. *Ann Acad Med Singap* 1996;25:869-872
- Cooper IS, Craig WM, Kernohan JW. Tumors of the spinal cord; primary extramedullary gliomas. *Surg Gynecol Obstet* 1951;92:183-190
- Duffau H, Gazzaz M, Kujas M, Fohanno D. Primary intradural extramedullary ependymoma: case report and review of the literature. *Spine (Phila Pa 1976)* 2000;25:1993-1995
- Katoh S, Ikata T, Inoue A, Takahashi M. Intradural extramedullary ependymoma. A case report. *Spine (Phila Pa 1976)* 1995;20:2036-2038
- Payer M, Yonekawa Y, Imhof HG. Solitary thoracic intradural extramedullary ependymoma. *J Clin Neurosci* 1999;6:344-345
- Robles SG, Saldaña C, Boto GR, Martinez A, Zamarron AP, Jorquera M, et al. Intradural extramedullary spinal ependymoma: a benign pathology? *Spine (Phila Pa 1976)* 2005;30:E251-E254
- Schuermans M, Vanneste JA, Verstege MJ, van Furth WR. Spinal extramedullary anaplastic ependymoma with spinal and intracranial metastases. *J Neurooncol* 2006;79:57-59
- Wagle WA, Jaufman B, Mincy JE. Intradural extramedullary ependymoma: MR-pathologic correlation. *J Comput Assist Tomogr* 1988;12:705-707
- Wolfla CE, Azzarelli B, Shah MV. Primary extramedullary ependymoma of the thoracic spine. Case illustration. *J Neurosurg* 1997;87:643
- Tripathy P, Mohapatra D, Mohapatra S. Primary intradural extramedullary ependymoma: report of two cases and review of the literature. *Neurol Neurochir Pol* 2011;45:397-401
- lunes EA, Stávale JN, de Cássia Caldas Pessoa R, Ansaí R, Onishi FJ, de Paiva Neto MA, et al. Multifocal intradural extramedullary ependymoma. Case report. *J Neurosurg Spine* 2011;14:65-70
- Celli P, Cervoni L, Cantore G. Ependymoma of the filum terminale: treatment and prognostic factors in a series of 28 cases. *Acta Neurochir (Wien)* 1993;124:99-103

25. Sonneland PR, Scheithauer BW, Onofrio BM. Myxopapillary ependymoma. A clinicopathologic and immunocytochemical study of 77 cases. *Cancer* 1985;56:883-893
26. Norstrom CW, Kernohan JW, Love JG. One hundred primary caudal tumors. *JAMA* 1961;178:1071-1077
27. Monajati A, Wayne WS, Rauschnig W, Ekholm SE. MR of the cauda equina. *AJNR Am J Neuroradiol* 1987;8:893-900
28. Rezai AR, Woo HH, Lee M, Cohen H, Zagzag D, Epstein FJ. Disseminated ependymomas of the central nervous system. *J Neurosurg* 1996;85:618-624
29. Kim BS, Kim SW, Kwak KW, Choi JH. Extra and intramedullary anaplastic ependymoma in thoracic spinal cord. *Korean J Spine* 2013;10:177-180
30. Shields LBE, Sun DA, Highfield HA, LaRocca RV, Spalding AC, Sinicrope KD, et al. Multifocal intradural extramedullary ependymoma, MYCN amplified: illustrative case. *J Neurosurg Case Lessons* 2022;3:CASE22141
31. Choi JY, Chang KH, Yu IK, Kim KH, Kwon BJ, Han MH, et al. Intracranial and spinal ependymomas: review of MR images in 61 patients. *Korean J Radiol* 2002;3:219-228
32. Gilhuis HJ, van der Laak J, Wesseling P, Boerman RH, Beute G, Teepen JL, et al. Inverse correlation between genetic aberrations and malignancy grade in ependymal tumors: a paradox? *J Neurooncol* 2004;66:111-116
33. Hirose Y, Aldape K, Bollen A, James CD, Brat D, Lamborn K, et al. Chromosomal abnormalities subdivide ependymal tumors into clinically relevant groups. *Am J Pathol* 2001;158:1137-1143
34. Ando K, Imagama S, Ito Z, Hirano K, Tsuchi R, Muramoto A, et al. Differentiation of spinal schwannomas and myxopapillary ependymomas: MR imaging and pathologic features. *J Spinal Disord Tech* 2014;27:105-110
35. Kahan H, Sklar EM, Post MJ, Bruce JH. MR characteristics of histopathologic subtypes of spinal ependymoma. *AJNR Am J Neuroradiol* 1996;17:143-150
36. Son DW, Song GS, Han IH, Choi BK. Primary extramedullary ependymoma of the cervical spine : case report and review of the literature. *J Korean Neurosurg Soc* 2011;50:57-59
37. Ando S, Tsuji O, Nagoshi N, Nori S, Suzuki S, Okada E, et al. Grade III intradural extramedullary anaplastic ependymoma managed with near-complete resection and adjuvant radiotherapy: a case report. *Spinal Cord Ser Cases* 2021;7:1
38. Patronas NJ, Courcoutsakis N, Bromley CM, Katzman GL, MacCollin M, Parry DM. Intradural and spinal canal tumors in patients with neurofibromatosis 2: MR imaging findings and correlation with genotype. *Radiology* 2001;218:434-442
39. Phalke VV, Gujar S, Quint DJ. Comparison of 3.0 T versus 1.5 T MR: imaging of the spine. *Neuroimaging Clin N Am* 2006;16:241-248, ix

## 경막내 척수외 뇌실막세포종의 임상 영상의학적 특징

이승현<sup>1</sup> · 차윤진<sup>2</sup> · 조용은<sup>3</sup> · 박미나 · 주비오<sup>1</sup> · 서상현<sup>1</sup> · 안성준<sup>1\*</sup>

**목적** 경막내척수외 뇌실막세포종의 임상 및 영상 특성에 대한 보고는 드물다. 하지만, 발생 위치와 병리학적 특성을 고려하였을 때 점액유두상 뇌실막세포종과 구별하기 어렵다. 본 연구는 경막내척수외 뇌실막세포종과 척수 점액유두상 뇌실막세포종을 구별하기 위한 임상적 특징 및 MRI 영상 특징을 조사하였다.

**대상과 방법** 종양 크기, 종양의 증축/횡축 위치, 조영 정도/패턴, 동공, 종양 변연, T2 강조 영상(T2-weighted image), T1 강조 영상(T1-weighted image; 이하 T1WI), 종양 아래의 cerebrospinal fluid (이하 CSF) T1 신호강도 증가 및 CSF space로의 종양 전파에 대하여 12개의 병리학적으로 확인된 경막내척수외 뇌실막세포종과 10개의 병리학적으로 확인된 척수 점액유두 뇌실막세포종을 대상으로 분석을 하였다. 또한, 분류 및 트리 분석(classification and tree analysis; 이하 CART) 을 수행하여 경막내척수외 척수 뇌실막세포종을 점액유두 뇌실막세포종과 구별하는 데 중요한 임상적 특징 및 MRI 영상 특징을 조사하였다.

**결과** 경막내척수외 뇌실막세포종 환자는 척수 점액유두 뇌실막세포종 환자보다 유의하게 나이가 많았으며(48세 vs. 29.5세,  $p < 0.05$ ), T1WI에서 높은 신호 강도는 점액유두상 뇌실막세포종보다 경막내척수외 척수 뇌실막세포종에서 더 자주 관찰되었다( $p = 0.02$ ). 반대로 점액유두상 뇌실막세포종은 지주막하강으로의 종양의 파급을 보였다. CSF 신호 강도는 경막내척수외 척수 뇌실막세포종보다 점액유두 뇌실막세포종에서 더 자주 관찰되었다( $p < 0.05$ ). 종양 아래로의 CSF T1 신호 증가 및 CSF space로의 종양 전파는 경막내척수외 척수 뇌실막세포종과 점액유두 뇌실막세포종을 구별하기 위한 CART 분석에서 가장 중요한 변수였다.

**결론** 경막내척수외 뇌실막세포종과 척수 점액유두 뇌실막세포종을 구별하는 데 있어 임상 및 MRI 영상의 특징이 도움이 될 수 있다.

연세대학교 의과대학 강남세브란스병원 <sup>1</sup>영상의학과, <sup>2</sup>병리과, <sup>3</sup>신경외과