



Correspondence:

Primary percutaneous coronary intervention in a COVID-19 patient with ST-segment elevation myocardial infarction after lung transplantation: a case report

Tian-ming XUAN¹, Xing-xiang WANG¹,
 Xiang-yuan PU¹, Wei-li HAN^{†‡2}, Xiao-gang GUO^{†‡1}

¹Department of Cardiology, the First Affiliated Hospital, School of Medicine, Zhejiang University, Hangzhou 310003, China

²Department of Lung Transplantation, the First Affiliated Hospital, School of Medicine, Zhejiang University, Hangzhou 310003, China

[†]E-mail: zjhzhdwc@zju.edu.cn; gxx22222@zju.edu.cn

<https://doi.org/10.1631/jzus.B2000182>

Published online May 9, 2020

We present an unusual case of a patient with bilateral-lung transplantation due to severe coronavirus disease 2019 (COVID-19), who subsequently suffered complications with acute myocardial infarction and underwent primary percutaneous coronary intervention (PCI).

A 70-year-old man presented with fever, cough, and dyspnea after returning from Hubei Province at the end of Jan. 2020. The diagnosis of COVID-19 had been confirmed by the nucleic acid test at a local hospital on Feb. 2, 2020. He had a history of mild hypertension and Type 2 diabetes without regular medication. He was a current smoker but denied the history of ischemic heart disease or hyperlipidemia.

Despite initial treatment with methylprednisolone, umifenovir, and darunavir, the patient's condition worsened with continued dyspnea and persisting fever. On Feb. 9 (Day 7 after symptoms onset), the patient was transferred to the intensive care unit (ICU) of our hospital. On arrival, the patient's vital signs were stable except for tachypnoea at 27 min⁻¹. Key

laboratory results were: white blood cell count, $6.6 \times 10^9 \text{ L}^{-1}$; neutrophil, 89.1%; hemoglobin, 129 g/L; platelet count, $180 \times 10^9 \text{ L}^{-1}$; creatinine, 64 $\mu\text{mol/L}$; high sensitive C reaction protein (hs-CRP), 45.51 mg/L. chest computed tomography (CT) scan showed bilateral diffuse infiltration.

After admission, he was treated with high-flow nasal oxygen, methylprednisolone, umifenovir, piperacillin, and tazobactam. On Feb. 14 (Day 12), he was intubated due to severe hypoxia. On Feb. 22 (Day 20), repeated nucleic acid tests for 2019 novel coronavirus (2019-nCoV) in sputum and bronchoalveolar lavage fluid were all negative; however, his condition continued to deteriorate due to pulmonary consolidation complicated by *Stenotrophomonas maltophilia* infection. We began venovenous extracorporeal membrane oxygenation (ECMO) treatment on Feb. 26 (Day 24). A CT scan on Mar. 2 (Day 29) revealed significant progression of pulmonary consolidation (Fig. 1).

A bilateral-lung transplantation was performed on Mar. 8 (Day 34) after multidisciplinary discussion. Postoperatively, the ECMO was withdrawn since the oxygenation had been improved and the patient's general condition was more stable. A continuous renal replacement therapy (CRRT) was started on Mar. 10 (Day 36/Day 2 postoperative) to support renal function. On Mar. 11 (Day 3 postoperative), laboratory results were: hemoglobin, 80 g/L; platelet count, $36 \times 10^9 \text{ L}^{-1}$; creatinine, 103 $\mu\text{mol/L}$; international normalized ratio (INR), 1.77; activated partial thromboplastin time (APTT), 45.9 s; prothrombin time (PT), 20.8 s; D-dimer, 2927.00 $\mu\text{g/L}$.

On Mar. 12 at 9:00 a.m. (Day 4 postoperative), the patient developed a sudden episode of ventricular fibrillation. After cardiopulmonary resuscitation with

[‡] Corresponding authors

ORCID: Xiao-gang GUO, <https://orcid.org/0000-0001-6754-1432>

© Zhejiang University and Springer-Verlag GmbH Germany, part of Springer Nature 2020

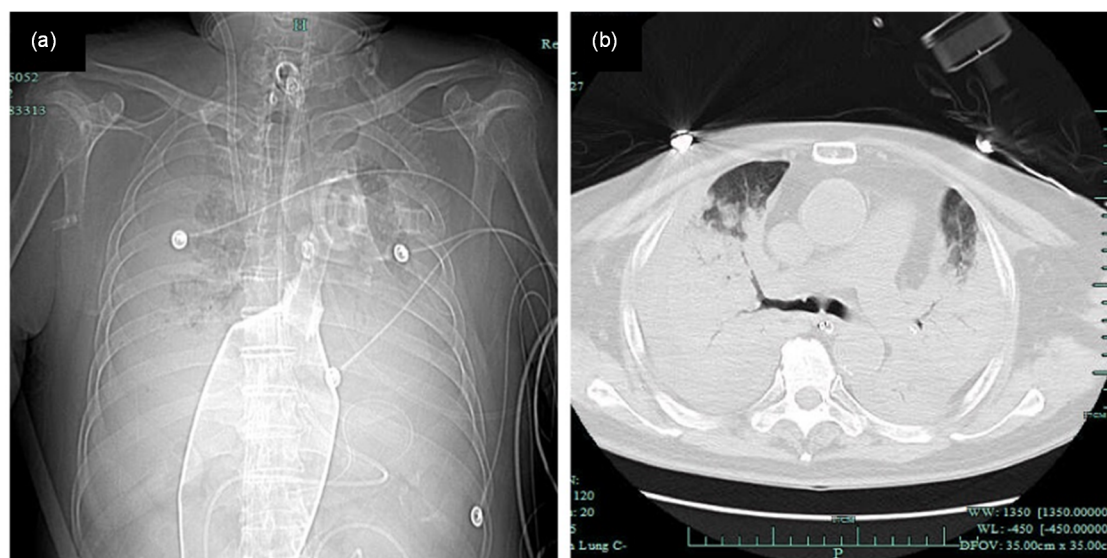


Fig. 1 Severely diffused consolidation of the lung shown by chest X-ray (a) and computed tomography (CT) (b) scans

defibrillation, sinus rhythm was restored. However, the high-sensitivity cardiac troponin I (hs-cTnI) gradually increased to 23.31 ng/mL. Electrocardiogram (ECG) showed dynamic change of ST-segment elevation through V1 to V6 leads (Fig. 2). Echocardiography suggested mildly reduced left ventricular (LV) systolic function and segmental hypokinesia of the ventricular septum and anterior LV wall. ST-segment elevation myocardial infarction (STEMI) was diagnosed and primary PCI was performed on Mar. 13 at 7:00 p.m. (Day 5 postoperative). Coronary angiography showed severe stenosis and thrombus formation in the middle segment of left anterior descending (LAD) artery with thrombolysis in myocardial infarction (TIMI) Grade 3 flow, and mild to moderate stenosis in the remaining vessels. A 3.0-mm diameter by 24-mm long sirolimus-eluting stent (Partner, Lepu Medical, Beijing, China) was deployed at the LAD lesion, followed by post-dilation with a 3.25-mm diameter by 15-mm non-compliant balloon (NC Quantum, Boston Scientific, USA). Post-procedural TIMI flow was Grade 3 (Fig. 2), and the patient's hemodynamics have remained stable since then. Dual antiplatelet therapy with aspirin 100 mg and clopidogrel 75 mg daily was started after intervention for 3 d. Aspirin was discontinued on the fourth day after PCI due to multiple bleeding risks. Post PCI ECG showed recovery of ST-segment, and cTnI gradually declined.

Beginning in Dec. 2019, a sudden outbreak of COVID-19 epidemic swept across China and spread

to many countries around the world. The WHO declared a public health emergency of international concern on Jan. 30, 2020. COVID-19 mainly affects the respiratory tract, and the clinical manifestations are mostly fever, dry cough, fatigue, and dyspnea. In some cases, the virus can develop into severe pneumonia, acute respiratory distress syndrome (ARDS), and multiple organ dysfunctions (Huang et al., 2020). It is worth noting that an increasing number of cases show that in addition to the typical respiratory symptoms caused by 2019-nCoV infection, the virus can also cause cardiovascular complications, especially severe myocardial damage, which aggravates the disease and impacts the prognosis.

A recent study reported that among the earliest 41 COVID-19 patients in Wuhan, five were diagnosed with acute myocardial injury (12%), which was mainly manifested by elevated levels of hs-cTnI (Huang et al., 2020). In another recent report of patients in Wuhan, of the 138 patients hospitalized for COVID-19, 16.7% developed arrhythmia and 7.2% had acute myocardial injury (Wang et al., 2020). Among the earliest reported deaths in Wuhan, one patient was diagnosed with severe COVID-19-associated myocarditis, with myocardial injury markers up to 20 times the upper limit of normal range and matched abnormal ECG manifestations (Wuhan Municipal Health Commission, 2020).

In addition to direct myocardial damage, COVID-19 may also be a potential factor that induces instability of coronary plaque, although researchers currently do

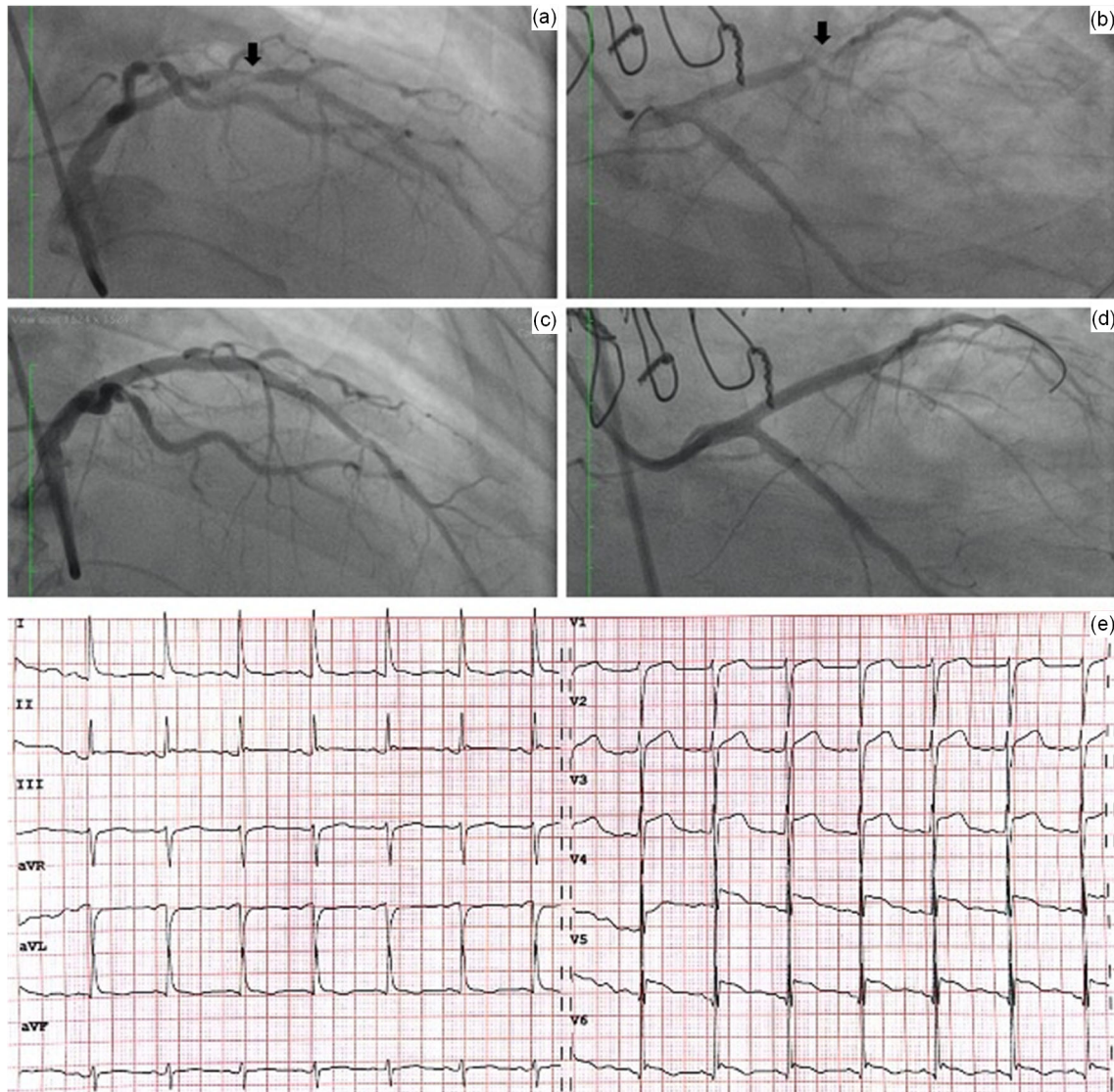


Fig. 2 Coronary angiograms and electrocardiogram (ECG) after cardiopulmonary resuscitation

Angiograms before (a, b) and after (c, d) primary percutaneous coronary intervention with stent implantation. Right anterior oblique (RAO) views with cranial angulation (a) and caudal angulation (b) suggest a significant lesion in the left anterior descending artery (arrows). (e) ECG shows diffuse ST-segment elevation through V1 to V6 leads

not have sufficient direct evidence to confirm this hypothesis. Previous severe acute respiratory syndrome (SARS)-related clinical studies reported multiple cases complicated with acute myocardial infarction. Researchers believed that SARS coronavirus infection may cause dysregulation of inflammatory cytokines, such as elevated interleukin (IL)-1 β , interferon (IFN)- γ , IFN-induced protein-10 (IP-10), and monocyte chemoattractant protein-1 (MCP-1), which in turn trigger cytokine storms that cause myocardial damage and plaque instability in turn leading to

myocardial infarction (Peiris et al., 2003; Tsui et al., 2005). Recent studies have shown that COVID-19 patients also have cytokine storms caused by the imbalance of T helper type 1 (Th1) and Th2 responses, and the levels of inflammatory factors IL-4, IL-10, and IL-6 in tissue samples were increased (Chen et al., 2020; Huang et al., 2020).

According to the current internationally accepted definition of myocardial infarction (Thygesen et al., 2018), myocardial infarction is divided into five types. Type 1 is plaque rupture or erosion of the coronary

arteries, which affects coronary blood flow and leads to myocardial infarction, and Type 2 refers to an imbalance of myocardial blood supply/demand caused by specific factors that can lead to myocardial ischemic infarction. In our case, the angiography showed that the LAD artery was severely stenotic along with thrombus formation, but the blood flow was TIMI Grade 3. Based on the clinical characteristics of this case, we propose that the possible mechanism of myocardial infarction here included severe pulmonary infection, imbalance between coagulation and fibrinolysis subsequent to lung transplantation, changes in blood flow shear stress, and possible cytokine storms, which in combination led to plaque rupture in the LAD artery. Additional factors such as hypoxia and blood loss may have aggravated the ischemia. In other words, both Type 1 and Type 2 myocardial infarctions may have contributed to the patient's pathophysiological changes.

In terms of treating acute myocardial infarction, considering that the patient had recent 2019-nCoV infection and bilateral-lung transplantation, we organized multiple rounds of multi-disciplinary discussions and decided that primary coronary intervention rather than thrombolytic therapy was suitable for the patient. Due to severe infection, recent lung transplantation, and a combination of high bleeding risks (e.g., advanced age, declined platelet count, and prolonged PT), we treated the patient with a tailored antithrombotic regime with dual antiplatelets of aspirin and clopidogrel for 3 d post-PCI, and single antiplatelet therapy with clopidogrel thereafter. We also intensified prevention of gastrointestinal bleeding with acid suppression by a proton pump inhibitor and gastric mucosa protection.

As the designated hospital for the treatment of critically ill patients with COVID-19 in Zhejiang Province, our hospital has formulated detailed and complete plans for various situations in dealing with infected patients. The areas in which this case patient was treated included a designated cardiac catheterization lab that had been divided into a contaminated area, a semi-contaminated area, a buffer zone, and a clean area. All the equipment and devices for the interventional procedures were prepared and were in place. To prevent cross contamination, our procedures established that all the items could only be transferred from the outside to the inside in one-way

direction. Although our patient's nucleic acid test for 2019-nCoV had been negative for over 20 d, all the participating medical staff were equipped to reduce the potential risk of cross-infection according to the standard three-level protection measures including N95 masks, goggles, face protection masks, and isolation gowns. Coronary intervention was carried out according to the cardiovascular management principles of COVID-19 recently released by the Chinese Society of Cardiology (CSC) (Han et al., 2020).

Finally, although coronary-computed tomography angiography (CTA) was recommended before the surgery, transporting this patient with multiple supportive equipment was not realistically possible and the risk for transferring such an unstable patient for a CT scan was considered to be too high. Thus, coronary CTA was not performed before lung transplantation. The alternative preoperative cardiac assessment could be considered.

This case is the first reported case of COVID-19 complicated with acute myocardial infarction treated with primary PCI, and the first case of acute myocardial infarction after bilateral-lung transplantation. In addition to the patient's underlying severe coronary atherosclerosis, factors such as viral infection, inflammatory cytokine storm, hypoxia, blood loss, and bilateral-lung transplantation may contribute to the pathophysiology of myocardial infarction. Supported by interdisciplinary team cooperation, we were able to effectively stabilize the patient, using for full protection procedures and strictly adhering to established methods primary PCI.

Contributors

Tian-ming XUAN and Xiang-yuan PU reviewed literatures and prepared the first draft of the manuscript. Xing-xiang WANG, Wei-li HAN, and Xiao-gang GUO revised, edited, and checked the final version. All authors have read and approved the final manuscript and, therefore, have full access to all the data in the study and take responsibility for the integrity and security of the data.

Compliance with ethics guidelines

Tian-ming XUAN, Xing-xiang WANG, Xiang-yuan PU, Wei-li HAN, and Xiao-gang GUO declare that they have no conflict of interest.

All procedures followed were in accordance with the ethical standards of the responsible committee on human experimentation (institutional and national) and with the Helsinki Declaration of 1975, as revised in 2008 (5). Informed

consent was obtained from the patient for being included in the report.

References

- Chen NS, Zhou M, Dong X, et al., 2020. Epidemiological and clinical characteristics of 99 cases of 2019 novel coronavirus pneumonia in Wuhan, China: a descriptive study. *Lancet*, 395(10223):507-513.
[https://doi.org/10.1016/S0140-6736\(20\)30211-7](https://doi.org/10.1016/S0140-6736(20)30211-7)
- Han YL, Zeng HS, Jiang H, et al., 2020. CSC expert consensus on principles of clinical management of patients with severe emergent cardiovascular diseases during the COVID-19 epidemic. *Circulation*, in press.
<https://doi.org/10.1161/CIRCULATIONAHA.120.047011>
- Huang CL, Wang YM, Li XW, et al., 2020. Clinical features of patients infected with 2019 novel coronavirus in Wuhan, China. *Lancet*, 395(10223):497-506.
[https://doi.org/10.1016/S0140-6736\(20\)30183-5](https://doi.org/10.1016/S0140-6736(20)30183-5)
- Peiris JSM, Chu CM, Cheng VCC, et al., 2003. Clinical progression and viral load in a community outbreak of coronavirus-associated SARS pneumonia: a prospective study. *Lancet*, 361(9371):1767-1772.
[https://doi.org/10.1016/S0140-6736\(03\)13412-5](https://doi.org/10.1016/S0140-6736(03)13412-5)
- Thygesen K, Alpert JS, Jaffe AS, et al., 2018. Fourth universal definition of myocardial infarction (2018). *J Am College Cardiol*, 72(18):2231-2264.
<https://doi.org/10.1016/j.jacc.2018.08.1038>
- Tsui KL, Leung TC, Yam LYC, et al., 2005. Coronary plaque instability in severe acute respiratory syndrome. *Int J Cardiol*, 99(3):471-472.
<https://doi.org/10.1016/j.ijcard.2003.11.052>
- Wang DW, Hu B, Hu C, et al., 2020. Clinical characteristics of 138 hospitalized patients with 2019 novel coronavirus-infected pneumonia in Wuhan, China. *JAMA*, 323(11):1061-1069.
<https://doi.org/10.1001/jama.2020.1585>
- Wuhan Municipal Health Commission, 2020. Website of Wuhan Municipal Health Commission, Hubei, China. <http://wjw.wuhan.gov.cn/front/web/showDetail/2020011609057> [Accessed on Mar. 26, 2020] (in Chinese).

中文概要

题目：重症 COVID-19 感染双肺移植术后急性心肌梗死行急症冠脉介入治疗一例报告

概要：本文首次报告了重症新型冠状病毒肺炎（COVID-19）感染接受肺移植并行急症冠脉介入治疗的病例。通过对多学科协作成功救治的总结，为重症 COVID-19 救治提供经验。我们发现，重症 COVID-19 感染在肺移植术后可能出现多种危险因素诱发心肌梗死，急症冠脉介入治疗是救治此类患者的重要手段。

关键词：新型冠状病毒肺炎（COVID-19）；肺移植；心肌梗死；冠脉介入治疗