

# Arterial thoracic outlet syndrome caused by cervical ribs—an unusual case report

Shuai Jiang, MD<sup>a</sup>, Hui Shen, MD<sup>a</sup>, Wei Qiang Tan, MD<sup>b</sup>, Hui Lu, MD<sup>a,\*</sup>

## Abstract

**Rationale:** Cervical ribs are rare conditions, occurring in 0.05% to 3.0% of the population. This manuscript reports a case of arterial thoracic outlet syndrome (ATOS) associated with this congenital anomaly.

**Patient concerns:** We report a 32-year-old female worker presenting pain in her left upper-extremity for 7 months. Her left hand became paler and cold when the temperature decreased, and the symptoms could not be eased through rest, physiotherapy and drugs medication.

**Diagnoses:** Compression of left subclavian artery with axillary and brachial arteries thrombosis was confirmed by duplex ultrasound and computed tomography angiography. ATOS caused by cervical ribs was confirmed by medical history, physical examination, and imaging.

**Interventions:** The patients underwent acute thrombolysis and balloon angioplasty.

**Outcomes:** Symptoms of pain and weakness disappeared after surgery. The patient had not experienced any apparent symptom recurrence at 1-year follow-up.

**Lessons:** Successful treatment of ATOS depends upon urgent assessment, accurate identification of causative factors and compression site and early diagnosis before the event of arterial thrombosis. The surgery combined with anticoagulation treatment can improve the treatment outcome of ATOS.

**Abbreviations:** CTA = computed tomography angiography, TOS = thoracic outlet syndrome.

**Keywords:** arterial thoracic outlet syndrome, cervical ribs, surgery

## 1. Introduction

Thoracic outlet syndrome (TOS) is a disease caused by compression on the subclavian vessels and/or brachial plexus

Editor: N/A.

The National Natural Science Foundation of China (grant no. 81702135) and Zhejiang Medicine and Hygiene Research Program (NO. 2018264489) support the work.

These study protocols were approved by the Ethics Committee of medical ethics committee of the First Affiliated Hospital, College of Medicine, Zhejiang University.

The dataset supporting the conclusions of this article is included in the article.

All the authors express the consent for publication in this journal. Written informed consent was obtained from the patient for publication of this case report and any accompanying images. A copy of the written consent is available for review by the Editor-in-Chief of this journal.

The authors report no conflicts of interest.

<sup>a</sup> Department of Hand Surgery, The First Affiliated Hospital, <sup>b</sup> Department of Plastic Surgery, Sir Run Run Shaw Hospital, College of Medicine, Zhejiang University, Hangzhou, Zhejiang Province, PR China.

\* Correspondence: Hui Lu, Department of Hand Surgery, the First Affiliated Hospital, College of Medicine, Zhejiang University, No. 79, Qingchun Road, 310003 Hangzhou, Zhejiang Province, PR China (e-mail: huilu@zju.edu.cn).

Copyright © 2019 the Author(s). Published by Wolters Kluwer Health, Inc. This is an open access article distributed under the terms of the Creative Commons Attribution-Non Commercial-No Derivatives License 4.0 (CCBY-NC-ND), where it is permissible to download and share the work provided it is properly cited. The work cannot be changed in any way or used commercially without permission from the journal.

Medicine (2019) 98:11(e14778)

Received: 19 September 2018 / Received in final form: 31 January 2019 /

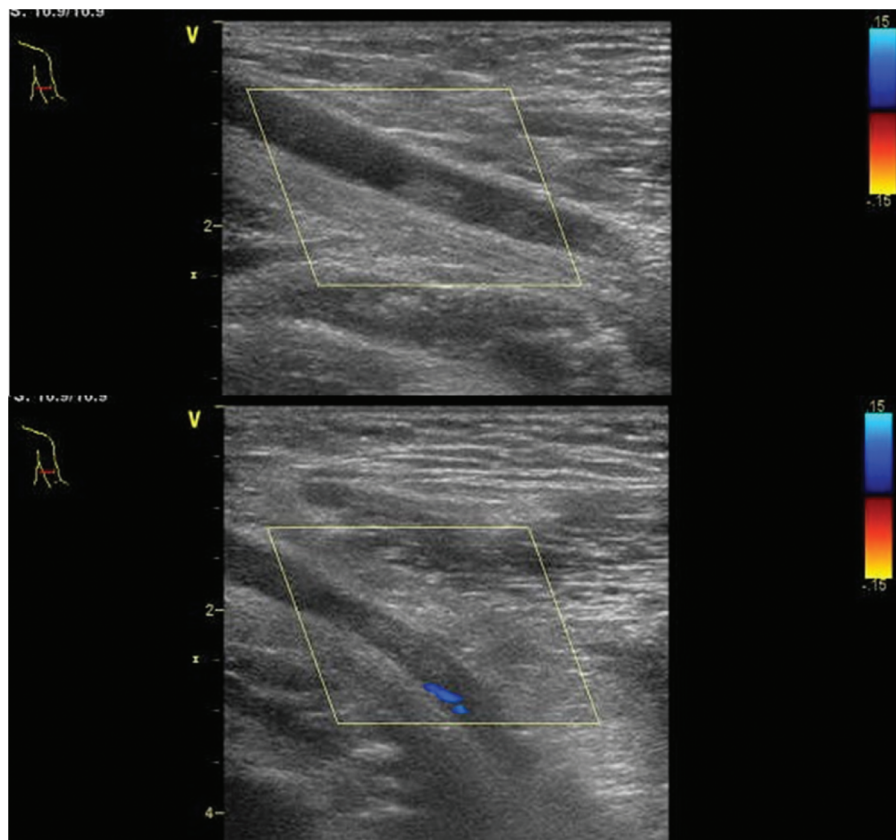
Accepted: 13 February 2019

<http://dx.doi.org/10.1097/MD.0000000000014778>

as it travels through the thoracic outlet. TOS is classified into 3 distinct subtypes based on the involved structure: neurogenic TOS (NTOS), venous TOS (VTOS), and arterial TOS (ATOS), with the minority of cases (less than 1%) being ATOS in nature. ATOS results from obstruction of the subclavian artery usually caused by a cervical or anomalous first rib, scalene muscle, fibromuscular bands, or pectoralis minor tendon,<sup>[1]</sup> with the majority of surgical cases (74%–100%) attributable to abnormal ribs.<sup>[2,3]</sup> ATOS often remains asymptomatic until embolization occurs. Chronic arterial compression may lead to claudication, thrombus formation, and possible embolization.<sup>[3]</sup> Successful ATOS treatment depends on accurate establishment of diagnosis and identification of the site(s) of arterial compression. The goal of treatment is restoring distal arterial blood flow and through surgical decompression. The management options of ATOS include cervical or anomalous first-rib resections, scalene or pectoralis minor muscle releases, and subclavian arterial reconstructions with grafting.<sup>[4]</sup> In this article, we report a rare case of ATOS caused by cervical rib. The patient's consent was obtained to publish his case.

## 2. Case presentation

A 32-year-old female presented with left hand and finger pain after exercise 7 months ago. The patient did not feel any other discomfort and she reported no history of trauma. Through physiotherapy, the patient's symptoms could not be eased. The pain level had slowly risen and since 4 months ago, the patient presented with coldness and pallor on her left hand. No numbness, tingling, neck and shoulder pain were found in this case. Physical examination revealed an absence of distal upper



**Figure 1.** Duplex ultrasound showed wide artery thrombosis in the left axillary and brachial arteries.

extremity pulses at rest, delayed capillary refill and color changes of the hands and fingers on her left. Provocative tests like Adson test and Roos test were positive. The patient had the normal activities of hand function and grip strength. Atrophy of the upper-extremity muscle and positive neurological signs were not seen. Duplex ultrasound scan showed wide artery thrombosis in the left axillary and brachial arteries (Fig. 1). A subsequent computed tomography (CT) angiography showed the existence of left cervical rib, leading the compression of left subclavian artery; the left brachial artery was narrow, with occlusion of the distal part, and the radial and ulnar artery could not be shown clearly (Fig. 2). A lateral neck radiograph identified an unusual bony contour anteriorly at C7/T1 suggesting a left cervical rib, and it articulated with the bony prominence arising from the mid part of the first rib and forming a pseudarthrosis (Fig. 3). So the diagnosis of ATOS combined with left axillary and brachial arterial thrombosis was made. The patient underwent acute thrombolysis and balloon angioplasty. Intraoperatively, the distal subclavian artery twisted with axillary and brachial artery thrombosis. Through acute thrombolysis and balloon angioplasty, partial thrombus was removed and the blood flow improved.

One month after the treatment, the symptom of pain in left upper-extremity was eased obviously. But the patient still complained about coldness and early fatigability. Physical examination elicited left-hand weakness with loss of the radial pulse. The computed tomography confirmed left cervical rib; the left articulating with an extended left transverse process of the seventh cervical vertebra, extending inferiorly to articulate with the anomalous bony prominence arising from the first rib. The left

subclavian artery passed immediately through these bony prominences and scalene fissure, and the diagnosis of ATOS was made. Tumor biological markers and laboratory analyses including complete blood count, C-reactive protein, electrolytes, blood coagulation, and D-dimer were normal. The operative management was performed. A supraclavicular incision was made. Intraoperatively, the left cervical rib was found to extend from the C7 transverse process to form a joint with the anomalous bony prominence and hypertrophied fibrosis scalene muscle on the first rib. The subclavian artery was severely compressed with significantly diminished arterial pulse. Both the cervical rib, anomalous bony prominence of the first rib and fibrosis scalene muscle were excised (Fig. 4). Adventitia releasing of subclavian artery was made completely, and the adherent tissue was released. Surgical procedure was carried out with surgical loupes. After this decompression, the subclavian arterial pulse was significantly enhanced. Considering the personal factors, the patient declined subclavian arterial reconstruction with grafting.

The incision healed without hospital infection. One week after the surgery, the patient was able to perform full motion of the operated upper extremity. The patient accepted antithrombotic therapy for the next 1 year. Symptoms of pain and weakness disappeared, and occasionally, coldness and color change still existed. The computed tomography angiography (CTA) showed the occlusion of subclavian artery with the formation of bypass from subclavian artery to axillary artery; distal brachial artery, radial, and ulnar artery were partially narrow a year after surgery (Fig. 5). The routine treatment of antithrombotic was significant in daily life. The patient was followed up by telephone every 3



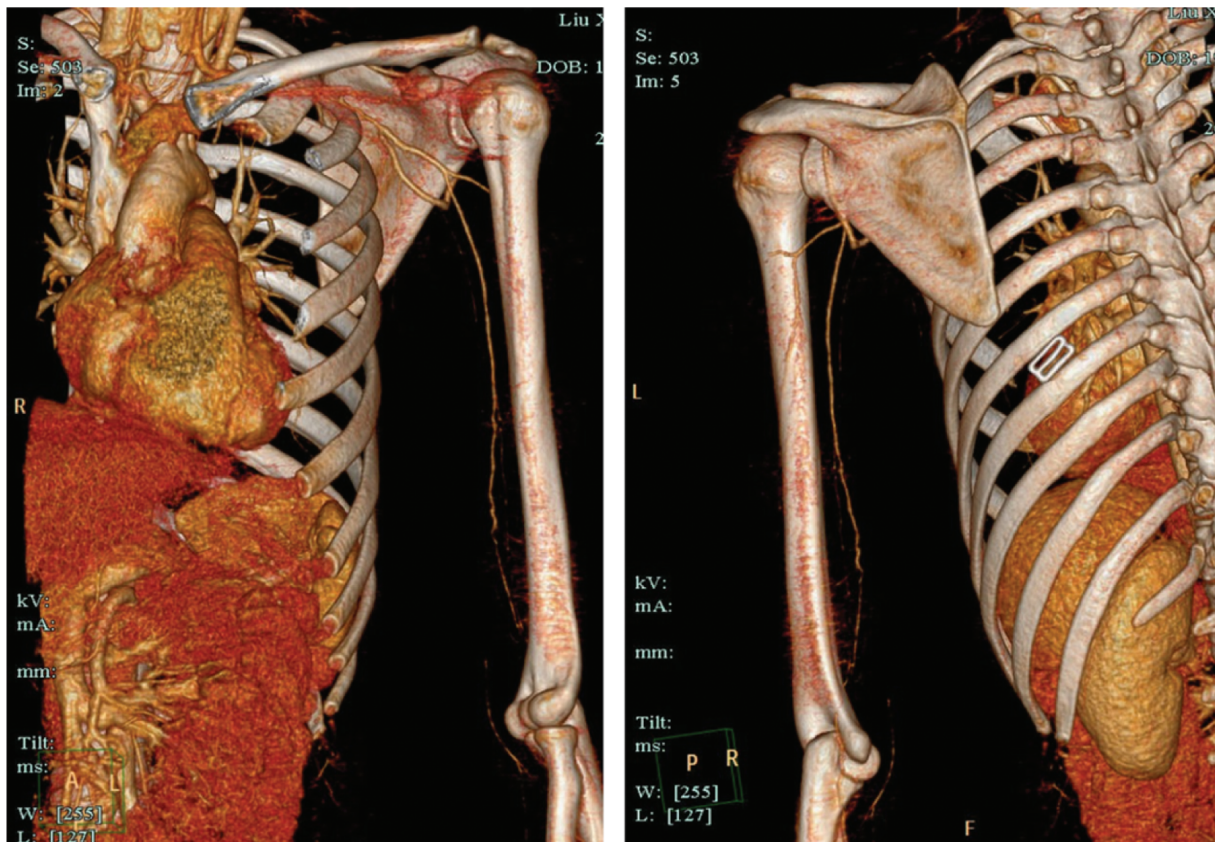


Figure 2. CTA showed the narrow left brachial artery with occlusion of the distal part. CTA=computed tomography angiography.

months. The patient reported their feelings of recovery, range of joint activity, outcomes of PT and INR, and so on. One year after the surgery, the patient had not experienced any apparent symptom recurrence and she was satisfied with the outcome of the surgery.

### 3. Discussion

Cervical ribs are congenital anomalies with incidences of 0.05% to 3.0%.<sup>[5,6]</sup> Generally, they are not clinically relevant. Cervical ribs may cause TOS because of compression on the subclavian vessels and/or brachial plexus by the rib or a fibrous band that connects the cervical rib to the first rib.<sup>[7]</sup> In our case, the patient had a left cervical rib with an unusual pseudoarthrosis between the cervical rib and bony prominence arising from the first rib without any previous history of fracture. In a previous case report by Mahadev Dixit et al, they discussed a similar case of bilateral cervical ribs with pseudoarthrosis of cervical rib with first rib

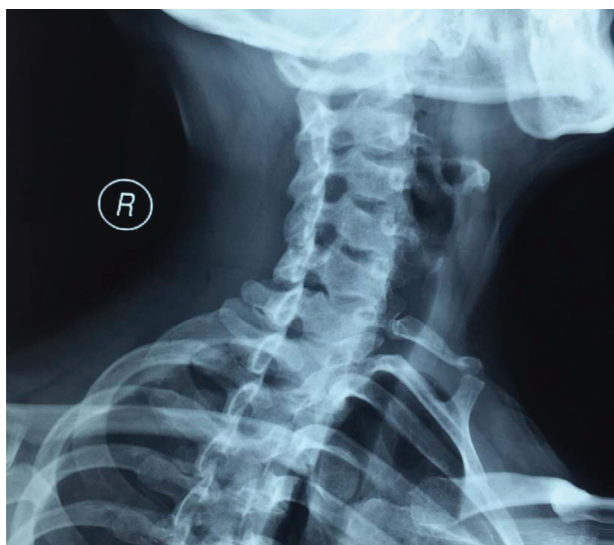


Figure 3. Lateral neck radiograph: an unusual bony contour anteriorly at C7/T1 suggested a left cervical rib, and it articulated with the bony prominence arising from the mid part of the first rib and forming a pseudoarthrosis.

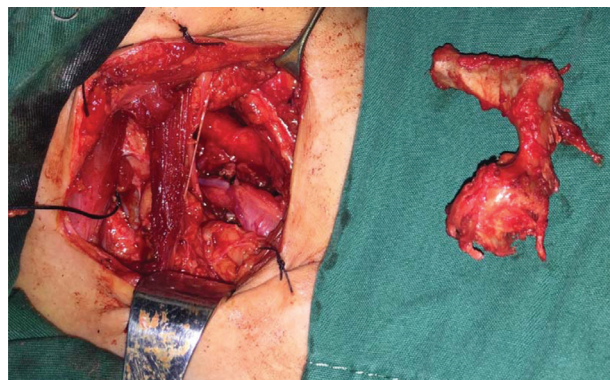
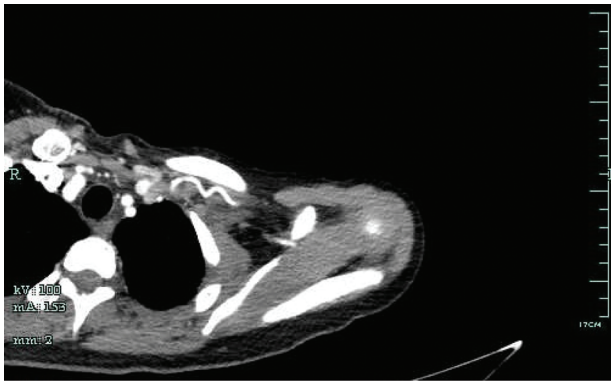


Figure 4. The cervical rib and anomalous bony prominence of the first rib were removed completely.



**Figure 5.** CTA: the occlusion of subclavian artery with the formation of bypass from subclavian artery to axillary artery 1 year after surgery. CTA=computed tomography angiography.

causing vascular complication in the form of total occlusion of subclavian artery.<sup>[8]</sup> With the adventitia released completely, the subclavian artery got adequate decompression. Fortunately, through urgent assessment and accurate diagnosis, acute thrombolysis and balloon angioplasty was performed in time and no limb gangrene was found in this patient.

ATOS often remains asymptomatic until embolization occurs. Symptoms and signs include pain, cyanosis, pallor, coldness, early fatigability, and delayed capillary refill because of arterial obstruction. When an arterial TOS is suspected, Doppler ultrasonography, conventional arteriography, and CTA or magnetic resonance angiography (MRA) are the competent imaging modality used to detect the stenosis, thrombus formation, and vascular compression, and further to identify the structural factors predisposing to arterial obstruction. As 74% to 100% of surgical cases in ATOS have abnormal ribs, neck radiographs are valuable to demonstrate the abnormality.<sup>[2,3]</sup> In this case, with the symptoms and signs of hand and finger pain, coldness, pallor, absence of distal limb pulses, and delayed capillary refill, ATOS was suspected and compression of left subclavian artery with axillary and brachial arteries thrombosis was confirmed by duplex ultrasound and CTA. The identification of left cervical rib and an unusual pseudarthrosis forming by the cervical rib and bony prominence arising from the first rib by neck radiographs contributed to the diagnosis of ATOS caused by abnormal cervical rib.

The goal of treatment is reconstructing distal arterial blood flow and complete relief of vascular symptoms. Successful treatment of ATOS depends upon urgent assessment, accurate identification of causative factors and compression site. Surgical management involves abnormal cervical rib removal and scalene or pectoralis minor muscle releases, and anomalous first rib resections, if indicated.<sup>[9]</sup> If the subclavian artery cannot provide sufficient distal arterial blood flow with adequate decompression, reconstructions with grafting should be done. In our case, the patient underwent acute thrombolysis and balloon angioplasty to

remove partial thrombus, and resections of cervical rib, anomalous bony prominence of the first rib and fibrosis scalene muscle were performed 1 month later. With complete adventitia releasing, the subclavian artery got adequate decompression, so no further anomalous first rib resection was performed.

#### 4. Conclusion

Successful treatment of ATOS depends upon urgent assessment, accurate identification of causative factors and compression site and early diagnosis before thrombus of artery events. Surgery with adequate decompression of subclavian artery can relieve vascular symptoms completely and improve the treatment outcome of ATOS.

#### Acknowledgments

First and foremost, I would like to show my deepest gratitude to my colleagues Dr Hui Lu and Dr Hui Shen who have provided me with valuable assist in every stage of writing this paper. Meanwhile, I also appreciate National Natural Science Foundation of China (grant no. 81702135) and Zhejiang Medicine and Hygiene Research Program (NO. 2018264489) for sponsoring our research. Last but not least, I'd like to thank all my friends, especially my lovely wife for her encouragement and support.

#### Author contributions

**Conceptualization:** Hui Shen.

**Data curation:** Shuai Jiang, Hui Shen.

**Funding acquisition:** Hui Lu, Shuai Jiang.

**Investigation:** Hui Shen.

**Resources:** Hui Lu.

**Writing – original draft:** Shuai Jiang.

**Writing – review & editing:** Shuai Jiang, Wei Qiang Tan, Hui Lu. Shuai Jiang orcid: 0000-0002-4401-6595.

#### References

- [1] Schon N, Netzsch C, Kroger K. Subclavian vein thrombosis and backpacking. *Clin Res Cardiol* 2007;96:42–4.
- [2] Sanders RJ, Hammond SL, Rao NM. Diagnosis of thoracic outlet syndrome. *J Vasc Surg* 2007;46:601–4.
- [3] Reeser JC. Diagnosis and management of vascular injuries in the shoulder girdle of the overhead athlete. *Curr Sports Med Rep* 2007;6:322–7.
- [4] Doyle A, Wolford HY, Davies MG, et al. Management of effort thrombosis of the subclavian vein: today's treatment. *Ann Vasc Surg* 2007;21:723–9.
- [5] Brewin J, Hill M, Ellis H. The prevalence of cervical ribs in a London population. *Clin Anat* 2009;22:331–6.
- [6] Viertel VG, Intrapiromkul J, Maluf F, et al. Cervical ribs: a common variant overlooked in CT imaging. *AJNR Am J Neuroradiol* 2012;33:2191–4.
- [7] Kuhn JE, Lebus VGF, Bible JE. Thoracic outlet syndrome. *J Am Acad Orthop Surg* 2015;23:222–32.
- [8] Dixit M, Gan M, Nishanimath N, et al. Double cervical rib with uncommon presentation. *Indian J Thorac Cardiovasc Surg* 2010;26:30–3.
- [9] Sanders RJ, Hammond SL. Management of cervical ribs and anomalous first ribs causing neurogenic thoracic outlet syndrome. *J Vasc Surg* 2002;36:51–6.