

Detorsion and Conservative Therapy for Twisted Adnexa: Our Experience

Sunita Tandulwadkar, Amit Shah,
Bhavana Agarwal

Ruby Hall IVF and Endoscopy Center, Ruby Hall
Clinic, Pune, India

ABSTRACT

Objective: 1) To determine if detorsion of the twisted adnexa is better than traditional adnexectomy to conserve the adnexa and preserve its function. 2) To determine the feasibility of detorsion in conservation of adnexa. **Design:** Prospective Study from September 2004 to September 2008. **Setting:** Private IVF and Endoscopy Centre. **Patients:** 22 patients with twisted adnexa (15 non-pregnant and 7 pregnant). **Intervention:** Surgical intervention and either detorsion of adnexa or adnexectomy. **Main Outcome Measures:** Ovarian preservation and conservation of ovarian function in 77.2% cases determined by: a) Follicular development on sonography (performed for one year after adnexectomy). b) Subsequent surgery for unrelated cause showing healthy ovaries. c) controlled ovarian hyperstimulation and successful oocyte retrieval subsequently. **Results:** We could conserve the adnexa in 77.2% cases. Laparoscopic detorsion was performed in 11/15(73.33 %) of non-pregnant women and adnexectomy done in four women 26.66%. Among the seven pregnant women, adnexa could be preserved in 6/7(85.7%) and only one woman required adnexectomy. Laparotomy was required in 2/22(9%) women both of which were in late second trimester of pregnancy. In one case (4.54%) we had recurrence of torsion. 88.23% of the women with conserved adnexa showed preservation of ovarian function. **Conclusion:** Our study showed that timely diagnosis and intervention could make the difference between ovarian loss and salvage- an outcome of great importance in population of reproductive age females. Laparoscopy with its many benefits proves to be superior to laparotomy.

Key words: Twisted adnexa, torsion, untwisting, detorsion, conservation

DOI: 10.4103/0974-1216.51905

INTRODUCTION

Adnexal torsion is a rare gynecological event with an incidence of 2.7%.^[1] Kustener first described ovarian torsion in 1891 as partial or complete rotation of the ovarian pedicle on its long axis, potentially compromising venous and lymphatic drainage.^[2]

Until two decades ago, the standard approach to twisted adnexa was salpingo-oophorectomy. In 1989, Mage *et al.* proved that detorsion and preservation of adnexa is an alternative mode of treatment and ever since it has become the method of approach by many, replacing excision of adnexa whenever possible.

Timely diagnosis and intervention can make the difference

Address for correspondence:

Sunita Tandulwadkar,
Ruby Hall IVF & Endoscopy Center, Ruby Hall Clinic, Pune.
E-mail: sunitart@hotmail.com

between ovarian loss and salvage - an outcome of great importance in population of reproductive age females. Laparoscopy with its many proven benefits seems to be superior to laparotomy.

MATERIALS AND METHODS

This prospective study was conducted in Ruby Hall IVF and Endoscopy Centre over the past four years (September 2004 to September 2008), 22 patients were treated out of which, 15 were non-pregnant and 7 pregnant. The study was reviewed and approved by Ruby Hall Clinic's institutional review board.

The patients with twisted adnexa were identified on the basis of signs and symptoms.

Classically, patients with torsion present with acute onset of severe, progressive unilateral abdominal or pelvic pain, which is crampy or colicky in nature.^[3] The pain radiated

to the thigh or lower half of affected side.^[4] Incomplete or complete torsion was characterized by bouts of severe pain separated by asymptomatic period as the ovary twists and untwists.^[5] Nausea and vomiting was common^[6,7] and low-grade fever was present in few patients (less than 38.8° F).^[8]

The physical examination revealed soft abdomen with lower quadrant tenderness. However if torsion was long standing, the abdomen may be diffusely tender with peritonitis and rigidity making localization difficult.^[4] Bimanual pelvic examination demonstrated uterine shift towards the affected side. Adnexal tenderness was typical and upto 50% of women had palpable adnexal mass.^[8]

Immediate ultrasound with color doppler was performed as the investigation of choice and more than 93% of patients of ovarian torsion have abnormal ultrasound findings.^[8] Findings depend on duration of ovarian torsion and degree of ischemia^[9] with the most common finding of ovarian enlargement,^[5] massive ovarian oedema,^[2] free fluid in cul-de-sac.^[10] Hyperechoic and hypoechoic areas may be seen which correspond to hemorrhage and edema respectively. Abnormal flow on colour doppler increases the likelihood of torsion^[5,8] but torsion may occur with incomplete vascular obstruction, therefore evidence of vascular flow does not rule out torsion with certainty.^[8]

Earlier the surgical intervention, better the outcome. As the proficiency of laparoscopic surgery has increased, laparoscopy has replaced laparotomy. The decision of conservation of the ovaries was taken on the basis of the age of the patient, desire to preserve future fertility, doppler flow of the ovaries (partial/ complete block), onset of symptoms to arrival of the patient, gangrenous/ nongangrenous appearance of the ovaries,^[11] pathological ovaries, peritonitis, systemic or local thromboembolism and reperfusion on detwisting.

The twisted ischemic adnexa is edematous and friable and liable to be traumatized. Detorsion was therefore performed with care and preferably with blunt non traumatic instruments. Detorsion should be performed and cystectomy alone should be avoided since removal of cyst may cause an undue removal of ovarian tissue inadvertently as in adnexal torsion there is no clear plane of separation between the cyst and its bed and the whole organ is highly

friable. Cystectomy can be performed later as an elective procedure. However, cystectomy should not be delayed for too long, as 5.4% of patients may have repeat torsion.^[12]

Since recurrence of torsion is rare except in profoundly enlarged ovaries, fixation of the ovary to pelvic wall (oophoropexy) is unwarranted. Laparoscopic plication of the utero-ovarian ligament was performed to prevent recurrent torsion in young patients in an attempt to shorten the excessively long ligament.

The preservation of ovarian function was studied in the 17 patients with ovarian conservation by performing ultrasound for follicular development, studying the condition of the ovary if subsequent surgery was performed for unrelated cause and successful ovum retrieval after controlled ovarian hyperstimulation in patients requiring IVF/ICSI subsequently.

RESULTS

In our experience of conservative management of twisted adnexa over the past 4 years (September 2004 to September 2008), 22 patients were treated out of which, 15 were non-pregnant and 7 pregnant.

We could conserve the adnexa in 77.2% cases ($P < 0.05$). Laparoscopic detorsion was performed in 11/15 (73.33%) of non-pregnant patients and adnexectomy done in 4 patients (26.66%) [Figures 1-3].

Among the 7 pregnant patients adnexa could be preserved in 6/7 (85.7%) of patients and only one patient required adnexectomy [Figure 4]. Laparotomy was required in 2/22 (9%) patients both of which were in late second trimester of pregnancy.

Out of our 22 patients, 5 were of controlled ovarian hyperstimulation, 2 had torsion during pregnancy and 3 immediately after ovum pick up. In all 5 cases detorsion was performed. Those with pregnancy continued well while in others, embryo freezing and subsequent frozen embryo transfer was done.

In one case (4.54%) we had recurrence of torsion [Table 1].

Table 1: Our experience

	No. of patients	Patients on COH	Detorsion	Adnexectomy	Laparoscopy	Laparotomy	Recurrence
Pregnant	7	2	6 (85.7)	1	5	2 (second trimester)	0
Non-pregnant	15	3	11 (73.3)	4	15	0	1
Total	22	5	17 (77.2)	5 (22.7)	20	2	1

Values in parenthesis are in percentages

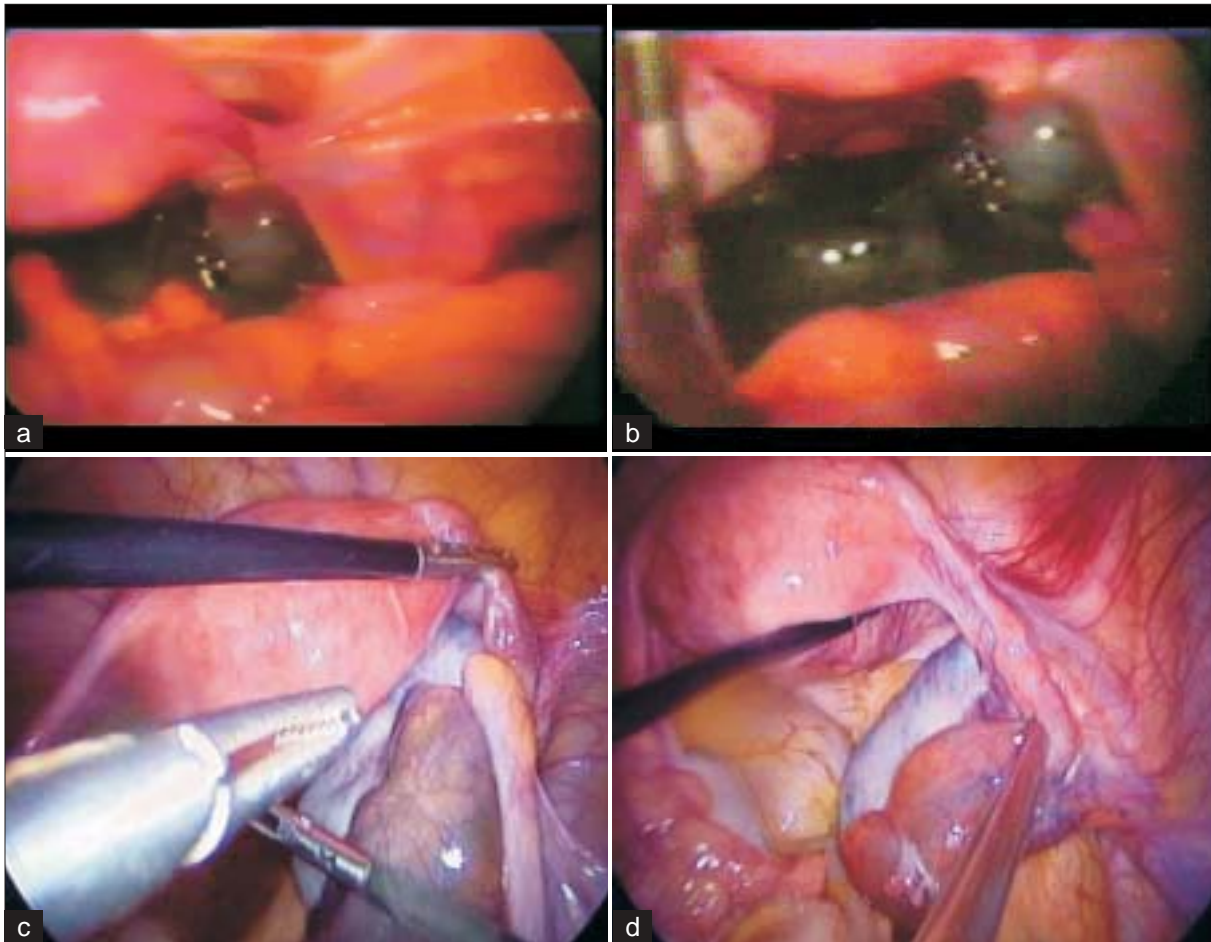


Figure 1: Acute torsion: Adnexa conserved. a) Preop: Acute torsion with black haemorrhagic adnexa; b) After detorsion with preservation of adnexa colour may not improve immediately; c) Preop: Acute torsion- oedematous tubes; d) After detorsion – Tubal swelling disappeared and colour back to normal

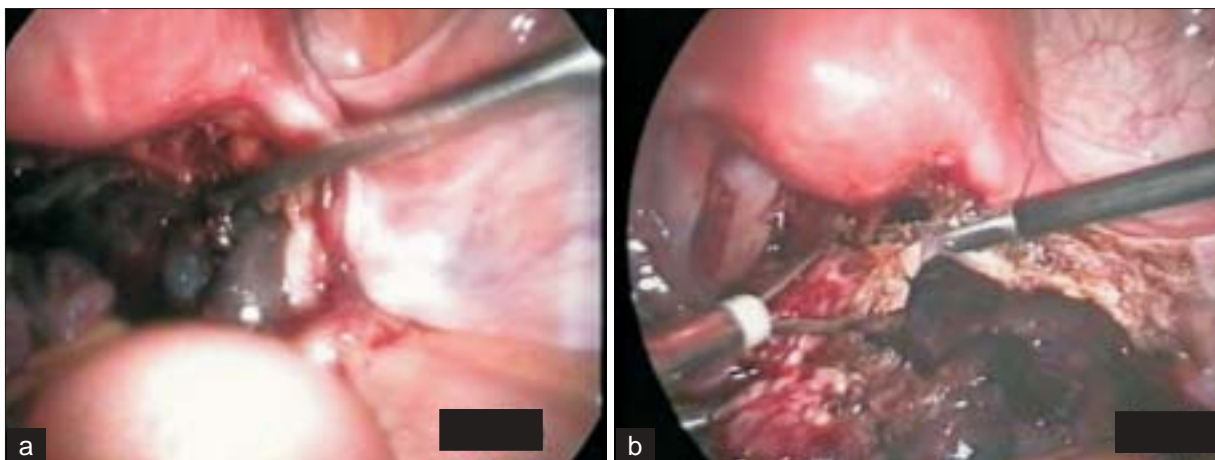


Figure 2: Chronic torsion: Not able to conserve adnexa. a) Preop: Chronic torsion – Adnexa discoloured, adherent to lateral pelvic walls; b) Adnexectomy done

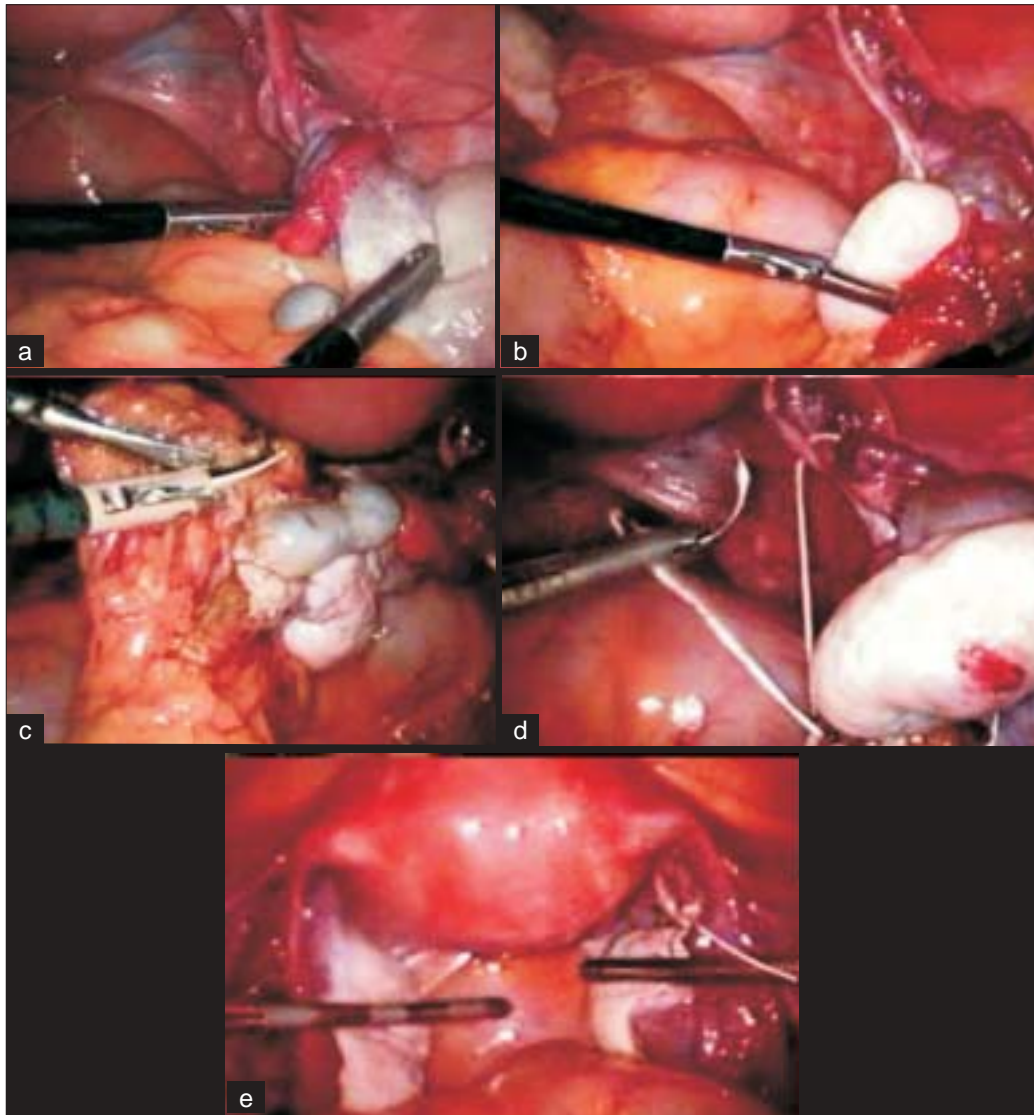


Figure 3: Chronic torsion: Adnexa conserved. a) Pre op: Chronic partial torsion, notice the lengthening of ligament; b) Detorsion done; c) Omental adhesions cut; d) Oopexy done to avoid recurrence; e) End result

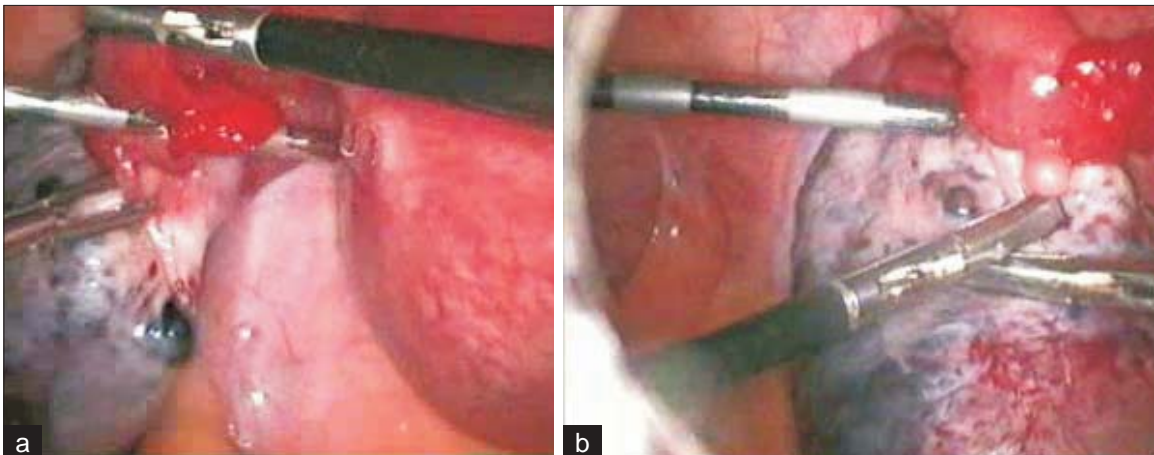


Figure 4: Adnexal torsion during pregnancy. a) Pre op: Torsion during pregnancy; b) Detorsion done and adnexa deposited back in pouch of douglas below gravid uterus gently to avoid retorsion

We followed the 17 patients with ovarian conservation with ultrasound for follicular development. 88.23% of the patients showed ovarian preservation in the form of follicular development on sonography. Two patients underwent subsequent surgery for unrelated cause and the ovaries were found to be healthy in appearance. Three patients were taken for controlled ovarian hyperstimulation and successful ovum retrieval could be done [Table 2]. Our study results are comparable with the other international studies [Table 3]

DISCUSSION

Adnexal torsion is rarely bilateral and more common on right side,^[13,5] perhaps because the sigmoid colon leaves limited space on left for adnexal mobility.^[4] Torsion occurs more commonly in young women with greatest incidence in 20-30 years age group.^[8]

Ovarian enlargement, adnexal masses, ovulation induction and pregnancy are most common predisposing factors for ovarian torsion, and exact mechanism of torsion varies according to its cause. Ovarian enlargement of any etiology predisposes the adnexa to torsion, however normal ovaries undergo torsion especially in pre-pubescent females.^[2] Because of the anatomy of broad ligament, both the ovaries (or adnexal masses) and the fallopian tubes are usually involved in the torsion. It is uncommon for these structures to be involved in isolation. If the rotation is partial or intermittent; the venous and lymphatic congestion may subside quickly, along with symptoms. If the rotation is complete and prolonged, venous and arterial thrombosis occurs ultimately causing adnexal infarction.^[6]

The diagnosis of twisted adnexa is based on awareness of the relevant risk factors, the clinical parameters and a high index of suspicion.

Until a decade ago, the standard approach to twisted adnexa was salpingo-oophorectomy^[19] but in 1989, Mage *et al.* proved that the detorsion and preservation of adnexa is an alternative mode of treatment^[14,15] and ever since it became the standard of care by many, replacing excision of adnexa.

The advantages of ovarian preservation are clear as adnexal torsion occurs most often in adolescent girls and women of childbearing age. Detorsion of adnexa helps to preserve ovarian function and maintain fertility. It reduces the risk of premature ovarian failure and the ensuing complications. After detorsion, even if ovarian masses look hemorrhagic and friable, ovarian function has been

Table 2: Preservation of ovarian function

Diagnostic means	No. of patients	Percentage
Ultrasound	15/17	88.23 ($P < 0.05$)
Subsequent surgery	2/2	100
IVF	3/3	100

Table 3: Detorsion of twisted adnexa and subsequent ovarian function: A review of literature

Study	No. of patients	Laparoscopy	Laparotomy	Subsequent ovarian function	%
Mage <i>et al.</i> 1989 ^[14]	27	22	5	16/17	94
Levy <i>et al.</i> 1995 ^[15]	3	3	-	3/3	100
Shalev <i>et al.</i> 1995 ^[16]	58	58	-	49/52	94
Pansky <i>et al.</i> 2000 ^[17]	8	8	-	7/8	88
Gabriel <i>et al.</i> 2003 ^[18]	102	67	35	85/92	91
Our study 2004-2008	17	16	1	15/17	88.23

found to be preserved, as shown by follicular development on ultrasound, subsequent unrelated laparotomy and fertilization at IVF.

There is theoretical risk of peritonitis and sepsis on detorsion especially if tissue have undergone gangrene. The risk of SIRS after detorsion due to reperfusion injury has also been described due to toxins liberated during reperfusion. The dislodged emboli may cause pulmonary thrombosis. The risk of subsequent torsion in the untwisted adnexa is also described.

Timely diagnosis and intervention can make the difference between ovarian loss and salvage- an outcome of great importance in population of reproductive age females. Laparoscopy with its many benefits proves to be superior to laparotomy.

REFERENCES

- Mancuso A, Broccio G, Angio LG, Pirri V. Adnexal torsion in pregnancy. *Acta Obstet Gynecol Scand* 1997;76:83-4.
- Coleman BG. Transvaginal sonography of adnexal masses. *Radiol Clin North Am* 1992;30:677-91.
- Gorkemli H, Camus M, Clasen K. Adnexal torsion after gonadotrophin ovulation induction for IVF or ICSI and its conservative treatment. *Arch Gynecol Obstet* 2002;267:4-6.
- Nichols DH, Julian PJ. Torsion of the adnexa. *Clin Obstet Gynecol* 1985;28:375-80.
- Albayram F, Hamper UM. Ovarian and adnexal torsion: spectrum of sonographic findings with pathologic correlation. *J Ultrasound Med* 2001;20:1083-9.
- Warner MA, Fleischer AC, Edell SL, Thieme GA, Bundy AL, Kurtz AB, *et al.* Uterine adnexal torsion: sonographic findings. *Radiology* 1985;154:773-5.

7. Burnett LS. Gynecological causes of the acute abdomen. *Surg Clin North Am* 1988;68:385-98.
8. Houry D, Abbott JT. Ovarian torsion: A fifteen year review. *Ann Emerg Med* 2001;38:156-9.
9. Webb EM, Green GE, Scoutt LM. Adnexal mass with pelvic pain. *Radiol Clin North Am* 2004;42:329-48.
10. Cappell MS, Friedel D. Abdominal pain during pregnancy. *Gastroenterol Clin North Am* 2003;32:1-58.
11. Mage G, Canis M, Manhes H, Pouly JL, Bruhat MA. Laparoscopic management of adnexal torsion: A review of 35 cases. *J Reprod Med* 1989;34:520-4.
12. Wagaman R, Williams RS. Conservative therapy for adnexal torsion: A case report. *J Reprod Med* 1990;35:833-4.
13. Hibbard LT. Adnexal torsion. *Am J Obstet Gynecol* 1985;152:456-61.
14. Mage G, Canis M, Manhes H, Pouly JL, Bruhat MA. Laparoscopic management of adnexal torsion, a review of 35 cases. *J Reprod Med* 1989;34:520-4.
15. Levy T, Dicker D, Shalev J, Dekel A, Farhi J, Peleg D, *et al.* Laparoscopic unwinding of hyperstimulated ischaemic ovaries during the second trimester of pregnancy. *Hum Reprod* 1995;10:1478-80.
16. Shalev E, Bustan M, Yarom I, Peleg D. The recovery of ovarian after laparoscopic detorsion. *Hum Reprod* 1995;10:2965-6.
17. Pansky M, Abargil A, Dreazen E, Golan A, Bukovsky I, Herman A. Conservative management of adnexal torsion in premenarchal girls. *J Am Assoc Gynecol Laparosc* 2000;7:121-4.
18. Oelsner G, Cohen SB, Soriano D, Admon D, Mashiach S, Carp H. Minimal surgery for the twisted ischaemic adnexa can preserve ovarian function. *Hum Reprod* 2003;18:2599-602.
19. Rapkin, A.J. Pelvic pain and dysmenorrhoea. In: Berek, J.S.(ed). *Novaks gynecology*. Williams and Wilkins; Baltimore. MD: 1996. p. 404.

Source of Support: Nil, **Conflict of Interest:** None.