

Successful Intra-Arterial Chemotherapy for Extramammary Paget's Disease of the Axilla in a Patient with Parkinson's Disease

Bruno Damascelli · Vladimira Ticha

Received: 13 October 2009 / Accepted: 8 December 2009 / Published online: 31 December 2009
© The Author(s) 2009. This article is published with open access at Springerlink.com

Abstract Extramammary Paget's disease (EMPD) is a rare intraepithelial neoplasm occurring less frequently in men and even more rarely in the axilla. A 59-year-old man with severe Parkinson's disease presented with axillary EMPD. The neurological comorbidity made treatment of the EMPD problematical and prompted us to propose locoregional intra-arterial chemotherapy in single short sessions. Two innovative chemotherapeutic macrocomplexes were used: doxorubicin incorporated in large liposomes and the taxane paclitaxel incorporated in albumin nanoparticles. A therapeutic response was seen right from the first treatment and was macroscopically close to complete after four cycles. Five months after the end of treatment the patient had minimal visible disease and had enjoyed a distinct improvement in quality of life, with no noteworthy complications related to the intra-arterial chemotherapy with percutaneous transfemoral catheterization.

Keywords Extramammary Paget's disease · Intra-arterial chemotherapy · Liposomal doxorubicin · Paclitaxel-albumin nanoparticles

Introduction

Extramammary Paget's disease (EMPD) is a somewhat rare [1], initially intraepithelial neoplasm that grows slowly but can become infiltrating and develop into a metastasizing adenocarcinoma [2]. EMPD can occur in various parts of the body, especially in those where the skin is rich in apocrine and eccrine glands [3, 4]. The most common treatment is surgical excision but the disease tends to recur very easily, and in a certain percentage of cases (12%) it is associated with a primary malignancy [2]. This neoplasm has recently gained more attention, thanks to the progress in diagnostic techniques and the application of new treatment methods [5, 6].

Case Report

A 59-year-old man presented with an extensive cutaneous lesion of the right axilla with symptoms of pruritus, irritation, burning sensation, and pain. His clinical history was significant for a finding of scoliosis at 18 years, appendectomy at 48 years, thyroidectomy due to colloid-cystic goiter at 57 years, and a diagnosis of progressive Parkinson's disease at 58 years, currently under treatment with levodopa and catechol-*O*-methyltransferase inhibitors, with marginal improvement. A partially ulcerated exophytic lesion with irregular margins, reddish in color, with white plaques, involved an area of 49 cm² in the right axilla (Fig. 1A). The patient's inability to attend to personal hygiene and the massive oozing and unpleasant odor and symptoms prompted his family, who had initially underestimated the cutaneous lesion, to seek treatment. The patient refused surgery but was persuaded to agree to biopsy (Fig. 1B, C). Radiotherapy, laser treatment, systemic chemotherapy, and

B. Damascelli (✉)
Department of Radiology and Diagnostic Imaging 2,
Istituto Nazionale per lo studio e la cura dei Tumori,
Via Venezian 1, 20133 Milan, Italy
e-mail: bruno.damascelli@istitutotumori.mi.it;
bruno.damascelli@fastwebnet.it

V. Ticha
Department of Radiology, Ospedale S. Carlo Borromeo,
Via Pio II 3, 20153 Milan, Italy

topical cytostatic chemotherapy were considered and proposed but proved impracticable. There was no evidence of axillary lymphadenopathy and physical examination of the chest was normal. CT of the thorax, abdomen, and pelvis and complete blood tests, including tumor markers, were performed to rule out an associated primary malignancy. All these tests were normal. The authors, who were consulted because of their experience in locoregional treatments, suggested intra-arterial chemotherapy with liposomal doxorubicin (Myocet) and paclitaxel in albumin nanoparticles (Abraxane).

Starting from January 2009, angiography (Fig. 1D) via transfemoral catheterization of the right axillary artery (5-Fr Envoy-H1 catheter; Cordis-Johnson&Johnson, Miami, FL, USA) was carried out under sedation, and treatment was given in four successive cycles at 4-week intervals. For each treatment cycle 200 mg of Abraxane (American BioScience, Inc., Los Angeles, CA, USA) and 80 mg of Myocet (Cephalon France, Maisons Alfort, France) were used. Each drug was diluted in 200 ml of normal saline and infused over 15 min. Counterpressure a little below the maximum arterial pressure was applied by sphygmomanometer to the

humeral artery to reduce distal escape of drugs. After each cycle therapeutic response was evaluated visually and documented photographically and by angiography before injection of the drugs (Fig. 2A–F). A complete blood count was done weekly.

Blood counts always remained within normal limits. Among the side effects were alopecia, transient general weakness, and paresthesias of the right arm. Complete blood counts showed no bone marrow depression requiring correction with growth factors. An objective response with minimal residual disease of the skin occurred 4 months from the start of treatment and was maintained for the 5 months that passed from the end of treatment to the time of writing (Fig. 3).

Discussion

EMPD of the axilla can be treated in various ways, which are rarely conclusive, either singly or in combination, because of the high frequency of recurrence [6]. The 5-year survival rate without treatment is 59%. Survival falls to

Fig. 1 Paget's disease of the right axilla. **A** Photograph of the patient upon presentation. Note the copious oozing on the surface of the neoplasm. **B, C** Histology obtained with excisional biopsy. "The skin shows an intraepidermal proliferation of large, atypical epithelial elements, with copious clear cytoplasm and a vesiculate nucleus, positive for cytokeratin and PAS and negative for Melan-A, HMB-45, and S-100." **D** Transfemoral angiogram of the axillary artery. The Paget's disease is intensely vascularized, with a capillary nest, and without evidence of early venous drainage

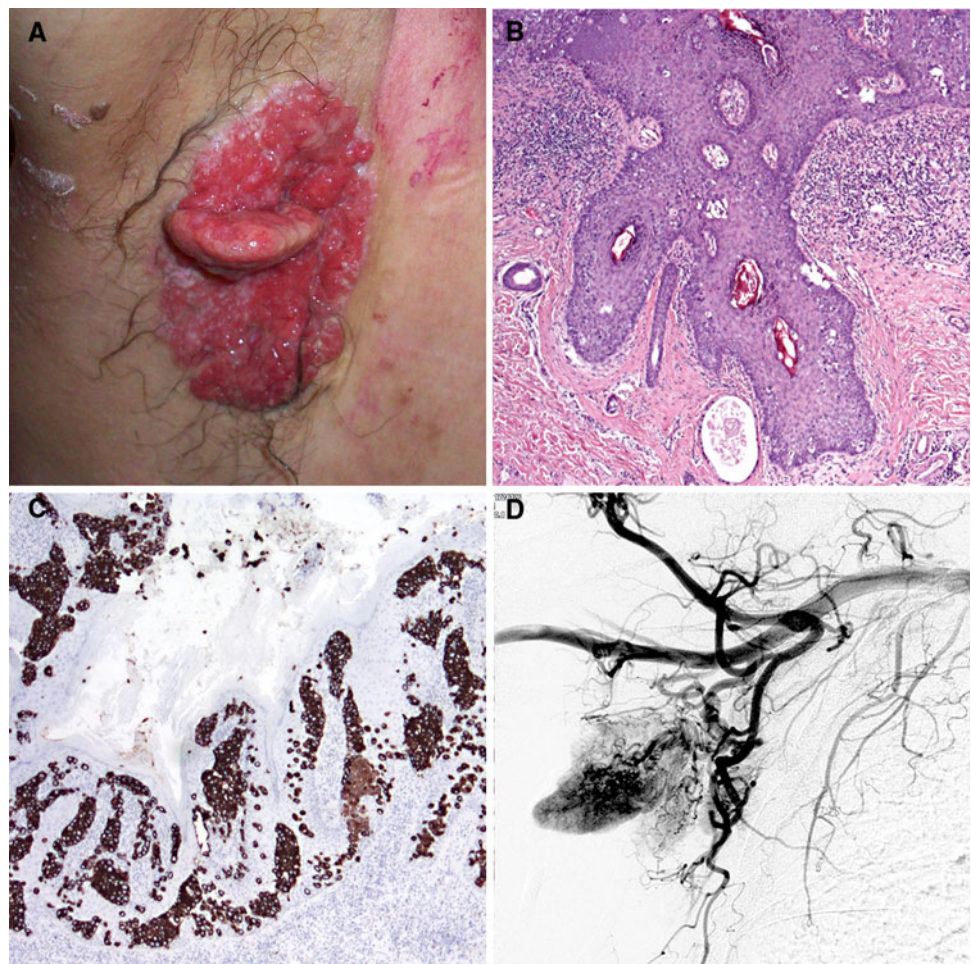
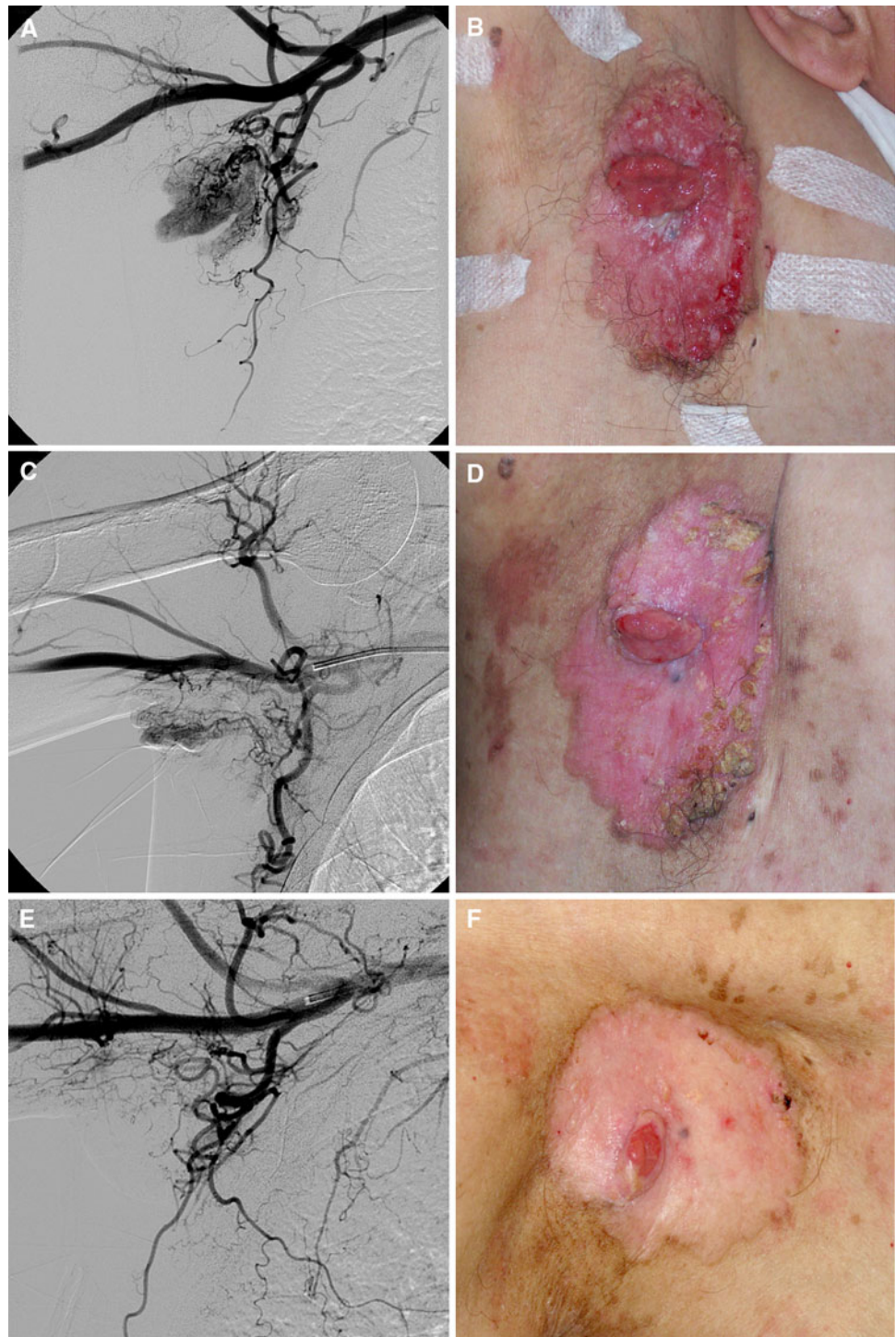


Fig. 2 Course of objective response during intra-arterial treatment of extramammary Paget's disease of the right axilla with Myocet-Abraxane. After the second treatment cycle: reduction in pathological vascularization at angiography (A) and reduced size of the skin lesion (B). C, D After the third cycle. E, F After the fourth cycle



25–40% if EMPD is associated with an underlying breast carcinoma at presentation [7]. The patient treated by the authors had Parkinson's disease with frequent tremors, rigidity, and postural instability, which made him difficult to manage from both a practical and a psychological point of view. Locoregional chemotherapy—to the authors' knowledge, never used before to treat EMPD—was

considered feasible because of the high dose intensity that can be achieved in single treatments, each of brief duration, which can be given under sedation.

The active principles were chosen on the basis of the similarity of EMPD to breast adenocarcinoma [7, 8], for which doxorubicin and taxanes are recognized to be effective. It was expected that greater tumor exposure

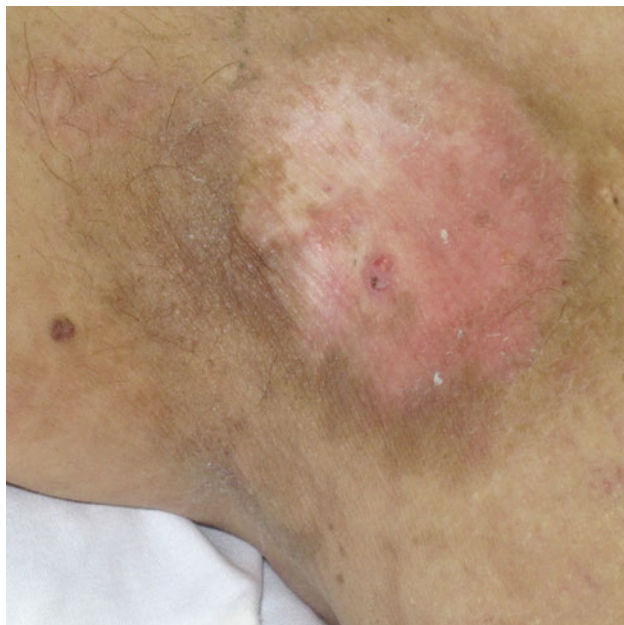

Fig. 3 Further improvement in appearance of the skin lesion 5 months after the end of treatment

could be achieved through the use of macrocomplexes—liposomes and albumin nanoparticles—measuring 150–200 nm in diameter, because of the tumor's substantial vascular network. In this setting, the so-called enhanced permeability and retention (EPR) effect occurs, whereby macrocomplexes pass through the discontinuous endothelium of tumor capillaries and maintain prolonged contact with the tumor cells because of the lack of effective lymphatic drainage toward the general circulation [9, 10]. This leads to high tumor exposure to the drugs with reduced systemic exposure. Liposome-encapsulated doxorubicin differs from conventional doxorubicin in its pharmacokinetic and therapeutic behavior. In practice, liposomes can be considered as a transport system which allows release of doxorubicin where greater vascular permeability occurs. Paclitaxel in albumin nanoparticles exploits the same transport mechanism, with the added advantage that albumin is used for tumor growth, representing the main source of energy for tumor cells. Once the cell membrane has been

crossed, the taxane is released, interfering with the tubular apparatus and causing cell death.

In the present case, treatment was not associated with major complications related to percutaneous catheterization or drug toxicity, ensuring a distinct improvement in the patient's quality of life. This objective result could suggest consideration of intra-arterial chemotherapy as a neoadjuvant treatment for EMPD before surgical resection or laser vaporization or concurrently with radiotherapy.

Open Access This article is distributed under the terms of the Creative Commons Attribution Noncommercial License which permits any noncommercial use, distribution, and reproduction in any medium, provided the original author(s) and source are credited.

References

1. Coppens M, Colpaert C, Van Damme P et al (1994) Extramammary Paget's disease of the axilla. *Eur J Obstet-Gynecol* 54:140–142
2. Chanda J (1985) Extramammary Paget's disease: prognosis and relationship to internal malignancy. *J Am Acad Dermatol* 13:1009–1014
3. Imai AS, Nitto H, Imai R (1981) Axillary Paget's disease. *J Dermatol* 8:245–252
4. Urabe A, Matsukuma A, Shimizu N et al (1990) Extramammary Paget's disease: comparative histopathologic studies of intraductal carcinoma of the breast and apocrine adenocarcinoma. *J Cutan Patol* 17:257–265
5. Chagpar AB, Heim K, Carron KR, Sewell C (2007) Extramammary Paget's disease of the axilla: an unusual case. *Breast J* 13:291–293
6. Zollo JD, Zeitouni NC (2000) The Roswell Park Cancer Institute experience with extramammary Paget's disease. *Br J Dermatol* 142:59–65
7. Kanitakis J (2007) Mammary and extramammary Paget's disease. *JEADV* 21:581–590
8. Castelli E, Wollina U, Anzarone A et al (2002) Extramammary Paget disease of the axilla associated with comedo-like apocrine carcinoma in situ. *Am J Dermatopathol* 24:351–357
9. Damascelli B, Patelli G, Ticha V et al (2007) Feasibility and efficacy of percutaneous transcatheter intraarterial chemotherapy with paclitaxel in albumin nanoparticles for advanced squamous-cell carcinoma of the oral cavity, oropharynx, and hypopharynx. *J Vasc Interv Radiol* 18:1395–1403
10. Andres R, Garcia-Bueno JM, Modejll CMA (2005) Phase II multicenter study of non-pegylated liposomal doxorubicin and docetaxel as neoadjuvant chemotherapy in patients with stage II-III inflammatory breast cancer. *J Clin Oncol* 23:798