

This is an Open Access article licensed under the terms of the Creative Commons Attribution-NonCommercial-NoDerivs 3.0 License (www.karger.com/OA-license), applicable to the online version of the article only. Distribution for non-commercial purposes only.

A Rare Presentation of Conjunctival Myxoma with Pain and Redness: Case Report and Literature Review

Yu-Po Chen^a Swei Hsiung Tsung^b Tommy Yet-Min Lin^{c, d}

^aNorthwestern University, Feinberg School of Medicine, Chicago, Ill., USA;

^bDepartment of Pathology, St. Mary's Hospital, and ^cWu-Fu Eye Clinic, Lotung, and ^dDepartment of Ophthalmology, Taipei Medical University, Taipei, Taiwan, ROC

Key Words

Conjunctival neoplasms, pathology · Conjunctival neoplasms, surgery · Myxoma, pathology

Abstract

Background: Conjunctival myxoma is a type of rare, benign tumor of mesenchymal cells, with fewer than 30 reported cases in the English literature. It is mostly an isolated occurrence but can sometimes be associated with systemic diseases such as Carney complex or Zollinger-Ellison syndrome. It is necessary in clinical practice to differentiate it from other similar lesions, such as amelanotic nevus, lymphangioma, myxoid liposarcoma, spindle-cell lipoma, myxoid neurofibroma, and rhabdomyosarcoma.

Case Presentation: The usual presentation of conjunctival myxoma is a translucent, well-circumscribed, and painless conjunctival mass, but in this report we discuss an unusual case of conjunctival myxoma in a 47-year-old Taiwanese woman who presented initially with pain and redness. This atypical presentation complicated the diagnosis and the management at first. Surgical excision of the mass was performed. The mass was found to be a conjunctival myxoma. The patient subsequently underwent extensive evaluation but was found not to have any systemic diseases with known association with conjunctival myxoma.

Conclusions: In summary, we present a case of conjunctival myxoma in a 47-year-old Taiwanese woman. The initial presentation with pain and redness was atypical for conjunctival myxoma. The lesion was successfully managed with complete excisional biopsy.

Introduction

Myxoma is a type of benign tumor derived from primitive mesenchymal cells. It is the most common primary tumor found in the heart [1]. Myxoma can also arise in other locations, including bone, skin, skeletal muscles, gastrointestinal system, and genitourinary systems. In the eye, myxomas have been found to involve the orbit, the cornea, and the conjunctiva [2, 3]. Conjunctival myxoma is extremely rare, representing only one case among the 1,643 conjunctival lesions surveyed in a study (<0.001%) [4]. We have found only 26 cases reported in the English literature. The typical presentation of conjunctival myxoma is a painless, circumscribed, rubbery, translucent/solid, yellow-pink mass or cyst [5–8]. Diseases that may resemble conjunctival myxoma include amelanotic nevus, lymphangioma, myxoid liposarcoma, spindle-cell lipoma, myxoid neurofibroma, and rhabdomyosarcoma [9]. In this report, we describe a case of conjunctival myxoma in a 47-year-old Taiwanese woman with an atypical initial presentation of pain and redness.

Case Presentation

A 47-year-old Taiwanese woman had a 3-year history of redness in her left eye prior to the initial visit. During these 3 years, she had been using unspecified kinds of ophthalmic drops sporadically. One month prior to the visit, she began to experience pain and irritation in her left eye and was diagnosed with allergic conjunctivitis and treated with cromolyn at another clinic. Her symptoms persisted for one month with no improvement from the treatment. Her past medical history was only significant for hypertension; she denied any ocular trauma in the past.

During the initial visit at our clinic, her visual acuity with correction was 1.0 in both eyes. A 6 × 4 mm mass with surrounding hyperemia was noted in the left eye, situated on the bulbar conjunctiva and 0.5 mm temporal to the limbus at 3 o'clock (fig. 1). No proptosis was observed. The rest of the ophthalmologic examination was unremarkable. The patient had no other history of ocular pathology. The initial impression was scleritis, given the erythema of the left eye conjunctiva. Topical steroid was prescribed; the patient was also referred to a rheumatologist for further workup. She returned one month later with no improvement in her symptom. The result of an autoimmune panel was within normal limit (erythrocyte sedimentation rate, ESR = 12 mm/h, normal: 0–28.5; IgA = 191 mg/dl, normal: 70–360; antinuclear antibody, ANA = negative, normal: negative; rheumatoid factor, RF <20 U/ml, normal: <20 U/ml). By the time of her second visit, the color of the mass had turned salmon-pink. The patient received an ultrasound B scan to rule out intraocular tumor, but it showed no mass. Since the mass persisted in spite of topical steroid treatment and a negative rheumatological workup, malignant lymphoma was suspected. The differential diagnosis also included amelanotic nevus, dermoid, myxoma, and lipoma. The lesion was subsequently excised and sent for histopathological study.

The specimen consisted of a pinkish tan and soft tissue fragment, measuring 9 × 6 × 4 mm. Histopathological examination revealed a benign tumor composed of spindle cells embedded in a myxomatous stroma. No nuclear atypia was seen (fig. 2). The tumor cells stained positive for vimentin (fig. 3). The findings were consistent with conjunctival myxoma. The patient returned after one month post-excision for follow-up and no longer complained of pain and redness in her left eye. The patient also received extensive cardiac and endocrine workup. Her echocardiogram showed no mass in the heart. The endocrine workup was only remarkable for a mildly depressed T3 level (0.75 ng/ml, normal: 0.8–2); TSH, T4, estradiol, and FSH were all within normal limits (T4 = 8.47 µg/dl, normal: 5.1–14.1; TSH = 1.95 µIU/ml, normal: 0.27–4.2; estradiol = 13.20 pg/ml, normal: <54.7 pg/ml; FSH = 100.40 mIU/ml, normal: 25.8–134.8). She had no atypical dermatological findings.

Discussion

Conjunctival myxoma is rare, with only 26 cases reported so far in the English literature ([table 1](#)). It occurs equally frequently in both sexes; the ages of the patients ranged from 11 to 80 years, with a median of 50 [5–8]. Chen et al. [6] reported the youngest case in an 11-year-old boy; the other cases were in the range of 18–80 years of age. The typical presentation is a translucent, well-circumscribed conjunctival mass, most often at the bulbar conjunctiva. Whereas the masses were painless in the previously reported cases, the patient in this report presented with pain and redness that resembled scleritis; in addition, the margin of the mass was more diffuse than in previously reported cases. It is possible that these symptoms resulted from the medication used by the patient prior to her initial visit, rather than from an actual variation in the presentation of conjunctival myxoma. To our knowledge, only one paper published in Japanese had ocular pain as the initial sign of conjunctival myxoma; no redness was noted in that case, however, unlike in our case [10].

According to a detailed study and literature review by Demirci et al. [5], conjunctival myxoma consists of scattered, relatively small stellate- and spindle-shaped cells embedded in myxoid matrix along with reticulin fibers, sparse vascular structures, and mature collagen fibers. Hyaluronic acid, along with some chondroitin sulfate, constituted the matrix. Conjunctival myxomas stain positive with Alcian blue and vimentin, and negative with S-100 protein, desmin, and smooth muscle-specific actin [8].

It is important to differentiate conjunctival myxoma from other similar lesions, which include nevus, amelanotic melanoma, lymphangioma, myxoid liposarcoma, spindle-cell lipoma, myxoid neurofibroma, and rhabdomyosarcoma. Compared to nevus and lymphangioma, myxoma does not have cysts [9]. In addition, lymphangioma and amelanotic nevus are highly vascular. Liposarcoma is similar to myxoma in being highly mucoid; however, myxoma does not contain pleomorphic multivacuolated lipoblasts or signet ring cells. Spindle-cell lipoma tends to be more yellowish and contains mature fat cells and signet ring cells when compared to myxoma [11].

The recommended management for conjunctival myxoma is complete excisional biopsy [5]. No cases of recurrence or malignant transformation have been reported.

While most reported cases of conjunctival myxoma were isolated occurrences, at least two had systemic involvement and presented as a component of Carney complex or in association with Zollinger-Ellison syndrome [12, 13]. Carney complex is an autosomal dominant syndrome first described in the mid-1980s. It can present with multiple endocrine tumors involving the adrenal, pituitary, and thyroid glands, or with Cushing syndrome; it is also associated with many other non-endocrine tumors, such as cardiac myxomas, breast myxomas, testicular tumors, melanotic schwannoma, and abnormal pigmentation. The Carney complex gene 1 had been identified as the regulatory subunit 1A of protein kinase A (PRKAR1A) located at 17q22–24 [14]. In addition to Carney complex, myxoma may also be a component of the Mazabraud syndrome (bone fibrous dysplasia and intramuscular myxoma) or of the McCune-Albright syndrome (café au lait spots and multinodular goiter) [5]. As a result of these associations, systemic evaluation of a patient with conjunctival myxoma, which includes cardiac echocardiography and analysis of hormone levels, is warranted.

In summary, we present a case of conjunctival myxoma in a 47-year-old Taiwanese woman. The diagnosis was somewhat complicated by the atypical presentation with pain and redness, but the histopathological and immunochemical findings were consistent with those of conjunctival myxoma. The lesion was successfully managed with complete excisional biopsy.

Disclosure Statement

The authors have no conflicts of interest to declare.

Table 1. The list of reported conjunctival myxoma cases published in English, adapted from Demirci et al. [5], updated with cases reported after the original publication

Source	Age, years/ sex	Systemic disease	Eye	Symptoms	Clinical features	Color	Conjunctival site	Conjunctival location	Outcome
Ffooks (1962)	72/M	None	OD	Conjunctival mass	Rubbery, circumscribed subconjunctival mass	White	Limbus	Superior	Stable
Doughman and Wenk (1970)	49/F	None	OD	Conjunctival mass	Rubbery, circumscribed subconjunctival mass	Yellow	Limbus	Temporal	Stable
Stafford (1971)	54/F	None	OD	Conjunctival cyst	Translucent, circumscribed subconjunctival mass	Pink	Limbus	Temporal	Stable
Patrinely and Green (1983)	50/F	None	OD	Conjunctival mass	Translucent, diffuse conjunctival mass	Yellow	Bulbar	Nasal	Stable
	53/F	None	OS	Conjunctival cyst	Solid, circumscribed conjunctival mass	Yellow	Bulbar	Temporal	Stable
	18/F	None	OS	Conjunctival mass	Semitranslucent, circumscribed conjunctival mass	Pink	Bulbar	Superior	Stable
	42/F	None	OD	Conjunctival mass	Translucent, circumscribed subconjunctival mass	Yellow	Limbus	Temporal	Stable
Mottow-Lippa et al. (1983)	54/M	None	OS	Conjunctival mass	Translucent, circumscribed subconjunctival mass	Pink	Limbus	Temporal	Stable
Pe'er et al. (1984)	18/F	None	OD	Conjunctival mass	Translucent, circumscribed subconjunctival mass	Pink	Bulbar	Nasal	Stable
Pe'er and Hidayat (1986)	48/M	None	NA	Conjunctival cyst	Conjunctival cyst	Yellow	Fornix	Inferior	Stable
	61/M	None	NA	Conjunctival growth	Solid, circumscribed subconjunctival mass	NA	Bulbar	Temporal	Stable
	34/M	None	NA	Conjunctival cyst	Conjunctival cyst	Yellow	Bulbar	Temporal	Stable
	64/M	None	NA	Conjunctival mass	Conjunctival mass	Pink	Bulbar	Temporal	Stable
	33/F	None	NA	Conjunctival mass	Solid, circumscribed conjunctival mass	Pink	Bulbar	NA	Stable
	20/M	None	NA	Conjunctival cyst	Translucent, circumscribed conjunctival mass	Yellow	Limbus	Temporal	Stable
	50/M	None	NA	Conjunctival cyst	Translucent, circumscribed conjunctival mass	Yellow	Bulbar	Nasal	Stable
	50/F	None	NA	Conjunctival mass	Solid, circumscribed conjunctival mass	Pink	Bulbar	NA	Stable
	76/M	None	NA	Conjunctival cyst	Translucent, circumscribed conjunctival mass	NA	Limbus	Superior	Stable
65/F	None	NA	Conjunctival mass	Translucent, diffuse conjunctival mass	NA	Bulbar	Temporal	Stable	
Kennedy et al. (1987)	23/M	Carney complex	NA	Conjunctival mass	Translucent, circumscribed conjunctival mass	Yellow	Palpebral	Superior	Stable
Horie et al. (1995)	80/F	None	OS	Conjunctival mass	Solid, circumscribed conjunctival mass	NA	Bulbar	Nasal	Stable
Ramaesh et al. (2001)	36/M	Zollinger-Ellison syndrome and thickness of atrial septum	OD	Conjunctival swelling	Translucent, circumscribed conjunctival mass	Pink	Bulbar	Nasal	Stable
Demirci et al. (2006)	31/M	None	OS	Conjunctival swelling	Translucent, circumscribed conjunctival mass	Yellow-pink	Bulbar	Nasal	Stable
Chen et al. (2008)	11/M	None	OS	Conjunctival mass	Translucent, circumscribed conjunctival mass	Yellow-pink	Bulbar	Temporal	Stable
Arya et al. (2008)	64/F	None	OD	Conjunctival swelling	Translucent, circumscribed conjunctival mass	Yellow-pink	Bulbar	Superonasal	Stable
Kiliç et al. (2008)	45/F	None	OS	Conjunctival mass	Translucent, circumscribed conjunctival mass	Yellow-pink	Bulbar	Temporal	Stable

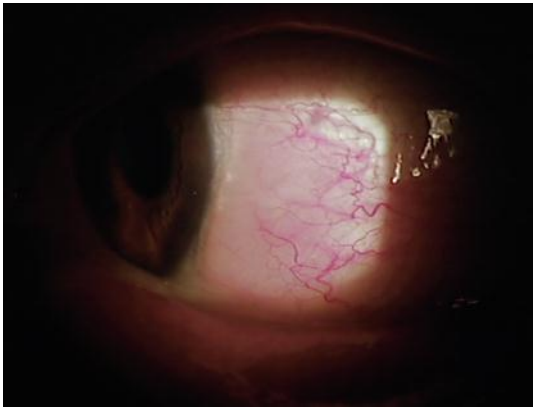


Fig. 1. A circumscribed mass in the temporal bulbar conjunctiva of the left eye, surrounded by region of hyperemia.

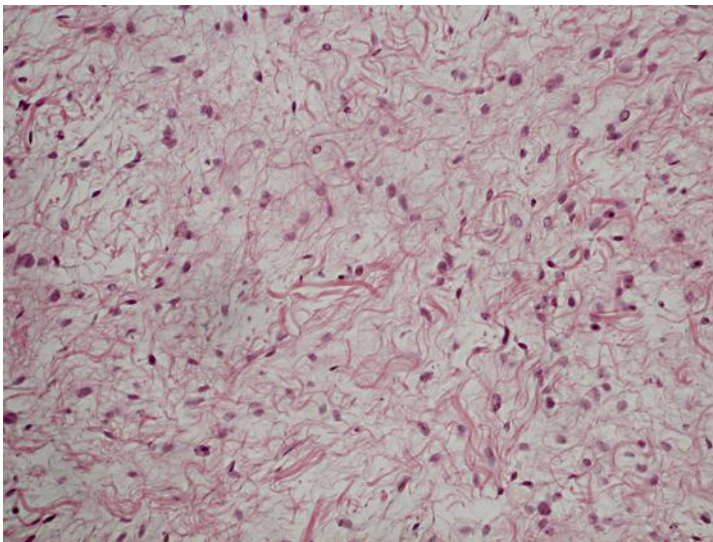


Fig. 2. Scattered spindle cells embedded in a myxomatous stroma (hematoxylin-eosin, original magnification $\times 200$).

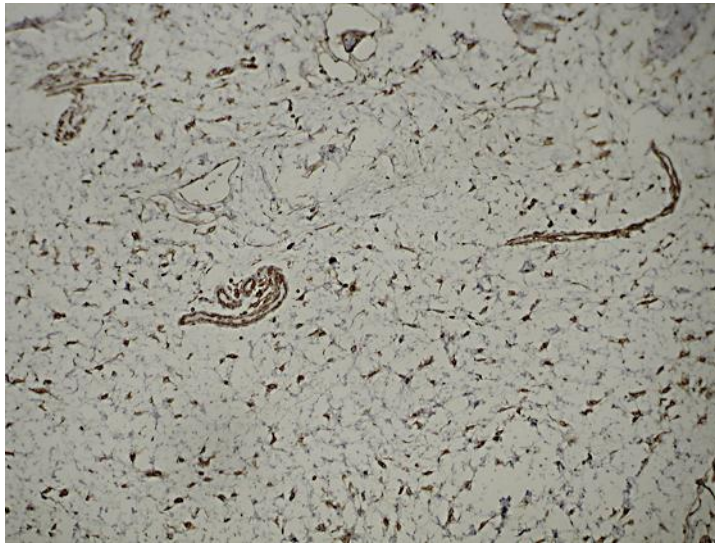


Fig. 3. Tumor cells staining positive for vimentin (immunoperoxidase, original magnification $\times 100$).

References

- 1 Bulkley BH, Hutchins GM: Atrial myxomas: a fifty year review. *Am Heart J* 1979;97:639–643.
- 2 Lieb WE, Goebel HH, Wallenfang T: Myxoma of the orbit: a clinicopathologic report. *Graefes Arch Clin Exp Ophthalmol* 1990;228:28–32.
- 3 Robinson JW, Brownstein S, Mintsoulis G: Corneal myxoma arising in a patient with repeated phototherapeutic keratectomies. *Cornea* 2006;25:1111–1114.
- 4 Shields CL, Demirci H, Karatza E, Shields JA: Clinical survey of 1,643 melanocytic and nonmelanocytic conjunctival tumors. *Ophthalmology* 2004;111:1747–1754.
- 5 Demirci H, Shields CL, Eagle RC, Shields JA: Report of a conjunctival myxoma case and review of the literature. *Arch Ophthalmol* 2006;124:735–738.
- 6 Chen CL, Tai MC, Chen JT, Chen CH, Jin JS, Lu DW: A rare case of conjunctival myxoma and a review of the literature. *Ophthalmologica* 2008;222:136–139.
- 7 Arya SK, Gupta H, Gupta S, Malik A, Samra SG, Sood S: Conjunctival myxoma in a 64-year-old patient. *Jpn J Ophthalmol* 2008;52:339–341.
- 8 Kiliç A, Kösem M, Demirok A, Cinal A, Yasar T: Conjunctival myxoma: a clinicopathologic report. *Ophthalmic Surg Lasers Imaging* 2008;39:514–516.
- 9 Shields JA, Shields CL: Myxoma, lipoma, and reticulohistiocytoma; in *Atlas of Eyelid and Conjunctival Tumors*. Philadelphia, PA, Lippincott Williams and Wilkins, 1999, pp 286–287.
- 10 Konari K, Suzuki J-I, Oyachi H, Ueno T, Nakagawa T: Ocular pain as the initial sign of conjunctival myxoma. *Jpn J Clin Ophthalmol* 1993;47:1361–1364.
- 11 Mottow-Lippa L, Tso MO, Sugar J: Conjunctival myxoma. A clinicopathologic study. *Ophthalmology* 1983;90:1452–1458.
- 12 Kennedy RH, Flanagan JC, Eagle RC Jr, Carney JA: The Carney complex with ocular signs suggestive of cardiac myxoma. *Am J Ophthalmol* 1991;111:699–702.
- 13 Ramaesh K, Wharton SB, Dhillon B: Conjunctival myxoma, Zollinger-Ellison syndrome and abnormal thickening of the inter-atrial septum: a case report and review of the literature. *Eye (Lond)* 2001;15:309–312.
- 14 Vezzosi D, Vignaux O, Dupin N, Bertherat J: Carney complex: Clinical and genetic 2010 update. *Ann Endocrinol (Paris)* 2010;71:486–493.