

Safety analysis of different intensities of elf-pemf in terms of apoptotic, inflammatory, and transcription factor NF-Kb expression levels in rat liver

Yasin Gokce¹, Ugur Seker², Merve Pekince Ozoner³

¹Department of Biophysics, Harran University School of Medicine, Sanliurfa, Turkiye; ²Department of Histology and Embryology, Mardin Artuklu University School of Medicine, Mardin, Turkiye; ³Department of Veterinary Histology and Embryology, School of Veterinary Medicine, Siirt University, Siirt, Turkiye

Abstract

Background and Aim: The purpose of this research was to ascertain how exposure to extremely low-frequency pulsed electromagnetic fields (ELF-PEMFs) at varying intensities affects apoptosis-related protein expression levels and liver morphology in rats.

Materials and Methods: In this experimental study, 40 Wistar albino rats were randomly divided into 4 groups, with 10 animals in each group: Control, Sham, 1 milli Tesla (1mT), and 5 mT groups. The control group did not expose any application during the experiment. Animals in the sham group were placed into the closed ELF-PEMF exposure environment, but the device was kept closed. The rats in the 1mT and 5mT groups were placed into a closed ELF-PEMF exposure environment, and the magnetic field application was applied 5 days a week for 4 hours a day for 8 weeks. At the end of the study, the animals were sacrificed, and their liver tissues were examined morphologically, and the expression levels of proteins related to apoptosis and inflammation in these tissues were analyzed.

Results: Our results indicated that ELF-PEMFs did not lead to any exact morphological alterations in the groups. Tissue apoptotic Bax and Caspase 3 expression levels in the 1mT and 5mT groups were similar ($p>0.05$) to the control group. Additionally, pro-inflammatory TNF- α and transcription factor NF- κ B in the 1mT and 5mT groups were similar ($p>0.05$) to each other and the control group.

Conclusion: It is feasible to conclude that neither the administration nor the exposure design of this study is changing the immunexpression of apoptosis-regulating protein expression levels or liver morphology exposed to ELF-PEMF in rats.

Keywords: Apoptosis; ELF-PEMF; inflammation; liver; NF- κ B.

Introduction

Magnetic fields (MFs) produced by electrical or electronic devices used in our surroundings and electrical power lines have frequency ranges of 50 Hz in a large portion of the world and 60 Hz in North America.^[1] The extremely low frequency (ELF) part of the electromagnetic spectrum is often defined as 0–300 Hz.^[2] Extremely low-frequency electromagnetic fields (ELF-EMFs) are unable to break chemical bonds or have thermal effects on tissue because of their low energy values. They are also known to interact with human tissues and cause a small amount of electrical currents to flow.^[3] Exposure to electromagnetic fields (EMFs) has become a necessary aspect of modern life, and it is expanding substantially as a result of growing needs and ongoing technological advancements. Because of this, a number of experimental and epidemiological studies that highlight the potential impacts of EMF exposure on biological systems have received international recognition.

The process of apoptosis via the elevation of intracellular reactive oxygen species (ROS) is considered to be the most likely mechanism explaining the anticancer effects of ELF-EMF. ROS, mainly from the mitochondria's electron transport chain during cell respiration, increase with dysfunction. Mitochondria, in the matrix (by MnSOD) or cytosol (by Cu/ZnSOD), are key sources of intracellular ROS during respiration. By devastating the equilibrium of the antioxidant defense system, overexpression of ROS results in oxidative stress, which damages the mitochondrial membrane and induces the release of cytochrome c.^[4] Ding et al.'s^[5] work showed that HL-60 leukemia cell lines could experience a potentiation of H₂O₂-induced apoptosis when exposed to 60 Hz, 5 milli Tesla (mT) ELF-EMF for a duration of 24 hours. A related study by Jian et al.^[6] demonstrated that human hepatoma cell lines pretreated with low-dose X-ray radiation experienced a substantial increase in the rate of apoptosis with intermittent exposure to EMF. Short-term exposure of the human acute monocytic leukemia cell line to pulsed EMF, as demonstrated by Kaszuba-Zwoinska et al.,^[7] markedly boosted the rate of apoptosis produced by colchicine and cyclophosphamide.

Notably, numerous additional research has placed a strong emphasis on ELF-EMF's anti-apoptotic properties in addition to its effects on ROS. A pretreatment of ELF-EMF exposure led to a 22% decrease in caspase 3-dependent apoptosis induced by anti-Fas therapy in Jurkat leukemic cell lines, according to Palumbo et al.^[8] Another study revealed that the anti-apoptotic effect of melatonin on HepG2 cell lines was totally eliminated after 42 hours of intermittent exposure to EMF.^[9] Brisdelli et al.^[10] also demonstrated that, in comparison to quercetin treatment alone, simultaneous treatment of K562 cell lines with ELF-EMF and

How to cite this article: Gokce Y, Seker U, Pekince Ozoner M. Safety analysis of different intensities of elf-pemf in terms of apoptotic, inflammatory, and transcription factor NF-Kb expression levels in rat liver. *Hepatology Forum* 2024; 5(4):178–183.

Received: February 13, 2024; **Revised:** March 04, 2024; **Accepted:** March 05, 2024; **Available online:** September 11, 2024

Corresponding author: Yasin Gokce; Harran Universitesi Tip Fakultesi, Biyofizik Anabilim Dalı, Sanliurfa, Turkiye

Phone: +90 530 223 82 78; **e-mail:** ygokce@harran.edu.tr



OPEN ACCESS
This work is licensed under a Creative Commons Attribution-NonCommercial 4.0 International License.

Hepatology Forum - Available online at www.hepatologyforum.org



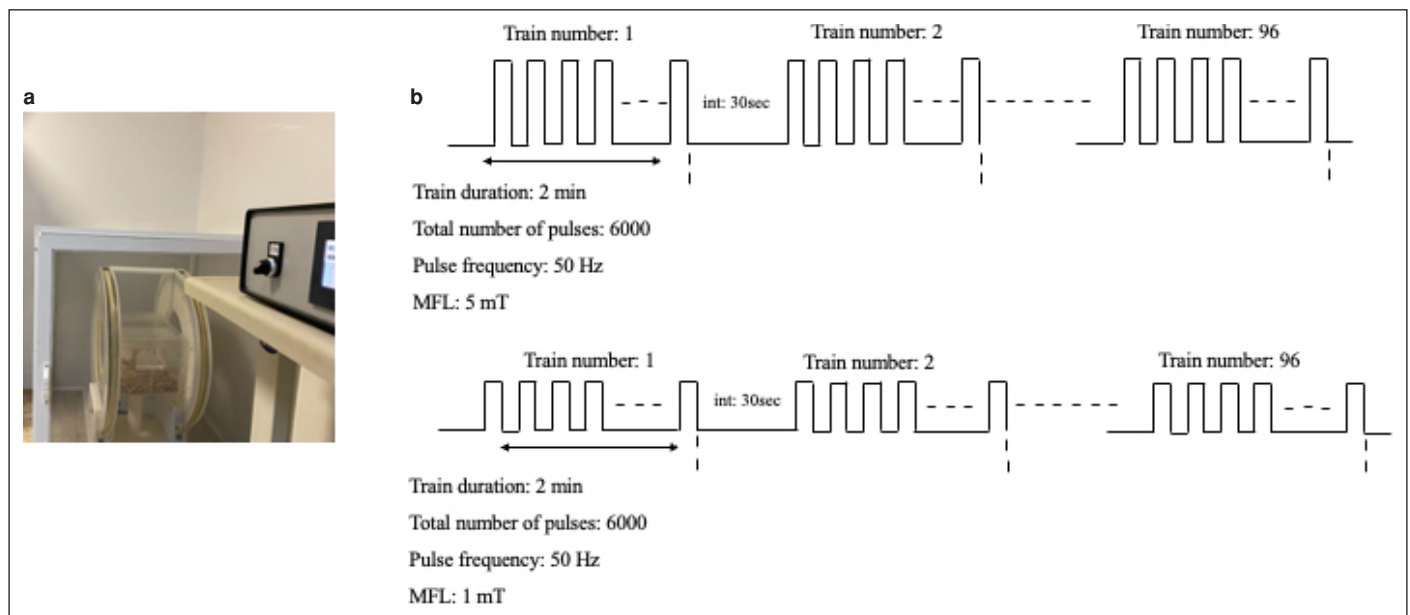


Figure 1. Pulsed magnetic field exposure system. (a) Signal generator and Helmholtz bobbin coils. (b) The pulse trains used in PMF application. Int: Interval.

quercetin markedly boosted the production of Bcl2. This reduction in effects was linked to a decrease in caspase 3 activity and an inhibition of the Bcl expression decrease that quercetin induced. Some research, however, indicates that exposure to ELF-EMF is not statistically significant.^[11,12] Some studies state that ELF-EMF has no consequences that indicate liver damage,^[13] while others report that it may cause effects such as necrosis, apoptosis, and inflammation in the liver.^[14,15] Therefore, the potential effects on liver morphology and apoptotic markers of long-term exposure to ELF-EMF were investigated in this work.

Materials and Methods

Preparation of Animals

Forty Wistar-Albino rats were used in this investigation. Four groups of ten rats each, weighing 200–250 g at 8 weeks of age, were randomly assigned to: control, sham, 1 milli Tesla (mT), and 5 mT groups. While the 1 mT and 5 mT groups were exposed to a magnetic field for 4 hours a day, 5 days a week for 8 weeks, the sham group was exposed to the same environment for the same period of time, but the magnetic field device was kept off. The guidelines set forth by the Harran University Local Ethics Committee regarding the use of animals in experiments were strictly followed with ethical approval no: 2022/006/15 and date: 07/09/2022. Each cage could contain a maximum of 4 animals, and the room temperature was kept at 22 ± 2 °C.

Pulsed Magnetic Field Application

Two Helmholtz Bobin coils, each measuring 50 cm in diameter and consisting of 120 turns of copper wire with a 2 mm² cross-section area, were inserted inside a Faraday cage. A programmable signal generator power source (ILFA Electronics, Adana, Türkiye) was used for the desired repeats of ELF-PEMF (Fig. 1).

Two experimental groups were exposed to a pulsed magnetic field of either 1 mT or 5 mT magnitude. A total of 96 successive pulse trains with a 2-minute duration and a 30-second gap made up the program. Magnetic fields with peaks at 1 mT and 5 mT were produced by the coils.

Four rats were given pulsed magnetic field (PMF) by placing them in a 40x15x20 plexiglass container. The rats in the sham group were again housed in plexiglass and were kept in the application area for 4 hours, but the power source was off. At the end of the study, all animals were sacrificed with exsanguination under general anesthesia through intraperitoneally administered 90 mg/kg ketamine and 10 mg/kg xylazine. The anesthesia doses were determined according to a previously performed experimental study.^[16] The liver tissues were received for histological examinations.

Statistical Analysis

The statistical analysis was carried out using GraphPad Prism. Every experimental result is displayed as mean \pm SEM. To find the difference between groups, all parameters were evaluated using a one-way ANOVA and then subjected to a post hoc Dunnett test. Significant P values were defined as those with a value of less than 0.05.

Tissue Processing Protocol and Routine Staining

After being preserved in 10% formalin, the liver tissue samples that were received were rinsed under tap water. The standard tissue processing was completed precisely as described in a previous study.^[17] The samples were cleaned in xylene after being dehydrated using an alcohol series. To facilitate further analysis, the tissue samples were embedded in paraffin blocks. Using a rotating microtome (Thermo Scientific, Waltham, MA, USA), 5 μ m thick sections were cut from paraffin blocks, and the slides were then stained with hematoxylin and eosin for pathological analysis. The remaining sections were subjected to immunohistochemical examination.

Immunohistochemistry and Quantification of Immunodensity Analysis

An immunohistochemistry procedure was used to assess the immunoexpression of the Bax (Santa Cruz Biotechnology, Dallas, TX, US. cat no: sc-7480), Caspase 3 (Santa Cruz Biotechnology, Dallas, TX, US. cat. no:

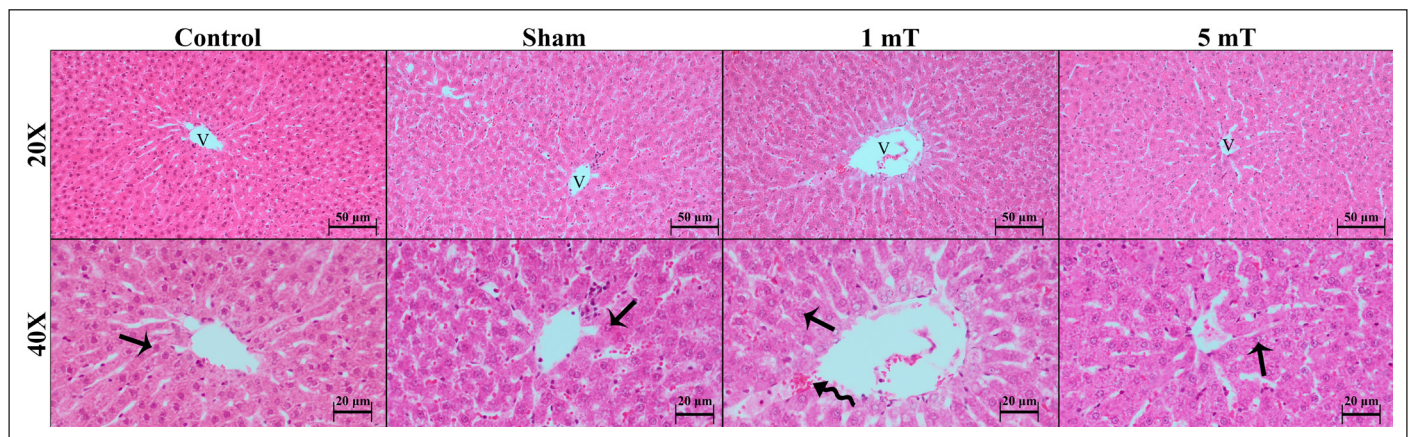


Figure 2. Representative histopathological micrographs of Control, Sham, 1mT, and 5mT groups. Our observations indicate there were no significantly morphological differences between the groups in terms of cellular morphology of hepatocytes (arrow) among the groups. However, there were some point-less congestions in sinusoidal (curved arrow) space in some of the hepatic lobules. Staining: H&E, Bar: 50 µm for 20X insets and 20 µm for 40X insets.

sc-56053), tumor necrosis factor- α (TNF- α , Santa Cruz Biotechnology, Dallas, TX, US. cat. no: sc-52746), and Nuclear factor kappa-light-chain-enhancer of activated B cells (NF- κ B, Santa Cruz Biotechnology, Dallas, TX, US. cat. no: sc-8008) proteins. The immunodensity analysis assessment was also performed on the stained samples. The slides underwent a succession of decreasing alcohol concentrations, deparaffinization, and PBS washing. Citrate buffer (pH 6.0) was used for antigen retrieval, and a methyl alcohol-prepared 3% H_2O_2 solution was used to reduce endogenous peroxidase activity. The remaining methods for immunohistochemistry were carried out using ready-to-use kits and antibodies. After being diluted with an antibody dilution solution at a 1:100 ratio, the Bax, Caspase 3, NF- κ B, and 1:300 TNF- α antibodies were applied to the tissue sections. Thermo Fisher Scientific, MA, USA's TP-125-HL ready-to-use IHC detection kit was used for secondary antibody and enzyme applications. Hematoxylin was used as the counterstain, and entellan was used to mount the samples. Using ImageJ, the measurement and creation of immunodensity datasets were carried out as previously mentioned.^[18] The immunodensity measures that were acquired were statistically assessed.

Results

Histopathological Observations

Our examinations indicated that hepatic tissue in the Control and Sham groups was normal. The parenchyma was filled with hepatic lobules containing a centrally localized vein surrounded by numerous hepatocytes. The hepatocytes were lined up between the sinusoidal structures. The corners of the lobules contained a portal area with a portal vein, bile duct, and hepatic artery. Some of the central vein neighboring hepatocytes were binuclear. Upon examining the morphology of livers in the 1 mT and 5 mT exposure groups, no significant degeneration was observed, except for pseudo-congestion resembling blood cell accumulation in hepatic sinusoids. This phenomenon is possibly a result of tissue processing protocols. Representative histopathological micrographs of the groups are shown in Figure 2.

Immunohistochemistry Results

Our examinations indicated that pro-apoptotic Bax and Caspase 3, inflammatory TNF- α , and transcriptional factor NF- κ B were highly expressed in the cytosol of the hepatocytes, but the immunodensity

of TNF- α was obviously higher than that of the hepatocytes in hepatic mononuclear phagocytic system members, the Kupffer cells (Fig. 3). However, we did not observe any qualitative immunodensity difference between the groups. When we consider our statistical analysis results, the immunodensity of Bax was $43.57 \pm 1.31\%$ and $43.33 \pm 1.43\%$ in the Control and Sham groups, respectively ($p > 0.05$, Control vs. Sham). The Bax immunodensity in the 1 mT and 5 mT groups was 41.84 ± 1.46 and $41.91 \pm 1.18\%$, and there was no significant difference between the groups compared to the control ($p > 0.05$). The Caspase 3 level in the Control group was $34.16 \pm 1.14\%$. The executioner Caspase 3 level in the Sham group was $32.11 \pm 1.14\%$ ($p > 0.05$, Control vs. Sham). The tissue expression was $34.42 \pm 1.20\%$ and $34.02 \pm 1.34\%$ in the 1 mT and 5 mT groups, respectively, and the immunodensity level of Caspase 3 between the groups was similar ($p > 0.05$). The pro-inflammatory TNF- α in the Control and Sham groups was $41.84 \pm 1.36\%$ and $40.20 \pm 1.17\%$. The difference between these two groups was not significant ($p > 0.05$). The TNF- α immunodensity level in the 1 mT and 5 mT groups was similar to each other and the other groups ($p > 0.05$). The immunoexpression level of TNF- α was $40.99 \pm 1.38\%$ and $42.64 \pm 1.40\%$ in these two groups ($p > 0.05$). The transcription factor NF- κ B level was similar ($p > 0.05$) in every group. The results were 49.18 ± 1.84 and 47.46 ± 2.04 in the Control and Sham groups. Additionally, the tissue immunoexpression of NF- κ B was $48.09 \pm 2.14\%$ and $47.77 \pm 2.23\%$ in the 1 mT and 5 mT groups. A brief graphical demonstration of the statistical analysis of Bax, Caspase 3, TNF- α , and NF- κ B is shown in Figure 4.

Discussion

The possible harmful or harmless effect of ELF-EMF has not been clearly explored or described yet because of numerous interfering factors such as exposure condition and dose, time, body mass of the organism, etc. For that reason, we still require more *in vitro* trials and *in vivo* randomized experiments to explore the potential effects of two types (pulsed or sinusoidal) of ELF-EMF on vital biological organs such as the liver. Additionally, it should be remembered that the cellular response of living cells to ELF-EMF is generated through the regulation of numerous cellular signaling mechanisms.^[19] When the literature is considered, some conflicting results can be reached. On one side, researchers such as Li et al.^[20] reported that exposure to 5, 10, or 20 mT

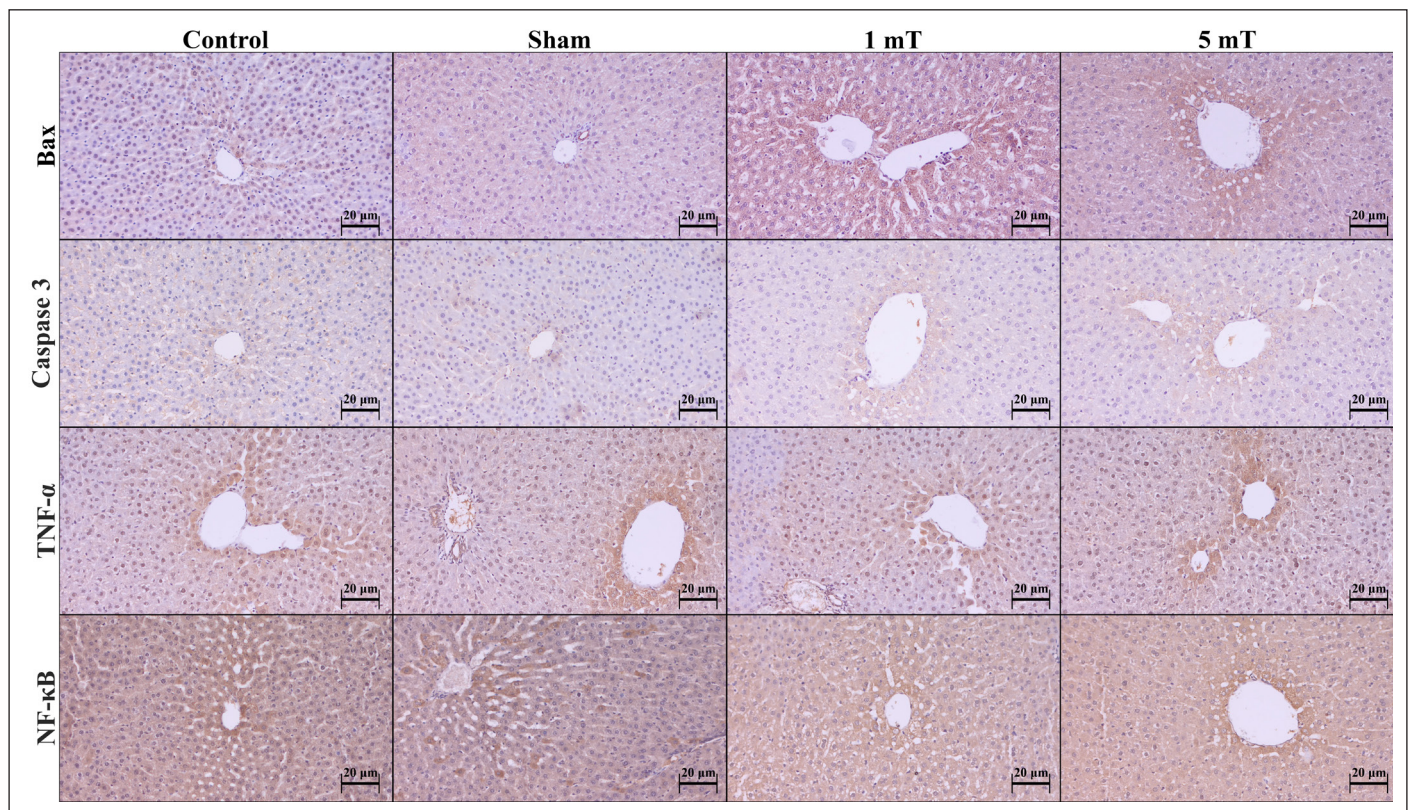


Figure 3. Representative micrographs of the immunohistochemistry of Bax, Caspase 3, TNF- α and NF- κ B in Control, Sham, 1mT and 5 mT groups. The brown staining indicates the immunopositivity of the protein of interest. Counterstain: Hematoxylin.

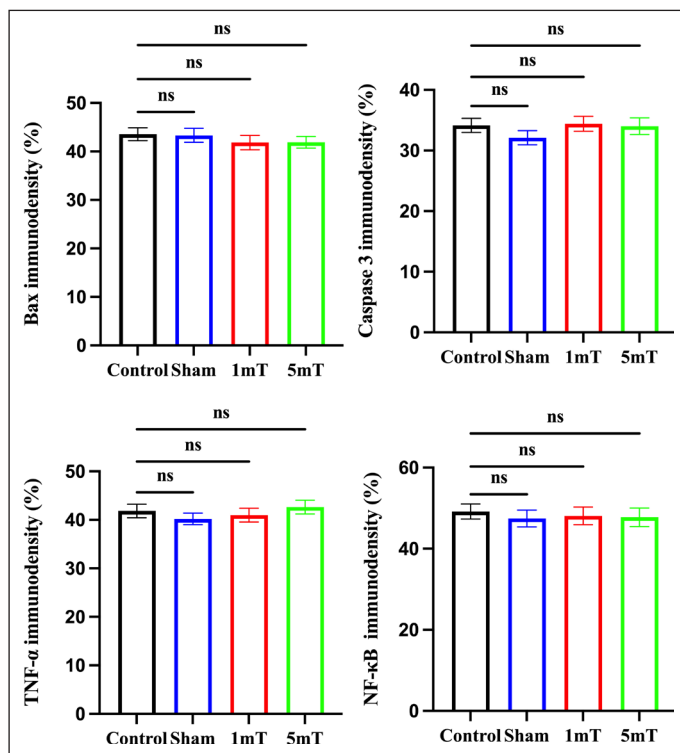


Figure 4. Graphical demonstration of the statistical analysis of immunodensity examinations. ns between the groups indicate statistically similarity ($p > 0.05$) between the groups.

for 10 weeks harmfully affected the serum markers of liver function enzymes and liver oxidative stress. From a cellular regulation perspective, a previously published study reported that exposure to ELF-EMF inhibits pre-neoplastic lesion formation in experimental animal liver through up-regulation of the apoptotic cellular response.^[21] The variations among the results of different studies can only be explained via administration or exposure factors as described above. For example, Kiray et al.^[22] reported upregulated Caspase 3 expression and DNA fragmentation in muscle tissue of rats exposed to 3 mT for 2 months (7 days a week and 4 hours a day). Additionally, the authors reported morphological abnormalities such as perinuclear vacuole formation and irregularities in myofilaments. From a clinical approach, some recent studies reported the beneficial effect of ELF-EMF exposure on the antioxidant enzyme system and psychological status in patients who received ischemic stroke treatment (Y). For that reason, recently published articles demonstrate some successful clinical properties of ELF-EMF besides the largely reported harmful effects.

The current investigation demonstrated that long-term extremely low-frequency pulsed-electromagnetic field (ELF-PEMF) exposure did not affect the morphology or promote apoptosis in the rat liver. Investigations demonstrated that ELF-EMF exposures affect apoptotic pathways in the liver and other tissues,^[14,23] despite the fact that some of the results obtained in this study are consistent with those of other investigations. These disparities could have resulted from the use of various experimental circumstances. It is believed that variables utilized in ELF-EMF exposures, such as frequency, waveform, intensity, duration, and timing, are typically uncontrollable in tests, which could lead to inconsistent results.^[24]

Bax and Bcl-2 proteins have a role in controlling the pore complex known as the mitochondrial permeability transition (MPT). Cytochrome c can be released into the cytosol when Bax opens the MPT pore; however, Bcl2 can stabilize the opening of the MPT pore, prevent cytochrome c release, and provide protection against it. Because of this, the quantity of pro-apoptotic Bax plays a critical role in both the apoptotic cascade process and mitochondrial integrity.^[25] Our findings demonstrated that Bax proteins were unaffected by PEMF exposure.

The release of cytochrome c from mitochondria is a crucial step in the pathways leading to apoptosis and the activation of caspases downstream, including caspase-3.^[26] In this study, the collected data showed that, in comparison to the control, ELF-PEMF exposure at 1 mT and 5 mT intensities did not produce a statistically significant change in caspase 3 level. Although our results seem consistent with previous studies, the existence of results suggesting the contrary also draws attention.^[8]

TNF- α plays a diverse role in numerous biological processes, such as immune homeostasis modulation and cell apoptosis regulation.^[27] TNF- α -induced signaling via TNF Receptor 1 (R1) triggers multiple physiological reactions, such as the enlistment and stimulation of caspase-8 inside the receptor complex. This, in turn, starts a cascade leading to apoptosis, the programmed cell death. The information gathered from this investigation indicated that ELF-PEMF exposure did not result in a dramatic change in TNF- α levels compared to the control and sham groups.

The transcription factor known as nuclear factor kappa B (NF- κ B) is an ancestral protein and is thought to regulate innate immunity.^[28] The NF- κ B signaling system controls cellular resistance to invasive infections by establishing a connection between pathogenic and cellular danger signals. TNF α binds to TNF receptors in response to stimuli such as TNF α or other cell stressors. After numerous iterations of these interactions, the active form is generated, and it has the ability to alter the cellular environment significantly. Depending on the kind of cell, developmental stage, and clinical condition, NF- κ B's impact on cell survival can be either pro-inflammatory or protective.^[29] Nevertheless, it is unclear how exposure to ELF-EMF affects NF- κ B in liver tissue. According to this study, there was no statistically significant difference in the NF- κ B response to ELF-PEMF exposure.

Conclusion

When we consider our observations in terms of morphological and apoptosis-associated protein expression levels, it is possible to conclude that the administration or exposure design of this study is not altering liver morphology and immunoexpression of apoptosis regulatory protein expression levels.

Acknowledgements: The authors would like to thank Professor Cemil Sert and Assistant Professor M. Zahid Tuysuz for their valuable contributions.

Ethics Committee Approval: The Harran University Local Ethics Committee granted approval for this study (date: 07.09.2022, number: 2022/006/15).

Author Contributions: Concept – YG, US, MPO; Design – YG, US; Supervision – YG, US; Fundings – YG; Materials – US, MPO; Data Collection and/or Processing – US, MPO; Analysis and/or Interpretation – YG, US, MPO; Literature Search – YG, US, MPO; Writing – YG, US; Critical Reviews – YG, US, MPO.

Conflict of Interest: The authors have no conflict of interest to declare.

Use of AI for Writing Assistance: Not declared.

Financial Disclosure: This study was supported by Harran University Scientific Research Projects (project number: 22128).

Peer-review: Externally peer-reviewed.

References

- Touitou Y, Selmaoui B. The effects of extremely low-frequency magnetic fields on melatonin and cortisol, two marker rhythms of the circadian system. *Dialogues Clin Neurosci* 2012;14(4):381-399.
- Zhao Q-R, Lu J-M, Yao J-J, Zhang Z-Y, Ling C, Mei Y-A. Neuritin reverses deficits in murine novel object associative recognition memory caused by exposure to extremely low-frequency (50 Hz) electromagnetic fields. *Sci Rep* 2015;5:11768.
- Feychting M, Ahlbom A, Kheifets L. EMF and Health. *Annu Rev Public Health* 2005;26:165-189.
- Roshanaee MK, Abtahi-Eivary SH, Shokoohi M, Fani M, Mahmoudian A, Moghimian M. Protective effect of minocycline on Bax and Bcl-2 gene expression, histological damages and oxidative stress induced by ovarian torsion in adult rats. *Int J Fertil Steril* 2022;16(1):30-35.
- Ding G-R, Nakahara T, Hirose H, Koyama S, Takashima Y, Miyakoshi J. Extremely low frequency magnetic fields and the promotion of H₂O₂-induced cell death in HL-60 cells. *Int J Radiat Biol* 2004;80(4):317-324.
- Jian W, Wei Z, Zhiqiang C, Zheng F. X-ray-induced apoptosis of BEL-7402 cell line enhanced by extremely low frequency electromagnetic field in vitro. *Bioelectromagnetics* 2009;30(2):163-165.
- Kaszuba-Zwoinska J, Wojcik K, Bereta M, Ziomber A, Pierzchalski P, Rokita E, et al. Pulsating electromagnetic field stimulation prevents cell death of puromycin treated U937 cell line. *J Physiol Pharmacol* 2010;61(2):201-205.
- Palumbo R, Capasso D, Brescia F, Mita P, Sarti M, Bersani F, et al. Effects on apoptosis and reactive oxygen species formation by Jurkat cells exposed to 50 Hz electromagnetic fields. *Bioelectromagnetics* 2006;27(2):159-162.
- Cid MA, Úbeda A, Hernández-Bule ML, Martínez MA, Trillo MÁ. Antagonistic effects of a 50 Hz magnetic field and melatonin in the proliferation and differentiation of hepatocarcinoma cells. *Cell Physiol Biochem* 2012;30(6):1502-1516.
- Brisdelli F, Bennato F, Bozzi A, Cinque B, Mancini F, Iorio R. ELF-MF attenuates quercetin-induced apoptosis in K562 cells through modulating the expression of Bcl-2 family proteins. *Mol Cell Biochem* 2014;397(1-2):33-43.
- Laqué-Rupérez E, Ruiz-Gómez MJ, de la Peña L, Gil L, Martínez-Morillo M. Methotrexate cytotoxicity on MCF-7 breast cancer cells is not altered by exposure to 25 Hz, 1.5 mT magnetic field and iron (III) chloride hexahydrate. *Bioelectrochemistry* 2003;60(1-2):81-86.
- Mizuno K, Narita E, Yamada M, Shinohara N, Miyakoshi J. ELF magnetic fields do not affect cell survival and DNA damage induced by ultraviolet B. *Bioelectromagnetics* 2014;35(2):108-115.
- Luo X, Ma L, Gao P, Zhang Y. Effects of subchronic extremely low-frequency electromagnetic field exposure on biochemical parameters in rats. *Toxicol Ind Health* 2017;33(4):365-372.
- Cevik A, Aydin M, Apaydin AM, Yuksel M. Pathological and immunohistochemical effects of electromagnetic fields on rat liver. *Indian J Anim Res* 2017;51(6):1134-1137.
- Holovská K, Almášiová V, Cigánková V, Beňová K, Račeková E, Martončíková M. Structural and ultrastructural study of rat liver influenced by electromagnetic radiation. *J Toxicol Environ Health A* 2015;78(6):353-356.
- Taş M, Cirit Ü, Özkan O, Denli M, Zincirlioğlu SB, Şeker U, et al. Protective role of vitamin C on sperm characteristics and testicular damage in rats exposed to radiation. *Kafkas Üniv Vet Fak Derg* 2014;20(1):59-64.
- Ayaz H, Kaya S, Seker U, Nergiz Y. Comparison of the anti-diabetic and nephroprotective activities of vitamin E, metformin, and Nigella sativa oil on kidney in experimental diabetic rats. *Iran J Basic Med Sci* 2023;26(4):395-399.
- Seker U. Effects of black cumin seed oil on oxidative stress and expression of membrane-cytoskeleton linker proteins, radixin and moesin, in streptozotocin induced diabetic liver. *Hepatol Forum* 2021;3(1):21-26.
- Barati M, Darvishi B, Javidi MA, Mohammadian A, Shariatpanahi SP, Eisavand MR, et al. Cellular stress response to extremely low-frequency elec-

- tromagnetic fields (ELF-EMF): An explanation for controversial effects of ELF-EMF on apoptosis. *Cell Prolif* 2021;54(12):e13154.
20. Li B, Li W, Bi J-Q, Zhao J, Qu Z-W, Lin C, et al. Effect of long-term pulsed electromagnetic field exposure on hepatic and immunologic functions of rats. *Wien Klin Wochenschr* 2015;127:959-962.
 21. Jiménez-García MN, Arellanes-Robledo J, Aparicio-Bautista DI, Rodríguez-Segura MÁ, Villa-Treviño S, Godina-Nava JJ. Anti-proliferative effect of extremely low frequency electromagnetic field on preneoplastic lesions formation in the rat liver. *BMC Cancer* 2010;10:159.
 22. Kiray A, Tayefi H, Kiray M, Bagriyanik HA, Pekcetin C, Ergur BU, et al. The effects of exposure to electromagnetic field on rat myocardium. *Toxicol Ind Health* 2013;29(5):418-425.
 23. Akdag MZ, Dasdag S, Uzunlar AK, Ulukaya E, Oral AY, Çelik N, et al. Can safe and long-term exposure to extremely low frequency (50 Hz) magnetic fields affect apoptosis, reproduction, and oxidative stress? *Int J Radiat Biol* 2013;89(12):1053-1060.
 24. Valberg PA. Designing EMF experiments: What is required to characterize "exposure"? *Bioelectromagnetics* 1995;16(6):396-401.
 25. Wu C-C, Bratton SB. Regulation of the intrinsic apoptosis pathway by reactive oxygen species. *Antioxid Redox Signal* 2013;19(6):546-558.
 26. Shalini S, Dorstyn L, Dawar S, Kumar S. Old, new and emerging functions of caspases. *Cell Death Differ* 2015;22(4):526-539.
 27. Pei Y, Xing D, Gao X, Liu L, Chen T. Real-time monitoring full length bid interacting with Bax during TNF-alpha-induced apoptosis. *Apoptosis* 2007;12(9):1681-1690.
 28. Baltimore D. *Discovering NF- B*. Cold Spring Harb Perspect Biol 2009;1(1):a000026.
 29. Qin Z, Tao L, Chen X. Dual roles of NF-κB in cell survival and implications of NF-κB inhibitors in neuroprotective therapy. *Acta Pharmacol Sin* 2007;28(12):1859-1872.