

Vertebroplasty Using Allograft Bone Chips with Posterior Instrumented Fusion in the Treatment of Osteoporotic Vertebral Fractures with Neurological Deficits

Soichiro Masuda, Eijiro Onishi, Satoshi Ota, Satoshi Fujita, Tatsuya Sueyoshi, Takumi Hashimura and Tadashi Yasuda

Department of Orthopedic Surgery, Kobe City Medical Center General Hospital, Hyogo, Japan

Abstract:

Introduction: In general, osteoporotic vertebral fractures with neurological deficits require surgery. However, the ideal surgical method remains controversial. We evaluated the efficacy of combining posterior instrumented fusion and vertebroplasty using allograft bone chips.

Methods: Twelve patients (five men, seven women; age 68-84 years, mean age 75.9 years) with osteoporotic vertebral fractures with neurological deficits were reviewed retrospectively. They underwent posterior instrumented fusion and vertebroplasty, using allograft bone, at our institution between January 2007 and June 2016. We assessed the surgical results, radiologically and neurologically, after a mean follow-up of 37.3 months.

Results: The mean local kyphosis angle was 10° before surgery, -3.3° immediately after surgery, and 4.4° at follow-up. The average spinal canal compromise was 26.9% before surgery and 19.5% at follow-up. All patients achieved bony fusion and none needed additional surgery. All patients improved by at least one grade on the modified Frankel grading system.

Conclusions: Combining vertebroplasty, using allograft bone chips, and posterior instrumented fusion appears to be an effective option for osteoporotic vertebral fractures with neurological deficits.

Keywords:

osteoporotic vertebral fracture, nonunion, allograft, vertebroplasty, posterior instrumentation

Spine Surg Relat Res 2019; 3(3): 249-254
dx.doi.org/10.22603/ssrr.2018-0102

Introduction

A large aging population has led to increased osteoporotic vertebral fracture cases, creating a serious health issue¹. Many can be treated conservatively, including bed rest and conventional braces². However, 13.5% of fractures fail to unite, causing intolerable back pain, spinal kyphotic deformity, and neurological deficits³. Neurological complications following a vertebral fracture in the osteoporotic spine are caused by neural compression, which occurs because of retropulsed bone fragments in the spinal canal, progressed kyphosis, and fracture site instability. Surgical intervention is highly recommended for patients with neurological deficits; however, there is no established method even though various surgical treatments have been developed^{4,8}.

Anterior decompression with fusion is considered the ideal method for surgery because it provides resection of the retropulsed bony fragments and reconstruction of the ante-

rior spinal column. However, about 20% of patients undergoing this procedure need additional posterior instrumentation surgery⁶. It is preferable to minimize the surgical invasiveness for older patients. Recently, some reports have shown that posterior instrumented fusion, combined with vertebroplasty, is a less invasive procedure providing immediate spinal stability and correcting kyphotic deformity^{5,7,8}. There are several vertebroplasty materials available, such as polymethyl methacrylate (PMMA) bone cement⁹, calcium phosphate cement^{5,10}, hydroxyapatite (HA) blocks^{5,7}, and autologous bone¹¹, but the optimal material remains controversial. Cement has a risk of embolism and nerve damage^{12,13}, and its stiffness can cause incident fracture at the adjacent level¹⁴. Autologous bone grafting has disadvantages such as donor-site pain, infection, and prolonged operative time¹¹.

Allograft bone has been shown to yield osteoinductive and osteoconductive capabilities compatible with autologous bone. Indeed, use of allograft bone is effective in total hip

Corresponding author: Soichiro Masuda, smasuda0306@gmail.com

Received: November 19, 2018, Accepted: December 19, 2018, Advance Publication: January 25, 2018

Copyright © 2019 The Japanese Society for Spine Surgery and Related Research

Table 1. Patient Demographic and Clinical Data.

Patient	Age (yr)/Sex	Cause of osteoporosis	Duration of disease (mo)	Affected vertebra	Fusion levels	Decompression	Sublaminar cables and/or hooks
1	77/F	RA	3	T12	T11-L1	None	None
2	68/M	CKD	3	L1	T11-L3	None	T12, L1, 2
3	78/F	Senile	3	L1	T11-L3	None	L1
4	69/F	Senile	1	L4	L2-S1	L4	None
5	76/M	Senile	2	T12	T10-L2	None	L1
6	82/F	Senile	5	L4	L3-5	L2-4	None
7	80/M	Senile	4	L5	L3-S1	L4-5	None
8	84/F	Senile	2	T12	T10-L2	None	None
9	76/F	Steroid	20	T12	T11-L1	None	None
10	79/M	RA	2	L2	T11-L4	None	T10, 11
11	68/F	Senile	1	T11	T10-12	None	T10, 12
12	74/F	CKD	2	L3	L2-4	None	L2, 4

F, female; M, male; RA, rheumatoid arthritis; CKD, chronic kidney disease; S, sacral; T, thoracic; L, lumbar

arthroplasty¹⁵⁾, anterior cervical fusion¹⁶⁾, and posterior spinal fusion¹⁷⁾. However, to our knowledge, there is no report, in English, on the result of vertebroplasty using allograft bone. The purpose of this study was to evaluate the efficacy of combining posterior instrumented fusion with vertebroplasty, using allograft bone, for osteoporotic vertebral fractures associated with neurological deficits in the thoracolumbar spine.

Materials and Methods

This research has been approved by the IRB of the authors' affiliated institutions.

Patient population

Between January 2007 and June 2016, 12 patients (five men and seven women) aged 68-84 years (mean age 75.9 years) with delayed neurological deficits following osteoporotic vertebral fractures of the thoracic or lumbar spine underwent posterior instrumented fusion, combined with vertebroplasty using allograft bone from a frozen human femoral head, in our institution. Indications for this surgery included vertebral fractures in the thoracic or lumbar spine with neurological deficits caused by retropulsion of the posterior vertebral wall and instability at the fracture site. All patients initially received conservative treatment but developed neurological deficits. The mean duration of the follow-up was 47.3 months (range 7-93 months). The mean duration from the onset of symptoms to surgery was 4.8 months (range 1-20 months). The causes of osteoporosis included senility (seven patients), rheumatoid arthritis (two patients), chronic kidney disease (two patients), and steroid use (one patient). The fracture levels were T12 (four patients), L1 (two patients), L4 (two patients), and other levels (four patients) (Table 1). We assessed the neurological status of each patient using the modified Frankel grading system¹⁸⁾. Preoperatively, eight patients had grade C deficits, three had grade D1 deficits, and one had grade D2 deficits.

Surgical procedures

The patients were placed prone on a radiolucent operating table with the hip joints flexed. The kyphotic deformity was corrected by postural reduction. A standard posterior midline approach was used to explore the spine. The pedicle screws were placed in the standard fashion¹⁹⁾. Following indirect reduction and fixation, we performed vertebroplasty using allograft bone. We used fresh-frozen femoral heads, retrieved during primary total hip arthroplasty from consenting donors, as the bone allograft. The bone was sterilized by pasteurization, using a Lobator SD2 bone disinfector (Telos, Marburg, Germany), and processed into morselized bone chips using a bone mill. No bone was irradiated, or no additional sterilization procedure was undertaken. In detail, a trocar was inserted into the defect of the fractured vertebral body through the pedicle. The morselized allograft bone chips were impacted into the fractured vertebral defect under fluoroscopic monitoring. The allograft was impacted until the vertebral body height became nearly normal. Principally, the spine was fused from one level above to one level below the collapsed vertebra. When the patients had old vertebral compression fractures, the longer levels were fused. The average number of fusion levels was 3.2 (range 2-5) (Table 1). In six patients, augmentation, with sublaminar cables and/or hooks, was added to increase the pedicle screws' pullout strength²⁰⁾. Although we do not usually perform decompression at the fracture level, laminectomy was performed for decompression in three patients with severe spinal canal stenosis and paralysis. Allograft bone was grafted onto the decorticated lamina and facet joints in all cases. The patients were allowed to ambulate, wearing a thoracolumbar orthosis, on the second postoperative day. The thoracolumbar orthosis was used for at least three months to protect the instrumentation from excessive mechanical constraint. Six patients were administered teriparatide postoperatively to enhance the spinal fusion. Vitamin D, bisphosphonate and raloxifene were administered in five, two, and one patients, respec-

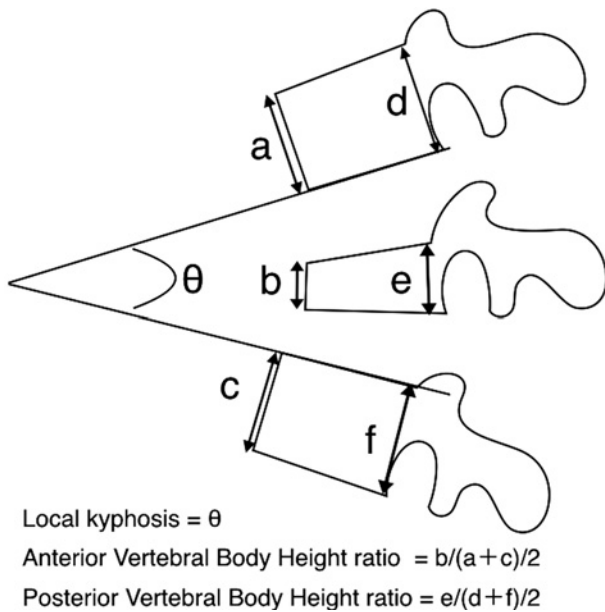


Figure 1. Schematic diagrams of radiographic measurements.

tively.

Radiographic assessment

Plain radiographs were obtained before surgery, immediately after surgery, three months after surgery, and at the final follow-up. On plain radiographs, the local kyphosis and the anterior and posterior vertebral body height ratios (AVBhr and PVBhr) were measured (Fig. 1). Local kyphosis was defined as the Cobb angle formed between the lower endplate of the uninvolved vertebra above the fractured level and the upper endplate of the uninvolved vertebra below the fractured level⁷. The AVBhr and PVBhr were defined as the percentage of the vertebral heights of the fractured vertebra with respect to the average heights of two adjacent vertebrae, respectively¹⁰. Spinal canal occupation, caused by retropulsed bony fragments, was measured on computed tomography (CT) images, preoperatively and at the final follow-up, except for one patient who had no CT images after surgery⁸.

Results

The mean operating time was 183 minutes (range 99-297), and the mean blood loss was 235 g (range 10-716). The mean local kyphosis was 10° before surgery, -3.3° immediately after surgery, 1.8° three months after surgery and 4.4° at the final follow-up. The mean correction of the local kyphosis was 13.3° immediately after surgery, 8.3° three months after surgery, and 5.6° at the final follow-up. The mean loss of correction was 7.7° from immediately after surgery to the final follow-up. The average AVBhr was 0.43 before surgery, 0.75 immediately after surgery, 0.63 three months after surgery, and 0.55 at the final follow-up. The average PVBhr was 0.72 before surgery, 0.79 immediately

after surgery, 0.77 three months after surgery, and 0.7 at the final follow-up. The average spinal canal compromise was 26.9% (range 15-41) before surgery and 19.5% (range 0-35) at the final follow-up (Table 2). There were no complications obviously related to the operation. Loosening of pedicle screws was observed in four patients. Three of those screws were inferior to the fracture vertebra, and the remaining one was superior to it. Two patients developed a subsequent vertebral compression fracture at the adjacent vertebra of the fusion level during the follow-up. However, all patients achieved bony fusion and none needed additional surgery. Postoperative neurological status based on the modified Frankel grading system was found grades D1, D2, D3, and E in two, five, one, and four patients, respectively. All patients gained neurological improvement by at least one grade (Fig. 2).

Case presentation

A 78-year-old woman suffered from back pain caused by osteoporotic vertebral fracture at L1 (Fig. 3, Table 2; Patient 3). She received conservative treatment with plastic orthoses and rest, resulting in gradual muscle weakness with persistent back pain. Three months after the onset of symptoms, the patient showed neurological deficits of modified Frankel grade C and was unable to walk. CT and magnetic resonance imaging demonstrated neural element compression by the retropulsed bone fragments of L1 with 16% occupation rate. Posterior fixation of T11-L3 and vertebroplasty of L1 using allograft bone corrected the local kyphosis from 24° to -5° . The neurological deficit recovered to modified Frankel grade D2 with immediate pain relief. At 58 months after surgery, bone union and remodeling of the L1 vertebra was achieved with the local kyphosis of 0° .

Discussion

In the current study, we found combining posterior instrumented fusion and vertebroplasty, using allograft bone for osteoporotic vertebral fracture nonunion with delayed neurological deficits, is a safe and effective surgical option. In this situation, we have had some difficulties with surgical treatment because most patients are old, with medical complications and severe osteoporosis. The anterior direct neural decompression and reconstruction method is thought to have several advantages, including direct neural decompression, structural anterior column support, and protection of the intact spinal posterior elements⁶. However, this method is technically demanding and highly invasive, and has a risk of chest or abdominal organ injury compared to the posterior approach. In addition, this method needs additional posterior instrumented fixation in about 20% of patients⁶. For older patients, it is preferable to minimize the invasiveness of the operation. Recent studies found that, in this situation, it is more effective to eliminate instability at the vertebral fracture site than to decompress the neural elements⁷. It is possible to provide firm spine stabilization and correct the

Table 2. Radiographic Data Pre- and Postoperatively.

Patient	Local kyphosis angle			Correction angle		Correc- tion loss at last follow- up	AVBH ratio		PVBH ratio		Spinal canal occupa- tion rate (%)	
	Preop	Postop	Last follow- up	Postop	Last follow- up		Preop	Postop	Preop	Postop	Preop	Last follow- up
1	28	5	16	23	12	11	0.26	0.91	0.74	0.87	32	26
2	9	1	10	8	-1	9	0.35	0.54	0.70	0.71	22	11
3	24	-5	1	29	23	6	0.16	0.82	0.60	0.80	16	7
4	-13	-10	-1	-3	-12	9	0.70	0.94	0.77	0.83	43	25
5	37	5	13	32	24	8	0.54	0.89	0.71	0.79	15	35
6	-3	-15	-6	12	3	9	0.49	0.90	0.84	0.86	41	29
7	-29	-25	-16	-4	-13	9	0.66	0.80	0.66	0.80	23	14
8	6	-5	2	11	4	7	0.42	0.75	0.80	0.79	34	25
9	15	11	11	4	4	0	0.40	0.50	0.79	0.85	26	22
10	1	-16	-9	17	10	7	0.68	0.91	0.81	0.85	17	0
11	37	11	32	26	5	21	0.15	0.35	0.45	0.58	27	21
12	8	4	0	4	8	-4	0.64	0.78	0.72	0.75	33	
mean±SD	10.0±19.0	-3.3±10.9	4.4±12.3	13.3±11.7	5.6±10.9	7.7±5.7	0.44±0.19	0.76±0.18	0.72±0.10	0.79±0.08	26.9±9.2	19.5±9.9

AVBH, anterior vertebral body height ratio; PVBH, Posterior vertebral body height ratio; Preop, preoperative; Postop, postoperative; SD, standard deviation

	A	B	C	D1	D2	D3	E
A							
B							
C				2	4	1	1
D1					1		2
D2							1
D3							
E							

Figure 2. Preoperative and postoperative neurological status using the modified Frankel grading system.

kyphotic changes using a pedicle screw and rod system and the posterior approach^{5,7,8}). However, these patients have such severe osteoporosis that treatment with only posterior spinal instrumentation, without anterior column support, cannot maintain the spinal alignment for long⁴). The addition of vertebroplasty to posterior instrumented fusion provides anterior column support of the spine^{5,7,8}). Furthermore, the biomechanical study showed that adding vertebroplasty reduced the posterior instrument load²¹). Some comparative studies have reported that posterior fixation with vertebroplasty offers stability equivalent to that of anterior reconstruction^{4,5}). Similarly, in our study, posterior instrumented fusion with vertebroplasty succeeded in maintaining spinal alignment over the follow-up time (an average of 47.3 months) and recovery from neurological deficits in all 12 patients.

The optimal method for vertebroplasty remains controversial. PMMA cement is used most commonly for vertebroplasty⁹). Recently, calcium phosphate cement has replaced

PMMA because it is a self-hardening material, without the need for local heating, and is nontoxic to surrounding bone tissue¹⁰). However, both of them have some disadvantages, including epidural leakage, subdural hematoma, pulmonary embolism, and adjacent vertebral fractures¹²⁻¹⁴). Although artificial bones, including HA blocks, are osteoconductive and can provide stability, they are not osteoinductive and remain as foreign materials because of the low absorption rate²²). Autogenous bone grafts, such as those from the iliac bone crest, have excellent biocompatibility but are associated with donor-site morbidity, including hematoma, infection, and pain¹¹).

To our knowledge, our study is the first description of vertebroplasty using allograft bone. Allograft bone grafts are used widely as a substitute due to the ease of use, availability, and avoidance of donor-site complication¹⁵⁻¹⁷). The allograft's porosity is similar to that of live bone; it promotes new bone formation and remodeling by providing an osteoconductive scaffold with osteoinductive factors²³). Furthermore, allograft bone has moderate mechanical strength since it contains cortical and cancellous bone²³). Because the morselized allograft bone has less stiffness than other materials, such as cement and artificial bone substitutes, it might fail to support the anterior vertebral column firmly. However, in our study, the mean correction loss at follow-up was 7.7°, which is similar to the correction losses of 4.6-13.4° in previous reports using calcium phosphate cement as well as HA blocks for vertebroplasty in other reports^{4,5}). There is concern that the use of allograft bone may be associated with transmission of diseases such as hepatitis C, human immunodeficiency virus, and others. Miller et al.²⁴) reported that there seems to be no overt risk associated with using allograft bone provided that donors are triaged to rule out a history of these diseases. In our study, no patient developed an infection associated with the allograft bone.

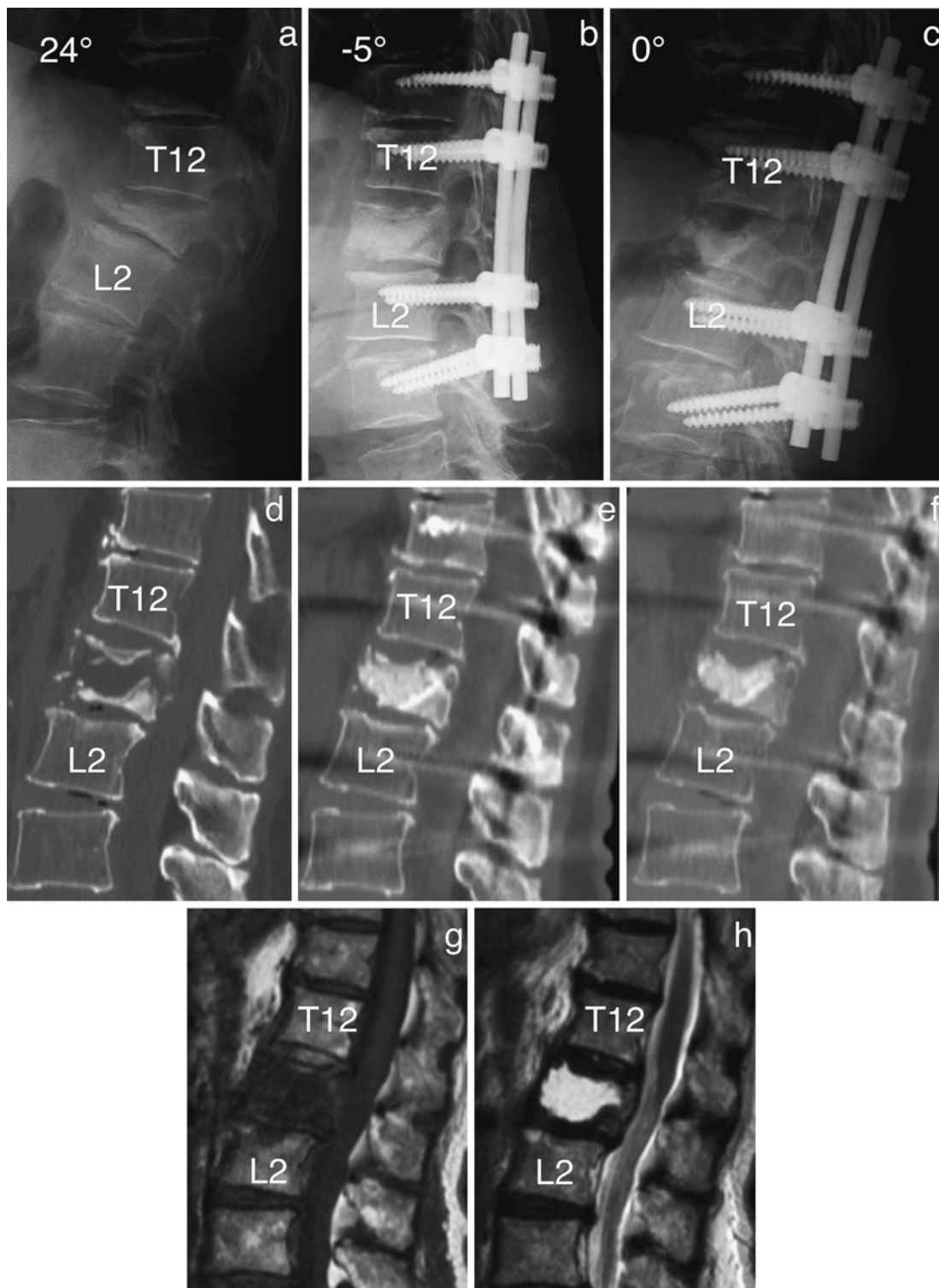


Figure 3. Patient 3. Lateral plain radiographs and computed tomography images obtained before surgery (a, d), immediately after surgery (b, e), and at the last follow-up (c, f). Magnetic resonance images obtained before surgery showed that the retropulsed bone fragments compressed the spinal cord (g, h).

This study has some limitations. First, the nature of the retrospective study and case series, which was performed in a single institution, may decrease its level of evidence. Second, the small number of patients evaluated limits the study's applicability. Third, the minimum follow-up period of seven months was too short to confirm the method's efficacy in this study. However, 10 of the 12 patients (83.3%)

were observed more than 19 months, and the mean follow-up duration of 47.3 months was sufficient. Fourth, this study did not have a control group. Further studies should be performed to compare this method with others. Fifth, although the restoration of well-balanced sagittal alignment of whole spine is necessary to treat vertebral compression fracture, we have evaluated only the local kyphotic angle of the patients.

Despite these limitations, this study provides an important approach for treating osteoporotic vertebral fractures with neurological deficits. Combining posterior instrumented fusion and vertebroplasty using allograft bone chips may provide neurological improvement and stabilization without the need for additional surgery.

In conclusion, this treatment, using allograft bone chips for vertebroplasty augmented with posterior instrumented fusion, offers one treatment option for osteoporotic vertebral fracture with neurological deficits.

Conflicts of Interest: The authors declare that there are no relevant conflicts of interest.

Author Contributions: Soichiro Masuda wrote and prepared the manuscript, and all of the authors participated in the study design. All authors have read, reviewed, and approved the article.

References

- Cummings SR, Melton LJ. Epidemiology and outcomes of osteoporotic fractures. *Lancet*. 2002;359(9319):1761-7.
- Mattie R, Laimi K, Yu S, et al. Comparing percutaneous vertebroplasty and conservative therapy for treating osteoporotic compression fractures in the thoracic and lumbar spine: a systematic review and meta-analysis. *J Bone Joint Surg Am*. 2016;98(12):1041-51.
- Tsujio T, Nakamura H, Terai H, et al. Characteristic radiographic or magnetic resonance images of fresh osteoporotic vertebral fractures predicting potential risk for nonunion: a prospective multicenter study. *Spine*. 2011;36(15):1229-35.
- Nakashima H, Imagama S, Yukawa Y, et al. Comparative study of 2 surgical procedures for osteoporotic delayed vertebral collapse: anterior and posterior combined surgery versus posterior spinal fusion with vertebroplasty. *Spine*. 2015;40(2):120-6.
- Uchida K, Nakajima H, Yayama T, et al. Vertebroplasty-augmented short-segment posterior fixation of osteoporotic vertebral collapse with neurological deficit in the thoracolumbar spine: comparisons with posterior surgery without vertebroplasty and anterior surgery. *J Neurosurg Spine*. 2010;13(5):612-21.
- Kanayama M, Ishida T, Hashimoto T, et al. Role of major spine surgery using Kaneda anterior instrumentation for osteoporotic vertebral collapse. *J Spinal Disord Tech*. 2010;23(1):53-6.
- Ataka H, Tanno T, Yamazaki M. Posterior instrumented fusion without neural decompression for incomplete neurological deficits following vertebral collapse in the osteoporotic thoracolumbar spine. *Eur Spine J*. 2009;18(1):69-76.
- Sudo H, Ito M, Abumi K, et al. One-stage posterior instrumentation surgery for the treatment of osteoporotic vertebral collapse with neurological deficits. *Eur Spine J*. 2010;19(6):907-15.
- Liu JT, Li CS, Chang CS, et al. Long-term follow-up study of osteoporotic vertebral compression fracture treated using balloon kyphoplasty and vertebroplasty. *J Neurosurg Spine*. 2015;23(1):94-8.
- Korovessis P, Hadjipavlou A, Repantis T. Minimal invasive short posterior instrumentation plus balloon kyphoplasty with calcium phosphate for burst and severe compression lumbar fractures. *Spine*. 2008;33(6):658-67.
- Liao JC, Fan KF, Keorochana G, et al. Transpedicular grafting after short-segment pedicle instrumentation for thoracolumbar burst fracture: calcium sulfate cement versus autogenous iliac bone graft. *Spine*. 2010;35(15):1482-8.
- Zhao Y, Liu T, Zheng Y, et al. Successful percutaneous retrieval of a large pulmonary cement embolus caused by cement leakage during percutaneous vertebroplasty: case report and literature review. *Spine*. 2014;39(26):1616-21.
- Cosar M, Sasani M, Oktenoglu T, et al. The major complications of transpedicular vertebroplasty. *J Neurosurg Spine*. 2009;11(5):607-13.
- Nouda S, Tomita S, Kin A, et al. Adjacent vertebral body fracture following vertebroplasty with polymethylmethacrylate or calcium phosphate cement: biomechanical evaluation of the cadaveric spine. *Spine*. 2009;34(24):2613-8.
- Kawanabe K, Akiyama H, Onishi E, et al. Revision total hip replacement using the Kerboull acetabular reinforcement device with morsellised or bulk graft: results at a mean follow-up of 8.7 years. *J Bone Joint Surg Br*. 2007;89(1):26-31.
- Murphy RF, Glotzbecker MP, Hresko MT, et al. Allograft bone use in pediatric subaxial cervical spine fusions. *J Pediatr Orthop*. 2017;37(2):e140-4.
- Theologis AA, Tabaraee E, Lin T, et al. Type of bone graft or substitute does not affect outcome of spine fusion with instrumentation for adolescent idiopathic scoliosis. *Spine*. 2015;40(17):1345-51.
- Frankel HL, Hancock DO, Hyslop G, et al. The value of postural reduction in the initial management of closed injuries of the spine with paraplegia and tetraplegia. I. Paraplegia. 1969;7(3):179-92.
- Karapinar L, Erel N, Ozturk H, et al. Pedicle screw placement with a free hand technique in thoracolumbar spine: is it safe? *J Spinal Disord Tech*. 2008;21(1):63-7.
- Sun E, Alkalay R, Vader D, et al. Preventing distal pullout of posterior spine instrumentation in thoracic hyperkyphosis: a biomechanical analysis. *J Spinal Disord Tech*. 2009;22(4):270-7.
- Hartensuer R, Gehweiler D, Schulze M, et al. Biomechanical evaluation of combined short segment fixation and augmentation of incomplete osteoporotic burst fractures. *BMC Musculoskelet Disord*. 2013;14:360.
- Falavigna A, Righesso O, Volquind D, et al. Anterior cervical interbody fusion with hydroxyapatite graft: clinical and radiological analysis of graft breakage. *Spine*. 2009;34(25):2769-74.
- Fadulelmola A, Drampalos E, Hodgkinson J, et al. Survivorship analysis of eighty revised hip arthroplasties with the impaction grafting technique using whole femoral head allografts with the articular cartilage. *J Arthroplasty*. 2017;32(6):1970-5.
- Miller LE, Block JE. Safety and effectiveness of bone allografts in anterior cervical discectomy and fusion surgery. *Spine*. 2011;36(24):2045-50.

Spine Surgery and Related Research is an Open Access journal distributed under the Creative Commons Attribution-NonCommercial-NoDerivatives 4.0 International License. To view the details of this license, please visit (<https://creativecommons.org/licenses/by-nc-nd/4.0/>).