



Case report

Unique way of chest wall reconstruction using Integra Dermal Regeneration Template (IDRT) in a patient with post traumatic mucormycosis: A case report

Sanjay Shah^{a,*}, Pushpa Budania^b, Akshay Shah^b, Uvaish Parmar^b

^a Consultant Trauma Surgeon and Head, Emergency Department, Apollo Hospitals International Ltd, Gandhinagar, Gujarat, India

^b Dept of General Surgery, Apollo Hospitals Int Ltd, Gandhinagar, Gujarat, India

ARTICLE INFO

Keywords:

Case report
Integra Dermal Regeneration Template (IDRT)
Negative pressure wound therapy (NPWT)
Necrotizing soft tissue infection (NSTI)
Surgical debridement
Trauma

ABSTRACT

Introduction and importance: Necrotizing soft tissue infections (NSTI) are caused by toxin-producing bacteria and fungi that results in rapid progression of disease with significant local tissue destruction.

Case presentation: We present a case report of a 57-year-old male patient in line with the SCARE 2020 criteria. He was admitted to the emergency department with a small abrasion on the right antero-lateral chest wall, and a diffuse necrotic patch of skin and soft tissues with purulent discharge.

Clinical discussion: Clinical examination, routine blood investigations, CT scan chest, and chest x-ray were performed. Patient underwent debridement six times, followed by negative pressure wound therapy (NPWT). After negative culture report, Integra Meshed Dermal Regeneration Template (IMDRT), measuring 4 × 5 in. was applied and NPWT continued. The outer layer of IDRT was removed on Day 19. Split thickness skin grafting (STSG) was performed once neodermis formation was confirmed. NPWT was continued post skin grafting for a week. IDRT was successfully taken up over the raw area with exposed lung. Patient was discharged 10 days after STSG. The patient's condition improved remarkably and he was able to breathe normally. There was no puckering or tethering effect on the grafted area and not much fibrosis. He showed speedy recovery with healed donor site and 100% uptake of grafted tissue.

Conclusion: IDRT along with NPWT is an effective and useful technique for spontaneous regeneration of the dermis and basement membrane to promote wound healing in traumatic patients with NSTIs.

Level of evidence: Level V.

Study type: Therapeutic.

1. Introduction

Necrotizing soft tissue infection is defined as rapidly progressive necrosis of skin and underneath tissue, commonly arising after bacterial infection. It requires prompt, radical, and often multiple surgical debridements of all necrotic and poorly perfused tissues [1]. Fungal NSTI by zygomycetes group are fatal and associated with a high mortality especially in immune compromised patients [2]. Trauma is an important mode of acquiring the cutaneous form of disease [3,4].

The clinical diagnosis of cutaneous mucormycosis is often difficult because of non-specific findings. Tissue examination by histopathology and culture confirms the fungal infection [5]. Despite aggressive treatment with extensive surgical debridement and longer intravenous

antifungal therapy, the overall mortality rate is high especially when the chest is involved because such patients are at even greater risk for pulmonary complications [6].

For large defects of the chest and with complex wounds to cover, well vascularised tissue flaps like myocutaneous rotation, pedicle flap or free tissue transfer have been traditionally advocated [7]. Integra Dermal Regeneration Template (IDRT) is a bi-layered membrane consisting of an inner dermal substitute and an outer silicone layer which allows for immediate large tissue coverage [8]. This Integra Dermal Regeneration Template not only reduces fluids, protein and electrolyte loss but also protects from microbial invasion. Also, it reduces donor site healing time and morbidity including hypertrophic scarring as it renders to use a thinner skin graft harvest [9]. Topical negative pressure wound therapy

* Corresponding author at: Consultant Trauma Surgeon & Head, Emergency Department, Apollo Hospitals International Ltd, Gandhinagar, Gujarat, India.

E-mail address: drsanjayshah2002@yahoo.com (S. Shah).

<https://doi.org/10.1016/j.ijscr.2022.107229>

Received 4 April 2022; Received in revised form 17 May 2022; Accepted 17 May 2022

Available online 20 May 2022

2210-2612/© 2022 Published by Elsevier Ltd on behalf of IJS Publishing Group Ltd. This is an open access article under the CC BY-NC-ND license (<http://creativecommons.org/licenses/by-nc-nd/4.0/>).

(NPWT) is an effective technique to promote wound healing and the integration of skin graft and synthetic dermal equivalents [10]. To our knowledge, we are the first one reporting such a unique case all over the world, where a patient with large, pleura deep, chest wall defect who had undergone multiple debridements due to NSTI infections was successfully reconstructed with IDRT (Mesh Integra).

2. Methodology

A detailed case history and examination of the patient was performed along with the relevant investigations. Written informed consent was obtained from the patient for publication of this case report and accompanying images. This case report has been reported in line with the SCARE 2020 criteria [11] and registered at Research Registry (Unique Identifying Number: researchregistry7774 and Browse the Registry - Research Registry).

3. Case presentation

A 57-year-old man presented in the emergency department complaining with severe pain and red-purple discoloration on right side of chest wall for the last 7 days. There was a small abrasion over right chest following by a minor trauma which appeared ten days ago [Fig. 1(a)]. He was a known case of diabetes mellitus type 2 for the last 12 years and had stopped using oral hypoglycaemic agents for the last one year. He also had herpes infection 2 months ago. Five days prior to visiting us, he had undergone incision and drainage at a local hospital. His condition continued to deteriorate; hence, was referred to our tertiary care hospital. On clinical examination, the patient was found to be febrile, hypotensive, tachypnoeic and had tachycardia. Local examination revealed a diffuse, tender swelling involving the right antero-lateral chest wall, with diffuse necrotic patch of skin and soft tissues of about 18 × 15 cm with purulent discharge. The blood investigations showed a

haemoglobin level of 9.5 g/dl, a random plasma glucose level of 298 mg/dl with total leucocyte counts of 36,000 mm³ and C reactive protein level was 234. His HbA1c level was 6.9%. Computed tomography (CT) scan of chest was indicative of cellulitis and marked necrosis of the underlying muscles of right chest wall.

The patient was resuscitated with intravenous fluids and taken for emergency surgical debridement after stabilization senior Trauma Surgeon. Intraoperatively there was extensive necrosis present involving the skin, subcutaneous tissue and soft tissue over pectoralis major muscle and there was no bleeding while debriding the tissues. In view of absence of bleeding while dissection, extensive debridement was performed, and the tissue was sent for histopathology and microbiology for aerobic, anaerobic and fungal culture. However, on inspection it appeared to be a fungal infection [Fig. 1(b)].

Blood culture and sensitivity found no growth. Culture of tracheal secretions found *Acinetobacter baumannii* and *Pseudomonas aeruginosa*. The treatment was started with broad spectrum antibiotics and liposomal amphotericin B after confirmation from microbiologist with other supportive care. Since the patient was diabetic, a strict blood glucose level control was recommended throughout the treatment. After 48 h, the patient was taken for relook and repeat debridement in the operation theatre. Since the condition of the wound was worsening and all debrided area was again invaded with black necrotic tissue clearly looking like fungus, the necrosed part was removed completely including superficial layer of pectoralis major and non-adhesive dressing was applied. Tissue culture report using special staining with periodic acid Schiff was positive for few broad aseptate ribbons like fungal hyphae and also showed the presence of *Klebsiella pneumonia* [Fig. 2(a)]. Thus, the antibiotics were upgraded as per the bacterial sensitivity. Antifungal treatment was initiated after first debridement only. Since, the patient's condition was not improving so repeat (third) debridement was planned again after 24 h [Fig. 2(b)]. When the dressing was opened, a red granulation tissue was found on the periphery of the wound with a necrosed center as the infection extended to the deeper tissues, but on the periphery, it was controlled.

Post 48 h, in the fourth debridement [Fig. 3(a)], as the infection spread more deeply, a decision was made to remove the anterolateral segments of fourth to eighth ribs including intercostal muscles of respective ribs without injuring the pleura and lung. A paraffine gauze dressing was applied on the raw area to cover the tissue. It was noted that the patient's general condition started improving by this time. The dressing was again opened after 48 h to check the severity of infection; the infection was significantly controlled [Fig. 3(b)]. The culture and sensitivity test for tissue were negative for any fungal or bacterial infection. Post 72 h of the sixth debridement [Fig. 4] the floor of raw area showed healthy granulation tissue with no infection spreading. The exposed lung was covered by partially preserved (medial aspect) latissimus dorsi flap. NPWT was applied on the flap with intermittent pressure of -125 mmHg to fasten the formation of granulation tissue and neoangiogenesis. When the dressing was opened after 72 h, red granulation tissue was found on the entire wound bed except a partially necrosed small patch of latissimus dorsi flap probably due to poor blood supply and hence it was debrided.

Tissue culture of this debridement turned out to be negative so next time when the dressing was to be opened, there were two options; either performing free tissue transfer or putting an IDRT. Since the raw area was quite large, there were chances of fungal thrombosis with any residual fungal elements if a free tissue transfer flap was done, along with donor site morbidity. Therefore, the decision was made to utilize IDRT (Meshed Integra 4 × 5 in.) to cover the central aspect of the raw area where the lung was exposed and a secondary dressing of NPWT was applied all over the wound. [Fig. 5(a)] showing tissue condition just before application of IDRT and [Fig. 5(b)] showing condition of tissue post implementing IDRT. Patient was managed in the ICU for about 4 weeks and kept sedated on ventilator support for one week post-operatively. Liposomal amphotericin B continued for 4 weeks with

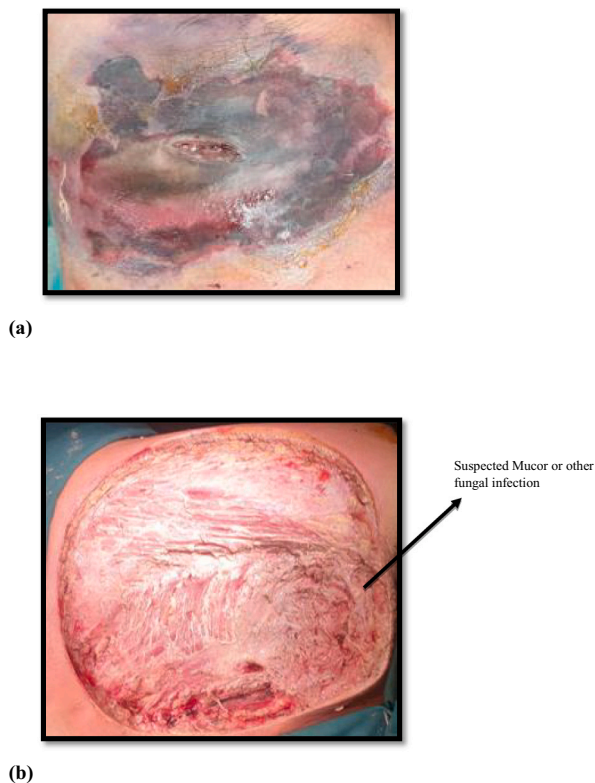
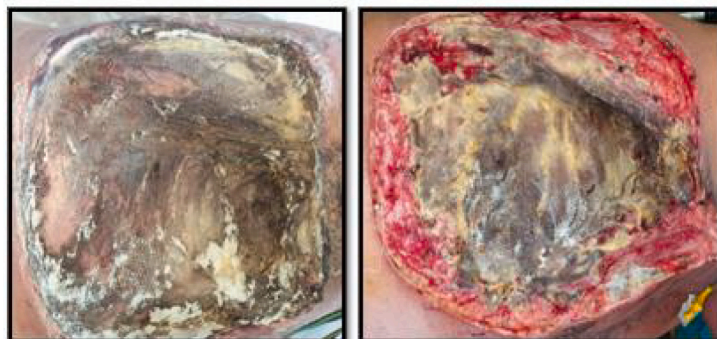

Fig. 1. (a): Patient's right chest wall view at the time of admission. (b): Post first debridement.

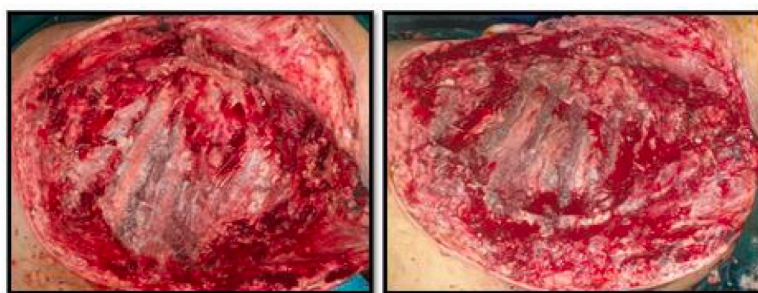


2(a): (Post 48hrs of First Debridement)

2(b): (Post 24hrs of Second Debridement):

Tissue Culture Confirmed Mucor

Fig. 2. (a): Post (48 h) first debridement: Culture confirmed.
(b): Second debridement.



3(a):(Post 24hrs of Third Debridement)

3(b) (Post 72 hrs of Fourth Debridement)

**Anterolateral Segmental excision of five ribs
without pleural injury**

Fig. 3. (a): Third debridement up to intercostal muscles.
(b): Anterolateral segmental excision of five ribs without injuring pleura.

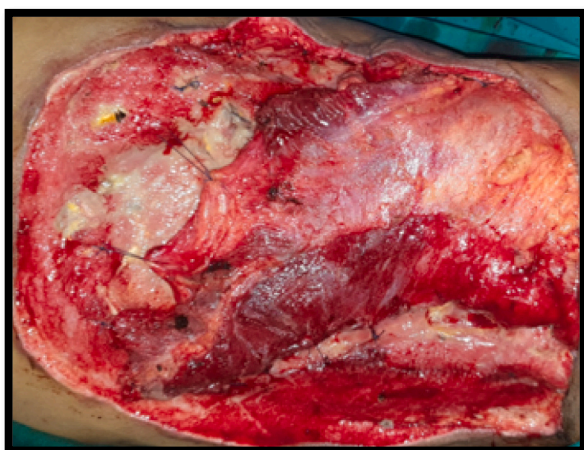

Fig. 4. Sixth debridement with local latissimus dorsi flap.

adequate hydration to prevent renal injury along with supportive management, good nutrition and physiotherapy. NPWT was done repeatedly every fifth day in operation theatre for examination under sterile condition, proper saline wash and ruling out subdermal collection. A good uptake of dermal matrix on Day 15 without any collection

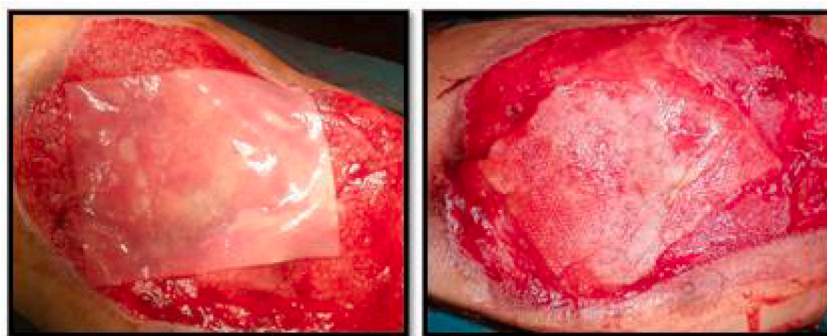was observed. The outer silicone layer of Integra Dermal Regeneration Template was removed on Day 19 and good pinkish neodermis formation was confirmed [Fig. 5(c)]. Split thickness skin graft (STSG) was harvested from thigh and applied on neodermis and surrounding raw area after meshing [Fig. 6(a)]. NPWT continued post skin grafting for a week and uptake of skin grafting was found 100% [Fig. 6(b)]. Patient was discharged 10 days post-surgery. On discharge, the patient was prescribed seven days follow up treatment. He was also given a chest belt with custom made PVC template to cover rib cage defect for prevention of injury.

The patient had a stable condition at the time of discharge. He was able to breathe normally, was able to move independently and there was not puckering or tethering effect on grafted area and not much fibrosis. At the 12-week follow up visit, a perfect skin graft uptake was observed properly healed donor site [Fig. 6(c)]. Patient was found to be compliant with the instructions given for wearing the chest belt to prevent injury externally, as observed by the well healed wound. No complications or adverse events were reported.

4. Discussion

NSTI is a common problem often encountered as an emergency, requiring urgent surgical debridement. The mortality is very high and management is especially challenging when the chest is involved, where mortality rate is often more than 89% [12].

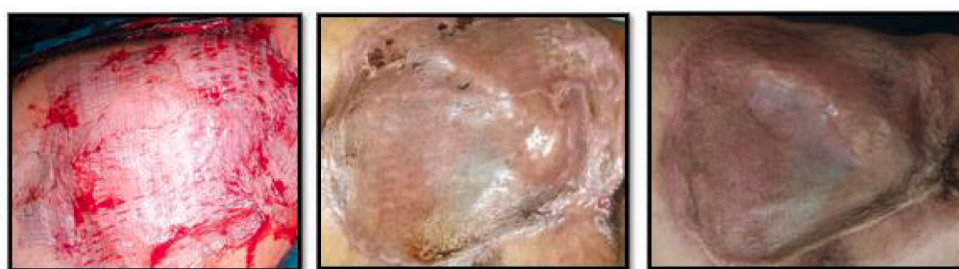Patients with suppressed immunity and with history of trauma are



5(a): Meshed IDRT (4x5 inch)

5(b): Silicon layer removed on day 19

Fig. 5. (a): Exposed lung in central area of wound with healthy granulation tissue in periphery: just before applying IDRT. (b): Post application of Integra Dermal Regeneration Template (IDRT): Meshed IDRT (4 × 5 inch). (c): Removal of silicon layer on day 19.



6(a)

6(b)

6(c)

→
Improvement Level Post STSG

Fig. 6. (a): Split Thickening Skin Grafting (STSG). (b): Tissue condition on day 14 post STSG. (c): Healed wound on follow up at 12 weeks.

more prone to develop cutaneous fungal infections [13]. Zygomycetes fungi are commonly found in the soil. These invasive organisms implant in the skin after trauma, invade and proliferate in the blood vessels and damage them causing necrosis of the surrounding tissue [14,15].

Occurrence of cutaneous necrotizing mucormycosis is a suspicion for clinical diagnosis [16].

Its aggressive nature demands prompt surgical debridement in combination with appropriate antifungal therapy, resuscitation, nutritional support and wound care to limit the extent of soft tissue loss to salvage the patient [17].

Hemodynamic instability usually persists postoperatively. Infectious spread, hypotension along with massive fluid and protein loss causes progressive soft tissue necrosis, so affected patients must return for further debridements as often as necessary [18].

Once all necrotic tissue is debrided and the patient gets stabilized, soft tissue reconstruction should be considered. Traditionally, if primary closure is not possible reconstruction should be performed with skin grafts and myocutaneous flaps. Soft tissue defects resulted from extensive debridement are often massive so autograft reconstruction may be restricted by limited donor-site availability or questionable underlying wound bed viability.

Since in the present case, the defect was large, complex and tissue culture were sterile; IDRT implantation was chosen to fill the defect instead of free tissue transfer. The option of free tissue transfer was kept reserved in case if Integra Dermal Regeneration Template did not work.

A bi-layered IDRT is a membrane system, consisting of an inner dermal substitute layer composed of a 3-dimensional matrix of cross-

linked bovine tendon collagen plus a glycosaminoglycan and a temporary outer epidermal substance layer composed of silicone [19]. After application, the patient's native lymphocytes, fibroblasts and macrophages infiltrate, and new capillary growth occurs into the matrix of the inner layer. As the inner layer degrades, an endogenous collagen matrix is deposited by the patient's own fibroblasts, forming a 'neodermis'. The outer silicone layer needs to be removed and epidermal autograft must be placed on the 'neodermis' once engraftment is complete. This dermal matrix allows immediate tissue coverage to reduce fluid and electrolyte loss, protection from microbial invasion, less painful wound care, thinner autograft requirement so decreased donor site morbidity and healing time with less hypertrophic scarring [20]. Active secondary wound infection is a contraindication to the dermal template use as it prevents neodermis formation. Our patient underwent successful neodermis formation requiring a thin skin graft just for epidermal coverage without any donor wound site complications.

5. Conclusion

Fungal NSTI of the chest wall poses a serious challenge to clinicians, not only for the appropriate early diagnosis and aggressive management of the disease, but also due to the difficult reconstruction of the soft tissue defect after management of the initial insult to the tissue. This case report showed that the IDRT offers the advantages of neodermis formation without the risks of pedicle flap or free tissue transfer in a patient with an exposed lung. Therefore, IDRT may show better patient outcomes in patients with large soft tissue defects, patients with failed

myocutaneous flaps and in those indicated for free tissue transfer as a last resort.

Sources of funding

None.

Ethical approval

Ethics clearance is not required as proper written informed consent was obtained from the patient and no personal details of the patient were revealed.

Consent

Not applicable as patient's identity was not revealed.

Author contribution

Dr Sanjay Shah: Main author, conceived and designed, wrote paper

Dr Pushpa Budania: collected data

Dr Akshay Shah: analysed data

Dr Uvaish Parmar: wrote paper

Research registration number

1. Name of the registry: Unique way of Chest Wall Reconstruction using Integra Dermal Regeneration Template (IDRT) in a Case of Post Traumatic Mucormycosis.
2. Unique identifying number or registration ID: researchregistry7774.
3. Hyperlink to your specific registration (must be publicly accessible and will be checked): [Browse the Registry - Research Registry](#).

Guarantor

Dr. Sanjay Shah.

Declaration of competing interest

The authors declare no conflict of interest.

Acknowledgements

The authors acknowledge Knowledge Isotopes Pvt. Ltd. (www.knowledgeisotopes.com) for the medical writing support provided for the manuscript.

Provenance and peer review

Not commissioned, externally peer-reviewed.

References

- [1] B. Sarani, M. Strong, J. Pascual, C.W. Schwab, Necrotizing fasciitis: current concepts and review of the literature, *J. Am. Coll. Surg.* 208 (2) (2009) 279–288.
- [2] M.L.S. Narayanan, C. Narayanan, A.J. Kindo, A. Arora, P.A. Haridas, Fatal fungal infection: the living dead, *J. Surg. Case Rep.* 2014 (10) (2014).
- [3] B. Spellberg, J. Edwards, A. Ibrahim, Novel perspectives on mucormycosis: pathophysiology, presentation, and management, *Clin. Microbiol. Rev.* 18 (3) (2005) 556–569.
- [4] D. Andresen, A. Donaldson, L. Choo, A. Knox, M. Klaassen, C. Ursic, et al., Multifocal cutaneous mucormycosis complicating polymicrobial wound infections in a tsunami survivor from Sri Lanka, *Lancet* 365 (9462) (2005) 876–878.
- [5] M. Arnáiz-García, D. Alonso-Pena, González-Vela M. del Carmen, J. García-Palomo, J. Sanz-Giménez-Rico, A. Arnáiz-García, Cutaneous mucormycosis: report of five cases and review of the literature, *J. Plast. Reconstr. Aesthet. Surg.* 62 (11) (2009) e434–e441.
- [6] J.D. Urschel, H. Takita, J.G. Antkowiak, Necrotizing soft tissue infections of the chest wall, *Ann. Thorac. Surg.* 64 (1) (1997) 276–279.
- [7] M. Cohen, S.S. Ramasastry, Reconstruction of complex chest wall defects, *Am. J. Surg.* 172 (1) (1996) 35–40.
- [8] E.J. Goldstein, D.A. Anaya, E.P. Dellinger, Necrotizing soft-tissue infection: diagnosis and management, *Clin. Infect. Dis.* 44 (5) (2007) 705–710.
- [9] P. Chang, B. Guo, Q. Hui, X. Liu, K. Tao, A bioartificial dermal regeneration template promotes skin cell proliferation in vitro and enhances large skin wound healing in vivo, *Oncotarget* 8 (15) (2017) 25226.
- [10] C. Baldwin, M. Potter, E. Clayton, L. Irvine, J. Dye, Topical negative pressure stimulates endothelial migration and proliferation: a suggested mechanism for improved integration of Integra, *Ann. Plast. Surg.* 62 (1) (2009) 92–96.
- [11] R.A. Agha, T. Franchi, C. Sohrabi, G. Mathew, A. Kerwan, A. Thoma, et al., The SCARE 2020 guideline: updating consensus Surgical CAse REport (SCARE) guidelines, *Int. J. Surg.* 84 (2020) 226–230.
- [12] J.D. U, Necrotizing soft tissue infections, *Postgrad. Med. J.* 75 (1999) 645–649.
- [13] J. Chander, J. Kaur, A. Attri, H. Mohan, Primary cutaneous zygomycosis from a tertiary care centre in north-west India, *Indian J. Med. Res.* 131 (6) (2010).
- [14] A. Diwakar, R. Dewan, A. Chowdhary, H. Randhawa, G. Khanna, S. Gaur, Zygomycosis—a case report and overview of the disease in India, *Mycoses* 50 (4) (2007) 247–254.
- [15] S. Hajdu, A. Obradovic, E. Presterl, V. Vecsei, Invasive mycoses following trauma, *Injury* 40 (5) (2009) 548–554.
- [16] S.T. Lille, T.T. Sato, L.H. Engrav, H. Foy, G.J. Jurkovich, Necrotizing soft tissue infections: obstacles in diagnosis, *J. Am. Coll. Surg.* 182 (1) (1996) 7–11.
- [17] A. Korzets, E. Cohen, I. Zahavi, Clinical problem-solving: necrotizing fasciitis, *N. Engl. J. Med.* 331 (4) (1994) 279–280.
- [18] L.A. Sudarsky, J.C. Laschinger, G.F. Coppa, F.C. Spencer, Improved results from a standardized approach in treating patients with necrotizing fasciitis, *Ann. Surg.* 206 (5) (1987) 661.
- [19] G. Phillips, M. Nizamoglu, A. Wakure, D. Barnes, N. El-Muttardi, P. Dzielwski, The use of dermal regeneration templates for primary burns surgery in a UK regional burns centre, *Ann. Burns Fire Disasters* 33 (3) (2020) 245.
- [20] O.M. Rashid, M. Nagahashi, K. Takabe, Management of massive soft tissue defects: the use of INTEGRA® artificial skin after necrotizing soft tissue infection of the chest, *J. Thorac. Dis.* 4 (3) (2012) 331.