

First case of deep neck and descending mediastinal abscess caused by dentoalveolar *Eggerthia catenaformis* infection

ABSTRACT

Descending mediastinal abscesses arising from oral (dental or peritonsillar abscess) or deep neck infections (DNIs) often become fatal without surgical drainage. Odontogenic origin was the most common cause of DNIs. We report the first clinical case of a patient with descending mediastinal abscess caused by DNI from *Eggerthia catenaformis* a Gram-positive anaerobic rod that can be rarely a human pathogen. The patient underwent the extraction of carious molars, cervical and thoracic surgical drainage, and targeted antibiotic therapy with resolution of the infection.

Keywords: Anaerobic bacteria, deep neck infection, *Eggerthia catenaformis*, mediastinitis, odontogenic infection

INTRODUCTION

In 1935, microbiologists isolated a new species of Gram-positive, spore-forming bacteria from human feces called *Lactobacillus catenaformis*.^[1] This bacterium, reclassified as *Eggerthia catenaformis* in 2011, based on 16S rRNA gene sequencing, was later isolated from intestinal and pleural infections.^[2] Recently, a second draft genome sequence of *E. catenaformis* has shown that this strain can be a human pathogen, and two patients with dental abscesses and one with a lung abscess and pleura empyema have been described.^[3-5]

We present an interesting case of DNI and descending mediastinitis complicating an isolated *E. catenaformis* odontogenic infection and which was successfully treated in our hospital. The patient gave consent for her radiological images and clinical information to be reported in a journal.

CASE REPORT

A 61-year-old immunocompetent Russian woman was admitted to the ENT department for severe right submandibular nonfluctuant swelling and mild trismus. These

symptoms were preceded by a 2-week history of infection in the right second and third mandibular molars (4.7 and 4.8 according to the Federation Dentaire Internationale World Dental Federation notation) treated with 6 days of amoxicillin 1 g BID, but with minimal improvement in the clinical picture.

Physical examination revealed dental caries in teeth 4.7 and 4.8 and swelling of the mouth floor.

Temperature on admission was 39.1°C, total leukocyte count was $18.1 \times 10^6/\text{mL}$ (reference: $3.5\text{--}8.5 \times 10^6/\text{mL}$), and C-reactive protein was 2.19 mg/dL (reference: $<0.3 \text{ mg/dL}$). A neck and chest computed tomography (CT) scan with

**STEFANIA GALASSI, ROBERTO MERANDA¹,
JACOPO CAMBI², SANTE DE SANTIS¹**

Departments of Interventional Radiology and ¹ENT, Cosenza SS. Annunziata Hospital, Cosenza, ²Department of ENT, Grosseto Misericordia Hospital, Grosseto, Italy


Address for correspondence: Dr. Jacopo Cambi, Via Senese 161, Grosseto 58100, Italy. E-mail: ishajacopo@hotmail.it

Received: 10 September 2021, **Revised:** 04 October 2021, **Accepted:** 12 November 2021, **Published:** 20 April 2022

This is an open access journal, and articles are distributed under the terms of the Creative Commons Attribution-NonCommercial-ShareAlike 4.0 License, which allows others to remix, tweak, and build upon the work non-commercially, as long as appropriate credit is given and the new creations are licensed under the identical terms.

For reprints contact: WKHLRPMedknow_reprints@wolterskluwer.com

How to cite this article: Galassi S, Meranda R, Cambi J, De Santis S. First case of deep neck and descending mediastinal abscess caused by dentoalveolar *Eggerthia catenaformis* infection. *Natl J Maxillofac Surg* 2022;13:111-3.

Access this article online	
Website: www.njms.in	Quick Response Code 
DOI: 10.4103/njms.njms_463_21	

intravenous contrast demonstrated an extensive abscess in the parapharyngeal and neck space on the right side with the left displacement of the larynx and trachea, but without superior mediastinum involvement [Figure 1]. The initial diagnosis was a cervical and mouth abscess with an odontogenic origin.

Acute surgical drainage of a right neck abscess, extraction of carious molars (teeth 4.6, 4.7, and 4.8), and tracheostomy were performed under general anesthesia. The abscess fluid was drained and sent to the microbiology laboratory for culture. At the same time, empirical therapy with intravenous ceftriaxone (1 g BID) and metronidazole (500 mg TID) was initiated.

On postoperative day 4, the patient's condition deteriorated with chest pain and tachypnea. An additional CT scan [Figure 2] showed a new abscess in the anterior superior mediastinal space and initial thrombosis of the jugular vein. An urgent right thoracotomy was performed with positioning of a Jackson-Pratt drainage tube.

Fluid abscess cultures from the neck and mediastinum revealed the presence of *E. cateniformis* and *Streptococcus constellatus*. After determination of the minimum inhibitory concentration [MIC; Table 1], antibiotic therapy was modified with the introduction of clindamycin (900 mg TID) for a total duration of 7 days.

In the following days, the patient gradually improved [Figure 3], the cervical drainage tube was removed on the 6th day and mediastinal drainage after 7 days. The patient was discharged on the 15th day with normal clinical and laboratory findings. At 3 months of follow-up, the patient had completely recovered.

DISCUSSION

Descending mediastinal abscesses usually arise from oral (dental or peritonsillar abscess) or neck infections and often become fatal without surgical drainage if the infection and inflammation spread widely in the mediastinum. This disease has become generally uncommon since the introduction of antibiotic therapy decades ago. Early surgical mediastinal drainage is strongly recommended to reduce the risk of mortality.^[6] Odontogenic infections are usually localized and remain confined to the oral cavity if treated early with antibiotherapy, dental treatment, extraction, incision, or drainage. However, odontogenic infections traveling through the fascial plane of the neck can spread into the mediastinum. The risk of this increase is in the case of poor oral hygiene, diabetes, or immunodeficiency. Most

studies report that men are affected more often by severe odontogenic infections than women.^[7,8]

In a recent retrospective analysis, an odontogenic origin was the most common cause of DNIs.^[9] Our patient had poor oral hygiene and was malnourished. She had several untreated tooth infections which involved the second and third mandibular molars with apical infection. We hypothesized that the recent low dose amoxicillin treatment may have selected *E. cateniformis* infection. This may explain the rapid downward spread of the infectious

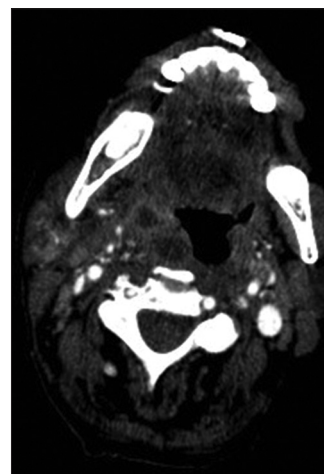


Figure 1: Computed tomography axial projection of the oropharynx shows an abscess in the right parapharyngeal space

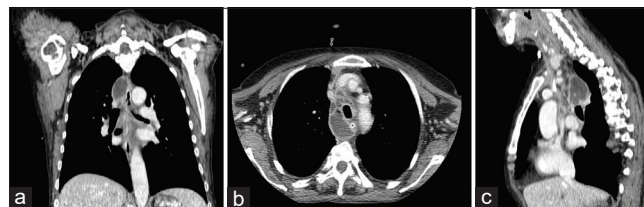


Figure 2: Chest computed tomography on the 4th day; abscesses were located in the upper mediastinal space and in the right paraesophageal and paratracheal spaces. (a) Coronal projection; (b) Axial projection; (c) Sagittal projection

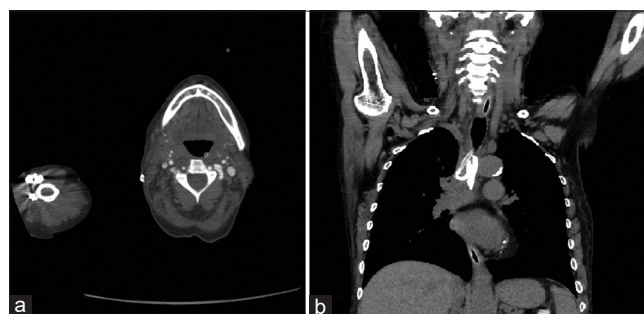

Figure 3: Neck and chest computed tomography after thoracotomy on the 6th day; (a) Axial projection of head-and-neck with volume reduction of the right laterocervical abscess (b) coronal projection of the chest with mediastinal drainage and the volumetric reduction of the mediastinal abscess

Table 1: Antimicrobial sensitivity with minimum inhibitory concentration

Antimicrobial agent	<i>Eggerthia cateniformis</i>		<i>Streptococcus constellatus</i>	
	MIC ($\mu\text{g/mL}$)	Interpretation	MIC ($\mu\text{g/mL}$)	Interpretation
Amoxicillin-clavulanate	<8	Sensitive	<8	Sensitive
Amoxicillin	<4	Sensitive	<8	Sensitive
Clindamycin	<0.25	Sensitive	<0.25	Sensitive
Piperacillin/tazobactam	<8	Sensitive	<0.25	Sensitive
Benzylpenicillin	<0.25	Sensitive	<1	Sensitive
Imipenem	<2	Sensitive	<1	Sensitive
Vancomycin	<2	Sensitive	<2	Sensitive
Imipenem	<2	Sensitive	<2	Sensitive

MIC: Minimum inhibitory concentration

process that had involved a large part of the neck and anterior mediastinum. In accordance with previous studies, we advocate broad-spectrum antibiotics in combination with early and aggressive cervical and superior mediastinal drainage. If the airways are compressed, temporary tracheostomy is the procedure of choice.^[10]

E. cateniformis, whose natural habitat is human feces, has only recently been associated with infections in humans.^[4,5] In our case, the isolated *E. cateniformis* strain was multisensitive, but it had a moderately high MIC value for amoxicillin-clavulanate. The best MIC value was for clindamycin and benzylpenicillin.

CONCLUSION

E. cateniformis may cause severe infections in association with other microorganisms. Combined treatment with intravenous antibiotics and surgery was effective.

Odontogenic infection should be considered a risk factor for descending mediastinal abscess. Dental practitioners should be aware that early diagnosis and aggressive management are required to reduce the morbidity and mortality of the disease. Despite the high mortality rate associated with this condition, prompt diagnosis, aggressive drainage, removal of the source of infection, and careful postoperative care can save patients with descending mediastinal abscesses.

This report also indicates that an accurate and rapid identification of unusual bacterial species can help with faster, more aggressive, and more appropriate antibiotic therapy.

Declaration of patient consent

The authors certify that they have obtained all appropriate patient consent forms. In the form, the patient has given her consent for her images and other clinical information

to be reported in the journal. The patient understands that her name and initial will not be published and due efforts will be made to conceal her identity, but anonymity cannot be guaranteed.

Financial support and sponsorship

Nil.

Conflicts of interest

There are no conflicts of interest.

REFERENCES

1. Eggerth AH. The gram-positive non-spore-bearing anaerobic bacilli of human feces. *J Bacteriol* 1935;30:277-99.
2. Salvetti E, Felis GE, Dellaglio F, Castioni A, Torriani S, Lawson PA. Reclassification of *Lactobacillus cateniformis* (Eggerth 1935) Moore and Holdeman 1970 and *Lactobacillus vitulinus* sharpe *et al.* 1973 as *Eggerthia cateniformis* gen. nov., comb. nov. and *Kandleria vitulina* gen. nov., comb. nov., respectively. *Int J Syst Evol Microbiol* 2011;61:2520-4.
3. Kordjian HH, Schultz JD, Rosenvinge FS, Møller J, Pedersen RM. First clinical description of *Eggerthia cateniformis* bacteremia in a patient with dental abscess. *Anaerobe* 2015;35:38-40.
4. Foronda C, Calatrava E, Casanovas I, Martín-Hita L, Navarro-Marí JM, Cobo F. *Eggerthia cateniformis* bacteremia in a patient with an odontogenic abscess. *Anaerobe* 2019;57:115-6.
5. Dupont P, Miltgen G, Kebbabi C, Belmonte O, Coolen-Allou N, Allyn J, *et al.* First case of pleural empyema and pulmonary abscess caused by *Eggerthia cateniformis*. *Anaerobe* 2018;50:9-11.
6. Corsten MJ, Shamji FM, Odell PF, Frederico JA, Laframboise GG, Reid KR, *et al.* Optimal treatment of descending necrotizing mediastinitis. *Thorax* 1997;52:702-8.
7. Alegbeleye BJ. Deep neck infection and descending mediastinitis as lethal complications of dentoalveolar infection: Two rare case reports. *J Med Case Rep* 2018;12:195.
8. Sancho LM, Minamoto H, Fernandez A, Sennes LU, Jatene FB. Descending necrotizing mediastinitis: A retrospective surgical experience. *Eur J Cardiothorac Surg* 1999;16:200-5.
9. Velhonoja J, Lääveri M, Soukka T, Irjala H, Kinnunen I. Deep neck space infections: An upward trend and changing characteristics. *Eur Arch Otorhinolaryngol* 2020;277:863-72.
10. Mihos P, Potaris K, Gakidis I, Papadakis D, Rallis G. Management of descending necrotizing mediastinitis. *J Oral Maxillofac Surg* 2004;62:966-72.