

What Does “Dr. Google” Show Patients Searching for Breast Reconstruction Outcomes Photographs?

Krista M. Nicklaus, PhD*†

Xiomara T. Gonzalez, BS‡

Koushalya Sachdev, BBA*

Jun Liu, PhD†

Deepthi Chopra, MBBS, MPH§

Aubri S. Hoffman, PhD¶

Summer E. Hanson, MD, PhD||

Mia K. Markey, PhD***

Gregory P. Reece, MD†

Background: Many women with breast cancer search the internet for photographs of their potential reconstruction outcomes, but little is known about the quality, variety, and relevance of images patients are viewing.

Methods: Breast reconstruction outcome photographs identified by a Google Images search were assessed based on the American Society of Plastic Surgeons/Plastic Surgery Foundation photographic guidelines. Information such as source metadata, breast reconstruction procedure information, and subject demographics was collected from the photographs. Additional analyses were conducted to assess whether nipple reconstruction or tattooing occurred and was disclosed, whether a symmetry procedure was performed and disclosed, and whether donor site scarring is visible in abdominal flap photographs.

Results: We acquired and analyzed 114 photograph sets. Although a variety of images were readily available, the majority of photograph sets did not follow photographic guidelines or provide sufficient information. Most photograph sets (60%) indicated symmetry procedures when a symmetry procedure was evident, but only 40% of photograph sets disclosed a nipple procedure when a nipple procedure was evident. Only 40% of abdominal flap photographs showed donor site scarring. Subject demographics were largely missing: 50% of photograph sets included subject age, 3% included race or ethnicity, and 12% included weight or BMI.

Conclusions: Although breast reconstruction outcome photographs shown by “Dr. Google” represent a variety of reconstruction types, they typically lack information that a patient needs to assess self-applicability. Patients may benefit from discussion with their healthcare team about the strengths and limitations of breast reconstruction outcome photographs available on the internet. (*Plast Reconstr Surg Glob Open* 2022;10:e4331; doi: [10.1097/GOX.0000000000004331](https://doi.org/10.1097/GOX.0000000000004331); Published online 16 May 2022.)

From the *Department of Biomedical Engineering, The University of Texas at Austin, Austin, Tex.; †Department of Plastic Surgery, The University of Texas MD Anderson Cancer Center, Houston, Tex.; ‡Department of Electrical and Computer Engineering, The University of Texas at Austin, Austin, Tex.; §Department of Psychiatry, The University of Texas MD Anderson Cancer Center, Houston, Tex.; ¶The Value Institute for Health and Care, Dell Medical School, The University of Texas at Austin, Austin, Tex.; ||Section of Plastic and Reconstructive Surgery, University of Chicago Medicine and Biological Sciences; Chicago, Ill.; and ***Department of Imaging Physics, The University of Texas MD Anderson Cancer Center, Houston, Tex.

Received for publication January 13, 2022; accepted March 30, 2022.

Presented at 65th Annual Meeting of Plastic Surgery Research Council, 2020.

Copyright © 2022 The Authors. Published by Wolters Kluwer Health, Inc. on behalf of The American Society of Plastic Surgeons. This is an open-access article distributed under the terms of the [Creative Commons Attribution-Non Commercial-No Derivatives License 4.0 \(CCBY-NC-ND\)](https://creativecommons.org/licenses/by-nc-nd/4.0/), where it is permissible to download and share the work provided it is properly cited. The work cannot be changed in any way or used commercially without permission from the journal.

DOI: [10.1097/GOX.0000000000004331](https://doi.org/10.1097/GOX.0000000000004331)

INTRODUCTION

Breast cancer patients actively consult online resources throughout their care.^{1–5} The internet is the second-most-frequently-cited source of information, after written material provided by physicians.² Over 90% of adults in the United States—regardless of age, affluence, or education—use the internet.⁶ Google is the most preferred search engine for health inquiries, engendering the term, “Dr. Google.”^{7–10} Breast cancer patients report viewing content from national cancer organizations, medical centers, and the government,^{1,2,11,12} and using the internet to search for information about breast reconstruction.^{4,13,14} Nguyen et al found that 100% of breast reconstruction patients surveyed from an American medical institution had internet access, and 95% of them had conducted searches on breast reconstruction, with the majority using the Google search engine.¹⁵ Patients consider the internet

Disclosure: The authors have no financial interest to declare in relation to the content of this article. This work was supported by U.S. National Institutes of Health grant R01CA203984, The University of Texas Dell Medical School, and the Livestrong Foundation.

to be an influential, helpful, and trustworthy source of breast reconstruction information.^{13,15}

Preoperative information and realistic expectations are key factors in breast reconstruction patients' postoperative satisfaction and psychosocial functioning.^{16–18} Unexpected appearance outcomes can impact body image, decision regret, and mental health.^{19,20} Breast reconstruction patients report dissatisfaction with the extent of information provided preoperatively by their surgeons regarding postoperative surgical care and possible complications.^{20–24} Women often feel unprepared for appearance-related changes, including nipple disfigurement, breast asymmetry, and donor site scarring.^{14,18,20,21,25,26} Only about half of women recall their healthcare team showing them photographs of possible breast reconstruction outcomes,²⁷ and they are often unsatisfied with the representation of body types, skin tone, range of outcomes, and viewing time when provided photographs.^{23,27,28} Thus, it is not surprising that breast reconstruction patients search the internet for photographs of reconstruction outcomes.^{13,15,24,27} It is vital to understand what the breast reconstruction photographs found on the internet communicate to patients because patients may expect to look like the women in the photographs.²⁰

Prior studies investigated the sources and quality of written information about breast reconstruction available on the internet.^{29–33} Studies of online images of breast augmentation, abdominoplasty, and rhinoplasty outcomes found that adherence rates to photographic guidelines set by the American Society of Plastic Surgeons and the Plastic Surgery Foundation (ASPS/PSF) vary widely, and a particular concern is photograph framing.^{34,35} In contrast, there are no prior studies on the quality of breast reconstruction photographs publicly available online.

We therefore investigated breast reconstruction outcomes photographs and accompanying information found through a Google Images search. In addition to evaluating the quality of the photographs on the basis of the ASPS/PSF photographic guidelines, we assessed them with respect to the information provided about three aspects of breast reconstruction that prior studies have commonly identified as unclear or inadequately explained to patients: timing of nipple-areola revision procedures, option of contralateral procedures to achieve symmetry, and extent of scarring.

METHODS

Google Images Search

Google Images searches were performed from June through July 2019. A variety of breast-reconstruction-related search terms were explored, then five terms were chosen that yielded the least overlap of unique photographs in the top search results. Private browsing mode was used to ensure that search history and local data (ie, cookies) associated with prior browsing did not influence results.

Sets of photographs of breast reconstruction outcomes and accompanying text were evaluated. All sets

Takeaways

Question: What is the quality, variety, and relevance of photographs of breast reconstruction outcomes shown by “Dr. Google?”

Findings: Google Images searches for photographs of breast reconstruction outcomes reveal a variety of diverse reconstructive approaches. Few photographs followed the ASPS photographic guidelines. Many photographs were missing key information necessary for patients to determine applicability to their own situation. Viewing photographs of breast reconstruction outcomes from a Google Images search is unlikely to mitigate common misconceptions about breast reconstruction.

Meaning: Patients may benefit from discussions with their healthcare team about the strengths and limitations of breast reconstruction outcomes photographs available on the internet.

included in the study had at least one photograph, and all photographs in the set were of human patients. Some photograph sets contained more than one photograph because the patient was posed in different positions and/or at different stages of their reconstruction. Sets that included animated content or illustrations of simulated reconstruction outcomes were excluded. Photograph sets were collected until saturation; that is, a search was terminated when it did not yield previously unseen photographs. If a photograph from the results page linked to a gallery with additional photographs of the same or a distinct patient(s), the gallery photographs were assessed separately for each patient if (1) the link to the gallery was apparent on the landing page, and (2) the photograph from Google Images was included in the gallery.

Photograph Set Database Schema

Metadata, breast reconstruction procedure, and patient demographics and anthropometrics were recorded (Table 1). Metadata consisted of pertinent information about the search, leading to a photograph set and the sources of the photographs. Sources were classified as blog, individual hospital, private practice (individual and group), government body, magazine, non-profit organization, for-profit company, or scientific literature. Breast reconstruction procedure information and the medical history disclosed with the photograph sets were documented. Patient age, race and/or ethnicity, and weight or body mass index (BMI) were recorded if available.

ASPS/PSF Photographic Guidelines

Photographs were reviewed with respect to the pre- and postoperative photographic guidelines of the ASPS/PSF (Fig. 1, Table 2).³⁶ The “abdominal flap” guidelines were considered when the information associated with the photograph set indicated that an autologous reconstruction procedure was performed. Photograph sets of patients who underwent an implant-based reconstruction were examined using the “breasts” guidelines. If the type of reconstruction was not stated, we inferred the

Table 1. Information Recorded from Photograph Sets

Information Type	
Metadata	<ul style="list-style-type: none"> • Search term • Website URL • Date of website access by researchers • Source classification [blog, individual hospital, private practice (individual and group), government body, magazine, non-profit organization, for-profit company, or scientific literature]
Procedural	<ul style="list-style-type: none"> • No. photographs in photograph set • Type of breast reconstruction • No. photographs for each stage (premastectomy, postmastectomy, postreconstruction) • Immediate or delayed reconstruction (relative to mastectomy) • Breast implant or flap size (if applicable) • Postsurgical cup size (if disclosed)
Demographic	<ul style="list-style-type: none"> • Age • Race • Ethnicity • Weight and body mass index (BMI)

procedure from the photograph set. For our evaluation of photograph framing, we note that for breast photographs, the target anatomy spans from the top of the

clavicles to the mid-epigastrium, and for abdominal flap photographs it extends to approximately the mid-thigh. Camera positioning was not considered in our analysis because camera-to-patient distance, magnification, and angling could not be reliably inferred from the search results. Our assessment was extensive, but not exhaustive; for example, other factors such as lighting may also affect one’s ability to accurately interpret a photograph.

Clarity of Reported Breast Reconstruction Procedures

Information about the breast reconstruction procedures depicted in a photograph set provides a patient with context to evaluate the applicability of the photograph set to her own situation. We reviewed the photographs to assess if the disclosed reconstruction was plausible, independent of any other text or caption associated with the photograph set. In cases where the procedure listed was not clearly consistent with the photographic evidence, we documented our observations, such as breast shape or volume not being consistent with the procedure disclosed, or the target anatomy not being captured adequately to see relevant scarring.

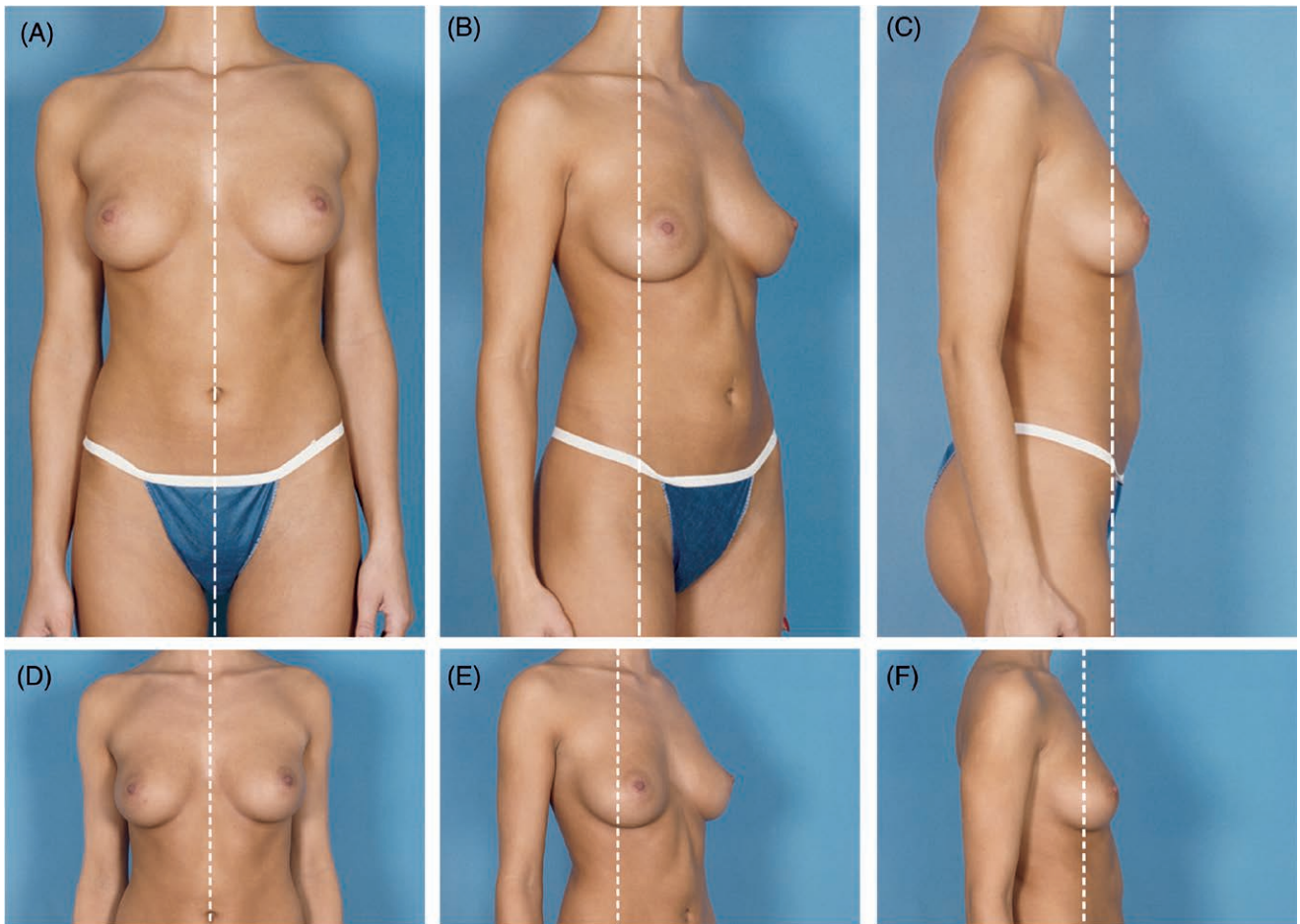


Fig. 1. Representative sample photographs illustrating the ASPS/PSF standard photographic views. Views for abdominal flap procedures: (A) frontal; (B) oblique; (C) lateral. Views for breast procedures: (D) frontal; (E) oblique; (F) lateral. Reproduced with permission from the American Society of Plastic Surgeons for Photographic Guidelines in Plastic Surgery 2019 version. ©All rights reserved.

Table 2. ASPS/PSF Abdominal Flap and Breast Guidelines

	Abdominal Flap	Breasts
Photograph framing	<ul style="list-style-type: none"> • Position clavicles at top of frame • Frontal and oblique views—center torso horizontally • Lateral views—center mass of proximal breast horizontally 	<ul style="list-style-type: none"> • Position clavicles at top of frame • Frontal and oblique views—center torso horizontally • Lateral views—center mass of proximal breast horizontally
Patient positioning	<ul style="list-style-type: none"> • Patient standing comfortably erect with arms at sides • Feet aligned with appropriate tape marks on floor • Oblique views—distal arm should be moved back slightly 	<ul style="list-style-type: none"> • Patient standing comfortably erect with arms at sides • Feet aligned with appropriate tape marks on floor • Oblique views—distal arm should be moved back slightly
Patient preparation	<ul style="list-style-type: none"> • Remove any visible jewelry • Remove gown completely • Patient should wear a photograph garment 	<ul style="list-style-type: none"> • Patient disrobed above the waist • Remove any visible jewelry
Camera positioning	<ul style="list-style-type: none"> • Camera height adjusted to match height of target area • Lens barrel parallel to floor to avoid tilting when framing an image 	<ul style="list-style-type: none"> • Camera height adjusted to match height of target area • Lens barrel parallel to floor to avoid tilting when framing an image

Number of Photographs Per Subject and Photograph Timing Information

The number of photographs for each set was recorded. Photographs were categorized as prereconstruction and postreconstruction. We also noted whether the prereconstruction photographs were representative of patients with native breasts, patients at the postmastectomy or lumpectomy stage, or patients who had undergone breast reconstruction and were seeking a revision procedure.

Considering Common Misconceptions about Breast Reconstruction

We reviewed the photographs with respect to three aspects of breast reconstruction that prior studies have identified as unclear or inadequately explained to patients. (1) Some women do not understand that nipple-areola reconstruction and nipple tattooing are separate procedures that typically are not done until at least a few months after the initial breast reconstruction.^{26,37} Therefore, we reviewed each photograph set to assess whether supplementary procedures had been performed to provide the appearance of a nipple and whether this information was clearly disclosed with the photograph set. (2) Some women who undergo unilateral mastectomy do not anticipate that additional procedures on the contralateral breast are typically required to mitigate asymmetry between the breast mounds.^{14,18,20,25,26} Therefore, we reviewed each photograph set to assess whether symmetry procedures had been performed and whether this information was clearly disclosed. (3) Patients who choose an autologous reconstruction can have many misconceptions about the postoperative shape, size, and maturation of donor site scarring.^{14,18,20,21} Accordingly, scarring visibility in the photograph sets of abdominal flap reconstructions was surveyed.

RESULTS

Image Search

In total, 114 photograph sets of breast reconstruction outcomes were retrieved from Google Images searches using five terms: “breast reconstruction surgery,” “breast reconstruction following mastectomy,” “autologous breast reconstruction,” “breast implant reconstruction,” and

“DIEP flap reconstruction.” Most of the photograph sets (80%) were found using two general reconstruction search terms: “breast reconstruction surgery” and “breast reconstruction following mastectomy.” The other photograph sets were identified using queries focused on a specific type of reconstruction procedure: “DIEP flap reconstruction” (12%), “autologous breast reconstruction” (4%), and “breast implant reconstruction” (4%).

Sources of Photograph Sets

The majority of the photograph sets (67/114 = 59%) were from private practice websites (Figure 2). Of these, most came from individual private practices (55/67 = 82%) as opposed to group practices (18%). Scientific literature contributed 28 of 114 (24%) of the photograph sets. Almost all of these (27/28) originated from peer-reviewed journals; one was in an open-access book. Three journal articles required a license to access the complete publication but provided public access to the figures (eg, the outcome photographs and captions).

Distribution of Breast Reconstruction Procedures

A variety of breast reconstruction procedures were represented in the photograph sets, including autologous procedures that used one or multiple tissue donor sites (45/114 = 39%); implant-based reconstructions (30/114 = 26%); external vacuum expansion (EVE) and autologous fat transfer (AFT) (12/114 = 11%); and combined autologous and implant reconstruction procedures (4/114 = 4%). The remaining 23 photograph sets (20%) did not specify the type of procedure performed.

Adherence to Abdominal Flap ASPS/PSF Guidelines

Of the 114 photograph sets, 54 were evaluated using abdominal flap guidelines (Table 3). The photographs were not framed correctly in most (94%) of the abdominal flap sets, ie, the target patient anatomy from the clavicles to approximately the mid-thigh was not captured. Rather, the photographs were of incomplete torsos or the patient’s arms and/or upper legs were left out of the captured boundaries. One abdominal flap photograph set did not show a complete view of the subject’s breasts. For 29 (54%) of the 54 photograph sets, the patients were not posed standing erect with their arms at their

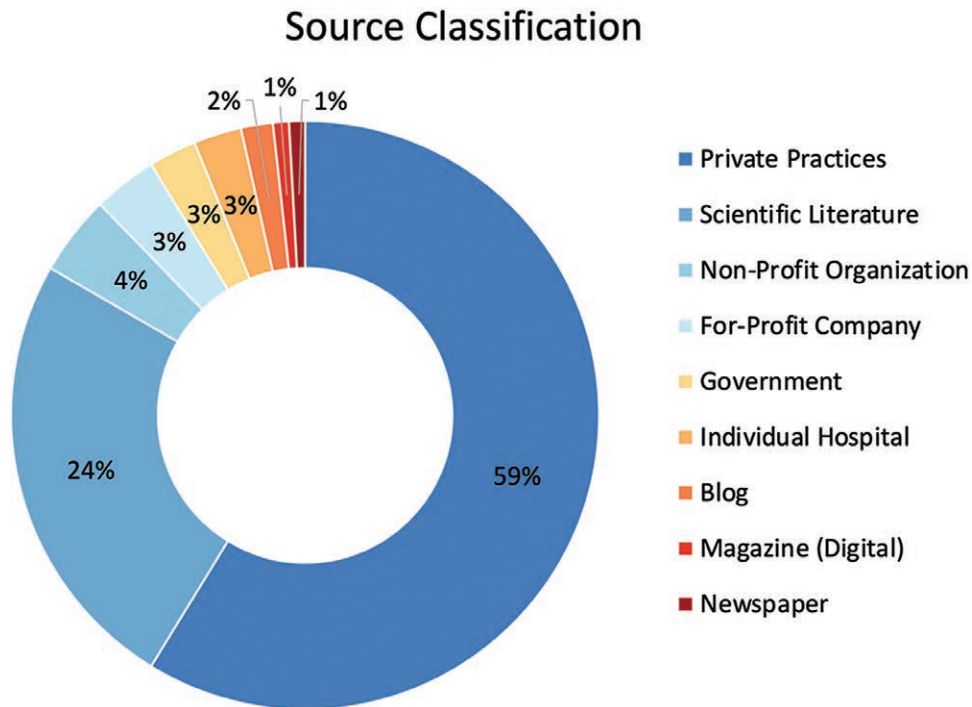


Fig. 2. Sources of breast reconstruction outcomes photograph sets.

sides. Often, patients had their arms on their abdomen or hips, behind their back, or outstretched. Patient preparation guidelines were not met by many (52%) abdominal flap sets because the patient was not wearing an appropriate photograph garment. In an additional 15 (28%) photograph sets, it could not be determined whether clothing was worn or not due to incorrect photograph framing.

Adherence to ASPS/PSF Breast Guidelines

Of the 114 photograph sets, 60 were evaluated using the breast guidelines. Forty-eight (80%) of the breast photograph sets ineffectively framed the photograph and did not capture the target anatomy from the top of the clavicles to the mid-epigastrium. Four (7%) photograph sets showed partial views of the breasts, and one photograph set covered both of the subject’s breasts with a bra. Patient positioning guidelines were not met in half (50%) of the breast photograph sets, as patients were photographed with their arms behind their back, outstretched, or resting on the abdomen or waist. Two (3%) photograph sets

featured the patient in a seated position. Additionally, four (7%) photograph sets did not show enough of the target anatomy to make a conclusion about arm placement. A few (8%) photograph sets failed the patient preparation criteria owing to the patient wearing a robe, having a cloth around their arms, or wearing a bra.

Clarity of Reported Breast Reconstructions

The entities’ disclosure of breast reconstruction procedures performed for each of the photograph sets aligned with our interpretation of the photograph sets in most cases. However, for 26% (30/114) of the photograph sets, we were not confident that the photograph sets depicted the indicated procedures, either because of photographic quality or because some procedures do not yield distinctive visible signs that can be assessed from a photograph. In addition, for a large percentage (17/23, 74%) of photograph sets that did not disclose the type of procedure, we felt that there was not enough data disclosed to make an assessment. Sets depicting implant-based reconstruction were found to be more presumptive; we were confident

Table 3. Adherence Rates to ASPS/PSF Breast and Abdominal Flap Guidelines

	ASPS/PSF Guidelines	All Sources	Did Not Meet Guidelines		
			Individual and Group Private Practices	Scientific Literature	Other
Abdominal flap photograph sets, % (n = 54)	Photograph framing	94% (51)	16	22	13
	Patient positioning	54% (29)	6	18	5
	Patient preparation	52% (28)	9	15	4
Breasts photograph sets, % (n = 60)	Photograph framing	80% (48)	40	4	4
	Patient positioning	50% (30)	25	3	2
	Patient preparation	8% (5)	3	0	2

Source breakdown is shown for photograph sets that do not meet the guidelines.

that an implant procedure was depicted for all but 7% (2/30) of the photograph sets disclosed as depicting implant-based reconstruction.

Number of Photographs Per Subject and Photograph Timing Information

Most photograph sets (106/114, 93%) consisted of at least one photograph of the patient at the prereconstruction stage and one photograph at the postreconstruction stage. The remaining eight sets included either prereconstruction only (2/114) or postreconstruction only (6/114) photographs. Of the 108 sets with prereconstruction photographs, 45 depicted patients with native breasts and 52 were of patients who had undergone a total mastectomy or lumpectomy. Ten (10/108) sets were of patients who had previously undergone a breast reconstruction procedure but were seeking an additional reconstruction. One photograph set (1/108) was of a burn victim. Of the 112 sets that included postreconstruction photographs, a few (4%) showed multiple time points after the reconstruction procedure.

Reconstruction Procedure Details

Information detailing flap or breast implant size and postsurgical cup size was extremely limited. In photograph sets classified as abdominal flap, only 9% (5/54) listed the flap size and none of the sets contained data on postsurgical cup size. Comparably, 22% (13/60) of photograph sets evaluated under the breast guidelines included the breast implant size and 5% (3/60) revealed the patients' postsurgical cup sizes.

Subject Demographic and Anthropometric Data

Insufficient demographic and anthropometric information was available. Patient age (mean, 48.4 ± 11 years) was disclosed for 50% (57/114) of the photograph sets. The patient's race and/or ethnicity was available for only 3% (3/114) of the photograph sets. Weight or BMI was included in only 12% (14/114) of the photograph sets.

Considering Common Misconceptions about Breast Reconstruction

Most photograph sets (112/114) included at least one postreconstruction photograph and, thus, were used to determine whether additional surgeries to improve the aesthetic outcomes had been performed. Fifty-eight percent (66/114) of photograph sets appeared to have nipple reconstruction or nipple tattooing, but only 45% (30/66) of this subgroup mentioned a nipple procedure in the photograph captions. A breast symmetry procedure was evident to the research team in 25 photograph sets, and symmetry procedures were disclosed in the majority of these cases (15/25, 60%). Fifty-two photograph sets were evaluated using the abdominal flap guidelines and included at least one postreconstruction photograph of the patient, but donor site scarring associated with transverse rectus abdominis muscle, deep inferior epigastric perforators, and latissimus dorsi flap reconstructions was clearly visible in only 40% (21/52).

DISCUSSION

Implications for Counseling Patients

Google Images search queries using general breast reconstruction keywords reveal many outcomes photographs, representative of the diversity of reconstruction approaches available. We note that none of the photographs meeting our search criteria originated from photograph galleries curated by plastic surgery professional societies or organizations. Rather, the photographs were from a variety of other sources, including scientific literature. In some cases, the public can see the publication's figures, including outcomes photographs, but do not have access to the full text due to licensing requirements. Consequently, viewers may be unable to obtain complete information about the reconstruction procedures depicted in the figures.

Most abdominal flap and breast photograph sets did not adhere to ASPS/PSF photographic guidelines, specifically the framing criteria, which is consistent with related work by Sanniec et al.³⁵ Patients might find it challenging to determine whether the subject's body is similar to theirs if the pertinent anatomy is not visible. Framing inconsistencies often lead to obstructed views of the breasts and flap donor sites, which hinders patients' understanding of the typical differences between pre- and postoperative appearances. Furthermore, incorrectly positioning subjects with slouched postures can distort a patient's perception of the relative size of the subject's reconstructed breasts compared with the body habitus.

We found that most demographic and anthropometric data were omitted from the photograph sets. Without this information, it is difficult for patients to search for and identify photographs of subjects with medical profiles analogous to theirs. Patients from underrepresented racial and ethnic groups and patients with atypical medical profiles are at a disadvantage, as the outcomes photographs available online are not representative of these populations.

Viewing outcomes photographs from a Google Images search is unlikely to mitigate common misconceptions about breast reconstruction. In photograph sets where nipple-areola reconstruction and breast symmetry procedures were evident, the majority of these procedures were not reported. Patients may form high expectations for their breast reconstruction outcomes on the basis of photographs they see online and be unpleasantly surprised with their results. Previous studies have shown that unmet expectations and dissatisfaction with aesthetic outcomes lead patients to experience detrimental psychological effects.^{16–18,20,21} In addition, most photograph sets only include one prereconstruction and one postreconstruction photograph. The lack of photographs depicting intermediate time points throughout the breast reconstruction process can propagate the idea that only one surgical procedure is needed to achieve the aesthetic result, which is often not the case.

Limitations

Google Images search results are contingent on factors beyond the query keywords, such as the browser search

history. Google Images searches are dynamic and sensitive to current events. Providers should expect variation in the quantity and quality of photographic content and sources that their patients view online.

Implications for Publishing Breast Reconstruction Photographs

A surprising finding for the authors was the prevalence of photographs from figures published in journals intended for surgical colleagues. Standalone figures that clearly communicate key aspects of the breast reconstruction procedure performed are critical, even in publications not intended for a lay audience, because figures may be publicly accessible online when the explanatory text is restricted. Moreover, more attention is needed to presenting outcomes photographs depicting diverse subjects with varying body shapes and sizes, ages, and surgical outcomes. Sharing photographs of multiple time points along the breast reconstruction process can raise patients' awareness of the aesthetic effects of revisions and help patients form realistic expectations for the short-term and the long-term.

Conclusions and Future Work

It is expected that patients will continue to use “Dr. Google” to find breast reconstruction outcome photographs. Therefore, patients may benefit from tools to facilitate discussions with their healthcare team about the strengths and limitations of breast reconstruction outcome photographs available on the internet. Professional societies can develop training tools for providers, and promote the issue at professional meetings and through social media. More research is needed on helping patients interpret online images in light of the information about breast reconstruction provided by their healthcare team.

Gregory P. Reece, MD

Department of Plastic Surgery
The University of Texas MD Anderson Cancer Center
1515 Holcombe Blvd., Box 443
Houston, TX 77030
E-mail: greece@mdanderson.org

ACKNOWLEDGMENTS

We thank Dawn Chalaire, Associate Director of Editing Services for The University of Texas MD Anderson Cancer Center Research Medical Library, for her editorial assistance. This study does not involve human subjects research and therefore does not require IRB approval.

REFERENCES

- Perrault EK, Hildenbrand GM, McCulloch SP, et al. Online information seeking behaviors of breast cancer patients before and after diagnosis: from website discovery to improving website information. *Cancer Treat Res Commun.* 2020;23:100176.
- Schmidt H, Cohen A, Mandeli J, et al. Decision-making in breast cancer surgery: where do patients go for information? *Am Surg.* 2016;82:397–402.
- Shen MJ, Dyson RC, D'Agostino TA, et al. Cancer-related internet information communication between oncologists and patients with breast cancer: a qualitative study. *Psychooncology.* 2015;24:1439–1447.
- Matros E, Yueh JH, Bar-Meir ED, et al. Sociodemographics, referral patterns, and internet use for decision-making in microsurgical breast reconstruction. *Plast Reconstr Surg.* 2010;125:1087–1094.
- Nagler RH, Gray SW, Romantan A, et al. Differences in information seeking among breast, prostate, and colorectal cancer patients: results from a population-based survey. *Patient Educ Couns.* 2010;81:S54–S62.
- Pew Research Center: Internet, Science & Tech. Demographics of internet and home broadband usage in the United States. Available at <https://www.pewresearch.org/internet/fact-sheet/internet-broadband/>. Accessed July 29, 2021.
- Pew Research Center: Internet, Science & Tech. Search engine use 2012. Available at <https://www.pewresearch.org/internet/2012/03/09/search-engine-use-2012-2/>. Accessed July 29, 2021.
- Rohrich RJ, Weinstein A. Paging Dr. Google: the changing face of plastic surgery. *Plast Reconstr Surg.* 2016;138:1133–1136.
- Fox S, Duggan M. Part two: Sources of health information. Available at <https://www.pewresearch.org/internet/2013/11/26/part-two-sources-of-health-information/>. Accessed July 29, 2021.
- Fiksdal AS, Kumbamu A, Jadhav AS, et al. Evaluating the process of online health information searching: a qualitative approach to exploring consumer perspectives. *J Med Internet Res.* 2014;16:e224.
- Currin-McCulloch J, Stanton A, Boyd R, et al. Understanding breast cancer survivors' information-seeking behaviours and overall experiences: a comparison of themes derived from social media posts and focus groups. *Psychol Health.* 2021;36:810–827.
- Maloney EK, D'Agostino TA, Heerd A, et al. Sources and types of online information that breast cancer patients read and discuss with their doctors. *Palliat Support Care.* 2015;13:107–114.
- Losken A, Burke R, Elliott LF 2nd, et al. Infonomics and breast reconstruction: are patients using the internet? *Ann Plast Surg.* 2005;54:247–250.
- Snell L, McCarthy C, Klassen A, et al. Clarifying the expectations of patients undergoing implant breast reconstruction: a qualitative study. *Plast Reconstr Surg.* 2010;126:1825–1830.
- Nguyen J, Thompson P, Losken A. Breast reconstruction in the social media age. *Aesthet Surg J.* 2021;41:200–205.
- Flitcroft K, Brennan M, Spillane A. Women's expectations of breast reconstruction following mastectomy for breast cancer: a systematic review. *Support Care Cancer.* 2017;25:2631–2661.
- Carr TL, Groot G, Cochran D, et al. Patient information needs and breast reconstruction after mastectomy. *Cancer Nurs.* 2019;42:229–241.
- Shammas RL, Fish LJ, Sergesketter AR, et al. Dissatisfaction after post-mastectomy breast reconstruction: a mixed-methods study. *Ann Surg Oncol.* 29:1109–1119.
- Teo I, Reece GP, Huang SC, et al. Body image dissatisfaction in patients undergoing breast reconstruction: examining the roles of breast symmetry and appearance investment. *Psychooncology.* 2018;27:857–863.
- Abu-Nab Z, Grunfeld EA. Satisfaction with outcome and attitudes towards scarring among women undergoing breast reconstructive surgery. *Patient Educ Couns.* 2007;66:243–249.
- Spector D, Mayer DK, Knafel K, et al. Not what I expected: informational needs of women undergoing breast surgery. *Plast Surg Nurs.* 2010;30:70–74.
- Pusic AL, Klassen AF, Snell L, et al. Measuring and managing patient expectations for breast reconstruction: impact on quality of life and patient satisfaction. *Expert Rev Pharmacoecon Outcomes Res.* 2012;12:149–158.

23. Lee CN, Hultman CS, Sepucha K. What are patients' goals and concerns about breast reconstruction after mastectomy? *Ann Plast Surg.* 2010;64:567–569.
24. Hasak JM, Myckatyn TM, Grabinski VF, et al. Stakeholders' perspectives on postmastectomy breast reconstruction: recognizing ways to improve shared decision making. *Plast Reconstr Surg Glob Open.* 2017;5:e1569.
25. Steffen LE, Johnson A, Levine BJ, et al. Met and unmet expectations for breast reconstruction in early post-treatment breast cancer survivors. *Plast Surg Nurs.* 2017;37:146–153.
26. Nissen MJ, Swenson KK, Kind EA. Quality of life after postmastectomy breast reconstruction. *Oncol Nurs Forum.* 2002;29:547–553.
27. Nicklaus KM, Bordes MC, Chopra D, et al. Appearance counseling needs of breast reconstruction patients. Presented at: Biomedical Engineering Society Annual Meeting; October 16, 2019; Philadelphia, Pa.
28. Grabinski VF, Myckatyn TM, Lee CN, et al. Importance of shared decision-making for vulnerable populations: examples from post-mastectomy breast reconstruction. *Health Equity.* 2018;2:234–238.
29. Marcasciano M, Frattaroli J, Mori FLR, et al. The new trend of pre-pectoral breast reconstruction: an objective evaluation of the quality of online information for patients undergoing breast reconstruction. *Aesthetic Plast Surg.* 2019;43:593–599.
30. Light A, Munro C, Breakey W, et al. The internet: what are our patients exposed to when considering breast reconstruction following mastectomy? *Breast.* 2014;23:799–806.
31. Vargas CR, Koolen PGL, Chuang DJ, et al. Online patient resources for breast reconstruction: an analysis of readability. *Plast Reconstr Surg.* 2014;134:406–413.
32. Vargas CR, Katak NA, Chuang DJ, et al. Assessment of online patient materials for breast reconstruction. *J Surg Res.* 2015;199:280–286.
33. Powell LE, Andersen ES, Pozez AL. Assessing readability of patient education materials on breast reconstruction by major US academic hospitals as compared with nonacademic sites. *Ann Plast Surg.* 2021;86:610–614.
34. American Society of Plastic Surgeons, The Plastic Surgery Foundation. Photographic standards in plastic surgery. Available at http://trebol.sirexmedica.com/download/Photographic_Standards.pdf. Published 2006.
35. Sanniec K, Velazco C, Macias L, et al. Adherence to photographic standards: a review of ASPS and ASAPS member surgeons' websites. *J Aesthetic Reconstr Surg.* 2016;2:11.
36. American Society of Plastic Surgeons, The Plastic Surgery Foundation. *Photographic Guidelines in Plastic Surgery.* 2019. Available at: https://www1.plasticsurgery.org/shopping/product.aspx?id=28521&to=shopasps?utm_source=Website&utm_medium=Health-Policy-Statements&utm_content=web-health-policy&utm_campaign=Health-Policy-Statements. Accessed August 30, 2021.
37. Jabor MA, Shayani P, Collins DR Jr, et al. Nipple-areola reconstruction: satisfaction and clinical determinants. *Plast Reconstr Surg.* 2002;110:457–63; discussion 464.