

# Advances in the treatment of central serous chorioretinopathy



Marwan A. Abouammoh, MD\*

## Abstract

Central serous chorioretinopathy is a disease that is partly understood. Novel advancements have led to further understanding of the disease, and have identified choroidal dysfunction as the principal element in CSCR development. New imaging tools have aided in better monitoring disease response to various treatment models. Enhanced depth imaging optical coherence tomography, in particular, has helped in observing choroidal thickness changes after various treatment models. To date, photodynamic therapy and focal laser remain the main stay of treatment. More understanding of disease pathophysiology in the future will help in determining the drug of choice and the best management option for such cases.

**Keywords:** CSCR, Central serous chorioretinopathy, Central serous retinopathy, Photodynamic therapy, Corticosteroids, Treatment

© 2015 Production and hosting by Elsevier B.V. on behalf of Saudi Ophthalmological Society, King Saud University. This is an open access article under the CC BY-NC-ND license (<http://creativecommons.org/licenses/by-nc-nd/4.0/>).  
<http://dx.doi.org/10.1016/j.sjopt.2015.01.007>

## Introduction

Central serous chorioretinopathy (CSCR) is an acquired chorioretinal disorder that was first described by Von Graefe in 1866 as recurrent central syphilitic retinitis.<sup>1</sup> Other names used to describe this disease entity include capillarospastic central retinitis, central angiospastic retinopathy, central serous retinopathy, and central serous pigment epitheliopathy.<sup>2,3</sup>

CSCR usually affects middle-aged men between the ages of twenty and fifty years.<sup>4–6</sup> It has also been associated with type A personality, or those who are experiencing psychological stress.<sup>5,7</sup> It has been also linked to use of sympathomimetic agents, corticosteroid use in any form, endogenous high levels of corticosteroids, and some psychopharmacologic agents.<sup>8–13</sup> Smokers tend to have poorer vision and need longer period for visual rehabilitation.<sup>14</sup>

## Clinical features

Patients with CSCR most commonly complain of metamorphopsia, micropsia, blurred vision, and mild dyschromatopsia in the affected eye. On fundus examination, typical signs include a round well-demarcated detachment of the neurosensory retina at the macula. Pigment epithelial detachment (PED) of variable size can also occur and can be single or multiple. The subretinal fluid (SRF) can be clear or turbid/fibrous. The turbid fluid may even form in the sub-retinal pigment epithelial (sub-RPE) space.<sup>15,16</sup> In chronic CSCR or in patients with old resolved disease, RPE mottling, atrophy, and clumping might be observed.<sup>17–19</sup> In addition, yellow dots that are thought to represent phagocytosed photoreceptor outer segments are frequently seen just over the inner surface of the RPE.<sup>18</sup> Other atypical CSCR presentations include bullous neurosensory retinal detachment, inferior neurosensory detachment with atrophic tracts, and multifocal CSCR.<sup>2,20,21</sup>

Received 27 October 2014; received in revised form 18 January 2015; accepted 19 January 2015; available online 24 January 2015.

King Saud University, Riyadh, Saudi Arabia

\* Address: Department of Ophthalmology, College of Medicine, King Saud University, P.O. Box 245, Riyadh 11411, Saudi Arabia. Tel.: +966 505476426; fax: +966 14775724.

e-mail address: [dr.abouammoh@gmail.com](mailto:dr.abouammoh@gmail.com)



Peer review under responsibility of Saudi Ophthalmological Society, King Saud University



Production and hosting by Elsevier

Access this article online:  
[www.saudiophthaljournal.com](http://www.saudiophthaljournal.com)  
[www.sciencedirect.com](http://www.sciencedirect.com)

Investigations for CSCR include fluorescein angiography (FA) which may show 'ink blot' pattern of leakage or the less common 'smoke stack' appearance that mimics a mushroom cloud.<sup>22</sup> In addition, dye pooling in the sub-RPE space can be seen in cases of PED. Diffuse leakage or multiple leaking points can be seen in recurrent, chronic, or multifocal CSCR. Indocyanine green (ICG) angiography may demonstrate dilated choroidal vasculature corresponding to the site of CSCR with choroidal hyperpermeability in the late phase.<sup>23,24</sup> Optical Coherence Tomography (OCT) can demonstrate the neurosensory detachment and areas of PED. Enhanced depth imaging (EDI) OCT can show the thickened choroid in the areas corresponding to the neurosensory detachment.<sup>25</sup>

### Pathophysiology

Notwithstanding the well-identified clinical picture of CSCR, its pathophysiology is inadequately understood. Proposed theories include choroidal hyperpermeability which overloads the RPE pumping mechanism responsible for keeping the subretinal space dry and may – in some instances – lead to decompensation and SRF collection.<sup>8,26,27</sup> RPE dysfunction is another theory for developing CSCR in which focal damage of adjacent RPE cells or even a single RPE cell leads to reversal of ion pumping mechanism and resulting in fluid accumulation in the subretinal space.<sup>28,29</sup> Marmor hypothesized that a dysfunction in the RPE metabolic transport system is needed in order to accumulate subretinal fluid in CSCR due to focal RPE defects.<sup>30</sup>

An alternative theory is a combined choroidal and RPE dysfunction.<sup>31</sup> In addition, there is a close relationship between CSCR and both endogenous and exogenous corticosteroids suggesting a role in pathogenesis.<sup>9–12</sup> It has been suggested that corticosteroids might sensitize the choroidal blood vessels or RPE to the effects of catecholamines;<sup>32</sup> furthermore, corticosteroids have certain genomic effects on adrenergic receptor gene transcription and expression which can result in an increase in the number of adrenergic receptors.<sup>33,34</sup>

Zhao et al. were the first to demonstrate that blocking the aldosterone upregulated the endothelial vasodilatory potassium channels that prevented aldosterone-induced choroidal thickening. This is suggestive of the presence of mineralocorticoid receptors in the choroidal vasculature which might be involved in the pathophysiology of CSCR.<sup>35</sup>

### Treatment

CSCR is usually a self-limiting disease with spontaneous resolution within 3–4 months with overall good visual outcome.<sup>36–38</sup> However, recurrences are seen in up to 50% of patients within the first year.<sup>39</sup>

Chronic CSCR diseases are the cases in which there are diffuse RPE changes without evident detachment in most cases.<sup>9</sup> However it is sometimes difficult to clinically differentiate a chronic disease from a recurrent episode of CSCR. Spaide identified chronic CSCR as serous macular elevation detected microscopically or by OCT, and is associated with RPE atrophic areas and subtle leaks or ill-defined staining on FA.<sup>15</sup> These recurrences or chronic neurosensory detachments may lead to RPE atrophy or hypertrophy with irreversible loss of visual function.<sup>40–44</sup>

Given all of the above, observation can be regarded as a first-line approach in newly diagnosed cases of less than 3 month duration.<sup>7</sup> In addition, risk factors should be addressed to increase the chance of spontaneous resolution. This includes discontinuing exogenous corticosteroids intake in any form – if possible – and life style modification for patients with type A personality traits.<sup>7,9,10,45–48</sup> On the other hand, different modalities of treatment for CSCR exist. These treatments are reserved for chronic CSCR, recurrent CSCR, single CSCR attack of more than 3 month duration, and if the fellow eye suffered from permanent visual loss due to a previous episode of CSCR whether acute or chronic. We will discuss below, current, emerging, and advances in therapeutics for CSCR.

### Laser photocoagulation

Applying laser photocoagulation to the leaking RPE guided by FA has been shown to hasten resolution of the neurosensory detachment in CSCR. Xenon laser was used at first followed by krypton laser; currently argon laser is more widely used.<sup>49–51</sup> Many level one evidence studies have demonstrated faster resolution of SRF in patients who underwent laser photocoagulation compared to control eyes.<sup>52–54</sup> Nevertheless laser photocoagulation does not influence the final visual outcome or rate of recurrence.<sup>6,54,55</sup>

Therefore, argon laser photocoagulation is an effective treatment for acute CSCR with clearly defined focal leakage point as seen on FA given that the leakage is not subfoveal or juxtafoveal. Still, side effects such as permanent scotoma, laser scar enlargement, and laser induced CNV can still occur (Fig. 1).

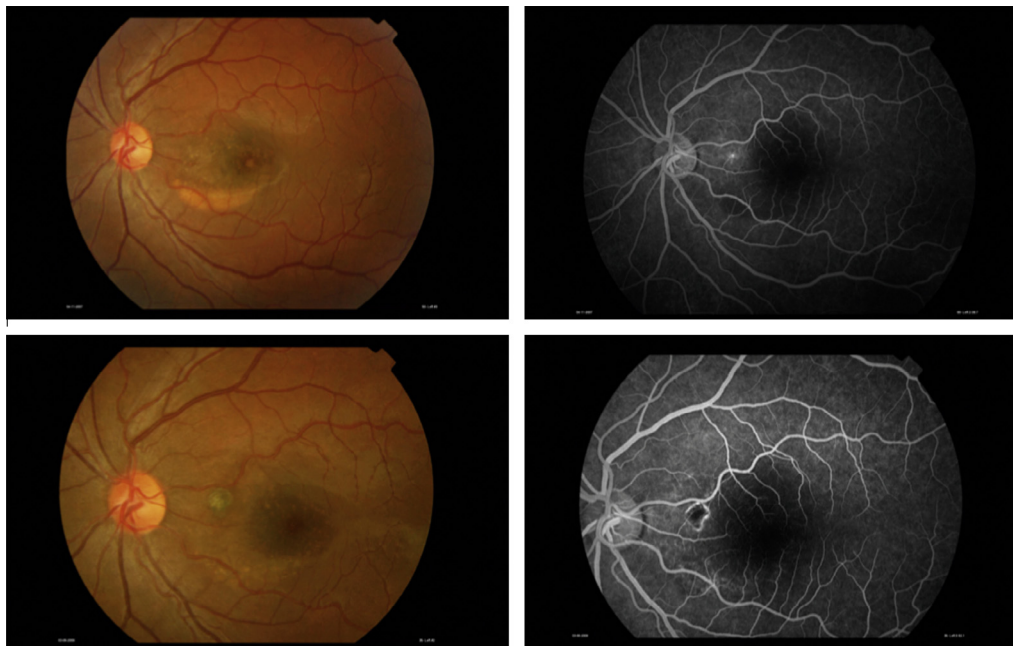
### Micropulse diode laser photocoagulation

This method of treatment uses subthreshold diode laser energy in order to minimize retinal damage. It is similarly effective in CSCR with point source leakage but not in eyes with diffuse leakage, and leaves no clinically detectable laser-induced damage.<sup>56–58</sup> Since there is no visible endpoint to diode micropulse laser (DMPL) application, ICG enhanced DMPL can be used to identify treated areas with post-treatment ICG angiography.<sup>59</sup>

To date, only one randomized clinical trial (RCT) assessed DMPL versus argon laser photocoagulation in acute CSCR.<sup>60</sup> Patients in both groups had complete resolution of SRF at 12 weeks of follow-up. All patients had no scotomas in the DMPL group compared to 3 out of 15 patients in the argon laser group who had persistent scotomas. Contrast sensitivity was also significantly better in the DMPL group.<sup>60</sup>

### Transpupillary thermotherapy

Transpupillary thermotherapy (TTT) is a 810 nm long-pulse low-energy diode laser. It works by raising the temperature of the choroid and outer retina while sparing the inner retina and photoreceptors to some degree, but the exact mechanism is not clear.<sup>61</sup> First described in 2005 by Wei, short-term encouraging visual and anatomical outcomes have been observed in CSCR with subfoveal leaks, multiple or diffuse leaks, and recurrent atypical CSCR with PEDs.<sup>61–64</sup> More well structured RCTs with long-term results are required to establish the role of TTT in the treatment of CSCR.



**Figure 1.** Left eye of a 32-year-old man with chronic CSCR showing turbid subretinal fluid (top right). Fluorescein angiography shows pin-point leakage between the optic nerve and fovea (top left). Six months after focal laser photocoagulation to the leakage site shows resolution of the subretinal fluid with enlargement of the laser scar and some atrophic RPE changes (bottom right). Fluorescein angiography shows hypofluorescent area surrounded by a hyperfluorescent rim corresponding to the laser scar (bottom left). (Courtesy of Dr. Saba Al-Rashaed).

### Photodynamic therapy

Photodynamic therapy (PDT) with verteporfin has been employed to treat both chronic and acute CSCR, as well as, to reduce recurrences. It is believed that PDT works in CSCR by inducing choroidal hypoperfusion, and vascular narrowing and remodeling to negate choroidal hyperpermeability which is consistently found in CSCR cases.<sup>65,66</sup> Others have proposed that PDT can also tighten the blood retina barrier.<sup>67</sup>

### Standard PDT

Chan et al. reported the first case series of full dose, full fluence PDT in 6 patients with persistent or chronic CSCR with subfoveal leakage.<sup>68</sup> Many RCTs demonstrated the efficacy of PDT. Inoue et al. reported that PDT is not effective or recurrence rate is thought to be high in eyes with no intense hyperfluorescence on ICG.<sup>69</sup> Moon et al. concluded that visual recovery might be limited in CSCR patients with lengthy symptom duration, post-PDT RPE atrophy progression, and in patients with possible foveal injury from PDT.<sup>70</sup> Tsakonas and coworkers demonstrated the effectiveness and safety of FA-guided full fluence PDT using multiple PDT spots at the same session for chronic CSCR.<sup>71</sup> Thus even FA-guided PDT can be an effective alternative in cases where ICG is not available.

Ruiz-Moreno treated 82 eyes with standard PDT for chronic CSCR and showed that it can improve visual acuity and reduce central macular thickness (CMT). SRF has disappeared in all cases. In his large case series, no patient developed severe visual loss or complications derived from PDT with an average follow-up of 12 months. However, 9 cases developed reactive RPE hypertrophy after PDT.<sup>72</sup> Furthermore, neuroretinal thinning after standard PDT has been described, but is not correlated with visual acuity decrease.<sup>73,74</sup> Morphological and functional chorioretinal changes such as RPE

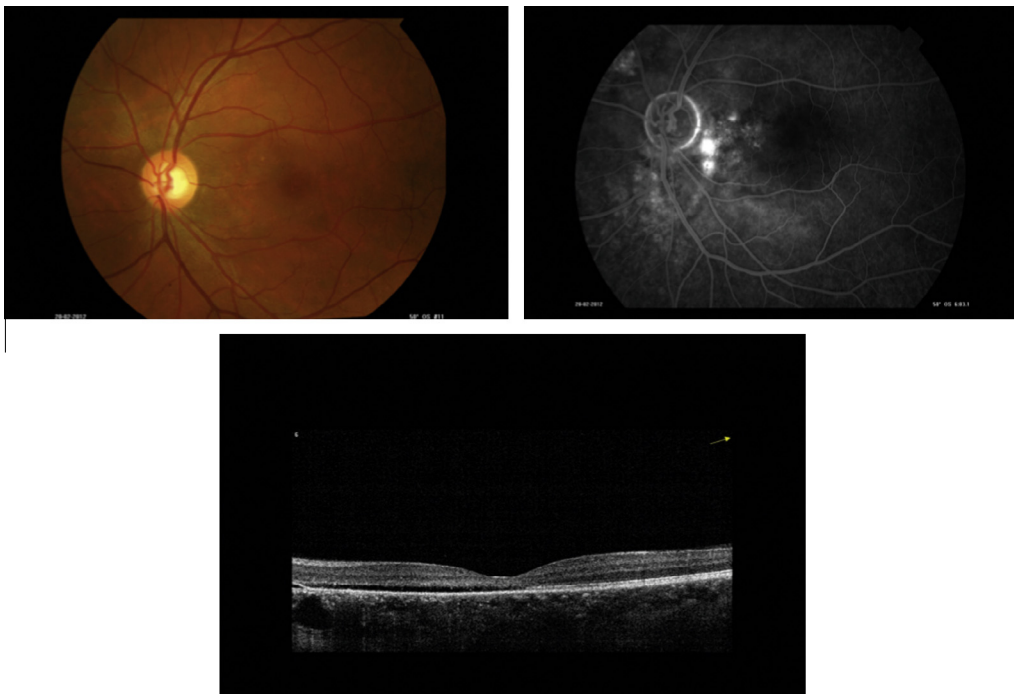
atrophy, external limiting membrane and inner segment/outer segment junction line discontinuity have been observed after standard PDT treatment for CSCR, but were not correlated with the area of PDT treatment nor with the change in visual acuity.<sup>74</sup> These post-PDT changes probably represent accelerated course of the disease, which if left to its natural chronic course might cause more damage.

Due to possible treatment-related risks such as choroidal ischemia, RPE atrophy, RPE rip, and secondary choroidal neovascular membrane (CNVM), some safety measures were adopted in order to minimize these risks.<sup>68,75–78</sup> These safety-enhanced measures include reducing the dose or power (fluence) of PDT (Figs. 2 and 3).

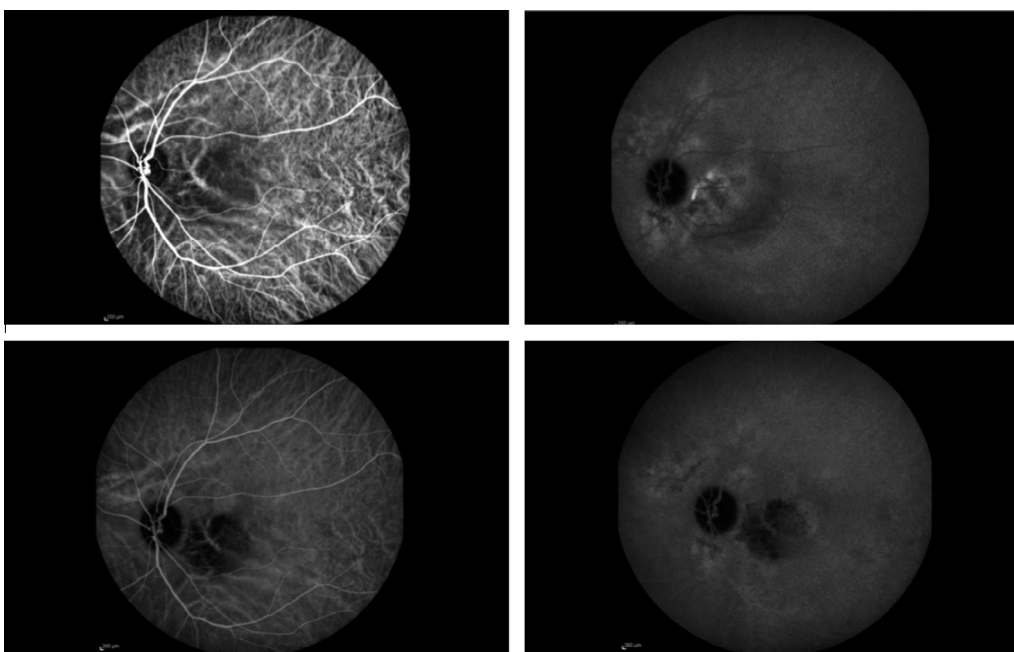
### Reduced dose PDT

A short-term pilot study by Lai et al. using half dose verteporfin for chronic CSCR has demonstrated both efficacy and safety.<sup>77</sup> Chan et al. have shown in an RCT that included 63 patients that half dose PDT was also effective both anatomically and functionally in treating acute symptomatic CSCR.<sup>65</sup> A comparative case series by Lim et al. have shown that half dose PDT facilitated earlier resolution of SRF and earlier recovery of visual function when compared to focal laser. No difference in final functional and anatomical results was noted at six month follow-up.<sup>79</sup> Kim and coworkers used FA-guided half dose PDT for acute CSCR and found that long-term anatomic and functional outcomes were not convincing when compared to observation only at the end of one year of follow-up in spite of complete resolution of SRF in 100% of cases at the 3 month follow-up point.<sup>80</sup>

Maruko et al. found that subfoveal choroidal thickness and ICG hyperpermeability decreased after PDT compared to laser photocoagulation.<sup>81</sup> Ratanasukon et al. concluded that about 45% of CSCR patients treated with half dose PDT had photoreceptor disruption at 1-year follow-up that



**Figure 2.** Left eye of a 48-year-old man with recurrent CSCR who was misdiagnosed as wet macular degeneration. Note the dull foveal reflex and RPE atrophic changes (top right). Fluorescein angiography shows diffuse irregular hyperfluorescence (top left). Optical coherence tomography shows shallow subretinal fluid reaching the fovea (Down).



**Figure 3.** Indocyanine green of the previous patient in Fig. 2 shows dilated/engorged choroidal vessels corresponding to the leakage seen on fluorescein angiography (top right). Late phase shows leakage from these choroidal vessels (top left). One month after half-dose photodynamic therapy the hypocyanescent area corresponds to the site of treatment (bottom right). It shows overall reduction in vascularity with decrease in choroidal vessel caliber. No more leakage can be seen on late phase of ICG (bottom left).

eventually led to poor visual outcomes. It should be noted, however, that the photoreceptor line at baseline was difficult to identify and that only the final photoreceptor status was documented but was not compared to baseline photoreceptor status.<sup>82</sup> Karakus et al. showed that half dose PDT was effective and safe after up to 3 years of follow-up for chronic

CSCR with improvement in contrast sensitivity compared to baseline.<sup>83</sup>

Dang et al. studied subfoveal choroidal thickness after one-third PDT dose, and found that subfoveal choroid was thicker in patients with acute CSCR than in normal population with symptomatic eyes being significantly thicker than in fel-

low eyes.<sup>84</sup> Zhao proposed that the lowest safe effective dose of verteporfin was 30% of the standard dose in treating acute CSCR.<sup>85</sup> Uetani and colleagues showed that half dose PDT was more effective than one-third PDT dose for chronic CSCR.<sup>86</sup> Nicolo concluded that chronic CSCR with posterior retinal cystoid degeneration might do worse when treated with half dose PDT when compared to chronic CSCR with SRF alone.<sup>87</sup>

### Reduced fluence PDT

As some of the risks of PDT still exist after reducing the dose of verteporfin, reducing the fluence by decreasing laser time or power was attempted. Reibaldi et al. compared full fluence to half fluence PDT in chronic CSCR. Both treatments achieved similar results in terms of visual outcome and SRF resolution, but choriocapillaris ischemia was significantly more in the full fluence group.<sup>76</sup> Similar promising results for reduced fluence PDT in terms of safety and efficacy have also been documented with half fluence and even minimal (12 J/cm<sup>2</sup>) fluence.<sup>88–91</sup>

Ohkuma et al. concluded that the outer nuclear layer thickness is a significant predictive factor for visual acuity after reduced fluence PDT for CSCR at 1 year.<sup>92</sup> Kang et al. showed that subfoveal choroidal thickness decreased after reduced fluence PDT, as well as, after spontaneous resolution, but normal subfoveal thickness was only achieved in the PDT group.<sup>93</sup> Nicolo compared half-fluence to half-dose PDT for chronic CSCR, and found that half-dose PDT induced faster SRF resolution and that the effects seem to last longer than half-fluence PDT. However, both were equally safe.<sup>94</sup>

Larger RCTs with long-term follow-up are still needed to establish the most effective and safe way for treating CSCR using PDT. The ideal PDT treatment for CSCR would be that which achieves the best results with the least possible complications.

### Intravitreal anti-vascular endothelial growth factor (VEGF)

Attempts to treat acute and chronic CSCR with intravitreal bevacizumab are based on the hypothesis that choroidal hyperpermeability is associated with increased expression of VEGF, albeit high VEGF levels were not detected in the aqueous humor.<sup>95–98</sup> Yet, Jung et al. have demonstrated that CSCR patients who responded to intravitreal bevacizumab had higher aqueous levels than those who did not respond.<sup>99</sup>

Lim et al. reported the absence of any positive effect in a series of 12 patients treated with a single intravitreal bevacizumab injection (1.25 mg/0.05 ml) when compared to observation group (12 eyes) during a six-month follow-up. Bae et al. demonstrated in another RCT that reduced-fluence PDT was superior to 3 monthly doses of intravitreal ranibizumab. They found that over 1-year of follow-up, 16 eyes (89%) remained dry in the PDT group versus only 2 eyes (12.5%) in the ranibizumab group. Visual acuity improved in both groups, but the difference was significantly better in the PDT group at the 3-month time point.<sup>100</sup>

Other uncontrolled case series suggest efficacy of anti-VEGF intravitreal injections for CSCR both functionally and anatomically.<sup>95,101–107</sup> As the natural history of CSCR is gen-

erally favorable, the lack of controls in these case series, is noteworthy. On the other hand, anti-VEGF therapy has a much obvious, well-established role in CNVMs secondary to CSCR.<sup>108,109</sup>

### Anti-corticosteroids

The connotation of corticosteroid use and the development of CSCR have led to the suggestion of anti-corticosteroids as a treatment.<sup>32</sup> This has led to several clinical trials to assess the effect of such treatment.

Ketoconazole is a synthetic imidazole which, in addition to its anti-fungal properties, has anti-glucocorticoid effects by blocking the conversion of cholesterol to androgenic glucocorticoid end-products. Meyerle et al. did not note any change in visual acuity, median lesion height on OCT, and linear dimensions through an 8-week follow-up period for 5 chronic CSCR patients who received oral ketoconazole 600 mg per day for 4 weeks in spite of documented decrease in endogenous cortisol levels.<sup>110</sup> Golshahi in a comparative non-randomized study of 15 patients with acute CSCR treated with ketoconazole for 4 weeks versus 15 patients in the control group concluded that systemic ketoconazole was not associated with a significantly better outcome.<sup>111</sup>

Mifepristone (RU-486) is an abortifacient agent. Its mechanism of action is mediated through its glucocorticoid and progesterone receptor antagonistic effects. Nielsen et al. studied 16 patients with chronic CSCR in an uncontrolled study. Systemic mifepristone 200 mg was administered for up to 12 weeks. Seven patients gained  $\geq 5$  letters of vision, and 7 patients had improved OCT findings. This led to the conclusion that oral mifepristone has a beneficial effect in some CSCR cases.<sup>112</sup>

Spironolactone and eplerenone are both aldosterone antagonist agents. Spironolactone possesses additional anti-androgen properties. Few case-series documented a reduction or complete resolution of SRF level and significant CMT reduction.<sup>113–116</sup> However, RCTs are warranted to further clarify the role of aldosterone receptor antagonist in CSCR. Currently there is only one ongoing trial with eplerenone (Clinical trial: NCT01990677).

Rifampicin is an anti-tuberculous medication which is thought to facilitate catabolism of endogenous steroids. It causes a proliferation of the smooth endoplasmic reticulum and an increase in the cytochrome P-450 content in the liver, thus affecting the metabolism and bioavailability of endogenous corticosteroids, consequently aiding in resolution of CSCR and improving its symptomatology.<sup>117,118</sup> However, care is to be taken as hepatotoxicity can develop as a side effect while being treated for CSCR.<sup>119</sup>

Finasteride is a weak anti-androgen that worked mainly through inhibiting type II 5  $\alpha$ -reductase that is necessary for converting testosterone to dihydrotestosterone (DHT), a potent androgen. Forooghian et al. described 5 cases of chronic CSCR treated with oral finasteride 5 mg daily for 3 months. Mean CMT and SRF volume decreased in all patients. This reduction corresponded to a drop in DHT serum levels in all patients. Following the cessation of finasteride, all patients but one had SRF recollection and an increase in CMT.<sup>120</sup> More trials are needed to evaluate the effect of finasteride in CSCR.

### Adrenergic blockers

As CSCR is closely associated with type A personality which is characterized by high adrenergic activity, it was proposed that blocking adrenergic receptors might have a positive effect on CSCR.<sup>121</sup> It has been shown that CSCR patients who were diagnosed to have hypertension and were started on metoprolol – a beta blocker – had improved symptomatology. Recurrence of CSCR once metoprolol was stopped was also noticed.<sup>122</sup> Chrapek et al. demonstrated no effect of metipranolol on acute CSCR in a recent double-blinded RCT in which 23 patients received 10 mg of metipranolol for up to 45 weeks compared to placebo pills in 25 patients.<sup>123</sup> The contradictory results demand further assessment of the actual role of adrenergic blockers.

### Systemic carbonic anhydrase inhibitors (CAIs)

CAIs are thought to mediate its action by inhibiting carbonic anhydrase enzyme in RPE, which supposedly aid in SRF absorption. Pikkell et al. reported a prospective non-randomized trial on 15 CAI-treated patients against 7 controls. They found that oral acetazolamide shortens the time for subjective and clinical improvement, but there was no difference in final visual acuity or recurrence rate between the two groups.<sup>124</sup>

### Aspirin

Caccavale et al. compared 109 patients with CSCR, who were treated with aspirin 100 mg once a day for a month followed by 100 mg every other day for 5 months, to a historic control group of 89 patients. They concluded that treatment with aspirin may hasten visual improvement and reduce recurrences compared to no treatment.<sup>125,126</sup> They theorized that the CSCR is due to impaired fibrinolysis and increased platelet aggregation in the choriocapillaris.<sup>125</sup> Therefore, it is presumed that aspirin works in such cases through its fibrinolytic and anti-platelet action.

### Helicobacter pylori treatment

*H. Pylori* infection has been recently linked to CSCR.<sup>127,128</sup> Rahbani-Nobar showed on a non-randomized trial the efficacy of anti-*H. Pylori* treatment regimen in hastening the absorption of SRF.<sup>129</sup> A RCT by Dang et al. concluded that anti-*H. Pylori* treatment regimen does not improve vision, SRF, nor alter the clinical course.<sup>130</sup> The exact role of anti-*H. Pylori* treatment in the management of CSCR remains to be defined.

### Methotrexate

Methotrexate is an antimetabolite drug that basically inhibits folic acid metabolism. It is used successfully for treating certain cancer entities, and some autoimmune rheumatologic diseases, including certain forms of vasculitis. Kurup et al. retrospectively evaluated methotrexate as a treatment for chronic CSCR in 11 eyes. They found that the mean CMT and visual acuity improved significantly compared to baseline values, and 9 eyes (83%) remained dry after completion of the treatment regimen. The mean duration of treatment

was 12 weeks.<sup>131</sup> More trials are needed to explore the potentials of methotrexate in treating CSCR and understand its mechanism of action.

### Search strategy

This review was conducted by performing an electronic search of the Medline and EMBASE databases. The search was limited to English language, and humans. We searched the databases for relevant terms which included central serous retinopathy, central serous chorioretinopathy, photodynamic therapy, CSC, CSCR, and treatment of central serous chorioretinopathy. In addition, referenced articles from extracted research papers were also reviewed for additional data and the articles were retrieved if deemed relevant.

### Conclusion

CSCR is a multifactorial disease that remains incompletely understood. Recent imaging innovations have led to further understanding and better monitoring of disease progression and response to treatment. The gold standard of care for CSCR is yet to be defined. To date, PDT offers good clinical results that are maintained for an extended period of time. Further long-term trials and continuous advances in retinal therapeutics might culminate in achieving the drug of choice for CSCR.

### Conflict of interest

The authors declared that there is no conflict of interest.

### Acknowledgment

The author would like to acknowledge Dr. Saba Al-Rashaed, King Khaled Eye Specialist Hospital, for her kind help with Fig. 1.

### References

1. Von Graefe A. Ueber central recidivierende retinitis. *Graefe's Arch Clin Exp Ophthalmol* 1866;12:211–5.
2. Yannuzzi LA, Shakin JL, Fisher YL, Altomonte MA. Peripheral retinal detachments and retinal pigment epithelial atrophic tracts secondary to central serous pigment epitheliopathy. *Ophthalmology* 1984;91(12):1554–72.
3. Maumenee AE. Macular diseases: clinical manifestations. *Trans Am Acad Ophthalmol Otolaryngol* 1965;69:605–13.
4. Gass JD. Photocoagulation treatment of idiopathic central serous choroidopathy. *Trans Sect Ophthalmol Am Acad Ophthalmol Otolaryngol* 1977;83(3 Pt 1):456–67.
5. Yannuzzi LA. Type A behavior and central serous chorioretinopathy. *Trans Am Ophthalmol Soc* 1986;84:799–845.
6. Gilbert CM, Owens SL, Smith PD, Fine SL. Long-term follow-up of central serous chorioretinopathy. *Br J Ophthalmol* 1984;68(11):815–20.
7. Yannuzzi LA. Type-A behavior and central serous chorioretinopathy. *Retina* 1987;7(2):111–31.
8. Prünte C, Flammer J. Choroidal capillary and venous congestion in central serous chorioretinopathy. *Am J Ophthalmol* 1996;121(1):26–34.
9. Polak BC, Baarsma GS, Snyers B. Diffuse retinal pigment epitheliopathy complicating systemic corticosteroid treatment. *Br J Ophthalmol* 1995;79(10):922–5.
10. Wakakura M, Ishikawa S. Central serous chorioretinopathy complicating systemic corticosteroid treatment. *Br J Ophthalmol* 1984;68(5):329–31.

11. Harada T, Harada K. Six cases of central serous choroidopathy induced by systemic corticosteroid therapy. *Doc Ophthalmol* 1985;**60**(1):37–44.
12. Bouzas EA, Scott MH, Mastorakos G, Chrousos GP, Kaiser-Kupfer MI. Central serous chorioretinopathy in endogenous hypercortisolism. *Arch Ophthalmol* 1993;**111**(9):1229–33.
13. Tittl MK, Spaide RF, Wong D, et al. Systemic findings associated with central serous chorioretinopathy. *Am J Ophthalmol* 1999;**128**(1):63–8.
14. Türkcü FM, Yüksel H, Sahin A, et al. Effects of smoking on visual acuity of central serous chorioretinopathy patients. *Cutan Ocul Toxicol* 2014;**33**(2):115–9. <http://dx.doi.org/10.3109/15569527.2013.810633>.
15. Spaide RF, Campeas L, Haas A, et al. Central serous chorioretinopathy in younger and older adults. *Ophthalmology* 1996;**103**(12):2070–9, discussion 2079–80.
16. Agarwal A. *Gass' atlas of macular diseases*. 5th ed. Elsevier; 2011.
17. Desai UR, Alhalel AA, Campen TJ, Schiffman RM, Edwards PA, Jacobsen GR. Central serous chorioretinopathy in African Americans. *J Natl Med Assoc* 2003;**95**(7):553–9.
18. Maruko I, Iida T, Ojima A, Sekiryu T. Subretinal dot-like precipitates and yellow material in central serous chorioretinopathy. *Retina* 2011;**31**(4):759–65. <http://dx.doi.org/10.1097/IAE.0b013e3181fbce8e>.
19. Ie D, Yannuzzi LA, Spaide RF, Rabb MF, Blair NP, Daily MJ. Subretinal exudative deposits in central serous chorioretinopathy. *Br J Ophthalmol* 1993;**77**(6):349–53.
20. Gass JD. Bullous retinal detachment. An unusual manifestation of idiopathic central serous choroidopathy. *Am J Ophthalmol* 1973;**75**(5):810–21.
21. O'Connor PR. Multifocal serous choroidopathy. *Ann Ophthalmol* 1975;**7**(2):237–45.
22. Bujarborua D, Nagpal PN, Deka M. Smokestack leak in central serous chorioretinopathy. *Graefes Arch Clin Exp Ophthalmol* 2010;**248**(3):339–51. <http://dx.doi.org/10.1007/s00417-009-1212-5>.
23. Spaide RF, Hall L, Haas A, et al. Indocyanine green videoangiography of older patients with central serous chorioretinopathy. *Retina* 1996;**16**(3):203–13.
24. Iida T, Kishi S, Hagimura N, Shimizu K. Persistent and bilateral choroidal vascular abnormalities in central serous chorioretinopathy. *Retina* 1999;**19**(6):508–12.
25. Imamura Y, Fujiwara T, Margolis R, Spaide RF. Enhanced depth imaging optical coherence tomography of the choroid in central serous chorioretinopathy. *Retina* 2009;**29**(10):1469–73. <http://dx.doi.org/10.1097/IAE.0b013e3181be0a83>.
26. Okushiba U, Takeda M. Study of choroidal vascular lesions in central serous chorioretinopathy using indocyanine green angiography. *Nihon Ganka Gakkai Zasshi* 1997;**101**(1):74–82.
27. Tittl M, Maar N, Polska E, Weigert G, Stur M, Schmetterer L. Choroidal hemodynamic changes during isometric exercise in patients with inactive central serous chorioretinopathy. *Invest Ophthalmol Vis Sci* 2005;**46**(12):4717–21. <http://dx.doi.org/10.1167/iovs.05-0268>.
28. Spitznas M. Pathogenesis of central serous retinopathy: a new working hypothesis. *Graefes Arch Clin Exp Ophthalmol* 1986;**224**(4):321–4.
29. Negi A, Marmor MF. Experimental serous retinal detachment and focal pigment epithelial damage. *Arch Ophthalmol* 1984;**102**(3):445–9.
30. Marmor MF. New hypotheses on the pathogenesis and treatment of serous retinal detachment. *Graefes Arch Clin Exp Ophthalmol* 1988;**226**(6):548–52.
31. Ryan S. *Retina*. 5th ed. Schachat A, Wilkinson C, Hinton D, Sadda S, Wiedemann P, editors. Saunders; 2012. p. 1291–305.
32. Jampol LM, Weinreb R, Yannuzzi L. Involvement of corticosteroids and catecholamines in the pathogenesis of central serous chorioretinopathy: a rationale for new treatment strategies. *Ophthalmology* 2002;**109**(10):1765–6.
33. Sakaue M, Hoffman BB. Glucocorticoids induce transcription and expression of the alpha 1B adrenergic receptor gene in DTT1 MF-2 smooth muscle cells. *J Clin Invest* 1991;**88**(2):385–9.
34. Hadcock JR, Malbon CC. Regulation of beta-adrenergic receptors by "permissive" hormones: glucocorticoids increase steady-state levels of receptor mRNA. *Proc Natl Acad Sci USA* 1988;**85**(22):8415–9.
35. Zhao M, Célérier I, Bousquet E, et al. Mineralocorticoid receptor is involved in rat and human ocular chorioretinopathy. *J Clin Invest* 2012;**122**(7):2672–9.
36. Ross A, Ross AH, Mohamed Q. Review and update of central serous chorioretinopathy. *Curr Opin Ophthalmol* 2011;**22**(3):166–73. <http://dx.doi.org/10.1097/ICU.0b013e318283459826>.
37. Klein ML, Van Buskirk EM, Friedman E, Gragoudas E, Chandra S. Experience with nontreatment of central serous choroidopathy. *Arch Ophthalmol* 1974;**91**(4):247–50.
38. Rudvari SS, Goff MJ, Fu AD, et al. The natural history of pigment epithelial detachment associated with central serous chorioretinopathy. *Retina* 2007;**27**(9):1168–73. <http://dx.doi.org/10.1097/IAE.0b013e318156db8a>.
39. Aggio FB, Roisman L, Melo GB, Lavinsky D, Cardillo JA, Farah ME. Clinical factors related to visual outcome in central serous chorioretinopathy. *Retina* 2010;**30**(7):1128–34. <http://dx.doi.org/10.1097/IAE.0b013e3181cdf381>.
40. Baran NV, Gürlü VP, Esgin H. Long-term macular function in eyes with central serous chorioretinopathy. *Clin Experiment Ophthalmol* 2005;**33**(4):369–72. <http://dx.doi.org/10.1111/j.1442-9071.2005.01027.x>.
41. Bujarborua D. Long-term follow-up of idiopathic central serous chorioretinopathy without laser. *Acta Ophthalmol Scand* 2001;**79**(4):417–21.
42. Folk JC, Thompson HS, Han DP, Brown CK. Visual function abnormalities in central serous retinopathy. *Arch Ophthalmol* 1984;**102**(9):1299–302.
43. Koskela P, Laatikainen L, von Dickhoff K. Contrast sensitivity after resolution of central serous retinopathy. *Graefes Arch Clin Exp Ophthalmol* 1994;**232**(8):473–6.
44. Maaranen TH, Tuppurainen KT, Mäntyjärvi MI. Color vision defects after central serous chorioretinopathy. *Retina* 2000;**20**(6):633–7.
45. Levy J, Marcus M, Belfair N, Klemperer I, Lifshitz T. Central serous chorioretinopathy in patients receiving systemic corticosteroid therapy. *Can J Ophthalmol* 2005;**40**(2):217–21. [http://dx.doi.org/10.1016/S0008-4182\(05\)80040-7](http://dx.doi.org/10.1016/S0008-4182(05)80040-7).
46. Conrad R, Geiser F, Kleiman A, Zur B, Karpawitz-Godt A. Temperament and character personality profile and illness-related stress in central serous chorioretinopathy. *Sci World J* 2014;**2014**:631687. <http://dx.doi.org/10.1155/2014/631687>.
47. Sahin A, Bez Y, Kaya MC, Türkcü FM, Sahin M, Yüksel H. Psychological distress and poor quality of life in patients with central serous chorioretinopathy. *Semin Ophthalmol* 2014;**29**(2):73–6. <http://dx.doi.org/10.3109/08820538.2013.793728>.
48. Yannuzzi LA. Central serous chorioretinopathy: a personal perspective. *Am J Ophthalmol* 2010;**149**(3):361–3. <http://dx.doi.org/10.1016/j.ajo.2009.11.017>.
49. Mitsui Y, Matsubara M, Kanagawa M. Xenon light-exposure as a treatment of central serous retinopathy (a preliminary report). *Nihon Ganka Kyo* 1969;**20**(3):291–4.
50. Slusher MM. Krypton red laser photocoagulation in selected cases of central serous chorioretinopathy. *Retina* 1986;**6**(2):81–4.
51. Novak MA, Singerman LJ, Rice TA. Krypton and argon laser photocoagulation for central serous chorioretinopathy. *Retina* 1987;**7**(3):162–9.
52. Robertson DM, Ilstrup D. Direct, indirect, and sham laser photocoagulation in the management of central serous chorioretinopathy. *Am J Ophthalmol* 1983;**95**(4):457–66.
53. Leaver P, Williams C. Argon laser photocoagulation in the treatment of central serous retinopathy. *Br J Ophthalmol* 1979;**63**(10):674–7.
54. Ficker L, Vafidis G, While A, Leaver P. Long-term follow-up of a prospective trial of argon laser photocoagulation in the treatment of central serous retinopathy. *Br J Ophthalmol* 1988;**72**(11):829–34.
55. Fok ACT, Chan PPM, Lam DSC, Lai TYY. Risk factors for recurrence of serous macular detachment in untreated patients with central serous chorioretinopathy. *Ophthalmic Res* 2011;**46**(3):160–3. <http://dx.doi.org/10.1159/000324599>.
56. Chen S-N, Hwang J-F, Tseng L-F, Lin C-J. Subthreshold diode micropulse photocoagulation for the treatment of chronic central serous chorioretinopathy with juxtafoveal leakage. *Ophthalmology* 2008;**115**(12):2229–34. <http://dx.doi.org/10.1016/j.ophtha.2008.08.026>.
57. Lanzetta P, Furlan F, Morgante L, Veritti D, Bandello F. Nonvisible subthreshold micropulse diode laser (810 nm) treatment of central serous chorioretinopathy. A pilot study. *Eur J Ophthalmol* 2008;**18**(6):934–40.

58. Gupta B, Elagouz M, McHugh D, Chong V, Sivaprasad S. Micropulse diode laser photocoagulation for central serous chorio-retinopathy. *Clin Experiment Ophthalmol* 2009;**37**(8):801–5. <http://dx.doi.org/10.1111/j.1442-9071.2009.02157.x>.
59. Ricci F, Missirolli F, Regine F, Grossi M, Dorin G. Indocyanine green enhanced subthreshold diode-laser micropulse photocoagulation treatment of chronic central serous chorioretinopathy. *Graefes Arch Clin Exp Ophthalmol* 2009;**247**(5):597–607. <http://dx.doi.org/10.1007/s00417-008-1014-1>.
60. Verma L, Sinha R, Venkatesh P, Tewari HK. Comparative evaluation of diode laser versus argon laser photocoagulation in patients with central serous retinopathy: a pilot, randomized controlled trial ISRCTN84128484. *BMC Ophthalmol* 2004;**4**:15. <http://dx.doi.org/10.1186/1471-2415-4-15>.
61. Kawamura R, Ideta H, Hori H, et al. Transpupillary thermotherapy for atypical central serous chorioretinopathy. *Clin Ophthalmol* 2012;**6**:175–9. <http://dx.doi.org/10.2147/OPHT.S28239>.
62. Shukla D, Kolluru C, Vignesh TP, Karthikprakash S, Kim R. Transpupillary thermotherapy for subfoveal leaks in central serous chorioretinopathy. *Eye (Lond)* 2008;**22**(1):100–6. <http://dx.doi.org/10.1038/sj.eye.6702449>.
63. Hussain N, Khanna R, Hussain A, Das T. Transpupillary thermotherapy for chronic central serous chorioretinopathy. *Graefes Arch Clin Exp Ophthalmol* 2006;**244**(8):1045–51. <http://dx.doi.org/10.1007/s00417-005-0175-4>.
64. Giudice GLo, de Belvis V, Tavolato M, Galan A. Large-spot subthreshold transpupillary thermotherapy for chronic serous macular detachment. *Clin Ophthalmol* 2011;**5**:355–60. <http://dx.doi.org/10.2147/OPHT.S16014>.
65. Chan W-M, Lai TYY, Lai RYK, Liu DTL, Lam DSC. Half-dose verteporfin photodynamic therapy for acute central serous chorioretinopathy: one-year results of a randomized controlled trial. *Ophthalmology* 2008;**115**(10):1756–65. <http://dx.doi.org/10.1016/j.ophtha.2008.04.014>.
66. Schmidt-Erfurth U, Laqua H, Schlötzer-Schrehard U, Viestenz A, Naumann GOH. Histopathological changes following photodynamic therapy in human eyes. *Arch Ophthalmol* 2002;**120**(6):835–44.
67. Tarantola RM, Law JC, Recchia FM, Sternberg P, Agarwal A. Photodynamic therapy as treatment of chronic idiopathic central serous chorioretinopathy. *Lasers Surg Med* 2008;**40**(10):671–5. <http://dx.doi.org/10.1002/lsm.20720>.
68. Chan W-M, Lam DSC, Lai TYY, Tam B, Liu DTL, Chan CKM. Choroidal vascular remodelling in central serous chorioretinopathy after indocyanine green guided photodynamic therapy with verteporfin: a novel treatment at the primary disease level. *Br J Ophthalmol* 2003;**87**:1453–9.
69. Inoue R, Sawa M, Tsujikawa M, Gomi F. Association between the efficacy of photodynamic therapy and indocyanine green angiography findings for central serous chorioretinopathy. *Am J Ophthalmol* 2010;**149**(3):441–6.e1–2. <http://dx.doi.org/10.1016/j.ajo.2009.10.011>.
70. Moon JW, Yu HG, Kim TW, Kim HC, Chung H. Prognostic factors related to photodynamic therapy for central serous chorioretinopathy. *Graefes Arch Clin Exp Ophthalmol* 2009;**247**(10):1315–23. <http://dx.doi.org/10.1007/s00417-009-1104-8>.
71. Tsakonas GD, Kotsolis AI, Koutsandrea C, Georgalas I, Papaconstantinou D, Ladas ID. Multiple spots of photodynamic therapy for the treatment of severe chronic central serous chorioretinopathy. *Clin Ophthalmol* 2012;**6**:1639–44. <http://dx.doi.org/10.2147/OPHT.S35733>.
72. Ruiz-Moreno JM, Lugo FL, Armada F, et al. Photodynamic therapy for chronic central serous chorioretinopathy. *Acta Ophthalmol* 2010;**88**(3):371–6. <http://dx.doi.org/10.1111/j.1755-3768.2008.01408.x>.
73. Copete S, Ruiz-Moreno JM, Cava C, Montero JA. Retinal thickness changes following photodynamic therapy in chronic central serous chorioretinopathy. *Graefes Arch Clin Exp Ophthalmol* 2012;**250**(6):803–8. <http://dx.doi.org/10.1007/s00417-011-1900-9>.
74. Vasconcelos H, Marques I, Santos AR. Long-term chorioretinal changes after photodynamic therapy for chronic central serous chorioretinopathy. *Graefes Arch Clin Exp Ophthalmol* 2013;**251**(7):1697–705. <http://dx.doi.org/10.1007/s00417-013-2270-2>.
75. Lee PY, Kim KS, Lee WK. Severe choroidal ischemia following photodynamic therapy for pigment epithelial detachment and chronic central serous chorioretinopathy. *Jpn J Ophthalmol* 2009;**53**(1):52–6. <http://dx.doi.org/10.1007/s10384-008-0613-z>.
76. Reibaldi M, Cardascia N, Longo A, et al. Standard-fluence versus low-fluence photodynamic therapy in chronic central serous chorioretinopathy: a nonrandomized clinical trial. *Am J Ophthalmol* 2010;**149**(2):307–315.e2. <http://dx.doi.org/10.1016/j.ajo.2009.08.026>.
77. Lai TYY, Chan W-M, Li H, Lai RYK, Liu DTL, Lam DSC. Safety enhanced photodynamic therapy with half dose verteporfin for chronic central serous chorioretinopathy: a short term pilot study. *Br J Ophthalmol* 2006;**90**(7):869–74. <http://dx.doi.org/10.1136/bjo.2006.090282>.
78. Kim S-W, Oh J, Oh IK, Huh K. Retinal pigment epithelial tear after half fluence PDT for serous pigment epithelial detachment in central serous chorioretinopathy. *Ophthalmic Surg Lasers Imag* 2009;**40**(3):300–3.
79. Lim JW, Kang SW, Kim Y-T, Chung SE, Lee SW. Comparative study of patients with central serous chorioretinopathy undergoing focal laser photocoagulation or photodynamic therapy. *Br J Ophthalmol* 2011;**95**(4):514–7. <http://dx.doi.org/10.1136/bjo.2010.182121>.
80. Kim KS, Lee WK, Lee SB. Half-dose photodynamic therapy targeting the leakage point on the fluorescein angiography in acute central serous chorioretinopathy: a pilot study. *Am J Ophthalmol* 2014;**157**(2):366–373.e1. <http://dx.doi.org/10.1016/j.ajo.2013.10.013>.
81. Maruko I, Iida T, Sugano Y, Ojima A, Ogasawara M, Spaide RF. Subfoveal choroidal thickness after treatment of central serous chorioretinopathy. *Ophthalmology* 2010;**117**(9):1792–9. <http://dx.doi.org/10.1016/j.ophtha.2010.01.023>.
82. Ratanasukon M, Thongthong K, Bhurayanontachai P, Jirarattanasopa P. Photoreceptor disruption in central serous chorioretinopathy treated by half-dose photodynamic therapy. *Clin Ophthalmol* 2013;**7**:87–92. <http://dx.doi.org/10.2147/OPHT.S39584>.
83. Karakus SH, Basarir B, Pinarci EY, Kirandi EU, Demirok A. Long-term results of half-dose photodynamic therapy for chronic central serous chorioretinopathy with contrast sensitivity changes. *Eye (Lond)* 2013;**27**(5):612–20. <http://dx.doi.org/10.1038/eye.2013.24>.
84. Dang Y, Sun X, Xu Y, et al. Subfoveal choroidal thickness after photodynamic therapy in patients with acute idiopathic central serous chorioretinopathy. *Ther Clin Risk Manage* 2014;**10**:37–43. <http://dx.doi.org/10.2147/TCRM.S54213>.
85. Zhao M-W, Zhou P, Xiao H-X, et al. Photodynamic therapy for acute central serous chorioretinopathy: the safe effective lowest dose of verteporfin. *Retina* 2009;**29**(8):1155–61. <http://dx.doi.org/10.1097/IAE.0b013e3181a6c028>.
86. Uetani R, Ito Y, Oiwa K, Ishikawa K, Terasaki H. Half-dose vs one-third-dose photodynamic therapy for chronic central serous chorioretinopathy. *Eye (Lond)* 2012;**26**(5):640–9. <http://dx.doi.org/10.1038/eye.2012.66>.
87. Nicolò M, Zoli D, Musolino M, Traverso CE. Association between the efficacy of half-dose photodynamic therapy with indocyanine green angiography and optical coherence tomography findings in the treatment of central serous chorioretinopathy. *Am J Ophthalmol* 2012;**153**(3):474–480.e1. <http://dx.doi.org/10.1016/j.ajo.2011.08.015>.
88. Alcubierre R, Arias L, Lorenzo D, Pujol O, Rubio M. Low-fluence photodynamic therapy in chronic central serous chorioretinopathy. *Arch la Soc Española Oftalmol* 2012;**87**(1):3–8. <http://dx.doi.org/10.1016/j.oftale.2012.04.006>, English Ed..
89. Butler AL, Fung AT, Merkur AB, Albani DA, Forooghian F. Very minimal fluence photodynamic therapy for chronic central serous chorioretinopathy. *Can J Ophthalmol* 2012;**47**(1):42–4. <http://dx.doi.org/10.1016/j.cjco.2011.12.020>.
90. Bae SH, Heo JW, Kim C, et al. A randomized pilot study of low-fluence photodynamic therapy versus intravitreal ranibizumab for chronic central serous chorioretinopathy. *Am J Ophthalmol* 2011;**152**(5):784–92.e2. <http://dx.doi.org/10.1016/j.ajo.2011.04.008>.
91. Lee T-G, Kim JE. Photodynamic therapy for steroid-associated central serous chorioretinopathy. *Br J Ophthalmol* 2011;**95**(4):518–23. <http://dx.doi.org/10.1136/bjo.2010.181149>.
92. Ohkuma Y, Hayashi T, Sakai T, Watanabe A, Tsuneoka H. One-year results of reduced fluence photodynamic therapy for central serous chorioretinopathy: the outer nuclear layer thickness is associated with visual prognosis. *Graefes Arch Clin Exp Ophthalmol* 2013;**251**(8):1909–17. <http://dx.doi.org/10.1007/s00417-013-2289-4>.



93. Kang NH, Kim YT. Change in subfoveal choroidal thickness in central serous chorioretinopathy following spontaneous resolution and low-fluence photodynamic therapy. *Eye (Lond)* 2013;**27**(3):387–91. <http://dx.doi.org/10.1038/eye.2012.273>.
94. Nicoló M, Eandi CM, Alovici C, et al. Half-fluence versus half-dose photodynamic therapy in chronic central serous chorioretinopathy. *Am J Ophthalmol* 2014;**157**(5):1033–7. <http://dx.doi.org/10.1016/j.ajo.2014.01.022>.
95. Seong HK, Bae JH, Kim ES, Han JR, Nam WH, Kim HK. Intravitreal bevacizumab to treat acute central serous chorioretinopathy: short-term effect. *Ophthalmologica* 2009;**223**(5):343–7. <http://dx.doi.org/10.1159/000224782>.
96. Schaal KB, Hoeh AE, Scheuerle A, Schuett F, Dithmar S. Intravitreal bevacizumab for treatment of chronic central serous chorioretinopathy. *Eur J Ophthalmol* 2009;**19**(4):613–7.
97. Lim JW, Kim MU, Shin M-C. Aqueous humor and plasma levels of vascular endothelial growth factor and interleukin-8 in patients with central serous chorioretinopathy. *Retina* 2010;**30**(9):1465–71. <http://dx.doi.org/10.1097/IAE.0b013e3181d8e7fe>.
98. Shin MC, Lim JW. Concentration of cytokines in the aqueous humor of patients with central serous chorioretinopathy. *Retina* 2011;**31**(9):1937–43. <http://dx.doi.org/10.1097/IAE.0b013e31820a6a17>.
99. Jung SH, Kim K-A, Sohn SW, Yang SJ. Cytokine levels of the aqueous humour in central serous chorioretinopathy. *Clin Exp Optom* 2014;**97**(3):264–9. <http://dx.doi.org/10.1111/cxo.12125>.
100. Bae SH, Heo J, Kim C, et al. Low-fluence photodynamic therapy versus ranibizumab for chronic central serous chorioretinopathy: one-year results of a randomized trial. *Ophthalmology* 2014;**121**(2):558–65. <http://dx.doi.org/10.1016/j.ophtha.2013.09.024>.
101. Lim SJ, Roh MI, Kwon OW. Intravitreal bevacizumab injection for central serous chorioretinopathy. *Retina* 2010;**30**(1):100–6. <http://dx.doi.org/10.1097/IAE.0b013e3181bcf0b4>.
102. Arevalo JF, Espinoza JV. Single-session combined photodynamic therapy with verteporfin and intravitreal anti-vascular endothelial growth factor therapy for chronic central serous chorioretinopathy: a pilot study at 12-month follow-up. *Graefes Arch Clin Exp Ophthalmol* 2011;**249**(8):1159–66. <http://dx.doi.org/10.1007/s00417-011-1651-7>.
103. Aydin E. The efficacy of intravitreal bevacizumab for acute central serous chorioretinopathy. *J Ocul Pharmacol Ther* 2013;**29**(1):10–3. <http://dx.doi.org/10.1089/jop.2012.0072>.
104. Semeraro F, Romano MR, Danzi P, Morescalchi F, Costagliola C. Intravitreal bevacizumab versus low-fluence photodynamic therapy for treatment of chronic central serous chorioretinopathy. *Jpn J Ophthalmol* 2012;**56**(6):608–12. <http://dx.doi.org/10.1007/s10384-012-0162-3>.
105. Lee ST, Adelman RA. The treatment of recurrent central serous chorioretinopathy with intravitreal bevacizumab. *J Ocul Pharmacol Ther* 2011;**27**(6):611–4. <http://dx.doi.org/10.1089/jop.2011.0045>.
106. Torres-Soriano ME, García-Aguirre G, Kon-Jara V, et al. A pilot study of intravitreal bevacizumab for the treatment of central serous chorioretinopathy (case reports). *Graefes Arch Clin Exp Ophthalmol* 2008;**246**(9):1235–9. <http://dx.doi.org/10.1007/s00417-008-0856-x>.
107. Lim JW, Kim MU. The efficacy of intravitreal bevacizumab for idiopathic central serous chorioretinopathy. *Graefes Arch Clin Exp Ophthalmol* 2011;**249**(7):969–74. <http://dx.doi.org/10.1007/s00417-010-1581-9>.
108. Montero JA, Ruiz-Moreno JM, Fernandez-Muñoz M. Intravitreal bevacizumab to treat choroidal neovascularization following photodynamic therapy in central serous chorioretinopathy. *Eur J Ophthalmol* 2011;**21**(4): 503–5. doi: <http://dx.doi.org/10.5301/EJO.2011.6290>.
109. Chan W-M, Lai TYY, Liu DTL, Lam DSC. Intravitreal bevacizumab (avastin) for choroidal neovascularization secondary to central serous chorioretinopathy, secondary to punctate inner choroidopathy, or of idiopathic origin. *Am J Ophthalmol* 2007;**143**(6):977–83. <http://dx.doi.org/10.1016/j.ajo.2007.02.039>.
110. Meyerle CB, Freund KB, Bhatnagar P, Shah V, Yannuzzi LA. Ketoconazole in the treatment of chronic idiopathic central serous chorioretinopathy. *Retina* 2007;**27**(7):943–6. <http://dx.doi.org/10.1097/IAE.0b013e318050ca69>.
111. Golshahi A, Klingmüller D, Holz FG, Eter N. Ketoconazole in the treatment of central serous chorioretinopathy: a pilot study. *Acta Ophthalmol* 2010;**88**(5):576–81. <http://dx.doi.org/10.1111/j.1755-3768.2008.01467.x>.
112. Nielsen JS, Jampol LM. Oral mifepristone for chronic central serous chorioretinopathy. *Retina* 2011;**31**(9):1928–36. <http://dx.doi.org/10.1097/IAE.0b013e31821c3ef6>.
113. Bousquet E, Beydoun T, Zhao M, Hassan L, Offret O, Behar-Cohen F. Mineralocorticoid receptor antagonism in the treatment of chronic central serous chorioretinopathy: a pilot study. *Retina* 2013;**33**(10):2096–102. <http://dx.doi.org/10.1097/IAE.0b013e318297a07a>.
114. Maier M, Stumpf S, Feucht N, Strobl P, Rath V, Lohmann CP. Mineralocorticoid receptor antagonists as treatment option for acute and chronic central serous chorioretinopathy. *Ophthalmologie* 2014;**111**(2):173–80. <http://dx.doi.org/10.1007/s00347-013-3001-0>.
115. Breukink MB, den Hollander AI, Keunen JEE, Boon CJF, Hoyng CB. The use of eplerenone in therapy-resistant chronic central serous chorioretinopathy. *Acta Ophthalmol* 2014. <http://dx.doi.org/10.1111/aos.12392>.
116. Gruszka A. Potential involvement of mineralocorticoid receptor activation in the pathogenesis of central serous chorioretinopathy: case report. *Eur Rev Med Pharmacol Sci* 2013;**17**(10):1369–73.
117. Steinle NC, Gupta N, Yuan A, Singh RP. Oral rifampin utilisation for the treatment of chronic multifocal central serous retinopathy. *Br J Ophthalmol* 2012;**96**(1):10–3. <http://dx.doi.org/10.1136/bjophthalmol-2011-300183>.
118. Ravage ZB, Packo KH, Creticos CM, Merrill PT. Chronic central serous chorioretinopathy responsive to rifampin. *Retin Cases Br Rep* 2012;**6**(1):129–32.
119. Nelson J, Saggau DD, Nielsen JS. Rifampin induced hepatotoxicity during treatment for chronic central serous chorioretinopathy. *Retin Cases Br Rep* 2014;**8**(1):70–2.
120. Forooghian F, Meleth AD, Cukras C, Chew EY, Wong WT, Meyerle CB. Finasteride for chronic central serous chorioretinopathy. *Retina* 2011;**31**(4):766–71. <http://dx.doi.org/10.1097/IAE.0b013e3181f04a35>.
121. Tatham A, Macfarlane A. The use of propranolol to treat central serous chorioretinopathy: an evaluation by serial OCT. *J Ocul Pharmacol Ther* 2006;**22**(2):145–9. <http://dx.doi.org/10.1089/jop.2006.22.145>.
122. Avci R, Deutman AF. Treatment of central serous choroidopathy with the beta receptor blocker metoprolol (preliminary results). *Klin Monbl Augenheilkd* 1993;**202**(3):199–205. <http://dx.doi.org/10.1055/s-2008-1045583>.
123. Chrapek O, Jirkova B, Kandrnl V, Rehak J, Sin M. Treatment of central serous chorioretinopathy with beta-blocker metipranolol. *Biomed Pap Med Fac Univ Palacky Olomouc Czech Repub* 2013;**3**–6. <http://dx.doi.org/10.5507/bp.2013.015>.
124. Pikkal J, Beiran I, Ophir A, Miller B. Acetazolamide for central serous retinopathy. *Ophthalmology* 2002;**109**(9):1723–5.
125. Caccavale A, Imperato M, Romanazzi F, Negri A, Porta A, Ferentini F. A new strategy of treatment with low-dosage acetyl salicylic acid in patients affected by central serous chorioretinopathy. *Med Hypotheses* 2009;**73**(3):435–7. <http://dx.doi.org/10.1016/j.mehy.2009.03.036>.
126. Caccavale A, Romanazzi F, Imperato M, Negri A, Morano A, Ferentini F. Low-dose aspirin as treatment for central serous chorioretinopathy. *Clin Ophthalmol* 2010;**4**:899–903.
127. Giusti C, Mauget-Fajssé M. *Helicobacter pylori* and idiopathic central serous chorioretinopathy. *Swiss Med Wkly* 2004;**134**(27–28):395–8.
128. Giusti C. Association of *Helicobacter pylori* with central serous chorioretinopathy: hypotheses regarding pathogenesis. *Med Hypotheses* 2004;**63**(3):524–7. <http://dx.doi.org/10.1016/j.mehy.2004.02.020>.
129. Rahbani-Nobar MB, Javazadeh A, Ghojzadeh L, Rafeey M, Ghorbanihaghjo A. The effect of *Helicobacter pylori* treatment on remission of idiopathic central serous chorioretinopathy. *Mol Vis* 2011;**17**(January):99–103.
130. Dang Y, Mu Y, Zhao M, Li L, Guo Y, Zhu Y. The effect of eradicating *Helicobacter pylori* on idiopathic central serous chorioretinopathy patients. *Ther Clin Risk Manage* 2013;**9**:355–60. <http://dx.doi.org/10.2147/TCRM.S50407>.
131. Kurup SK, Oliver A, Emanuelli A, Hau V, Callanan D. Low-dose methotrexate for the treatment of chronic central serous chorioretinopathy: a retrospective analysis. *Retina* 2012;**32**(10):2096–101. <http://dx.doi.org/10.1097/IAE.0b013e31825dd281>.