

# Successful treatment of cutaneous squamous cell carcinoma with intralesional cryosurgery

## Case report

Chaw-Ning Lee, MD<sup>a</sup>, Shin-Chen Pan, MD, PhD<sup>b</sup>, Julia Yu-Yun Lee, MD<sup>a</sup>, Tak-Wah Wong, MD, PhD<sup>a,c,\*</sup>

### Abstract

**Background:** Wide excision or Mohs surgery is the standard treatment of skin squamous cell carcinoma (SCC). Superficial SCC or tumor smaller than 1 cm has been treated successfully with open spray cryosurgery. Larger tumor may not be as effective because tissue destruction is usually superficial. Intralesional cryosurgery (IC) may provide a deeper and better cell killing effect in larger tumors. We investigated the safety and efficacy of treating nodular SCC in 4 patients with IC.

**Methods:** Four patients with nodular SCC/keratoacanthoma (tumor size, 1–2.5 cm, average 1.48 cm) on the face and extremity were treated with IC. An 18-ga needle was connected to a cryogun and inserted into the center of the tumor after local anesthesia. The tumors were treated with 2 freeze–thaw cycles with a 5- to 10-mm free margin. Additional IC or open spray cryosurgery was applied if residual tumor was noted during monthly follow-up.

**Results:** No patient required analgesics or experienced wound infection after the procedures. After IC, all tumors reduced 40% to 75% in size within 1 week. Two patients received 1 additional spray cryosurgery. Complete remission was noted in all tumors (100%) in 2 months. No recurrence was noted during follow-up (average 5.1 years). All patients were satisfied with the results.

**Conclusion:** Our observation suggests that IC can be simple and effective alternative treatment for SCC patients whose condition is not suitable for or who refused operation.

**Abbreviations:** IC = intralesional cryosurgery, KA = keratoacanthoma, SCC = squamous cell carcinoma.

**Keywords:** case report, intralesional cryosurgery, keratoacanthoma, squamous cell carcinoma

## 1. Introduction

Cutaneous squamous cell carcinoma (SCC) is the second most common nonmelanoma skin cancers.<sup>[1]</sup> Keratoacanthoma (KA) is a variant of SCC with a tendency to self-regression. However, some KA may progress with tumor metastasis as the conventional SCC. The National Comprehensive Cancer Network guideline for the treatment of local, low-risk SCC is complete surgical excision with at least 4 to 6 mm safety margins, or Mohs

micrographic surgery if feasible.<sup>[2,3]</sup> Alternative treatments may be required for patients who are not suitable for or refuse surgery. Cryosurgery has been used for different benign, premalignant, and malignant skin lesions by different application methods such as cotton-tipped applicator, cryoprobe, superficial spray, and intralesional.<sup>[4]</sup>

Superficial, in situ, or SCC less and equal to 1 cm has been successfully treated with cryosurgery with results comparable to traditional surgical excision.<sup>[5,6]</sup> Intralesional cryosurgery (IC) has been applied to treat keloids in 1990s.<sup>[7]</sup> Weshahy et al<sup>[8]</sup> reported the success of treating basal cell carcinoma with IC. Taking the advantage of possible more effective cell killing from deep freezing of the tumor tissue by inserting a cooling needle inside SCC, we treated 4 elderly patients with nodular SCC/KA with IC.

## 2. Patients and methods

### 2.1. Case series

Four elderly Taiwanese men (Table 1) with nodular SCC or KA larger than 1 cm were treated with IC in the outpatient clinic of the Department of Dermatology, National Cheng Kung University Hospital after the diagnosis was confirmed histopathologically. Ethical approval and informed consent were not required for this case report as it did not relate to the patient's privacy and IC is not a new treatment. No regional lymphadenopathy or distant metastasis was noted during physical examination. After local anesthesia, an 18-ga needle was connected to a liquid nitrogen gun (Cry-AC; Brymill Cryogenic Systems, Basingstoke, United Kingdom) and inserted into the

Editor: Jianfeng Li.

The study was funded by National Cheng Kung University Hospital grant NCKUH-10505023.

The authors have no conflicts of interest to disclose.

<sup>a</sup>Department of Dermatology, <sup>b</sup>Section of Plastic and Reconstructive Surgery, Department of Surgery, National Cheng Kung University Hospital, <sup>c</sup>Department of Biochemistry and Molecular Biology, College of Medicine, National Cheng Kung University, Tainan, Taiwan.

\*Correspondence: Tak-Wah Wong, Department of Dermatology, National Cheng Kung University Medical College and Hospital, National Cheng Kung University, 138 Sheng Li Road, Tainan 704, Taiwan (e-mail: Dr.kentwwong@gmail.com; twwong@mail.ncku.edu.tw)

Copyright © 2016 the Author(s). Published by Wolters Kluwer Health, Inc. All rights reserved.

This is an open access article distributed under the Creative Commons Attribution-NoDerivatives License 4.0, which allows for redistribution, commercial and non-commercial, as long as it is passed along unchanged and in whole, with credit to the author.

Medicine (2016) 95:39(e4991)

Received: 2 July 2016 / Received in final form: 30 August 2016 / Accepted: 7 September 2016

<http://dx.doi.org/10.1097/MD.0000000000004991>

**Table 1****Demographic data and outcomes of 4 patients treated with IC.**

| Patient no. | Age/<br>gender | Size, cm <sup>2</sup> | Location             | Pathology                                      | Treatments                      | Follow-up, y | Treatment<br>outcomes | Cosmetic<br>outcomes |
|-------------|----------------|-----------------------|----------------------|--|---------------------------------|--------------|-----------------------|----------------------|
| 1           | 81/M           | 1 × 1                 | Right shin           | Well differentiated SCC<br>with features of KA | MTX, IC, 1 spray<br>cryosurgery | 9.5          | CR                    | Good                 |
| 2           | 68/M           | 2 × 2                 | Left dorsal hand     | Well differentiated SCC,<br>KA type            | IC, 1 spray<br>cryosurgery      | 5.7          | CR                    | Good                 |
| 3           | 77/M           | 1 × 0.9               | Left popliteal fossa | KA   | IC                              | 3.8          | CR                    | Good                 |
| 4           | 94/M           | 1.2 × 1.4             | Left cheek           | Thick ulcerated well<br>differentiated SCC     | IC                              | 1.4          | CR                    | Good                 |

CR = complete remission, IC = intralesional cryosurgery, KA = keratoacanthoma, MTX = methotrexate, SCC = squamous cell carcinoma.

center along the long axis of the tumor (Fig. 1A). The tumor was treated with 2 freeze–thaw cycles. Freezing time was around 30 to 60 seconds. The end point was ice formation of the whole tumor with at least 5-mm free margins (Fig. 1B). For tumors larger than 1.5 cm, 2 needles were inserted perpendicular at 1/3 and 2/3 of the long (y) axis of the tumor to achieve adequate free margins. Regional lymph node and the tumor were examined at monthly follow-up. Additional IC or spray cryosurgery was performed if there was residual tumor during follow-up.

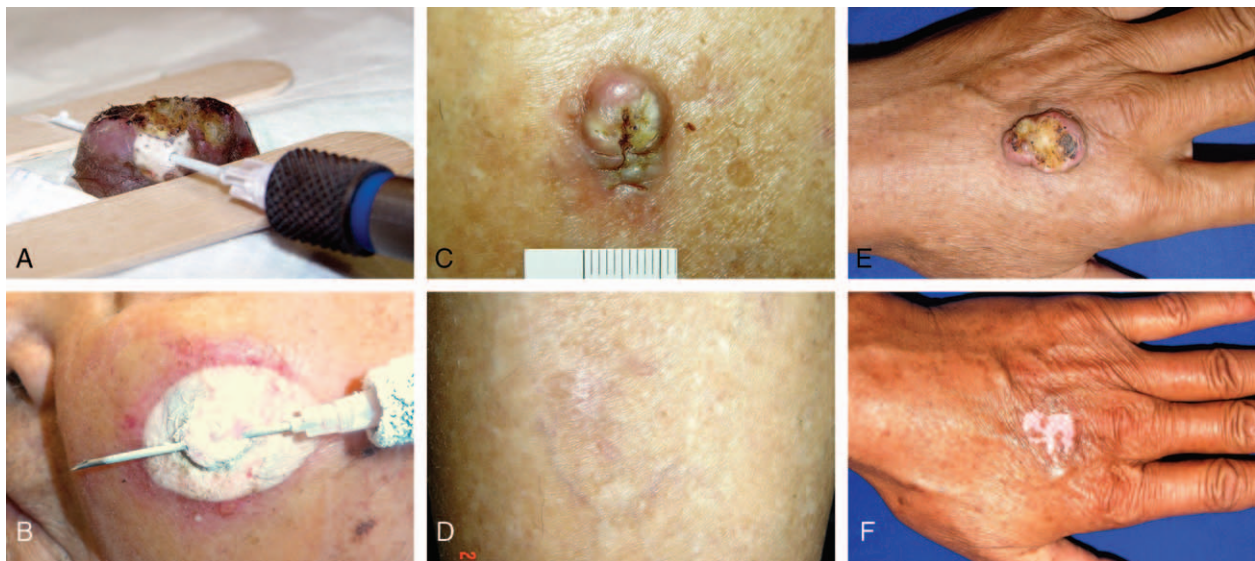
## 2.2. Illustrative cases

Case 1 was an 81-year-old male farmer. He received surgical removal of an SCC on his left hand 6 months ago. Another asymptomatic nodule (1.2 × 1 cm<sup>2</sup>) grew on his right shin (it became smaller after biopsied, Fig. 1C). Skin biopsy revealed well differentiated SCC with features of KA. He refused surgical intervention and was treated with IC after failed 1 intralesional methotrexate 0.12-mL (50 mg/2 mL, Hospira Australia Pty Ltd., Melbourne, Victoria, Australia) injection. Within 1 week, the

tumor reduced around 40%. Spray cryosurgery (3 freeze–thaw cycles with 10-second freezing) was performed 3 weeks after IC because the tumor was too small for IC. No visible tumor was observed by week 6, and no recurrence was noted during follow-up at 9.5 years (Fig. 1D). He died of colon cancer with lung metastasis.

Case 2 was a 68-year-old man who presented with an itchy 2 × 2 × 0.5 cm<sup>3</sup> protruded nodule with central hyperkeratosis over his left dorsal hand for 2 months. Skin biopsy revealed well differentiated SCC, KA type (Fig. 1E). The tumor shrank by 75% 2 weeks after IC. A spray cryosurgery (25 seconds × 2 cycles) was applied at 4 weeks after IC to reinforce the effect. No tumor was observed by week 7. There was no recurrence, and the scar was invisible at 5.7-year follow-up.

Case 3 was a 77-year-old man presented with a 1.1 × 0.9 cm<sup>2</sup> tumor on his left popliteal fossa. The tumor was growing after he was treated with 5 spray cryosurgeries every 2 weeks under the impression of verruca at a local clinic. Skin biopsy confirmed the diagnosis of SCC, KA type. The tumor was treated with IC and became undetectable clinically at week 8. No clinical recurrence of tumor was noted at 3.8-year follow-up.



**Figure 1.** An 18-ga needle was connected to a cryogun and inserted into the center of squamous cell carcinoma (SCC) after local anesthesia. (A) Two wooden tongue blades were placed under the needle to keep frostbites from adjacent normal skin. (B) A 1.2 × 1.4 cm<sup>2</sup> well differentiated SCC on the left cheek of a 94-year-old gentleman (case 4). The tumor was treated with 2 freeze–thaw cycles with 5- to 10-mm free margins. (C) A 1.2 × 1 cm<sup>2</sup> well differentiated SCC with features of keratoacanthoma (KA) appeared on the right shin of an 81-year-old male farmer (case 1). (D) No visible tumor and scar 5 months after treatment. The patient was free of tumor at 9.5 years follow-up. (E) A 68-year-old man (case 2) with a 2 × 2 × 0.5 cm<sup>3</sup> well differentiated SCC, KA type, on his left dorsal hand for 2 months. (F) No tumor was observed 14 weeks and no recurrence at 5.7 years follow-up after intralesional cryosurgery. The skin healed well with hypopigmentation which was recovered 8 months later.

Case 4 was a 94-year-old bedridden man. His medical history was significant for dementia, hypertension, prostate cancer complicated with neurogenic bladder and hip fracture with partial hip replacement. He presented with a 1-month history of fast growing tumor on his left cheek. On examination, a  $1.2 \times 1.4$  cm<sup>2</sup> nodule was noted on his left cheek, which was proved to be well differentiated SCC histologically. His general condition precluded surgery or chemotherapy. He lived in rural area, and it was not easy for him to come for daily radiotherapy. He was finally treated with IC (Fig. 1B). The tumor subsided by week 6 after 1 IC. No additional cryosurgery was needed. He was free of tumor at 1.4-year follow-up.

### 3. Discussion

We described 4 cases of SCC, 3 of them were KA types, in elderly patients who were successfully treated with IC without complications. Takai et al<sup>[1]</sup> showed a regression rate of 98.1% in KA, 33.3% in that of KA-like SCC/KA with malignant transformation.<sup>[1]</sup> With the potential progression as in conventional SCC, we believe that active treatment of SCC, KA type is more advisable than watchful waiting.

There are several large studies showing high cure rates of cryosurgery for nonmelanocytic skin cancers.<sup>[9,10]</sup> In the report by Kuflik,<sup>[11]</sup> most patients were treated by curettage before open spray technique, which achieved a 99% cure rate in 522 cases. The 5-year cure rate in SCC smaller than 2 cm (n=134) was 100%. In dermatology, IC was first introduced by Weshahy<sup>[7]</sup> to treat keloid or hypertrophic scar. A newly developed intralesional cryoneedle, which consists of an elongated double-lumen uninsulated needle (CryoShape; Etgar Group International Ltd., Raanana, Israel) was invented.<sup>[12,13]</sup> The cryoneedle is not available in our country. We simply connected an 18-ga needle to a liquid nitrogen gun as a cryoneedle. This is simple and feasible in most clinics. IC shows more therapeutic effect than spraying in nodular lesions because the lethal zone is located in deep tissue and causes more tumor damage. In comparison to spray cryosurgery, IC induces almost no hypopigmentation of the skin because a deep-seated cryoprobe is less damaging to the epidermal melanocytes. Our results agree with previous report,<sup>[14]</sup> and only 1 patient (25%) developed temporally hypopigmentation on the skin even 3 patients received additional spray cryosurgery (Fig. 1F).

Our study is limited by its small case number. Nevertheless, IC appears safe, simple, and suitable for elevated nodular tumor. All tumors reduced in sizes after 1 IC treatment in our patients. The residual tumor was cleared by additional spray cryosurgery. IC may provide long-term remission as complete clinical remission was noted in all 4 cases during the 1.4 to 9.5 years of follow-up (average 5.1 years). Moreover, the cosmetic outcome was also

highly satisfactory. Nevertheless, it should be noted that IC may not be suitable for patients with conditions or tumor locations where cryosurgery is contraindicated, such as medial canthus or eyelash region to avoid damage of canaliculus or ocular tissue, acral part in patients with poor circulation or poor healing, or location where nerves are fairly superficial with potential of nerve injury. In addition, IC is superior to radiotherapy for its simplicity and free of complications such as radiodermatitis, lymphedema, and secondary cancers.<sup>[15]</sup>

In conclusion, IC can be an effective alternative treatment for elevated, nodular SCC in elder patients, especially those who refuse or whose condition is not suitable for operation. Larger, controlled studies are needed to confirm its safety and efficacy.

### References

- [1] Takai T, Misago N, Murata Y. Natural course of keratoacanthoma and related lesions after partial biopsy: clinical analysis of 66 lesions. *J Dermatol* 2015;42:353–62.
- [2] Brodland DG, Zitelli JA. Surgical margins for excision of primary cutaneous squamous cell carcinoma. *J Am Acad Dermatol* 1992;27:241–8.
- [3] Network NCC. Squamous Cell Skin Cancer (Version 1.2015). [http://www.nccn.org/professionals/physician\\_gls/pdf/squamous.pdf](http://www.nccn.org/professionals/physician_gls/pdf/squamous.pdf). Accessed June 2, 2016.
- [4] Emanuel GK, Julianne HK, Bologna JL, Jorizzo JL, Schaffer JV, et al. Cryosurgery. *Dermatology* 3rd ed. Amsterdam, Netherlands:Elsevier Limited; 2012;Section 20, Ch 138, p2283-2289.
- [5] Ridky TW. Nonmelanoma skin cancer. *J Am Acad Dermatol* 2007;57:484–501.
- [6] Neville JA, Welch E, Leffell DJ. Management of nonmelanoma skin cancer in 2007. *Nat Clin Pract Oncol* 2007;4:462–9.
- [7] Weshahy AH. Intralesional cryosurgery. A new technique using cryoneedles. *J Dermatol Surg Oncol* 1993;19:123–6.
- [8] Weshahy AH, Abdel Hay RM, Metwally D, et al. The efficacy of intralesional cryosurgery in the treatment of small- and medium-sized basal cell carcinoma: a pilot study. *J Dermatolog Treat* 2015;26:147–50.
- [9] Lansbury L, Bath-Hextall F, Perkins W, et al. Interventions for non-metastatic squamous cell carcinoma of the skin: systematic review and pooled analysis of observational studies. *BMJ* 2013;347:f6153.
- [10] Bahner JD, Bordeaux JS. Non-melanoma skin cancers: photodynamic therapy, cryotherapy, 5-fluorouracil, imiquimod, diclofenac, or what? Facts and controversies. *Clin Dermatol* 2013;31:792–8.
- [11] Kuflik EG. Cryosurgery for skin cancer: 30-year experience and cure rates. *Dermatol Surg* 2004;30:297–300.
- [12] Har-Shai Y, Amar M, Sabo E. Intralesional cryotherapy for enhancing the involution of hypertrophic scars and keloids. *Plast Reconstr Surg* 2003;111:1841–52.
- [13] Chopinaud M, Pham AD, Labbe D, et al. Intralesional cryosurgery to treat keloid scars: results from a retrospective study. *Dermatology* 2014;229:263–70.
- [14] Har-Shai Y, Dujovny E, Rohde E, et al. Effect of skin surface temperature on skin pigmentation during contact and intralesional cryosurgery of keloids. *J Eur Acad Dermatol Venereol* 2007;21:191–8.
- [15] Samstein RM, Ho AL, Lee NY, et al. Locally advanced and unresectable cutaneous squamous cell carcinoma: outcomes of concurrent cetuximab and radiotherapy. *J Skin Cancer* 2014;2014:284582.