

Pancreaticoduodenectomy assisted by 3-D visualization reconstruction and portal vein arterialization

A case report (a CARE-compliant article)

Zhao-jie Su, MA^a, Wen-gang Li, MD^{a,*}, Jun-li Huang, MA^a, Lin-feng Xiao, MA^a, Fu-zhen Chen, BA^a, Bo-liang Wang, PhD^b

Abstract

Background: Three-dimensional visualization reconstruction, the 3-D visualization model reconstructed by software using 2-D CT images, has been widely applied in medicine; but it has rarely been applied in pancreaticoduodenectomy. Although the hepatic artery is very important for the liver, it has to be removed when tumor invades it. Therefore, portal vein arterialization has been used in clinic as a remedial measure, but there still is professional debate on portal vein arterialization.

Methods: Here, we report 1 case that was diagnosed with poorly differentiated adenocarcinoma of the duodenum. The tumor had large size and invaded surrounding organs and vessels.

Results: Preliminary diagnoses were poorly differentiated adenocarcinoma of the duodenum and viral hepatitis B. Pancreaticoduodenectomy assisted by 3-D visualization reconstruction and portal vein arterialization were performed in this case. The tumor was removed. Liver function returned to normal limits 1 week after operation. Digital subtraction arteriography showed compensatory artery branches within the liver 1 month after operation.

Conclusion: 3-D visualization reconstruction can provide a reliable assistance for the accurate assessment and surgical design before pancreaticoduodenectomy, and it is certainly worth adopting portal vein arterialization when retention of hepatic artery is impossible or conventional arterial anastomosis is required during pancreaticoduodenectomy.

Keywords: pancreaticoduodenectomy, portal vein arterialization, 3-dimensional visualization reconstruction

1. Introduction

Three-dimensional visualization reconstruction refers to 3-D visualization model reconstructed by software using 2-D computed tomography (CT) images. The IQQA-Liver system developed by EDDA Company is currently the most popular software for 3-D visualization, and XMQB-liver software with independent intellectual property rights has been developed by

Xiamen Qiangben Technology Co., Ltd (China). In recent years, although the 3-D visualization reconstruction technology has achieved better therapeutic effects when being applied in liver surgery, plastic surgery, and orthopedics,^[1] it has been rarely used in pancreaticoduodenectomy. Portal vein arterialization refers to the method of introducing arterial blood into portal veins to prevent liver damages caused by hepatic blood flow insufficiency due to various causes. Hepatic artery is very important for the liver, but it has to be removed when tumor invades it. Therefore, portal vein arterialization has been used in clinic as a remedial measure, but there still is professional debate on portal vein arterialization.^[2] We report here 1 case that underwent pancreaticoduodenectomy assisted by 3-D visualization reconstruction and portal vein arterialization.

2. Case report

All study methods were approved by ethics committee of the Chenggong Hospital Affiliated to Xiamen University. The patient gave written informed consent to participate in this study.

One 33-year-old female patient was admitted to hospital due to repeated onsets of right upper abdomen distension on April 4, 2015. Gastroscopy revealed a mass in duodenal bulb, histopathologic examination suggested poorly differentiated adenocarcinoma of the duodenum, and further immunohistochemistry was recommended in other hospital. The patient has a 10-year history of viral hepatitis B, but no histories of hypertension or diabetes. Physical examinations on admission showed yellow sclera, flat and soft abdomen, tenderness in the epigastrium below xiphoid

Editor: Mahmoud Mohamed Abdelwahab Ali.

Great interests in this case: 3-D visualization reconstruction is important for successful surgery of duodenal cancer.

Funding/support: This study was supported by the National Natural Science Foundation of China (No. 81272246, 81101502, 61271336, 61327001).

The authors have no conflicts of interest to disclose.

^a Department of Hepatobiliary Surgery, Chenggong Hospital Affiliated to Xiamen University, ^b Xiamen Qiangben Technology Co., Ltd, Xiamen, China.

* Correspondence: Wen-gang Li, Department of Hepatobiliary Surgery, Chenggong Hospital Affiliated to Xiamen University, No. 96, Wenyuan Road, Xiamen 361000, China (e-mail: lwg11861@163.com).

Copyright © 2016 the Author(s). Published by Wolters Kluwer Health, Inc. All rights reserved.

This is an open access article distributed under the terms of the Creative Commons Attribution-Non Commercial-No Derivatives License 4.0 (CCBY-NC-ND), where it is permissible to download and share the work provided it is properly cited. The work cannot be changed in any way or used commercially.

Medicine (2016) 95:36(e4697)

Received: 26 April 2016 / Received in final form: 10 July 2016 / Accepted: 2 August 2016

<http://dx.doi.org/10.1097/MD.0000000000004697>

and in the right upper abdominal quadrant without rebound tenderness and palpable masses, and positive stomach water vibration. Liver and spleen were impalpable under ribs and there was no percussion pain in hepatic region and both renal regions. Weak borborygmi were identified and there was no abdominal shifting dullness. Laboratory examination indicated that total bilirubin was $98\ \mu\text{mol/L}$, direct bilirubin was $75\ \mu\text{mol/L}$, and blood routine examination and tumor-related markers were roughly normal. CT scan showed that pylorus and duodenal bulb were thickened, and the boundary of them with hepatic portal, caput pancreatis, choledochus, and gallbladder was obscure with slightly dilated choledochus. This suggested gastrointestinal malignancy (Fig. 1). CT image data stored in the form of DICOM were imported into XMQB-liver system for 3-D visualization reconstruction. The results of 3-D visualization reconstruction included the following information (Fig. 2): location – the tumor is located in the duodenal bulb and hepatic portal, and above pancreas; relation with blood vessels – the tumor surrounds common hepatic artery, proper hepatic artery, gastroduodenal artery, and partial portal vein; and relation with peripheral organs – the tumor completely invades the pylorus and duodenal bulb, and its boundary with the hepatic portal, caput pancreatis, choledochus, and gallbladder is obscure. Based on the 3-D reconstruction results combined with dynamic image and

static model, we could understand the conditions that tumor invaded the caput pancreatis and it surrounded the hepatic portal.

Preliminary diagnoses were poorly differentiated adenocarcinoma of the duodenum and viral hepatitis B. The surgical proposal included exploratory laparotomy and pancreaticoduodenectomy (resection of the invaded vessels and revascularization). The operation was performed under general anesthesia on August 14, 2015. A 20 cm-midline incision was made in the abdomen, and cholestatic liver and swollen gallbladder was seen. One hard mass ($7\text{ cm} \times 6\text{ cm} \times 6\text{ cm}$), surrounding the portal vascular structure, could be palpable at duodenal bulb and hepatic portal; and it was not sharply demarcated from the hepatic portal. Enlarged lymph nodes could be palpable beside greater omentum and common hepatic artery. Duodenal lateral peritoneum was opened by Kocher maneuver. After the 2nd and 3rd segments of duodenum as well as the caput pancreatis were separated from behind the peritoneum, we saw that the caput pancreatis was involved by the tumor. The superior mesenteric artery and superior mesenteric vein were separated along pancreatic inferior border because they were not involved by tumor. Based on the conditions above, we decided to carry out pancreaticoduodenectomy. After the vascular structure in the hepatoduodenal ligament, celiac trunk, common hepatic artery,

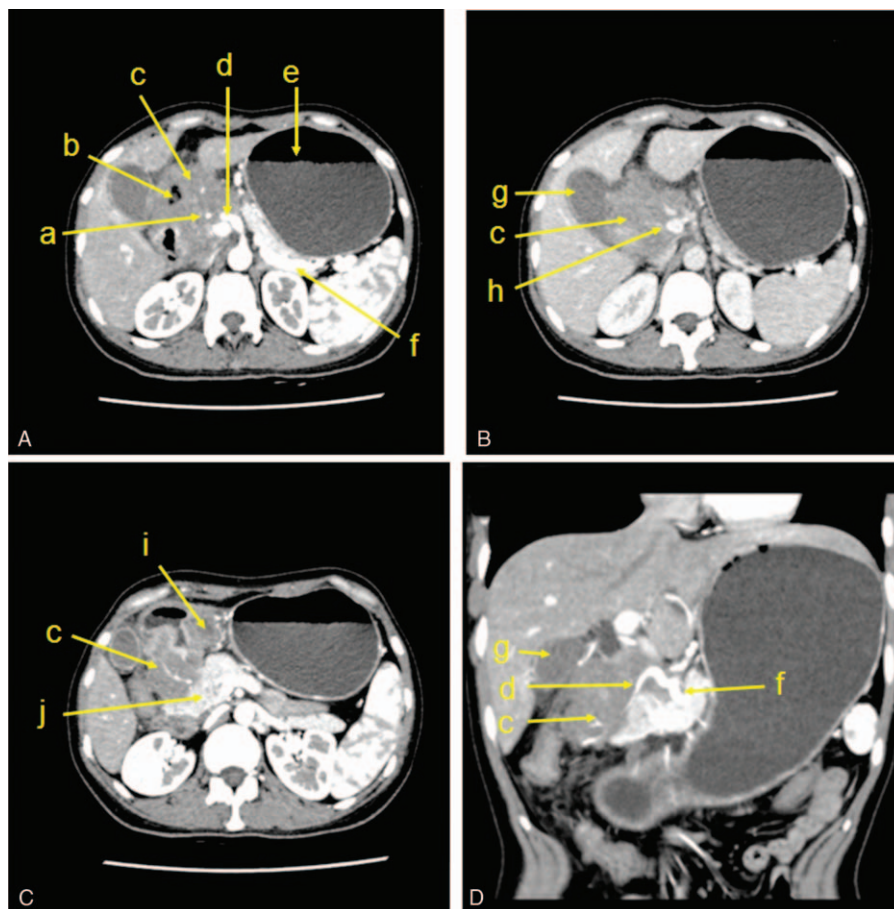


Figure 1. Abdominal CT, (A) (arterial phase): the tumor invades the hepatic portal and gallbladder, and surrounds the proper hepatic artery, right hepatic artery, and left hepatic artery. (B) (Venous phase): the tumor surrounds the portal vein. (C) (Arterial phase): the lower end of the tumor invades the caput pancreatis. (D) (Coronal view in arterial phase): the tumor invades the proper hepatic artery. a: right hepatic artery, b: enteric cavity of duodenum, c: tumor, d: proper hepatic artery, e: stomach, f: splenic artery, g: gallbladder, h: portal vein, i: duodenal bulb, and j: pancreas.

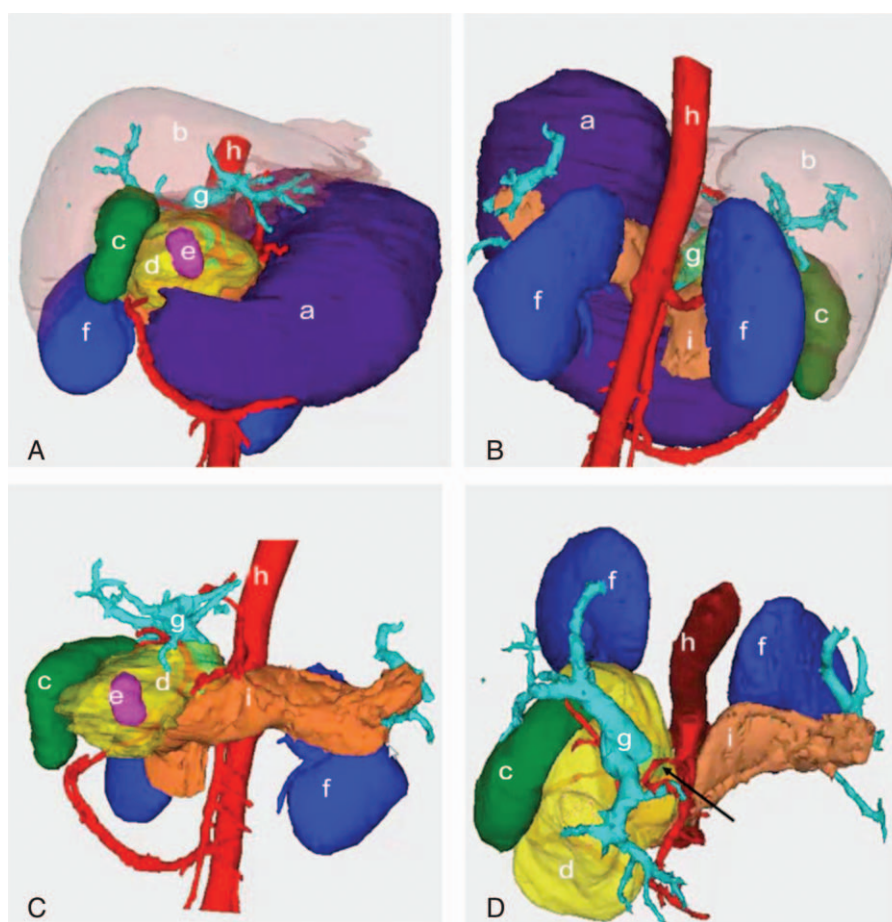


Figure 2. Images obtained by 3-D visualization reconstruction. (A) (Front view): the boundary between tumor and gallbladder is obscure, the tumor surrounds the duodenum and choledochus, but the liver is not invaded by the tumor. (B) (Dorsal view): both kidneys and stomach fail to be invaded by the tumor. (C) The caput pancreatic is severely invaded by the tumor and the portal vein and hepatic artery are surrounded by the tumor also. (D) (Vertical view): the portal vein and hepatic artery are surrounded by the tumor and the arrow indicates the common hepatic artery. a: stomach, b: liver, c: gallbladder, d: tumor, e: duodenum, f: both kidneys, g: portal vein, h: abdominal aorta, and i: pancreas.

and splenic artery were exposed, we found that the proper hepatic artery and gastroduodenal artery were surrounded by tumor, and they could not be completely dissociated. Therefore, we decided to cut off the proper hepatic artery followed by end-to-side anastomosis between the proper hepatic artery and the portal vein. Pancreatic transection was performed through the upper and lower margins of the pancreas on the left side of superior mesenteric vein, and then the greater and lesser gastric curvatures were separated followed by gastric amputation. After the gallbladder was removed and the common hepatic duct was cut off; tumor removal, regional lymphadenectomy, and digestive tract reconstruction were performed (Figs. 3 and 4). The operation lasted for 6.5 hours, and intraoperative blood loss was about 1500 mL. Pathology conformed diffuse large B-cell lymphoma (Fig. 5).

Liver function was dynamically monitored after operation, and it returned to normal limits 1 week later (Fig. 6). One week after operation, color Doppler ultrasound showed portal vein patency, the signal of blood stream from proper hepatic artery into portal vein, 10 cm-inner diameter of the portal vein at the hepatic portal with a high flow velocity of 21 cm/s, and 12 cm-inner diameter at the midpiece of the portal vein with a high flow velocity of 94.8 cm/s (Fig. 7). One month after operation, color Doppler

ultrasound reexamination showed portal vein patency, no marked signal of blood stream in the proper hepatic artery, 8.5 cm-inner diameter of the portal vein at the hepatic portal with a high flow velocity of 22.52 cm/s, and 9.9 cm-inner diameter at the midpiece of the portal vein with a high flow velocity of 50.87 cm/s (Fig. 8). Digital subtraction arteriography was performed through the celiac trunk 1 month after operation, and it showed clear shadow of splenic artery, a compensatory artery branch into the left liver, and no shadow in the proper hepatic artery. Therefore, proper hepatic artery embolization was not performed (Fig. 9). Angiography of superior mesenteric artery revealed clear shadow of mesenteric vessels and a compensatory artery branch into the right liver (Fig. 10). Angiography of abdominal aorta showed compensatory artery branches within the liver (Fig. 11).

3. Discussion

Pancreaticoduodenectomy, mainly applied for surgical treatment of the tumors in caput pancreatitis, is difficult with high risks. It has been reported that the incidence of complications is 15% to 45% and perioperative fatality rate is less than 5% after pancreaticoduodenectomy.^[3] Due to occult pathogenesis and special

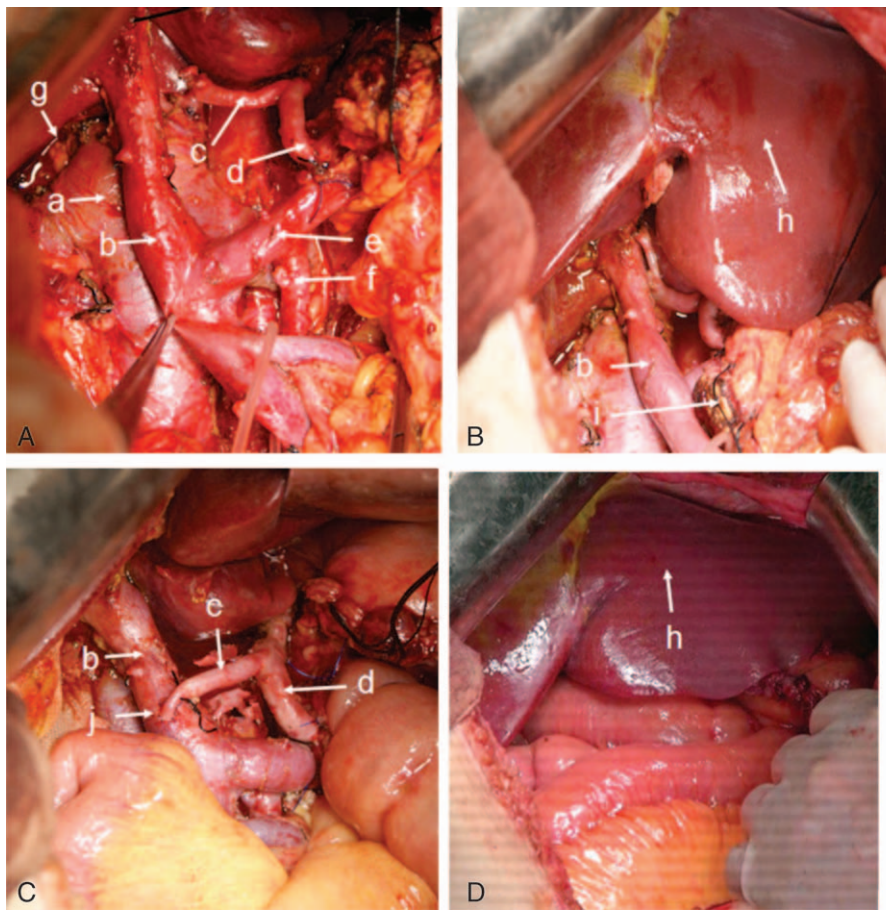


Figure 3. Intraoperative pictures. (A) The tumor is removed and vessels are exposed. (B) The liver before portal vein arterialization. (C) Portal vein-proper hepatic artery arterialization. (D) The liver after portal vein arterialization. a: inferior vena cava, b: portal vein, c: proper hepatic artery, d: splenic artery, e: splenic vein, f: superior mesenteric artery, g: common hepatic duct, h: liver, i: pancreas, and j: anastomotic stoma between portal vein and proper hepatic artery images obtained by 3-D visualization reconstruction.

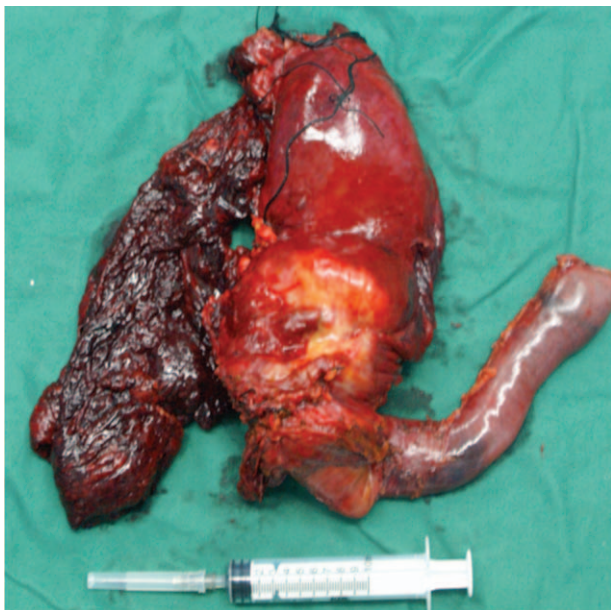

Figure 4. Excisional tumor.

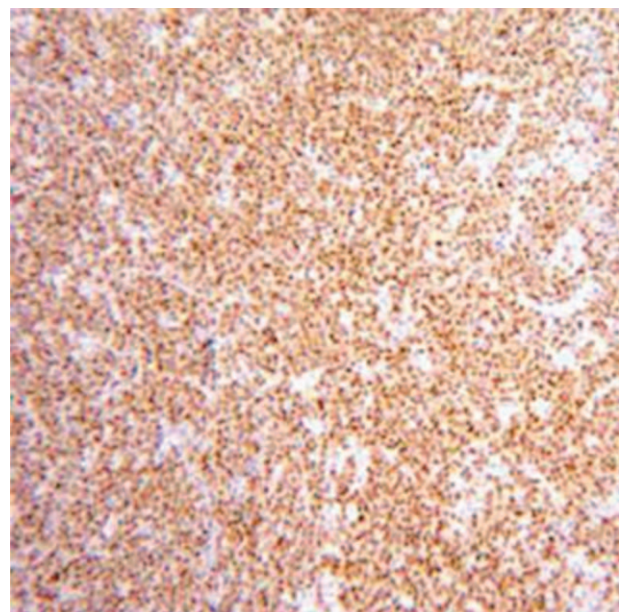


Figure 5. Immunohistochemistry picture of the tumor indicates diffuse large B cell lymphoma.

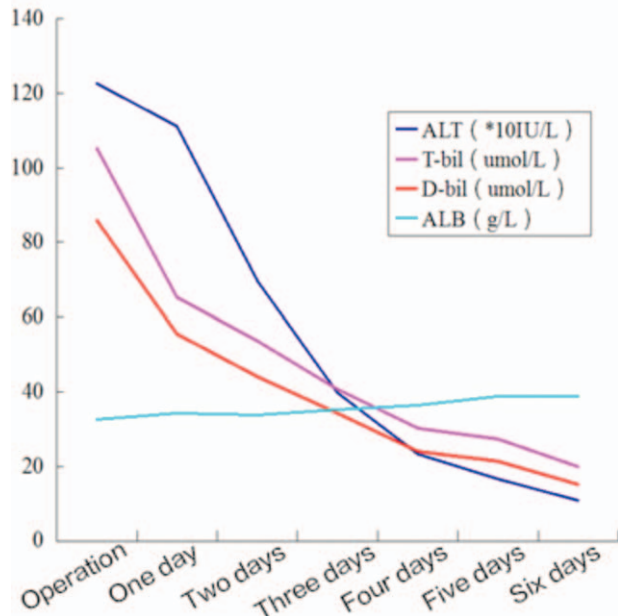


Figure 6. Liver function within 1 week after operation. ALB=albumin, ALT=alanine aminotransferase, D-bil=direct bilirubin, T-bil=total bilirubin.

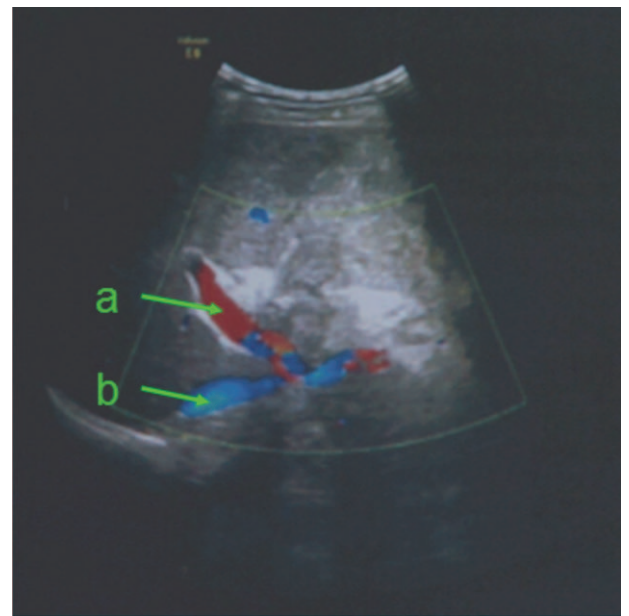


Figure 8. One month after operation, color Doppler ultrasound shows no marked signal of blood stream in proper hepatic artery. a: portal vein, b: inferior vena cava.

biological behaviors of tumors occurring in the caput pancreatic, they readily invade surrounding blood vessels and nerves, bringing difficulties to radical resection for these tumors.^[4] Blood vessel involvement is an important factor affecting radical resection.^[5] Therefore, it is critical to understand the tumor anatomy and evaluate resectability before operation. Nowadays, preoperative assessment is mainly assisted by CT and MRI

imaging examinations. CT examination, characterized by its high resolution and image clarity, is capable of showing the relation between tumor and surrounding organs and vessels, thus has been widely applied in clinic.

With the development of medical imaging technology, 3-D visualization reconstruction has widely used in recent years.^[6] The capability of 3-D visualization reconstruction, including

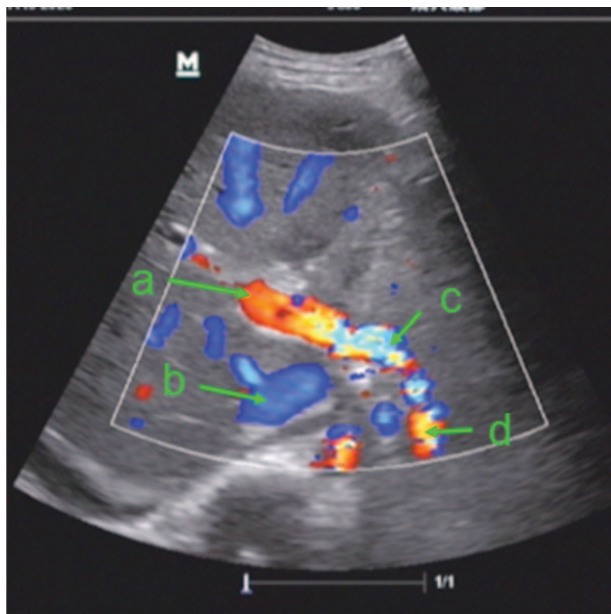


Figure 7. One week after operation, color Doppler ultrasound shows the signal of blood stream from proper hepatic artery into portal vein. a: portal vein, b: inferior vena cava, c: blood stream from proper hepatic artery into portal vein, and d: proper hepatic artery.

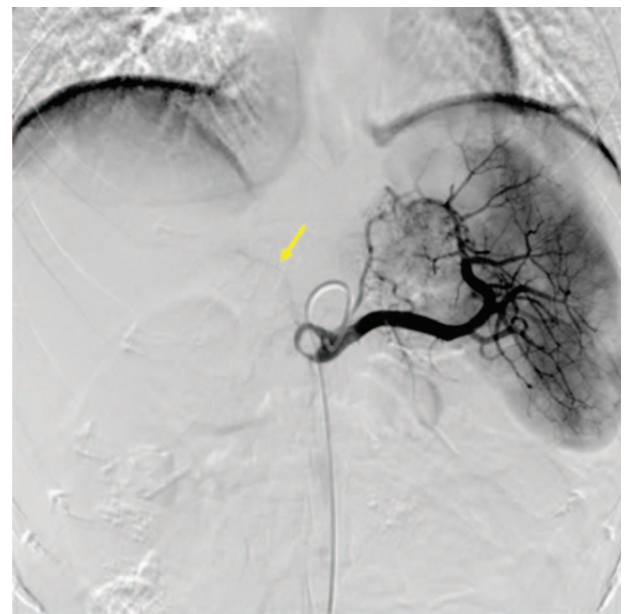


Figure 9. Digital subtraction arteriography (DSA) performed through the celiac trunk shows a compensatory artery branch into the left liver and no shadow in the proper hepatic artery. The arrow indicates a compensatory artery branch into the left liver.

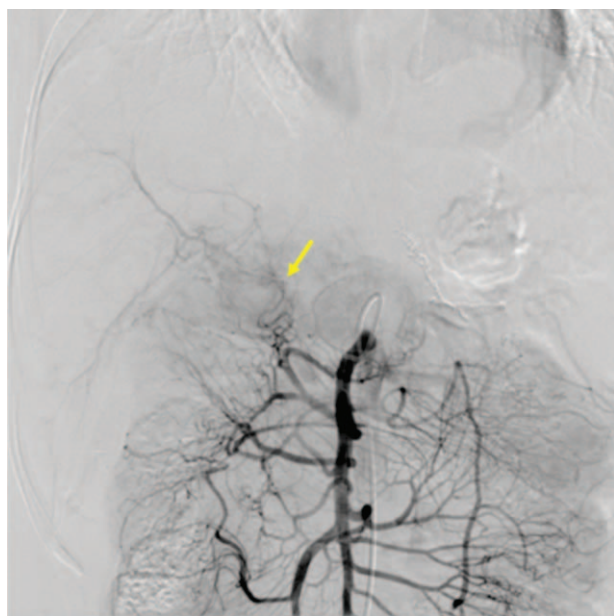


Figure 10. Angiography of superior mesenteric artery shows a compensatory artery branch in the right liver. The arrow indicates a compensatory artery branch within the right liver.

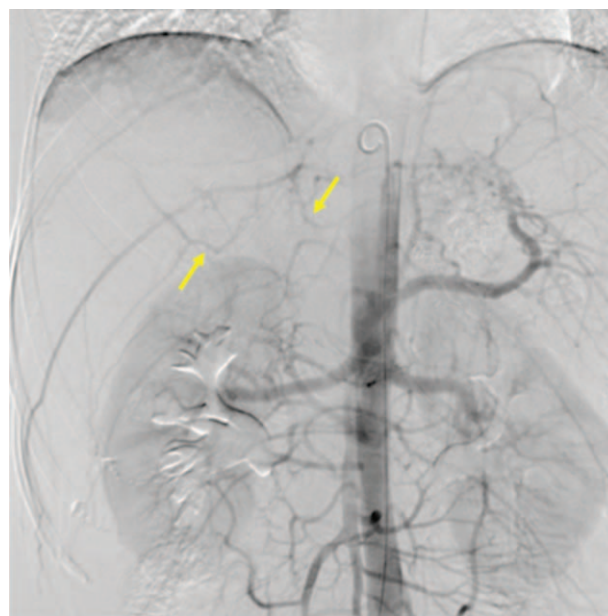


Figure 11. Angiography of abdominal aorta shows compensatory artery branches within the liver. The arrows indicate compensatory artery branches within the liver.

arbitrarily rotating, zooming, combinatorially viewing, vitrification and concealing target organ model, makes it powerful in displaying the tumor's volume and shape, anatomical relationship with organs and vessels, and the invasion condition.^[7] Tumors and vessels cannot be stereoscopically shown in CT images, but the 3-D visualization reconstruction can greatly make up the limitation, and can provide more reliable preoperative assessment and more effective surgical proposal.

For the tumors occurring in caput pancreatic and involving hepatic artery, it is difficult to obtain radical resection only by classical pancreatoduodenectomy, so simultaneous removal of the hepatic artery is necessary. Because blood supply for the liver is mainly from portal vein; if liver function is normal, liver artery ligation usually will not lead to liver ischemia or necrosis.^[8] However, in extensive radical resection of tumor in porta hepatis, exposure of blood vessels in hepatoduodenal ligament often cut off the blood supply of collateral circulation for the remaining liver, so hepatic artery resection may cause severe biliary tract ischemia-related complications such as liver abscess, bilioenteric anastomotic leakage, and even hepatic failure.^[9] Based on the reduction of liver blood perfusion and increased incidence of hepatic encephalopathy after portacaval shunt for the treatment of portal hypertension, Cohn (1952) and Fisher (1954) conceived the idea of liver perfusion using arterial blood instead of portal vein blood.^[10] Portal vein arterialization could be performed by multiple ways such as complete or partial portal vein arterialization, direct or bridging anastomosis. The blood supply could be from hepatic artery, right renal artery, splenic artery and right gastric artery, etc.^[11] Portal vein arterialization could effectively improve liver function, promote hepatic cell regeneration, prevent hepatic failure, and reduce biliary tract complications.^[12,13] One case had acute hepatic failure and was not suitable for liver transplantation, this patient tried to receive portal vein arterialization and finally this patient was discharged from hospital because his liver function gradually recovered after

operation.^[14] Tsivian et al^[15] performed a systematic review for literatures and found that portal vein arterialization was safe and reliable in prevention and treatment for acute liver failure. Portal vein arterialization can benefit liver in a short time. However, it may also induce some adverse side effects such as increased portal vein pressure, hepatic cell apoptosis, and reduced hepatotrophic factors.^[16] To reduce the adverse side effects caused by portal vein arterialization, Bonnet et al^[17] adopted the method to limit portal vein flow, and Kondo et al^[18] carried out anastomotic embolism after portal hypertension and collateral circulation were observed by angiography. Therefore, limiting blood flow and anastomotic embolism are the main methods to reduce or avoid the adverse side effects caused by portal vein arterialization. Chen et al^[13] believe that it is reasonable to block arterialization 1 to 6 months after operation.

Because the patient in this study had a 10-year medical history of viral hepatitis B and increased total bilirubin level before operation, and exposure of blood vessels in the hepatoduodenal ligament led to loss of hepatic blood supply from hepatic artery and most collateral circulation; complications such as liver damage, bilioenteric anastomotic leakage, liver abscess, and even liver failure would readily occur. Therefore, we adopted the anastomosis between portal vein and proper hepatic artery to increase portal vein blood flow and promote liver function recovery. Six days after operation, the liver function returned to normal limits, and no biliary tract complications occurred. To avoid side effects such as portal hypertension induced by long-term portal vein arterialization, proper hepatic artery embolism was planned. Digital subtraction arteriography angiography revealed anastomotic occlusion of portal vein arterialization and formation of liver compensatory arterial branches. Anastomotic occlusion might be caused by long proximal hepatic artery, end-to-side anastomosis, and small anastomotic stoma. And the increase in portal pressure caused by artery blood perfusion decreased the pressure difference between arteries and veins,

reducing blood flow rate at anastomotic stoma and finally resulting in thrombosis. Moreover, the formation of compensatory arterial branches was beneficial for liver function recovery. No biliary fistula or anastomotic leakage occurred in this case, suggesting that this surgical proposal was safe and effective.

4. Conclusion

In summary, 3-D visualization reconstruction can provide reliable basis and assistance for the accurate assessment and surgical design before pancreatoduodenectomy, and also is conducive to full preparation for extensive pancreatoduodenectomy and vessel reconstruction. Meanwhile, from the case of this study, we can see that it is certainly worth adopting portal vein arterialization when retention of hepatic artery is impossible or conventional arterial anastomosis is required during pancreatoduodenectomy. Although portal vein arterialization is used in clinic as an important remedial measure, its application still needs to be standardized.

Acknowledgments

The authors thank National Natural Science Foundation of China (No. 81272246, 81101502, 61271336, 61327001) for the support.

References

- [1] Su Z-j, Duan P, Liu C-h. Application of 3-D visualization in the treatment for cholangiocarcinoma in porta hepatic. *Chin J Digest Surg* 2013;12:213–6.
- [2] Zhao Y, Wang H-q, Liu Y, et al. Basis and clinic about portal vein arterialization. *Med Recapitulate* 2014;20:1421–4.
- [3] Zhou X-h, He Y, Gong J-p. Prevention and treatment for four main complications after pabcreaticoduodenectomy. *Chin J Curr Adv Gen Surg* 2011;14:377–9.
- [4] Chua TC, Saxena A. Extended pancreaticoduodenectomy with vascular resection for pancreatic cancer: a systematic review. *J Gastrointest Surg* 2010;14:1442–52.
- [5] Gong Y, Zhang L-d, Ding J. Clinical significance of vascular resection and reconstruction during pancreaticoduodenectomy for treatment of pancreatic cancer. *Chin J Digest Surg* 2013;12:455–9.
- [6] Fang C-h, Xiang N. Application of digital mini-invasive technique in the surgery for liver, gallbladder and pancreas. *Chin J Min Invasive Surg* 2011;11:15–9.
- [7] Su Z-j, Li W-g, Chen F-z, et al. Application of three dimensional visualization technique in preoperative evaluation of retroperitoneal tumor. *Chin J Pract Surg* 2015;35:111–4.
- [8] Guan X-q, Ghen Y, Gu S-c, et al. Feasibility study on extended pancreaticoduodenectomy combined with resection of hepatic artery, proper hepatic artery and internal iliac vein. *Chin J Bases Clin Gen Surg* 2012;19:181–7.
- [9] Iseki J, Noie T, Touyama K. Mesenteric arteriportal shunt after hepatic artery interruption. *Surgery* 1998;123:58–66.
- [10] Li W-g, Huang Z-q. Application of portal vein arterialization in liver transplantation. *Digest Surg* 2003;2:288–91.
- [11] Zhao Y, Wang H-q. Basis and clinic about portal vein arterialization. *Med Recapitulate* 2014;20:1421–4.
- [12] Zhang J-j, Meng X-k. Current situation and prospect about application of portal vein arterialization in general surgery. *Chin J Hepatobil Surg* 2011;17:349–52.
- [13] Chen Y-l, Huang Z-q, Zhou N-x. Application of portal vein arterialization of in the radical resection for hepatic portal cholangiocarcinoma. *Chin J Gen Surg* 2007;22:404–6.
- [14] Nardo B, Puviani L. Technical aspects of portal vein arterialization for acute liver failure: from rat lab to man. *Transplant Proc* 2006;38:1195–7.
- [15] Tsivian M, Neri F, Prezzi D. Portal vein arterialization in hepatobiliary surgery and liver transplantation. *Transplant Proc* 2007;39:1877–8.
- [16] Li W-g, Li B, Gao L-j. Long-term effects of flow-limited portal vein arterialization on hepatic function and structure in rats. *Chin J Gen Surg* 2006;21:55–8.
- [17] Bonnet S, Sauvanet A, Bruno O. Long-term survival after portal vein arterialization for portal vein thrombosis in orthotopic liver transplantation. *Gastroenterol Clin Biol* 2010;34:23–8.
- [18] Kondo S, Hirano S, Ambo Y. Arterioportal shunting alternative to microvascular reconstruction after hepatic artery resection. *Br J Surg* 2004;91:248–51.