



Since January 2020 Elsevier has created a COVID-19 resource centre with free information in English and Mandarin on the novel coronavirus COVID-19. The COVID-19 resource centre is hosted on Elsevier Connect, the company's public news and information website.

Elsevier hereby grants permission to make all its COVID-19-related research that is available on the COVID-19 resource centre - including this research content - immediately available in PubMed Central and other publicly funded repositories, such as the WHO COVID database with rights for unrestricted research re-use and analyses in any form or by any means with acknowledgement of the original source. These permissions are granted for free by Elsevier for as long as the COVID-19 resource centre remains active.

## SECTION A

### Canine Lymphoma and Lymphoid Leukemias

DAVID M. VAIL, MARIE E. PINKERTON,  
AND KAREN M. YOUNG

#### Lymphoma

The lymphomas (malignant lymphoma or lymphosarcoma) are a diverse group of neoplasms that have in common their origin from lymphoreticular cells. They usually arise in lymphoid tissues such as lymph nodes, spleen, and bone marrow; however, they may arise in almost any tissue in the body. Although the annual incidence of lymphoma is difficult to predict in the absence of a national canine tumor registry, it is clear that it represents one of the most common neoplasms seen in the dog. The annual incidence has been estimated to range between 13 to 24 per 100,000 dogs at risk.<sup>1-3</sup> The annual incidence rates at specific ages are estimated to be 1.5 per 100,000 for dogs less than 1.0 year of age and 84 per 100,000 in the 10- to 11-year-old group. Lymphoma comprises approximately 7% to 24% of all canine neoplasia and 83% of all canine hematopoietic malignancies.<sup>4,5</sup> In a review of the Veterinary Medical Data Base Program (VMDP) at Purdue University from 1987 to 1997, the frequency of canine lymphoma patients presented to 20 veterinary institutions increased from 0.75% of total case load to 2.0%, and it appears the frequency is continuing to increase. A similar trend is present in physician-based oncology; non-Hodgkin's lymphoma (NHL) represents 5% of all new cancer cases, the fifth leading cause of cancer death, and the second fastest growing cancer in terms of mortality in humans.<sup>6</sup> Middle-aged to older (median age of 6 to 9 years) dogs are primarily affected. A decreased risk for lymphoma is reported for intact females.<sup>7</sup> Breeds reported to have a higher incidence include Boxers, bull mastiffs, basset hounds, St. Bernards, Scottish terriers, Airedales, and bulldogs; breeds at lower risk include dachshunds and Pomeranians.<sup>8,9</sup>

#### Etiology

The etiology of canine lymphoma is likely multifactorial and largely unknown; however, investigations are currently shedding significant light on the subject.

#### Genetic and Molecular Factors

Recent advances in molecular cytogenetics (see Chapter 1, Section A), including gene microarray techniques, have been and are currently being applied to investigations of chromosomal aberrations in dogs with lymphoma.<sup>10-16</sup> The publication of the canine genome and the commercial availability of canine gene microarrays

(GeneChip Canine Genome 2.0 Array, Affymetrix, Inc.) have led to advances in our understanding of genetic events occurring in lymphoma.<sup>17</sup> Breen's group has documented gain of dog chromosomes 13 and 31 and loss of chromosome 14 as the most common aberrations in a group of 25 cases analyzed.<sup>11</sup> Chromosomal aberrations have also been associated with prognosis in dogs with lymphoma. A study of 61 dogs with lymphoma demonstrated a prognostic advantage in dogs with trisomy of chromosome 13 (25% of the dogs studied) as evidenced by increase in duration of first remission and overall survival time.<sup>18</sup> Germline and somatic genetic mutations and altered oncogene/tumor suppressor gene expression, epigenetic changes (e.g., DNA hypomethylation), signal transduction, and death-pathway alterations (e.g., *Bcl-2* family) are common in human lymphomas and have been reported in the dog as well (see Chapter 1, Section A, and Chapter 14, Section B). These include *N-ras*, *p53*, *Rb*, and p16 cyclin-dependent kinase aberrations.<sup>19-24</sup> Additionally, differences in the prevalence of immunophenotypic subtypes of lymphoma among different breeds indicate heritable risks.<sup>25</sup> Additionally, telomerase activity (see Chapter 2) has been documented in canine lymphoma tissues.<sup>26-28</sup>

#### Infectious Factors

The hypothesis that a retrovirus may be involved in the pathogenesis of canine lymphoma has not been confirmed. However, serologic detection of Epstein-Barr virus infection, linked to some forms of lymphoma in humans, has been documented in dogs with lymphoma and is currently being investigated.<sup>29</sup>

In humans, a direct association between *Helicobacter* sp. infections and development of gastric lymphoma has been made.<sup>30</sup> Although this has not been definitively shown in dogs, there is evidence of *Helicobacter* sp. infection in laboratory beagle dogs resulting in gastric lymphoid follicle formation that is considered a precursor of mucosa-associated lymphoid tissue (MALT) lymphoma in humans.<sup>31</sup>

#### Environmental Factors

In humans, evidence has accumulated implicating phenoxyacetic acid herbicides, in particular 2, 4-dichlorophenoxyacetic acid (2, 4-D), in the development of NHL. A published hospital-based case-control study of dogs indicated that owners in households with dogs that develop malignant lymphoma applied 2, 4-D herbicides to their lawn and/or employed commercial lawn care companies to treat their yard more frequently than owners of dogs without lymphoma.<sup>32</sup> The risk of canine lymphoma was reported to rise twofold (odds ratio [OR] = 1.3) with four or more yearly owner applications of 2, 4-D. The results of this study have come under criticism, and three additional follow-up investigations have not validated assertions of increased risk.<sup>33-35</sup> In another study, dogs exposed to lawn treatment within 7 days of application were greater than 50 times

more likely to have urine levels of 2, 4-D at 50 µg/L or higher.<sup>36</sup> The highest concentration was noted 2 days after application. In an environmental case-control study performed in Europe, two variables, residency in industrial areas and use of chemicals (defined as paints or solvents) by owners, modestly increased the risk of developing lymphoma; however, no link was found with pesticide use.<sup>37</sup>

A weak association between lymphoma in dogs and exposure to strong magnetic fields was observed in a preliminary epidemiologic study.<sup>38</sup> In this hospital-based case-control study, the risk of developing lymphoma categorized into high or very high exposure was increased (odds ratio = 1.8). More thorough studies are necessary to evaluate this association further. Proximity to environmental waste was implicated in two European studies; however, it was felt to be a risk indicator rather than a risk factor and would require further case-control investigations.<sup>39,40</sup>

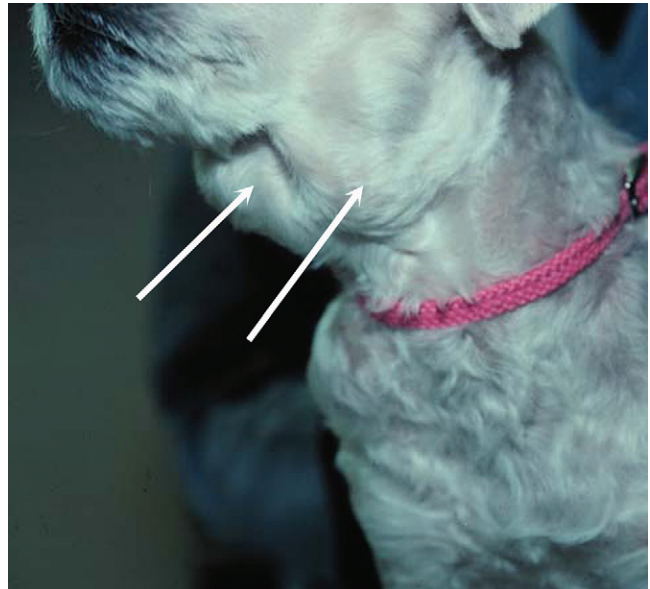### Immunologic Factors

Impaired immune function has also been implicated in dogs with lymphoma. Immune system alterations in the dog such as immune-mediated thrombocytopenia, independent of age and sex, have been associated with a higher risk of subsequently developing lymphoma when compared to the normal population.<sup>41,42</sup> Additional evidence comes from observations in human and feline transplantation patients. In a case-control study of cats undergoing renal transplant, 24% of cases developed cancer (36% of those were lymphoma) while on cyclosporine immunosuppressive therapy compared to 5.1% of control cats, none of which developed lymphoma (OR, 6.1;  $p = 0.001$ ).<sup>43</sup> A case of lymphoma developing in a dog following treatment with cyclosporine also exists.<sup>44</sup> One report suggests an association between the immunodysregulation observed in dogs with atopic dermatitis and the risk of developing epitheliotropic T-cell lymphoma; whether this is associated with the disease or the immunomodulatory treatments commonly applied is unknown.<sup>45</sup>

### Classification and Pathology

Classification of malignant lymphoma in dogs is based on anatomic location, histologic criteria, and immunophenotypic characteristics. The most common anatomic forms of lymphoma, in order of decreasing prevalence, are multicentric, gastrointestinal (GI), mediastinal, and cutaneous forms.<sup>46</sup> Primary extranodal forms, which can occur in any location outside the lymphatic system, include the eyes, central nervous system (CNS), bone marrow, bladder, heart, and nasal cavity. The pathologic characteristics of the various anatomic classifications will be discussed in this section and clinical characteristics will be described in subsequent sections.

Eighty-four percent of dogs with lymphoma develop the multicentric form, which is usually characterized by the presence of superficial lymphadenopathy (Figure 32-1).<sup>46</sup> The alimentary form of lymphoma is much less common, accounting for 5% to 7% of all canine lymphomas. This form is reported to be more common in male dogs than female dogs.<sup>6</sup> Primary GI lymphoma in dogs may occur focally but more often affects multiple segments, with thickening of the wall, narrowing of the lumen, and frequently mucosal ulceration.<sup>47,48</sup> Histologically, there is infiltration of neoplastic lymphocytes throughout the mucosa and submucosa, with occasional transmural infiltration. Liver and local lymph nodes are often secondarily involved. Lymphocytic-plasmacytic enteritis (LPE) can be seen adjacent to or distant from the primary tumor. Pathologically, some of these neoplasms may resemble plasma cell tumors, and aberrant production of immunoglobulins may occur.

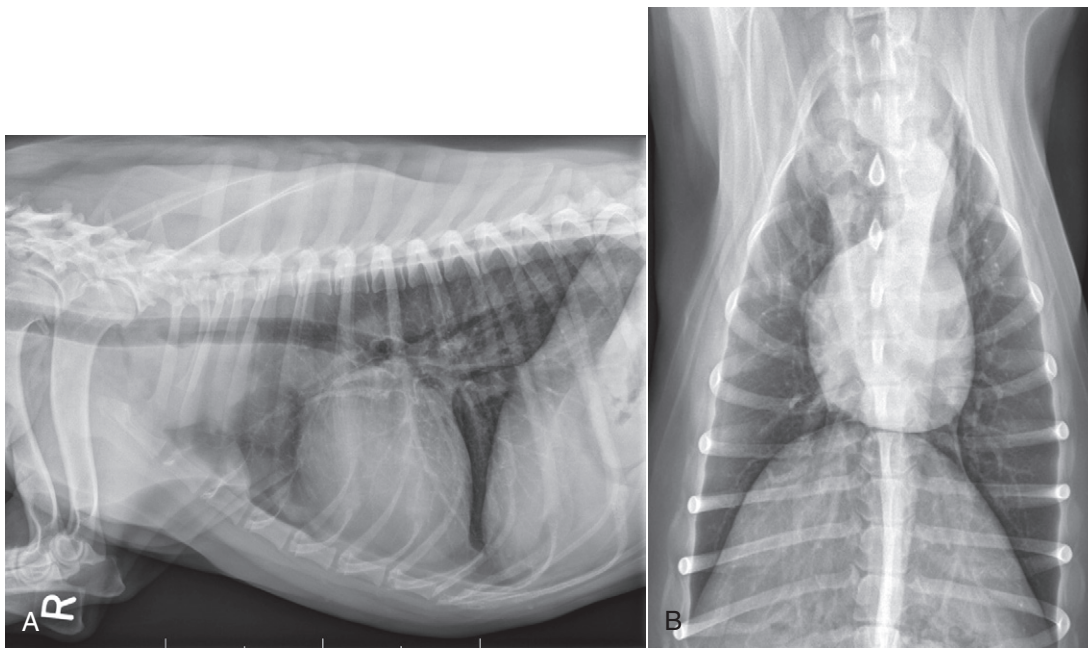


• **FIGURE 32-1** A dog with obvious mandibular lymphadenopathy resulting from multicentric lymphoma.

Histopathologically, distinguishing between GI lymphoma and LPE can be difficult. Some have suggested that LPE may be a prelymphomatous change in the GI tract. A syndrome of immunoproliferative intestinal disease characterized by LPE has been described in Basenjis, which subsequently develop GI lymphoma.<sup>49</sup> In addition, plasma cell-rich areas with heterogeneous lymphomatous infiltration may resemble lesions of LPE. Only a few reports specifically identify the immunophenotype of the lymphocyte subpopulations in alimentary lymphoma in dogs. Historically, it was presumed that they most likely originate from B cells; however, recent evidence suggests that most GI lymphomas in dogs arise from T cells and often exhibit epitheliotropism.<sup>48,50</sup> The Boxer and Shar-pei breeds may be overrepresented in cases of alimentary lymphoma.<sup>50,51</sup>

The mediastinal form of the disease occurs in approximately 5% of cases.<sup>46</sup> This form is characterized by enlargement of the cranial mediastinal lymph nodes, thymus, or both (Figure 32-2). Hypercalcemia is reported to occur in 10% to 40% of dogs with lymphoma and is most common with the mediastinal form. In a study of 37 dogs with lymphoma and hypercalcemia, 16 (43%) had mediastinal lymphoma.<sup>52</sup> The mediastinal form in dogs is most commonly associated with a T-cell phenotype.<sup>53,54</sup>

Cutaneous lymphoma can be solitary or more generalized and usually is classified as epitheliotropic (mycosis fungoides) or non-epitheliotropic.<sup>55</sup> Canine epitheliotropic cutaneous lymphoma originates from T-cells,<sup>55-60</sup> similar to its development in humans. In dogs, these more commonly represent CD8<sup>+</sup> cells, whereas in humans they are typically CD4<sup>+</sup> cells. A rare form of cutaneous T-cell lymphoma, characterized by skin involvement with evidence of peripherally circulating large (15 to 20 µm in diameter) malignant T-cells with folded, grooved nuclei, has been described. In humans, this is referred to as Sézary syndrome and has been reported in both dogs and cats.<sup>61-63</sup> Nonepitheliotropic cutaneous lymphomas form single or multiple dermal or subcutaneous nodules or plaques; histologically, they spare the epidermis and papillary dermis and affect the middle and deep portions of the dermis and subcutis.<sup>55</sup>



• **FIGURE 32-2** A, Lateral radiographic projection of a dog with mediastinal lymphoma. B, Ventrodorsal projection of the same dog.

### Atypical Anatomic Forms of Lymphoma

Hepatosplenic lymphoma is a relatively uncommon, distinct presentation in the dog marked by a lack of significant peripheral lymphadenopathy in the face of hepatic, splenic, and bone marrow infiltration with malignant lymphocytes, usually of T-cell origin.<sup>64,65</sup> Biologically, this form of lymphoma is extremely aggressive and poorly responsive to therapy. In humans the tumor usually is composed of  $\gamma\delta$ T-cells (i.e., T-cells that express the  $\gamma\delta$ T-cell receptor), and this immunophenotype has been confirmed in at least one dog in the veterinary literature.<sup>65</sup>

Intravascular (angiotropic, angioendotheliomatosis) lymphoma is a distinct form of lymphoma defined as proliferations of neoplastic lymphocytes within the lumen and wall of blood vessels in the absence of a primary extravascular mass or leukemia. It has been reported several times in the veterinary literature, and in most cases it involves the CNS and peripheral nervous system (PNS), including the eye.<sup>66-71</sup> The B-cell immunophenotype is most common in humans; however, in most reported cases in dogs, the origin is either T-cell or null cell (neither B- nor T-cell), although one case of a B-cell phenotype has been reported.

Pulmonary lymphomatoid granulomatosis (PLG) is a rare pulmonary infiltrative and/or nodular disorder characterized by a heterogeneous accumulation of lymphocytes (both B and T, although some evidence suggests primarily a T-cell origin), neutrophils, plasma cells, and macrophages, often arranged angiocentrically.<sup>72-75</sup> Whether this syndrome is a true lymphoma or a prelymphoma state is debatable. Clinical signs are related to respiratory compromise, and various chemotherapeutic protocols have been used with reported results varying from rapid progression to long-term clinical remissions.

### Histologic Classification Systems

Lymphomas arise from clonal expansion of lymphoid cells with distinctive morphologic and immunophenotypic features. Many histologic systems have been used to classify NHL in humans, and some of these have been applied to lymphoma in the dog and other

species. The National Cancer Institute (NCI) Working Formulation<sup>76</sup> and the updated Kiel system<sup>77</sup> have been adapted to canine tumors with some success. The World Health Organization (WHO) also publishes a histologic classification scheme, which uses the revised European American lymphoma (REAL) system as a basis for defining histologic categories of hematopoietic and lymphoid tumors in domestic animals.<sup>78</sup> This system incorporates anatomic, histologic, and immunophenotypic criteria (B- and T-cell immunophenotype), with the goal of enabling accurate and reproducible diagnosis of specific neoplastic disease entities. This theoretically should assist in better tailoring of treatment protocols, better correlation of prognosis, and better comparative capabilities. Table 32-1 shows some of the WHO categories in three different surveys, including a 2-year survey (2008-2009) of canine necropsy and biopsy cases at the University of Wisconsin-Madison Veterinary Medical Teaching Hospital pathology service<sup>79,80</sup>; some of the less common categories in the WHO system were not represented and are not listed. The WHO system provides accurate and consistent reproducible diagnostic results similar to the system used in human pathology; accuracy among a group of pathologists examining 300 cases was at 83% agreement, and accuracy in evaluating the six most common diagnoses (80% of the cases) was 87%.<sup>81</sup> Clinical studies are needed to correlate the various categories of disease with biologic behavior, response to treatment, and prognosis. Preliminary results indicate dogs with indolent lymphoma (e.g., marginal zone lymphoma, follicular lymphoma, B- or T-cell small cell lymphoma, T-cell-rich B-cell lymphoma, and T zone lymphoma) maintain normal activity and appetite levels even during advanced stages of disease and experience long-term survival even with limited or no therapy.<sup>81-84</sup>

The Working Formulation (WF) was developed to allow investigators to “translate” among the numerous classification systems so that clinical trials could be compared in humans. Most of the larger compilations agree that most canine lymphomas are intermediate or high grade; however, diffuse immunoblastic forms appear to predominate in the United States, whereas the follicular



• TABLE 32-1 World Health Organization Classification System for Canine Lymphoma

CATEGORY	PERCENTAGE		
	SUEIRO ET AL (N = 55)	VEZZALI ET AL (N = 123)	UNIVERSITY OF WISCONSIN (N = 122)
<b>B-cell neoplasms</b>	72.7	78.9	59.0
Precursor B lymphoblastic leukemia/lymphoma	—	2.4	8.2
B-cell chronic lymphocytic leukemia/small lymphocytic lymphoma	1.8	2.4	0.8
Lymphocytic lymphoma—intermediate type	—	0.8	—
Lymphoplasmacytic lymphoma	10.9	3.3	0.8
Mantle cell lymphoma	—	1.6	—
Follicular center cell lymphomas	1.8	2.4	—
Marginal zone lymphoma (splenic, nodal, mucosa-associated lymphoid tissue)	—	3.3	2.5
Plasma cell myeloma/plasmacytoma	—	16.3	9.8
Diffuse large cell lymphoma	56.3	33.3	24.6
T-cell-rich, B-cell lymphoma	—	0.8	—
Large cell immunoblastic lymphoma	—	10.6	10.7
Mediastinal (thymic) large B-cell lymphoma	—	0.8	—
Burkitt's lymphoma/leukemia	—	0.8	1.6
<b>T-cell and natural killer (NK) cell lymphomas</b>	21.8, 5.4*	21.1	41.0
Precursor T lymphoblastic lymphoma/leukemia	—	6.5	9.8
T-cell chronic lymphocytic leukemia (CLL)	—	3.3	0.8
Intestinal T-cell lymphoma	—	4.1	4.1
Mycosis fungoides/Sézary syndrome	—	1.6	11.5
Cutaneous nonepitheliotropic lymphoma	12.7 <sup>†</sup>	3.3	—
Anaplastic large cell lymphoma	1.8	—	0.8
Peripheral T-cell lymphoma, unspecified	20.0	2.4	13.1 <sup>‡</sup>

\*Non-B, non-T lymphomas.

<sup>†</sup>Three B-cell and four T-cell cutaneous lymphomas, not specified as epitheliotropic/nonepitheliotropic.

<sup>‡</sup>Includes one T-zone lymphoma.

Modified from Sueiro FAR, Alessi AC, Vassallo J: Canine lymphomas: A morphological and immunohistochemical study of 55 cases, with observations on p53 immunoeexpression, *J Comp Pathol* 131:207–213, 2004; and Vezzali E, Parodi AL, Marcato PS, et al: Histopathological classification of 171 cases of canine and feline non-Hodgkin lymphoma according to the WHO, *Vet Comp Oncol* 8:36–49, 2009.

large cell variations predominate in Europe. A comparison of European and American classifications is warranted based on this discrepancy. The WF categorizes tumors according to pattern (diffuse or follicular) and cell type (e.g., small cleaved cell, large cell, immunoblastic), but it does not include information about the immunophenotype of the tumor.<sup>76</sup> The WF subtypes are related to the biology of the tumor and patient survival. The updated Kiel classification includes the architectural pattern, morphology (centroblastic, centrocytic, or immunoblastic), and immunophenotype (B-cell or T-cell) of the tumor cells.<sup>77</sup> In both systems, the tumors can then be categorized as low-grade, intermediate grade, or high-grade malignancies. Low-grade lymphomas composed of small cells with a low mitotic rate typically progress slowly and are associated with long survival times but are ultimately incurable. High-grade lymphomas with a high mitotic rate progress rapidly but are more likely to respond initially to chemotherapy and, in humans, are potentially curable.

Several features of canine lymphomas become apparent when these classification systems are applied. The most striking difference between canine and human lymphomas is the scarcity of follicular lymphomas in the dog.<sup>79,80</sup> Some diffuse lymphomas in the dog may initially be follicular, but these may progress to the more aggressive, diffuse form by the time of diagnostic biopsy. The most common form of canine lymphoma is diffuse large-cell lymphoma, a high-grade tumor most commonly of B-cell origin.<sup>80,81,85</sup> Only a small

percentage of canine lymphomas (5.3% to 29%) are considered low-grade tumors.

High-grade lymphomas occur frequently if diffuse large-cell lymphomas, classified as intermediate grade in the WF, are considered high-grade, as in the updated Kiel classification (in which they are labeled as diffuse centroblastic lymphomas). A documented difference exists in the prevalence of the various immunophenotypes based on breed.<sup>25</sup> For example, cocker spaniels and Doberman pinschers are more likely to develop B-cell lymphoma, Boxers are more likely to have T-cell lymphoma, and golden retrievers appear to have an equal likelihood of B- and T-cell tumors.

To be clinically useful, these classification systems in the end must yield information about response to therapy, maintenance of remission, and survival. Some studies suggest that the subtypes in the WF can be correlated with survival, and the Kiel system may be useful for predicting relapse.<sup>86,87</sup> In most studies, high-grade lymphomas achieve a complete response (CR) to chemotherapy significantly more often than low-grade tumors. However, dogs with low-grade tumors may live a long time without aggressive chemotherapy.<sup>83,84</sup> Dogs with T-cell lymphomas have shown a lower rate of CR to chemotherapy and shorter remission and survival times than dogs with B-cell tumors (with the exception of low-grade T-cell subtypes).<sup>53,54,86,88</sup> Furthermore, T-cell lymphomas tend to be associated with hypercalcemia.<sup>89,90</sup>

In the veterinary literature, 60% to 80% of canine lymphomas are of B-cell origin; T-cell lymphomas account for 10% to 38%; mixed B- and T-cell lymphomas account for as many as 22%; and null cell tumors (i.e., neither B-cell nor T-cell immunoreactive) represent fewer than 5%.<sup>53,54,91-93</sup> The development of monoclonal antibodies to detect specific markers on canine lymphocytes has made immunophenotyping of tumors in dogs routinely available in many commercial laboratories. Such techniques can be performed on paraffin-embedded samples, from tissue microarrays, on cytologic specimens obtained by fine-needle aspiration (FNA) of lesions, or by flow cytometric analysis of cellular fluid samples (e.g., peripheral blood, effusions) and lesion aspirates.

The Rappaport classification system, proposed in 1956 for human NHL, describes the architectural pattern (follicular or diffuse) and the cytologic features (well differentiated, poorly differentiated, or histiocytic) of lymphoma.<sup>94,95</sup> This system has not proved useful in providing prognostic information or in guiding therapy in dogs with lymphoma because of the low number of follicular lymphomas in dogs, the problematic “histiocytic” subgroup, and the failure to account for different morphologic and immunologic cell types.

One criticism of the Rappaport, Kiel, and WF classification systems is that they fail to include extranodal lymphomas as a separate category. The WHO system does include anatomic location as a factor in determining certain categories. Although differences between nodal and extranodal tumors in biologic behavior and prognosis are well recognized, comparative information about the histogenesis of these tumors is lacking. For example, in humans small-cell lymphomas arising from MALT are composed of cells with a different immunophenotype than that of other small-cell lymphomas (i.e., MALT lymphomas typically are negative for both CD5 and CD10). Except for cutaneous lymphoid neoplasms, detailed characterization of extranodal lymphomas in dogs has not been done. Although cutaneous lymphoma is a heterogeneous group of neoplasms that includes an epitheliotropic form resembling mycosis fungoides and a nonepitheliotropic form, most cutaneous lymphomas have a T-cell phenotype.<sup>64,96</sup>

To summarize, it is important to determine the histologic grade of canine lymphomas as low (small lymphocytic or centrocytic lymphomas) or intermediate to high (diffuse large cell, centroblastic, and immunoblastic lymphomas) and the architecture as diffuse or follicular. Furthermore, determining the immunophenotype of the tumor provides useful information. Response rates to chemotherapy are, in general, better in animals with B-cell tumors and intermediate- to high-grade lymphomas. Dogs with low-grade lymphomas can have long survival times without aggressive therapy.

## History and Clinical Signs

The clinical signs associated with canine lymphoma are variable and depend on the extent and location of the tumor. Multicentric lymphoma, the most common form, is usually distinguished by the presence of generalized painless lymphadenopathy (see Figure 32-1). Enlarged lymph nodes are usually painless, rubbery, and discrete and may initially include the mandibular and prescapular nodes. In addition, hepatosplenomegaly and bone marrow involvement occur commonly. Most dogs with multicentric lymphoma present without dramatic signs of systemic illness (WHO substage *a*) (Box 32-1); however, a large array of nonspecific signs such as anorexia, weight loss, vomiting, diarrhea, emaciation, ascites, dyspnea, polydipsia, polyuria, and fever can occur (WHO substage *b*). Dogs presented with T-cell lymphoma are more likely to have constitutional (i.e., substage *b*) signs. Polydipsia and polyuria are

### Box 32-1 World Health Organization's Clinical Staging System for Lymphoma in Domestic Animals

#### Anatomic Site

- A Generalized
- B Alimentary
- C Thymic
- D Skin
- E Leukemia (true)\*
- F Others (including solitary renal)

#### Stage (to include anatomic site)

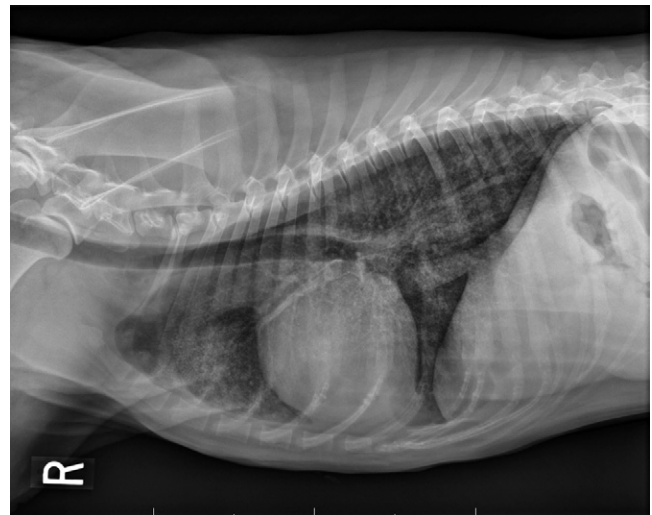
- I Involvement limited to a single node or lymphoid tissue in a single organ.<sup>†</sup>
- II Involvement of many lymph nodes in a regional area ( $\pm$ tonsils).
- III Generalized lymph node involvement.
- IV Liver and/or spleen involvement ( $\pm$ stage III).
- V Manifestation in the blood and involvement of bone marrow and/or other organ systems ( $\pm$ stage I-IV).

Each stage is subclassified into:

- a Without systemic signs
- b With systemic signs

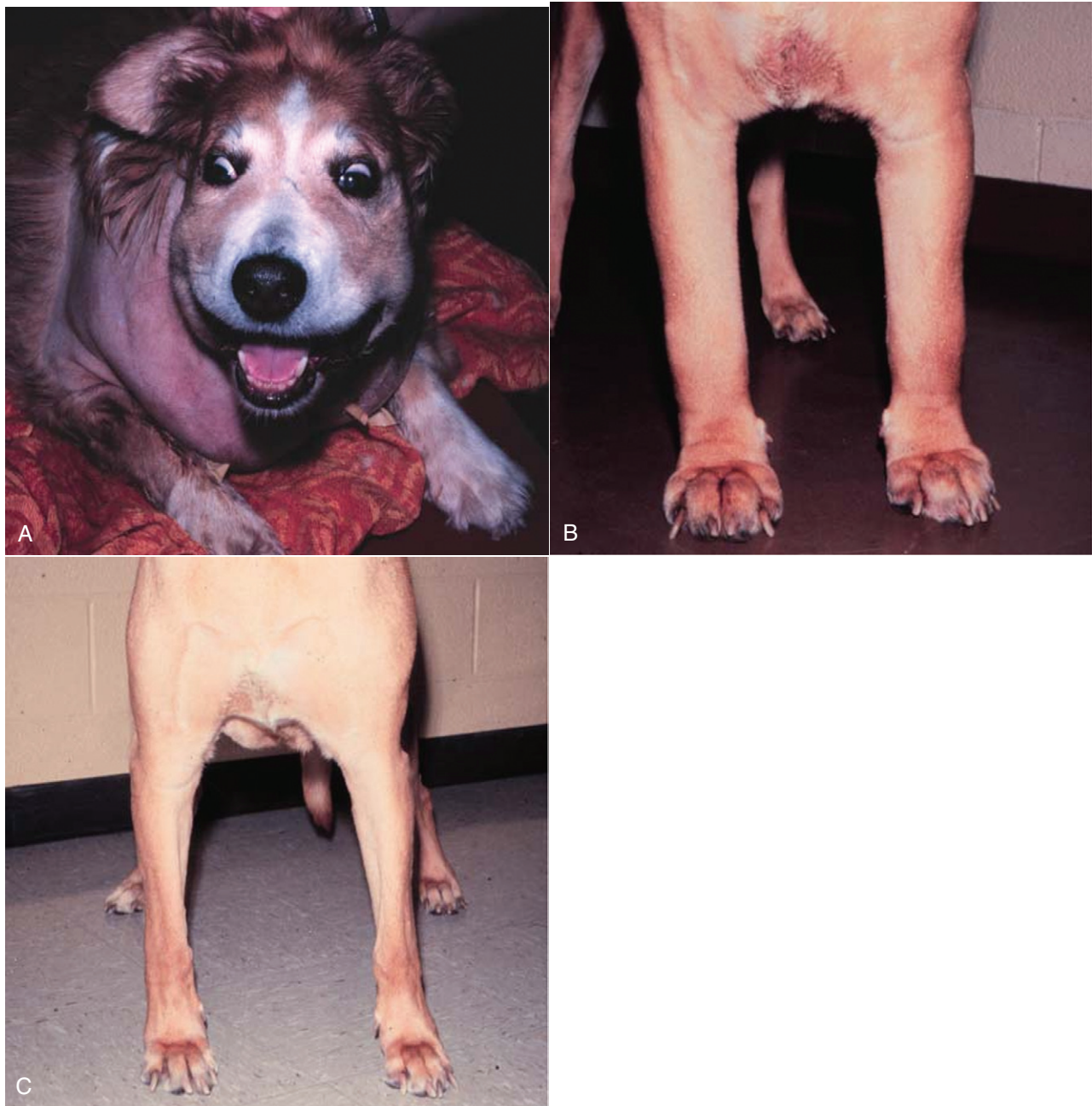\*Only blood and bone marrow involved.

<sup>†</sup>Excluding bone marrow.



• **FIGURE 32-3** Lateral projection of a thoracic radiograph of a dog with diffuse interstitial infiltration with lymphoma secondary to multicentric lymphoma.

particularly evident in dogs with hypercalcemia of malignancy. Dogs may also be presented with clinical signs related to blood dyscrasias secondary to marked tumor infiltration of bone marrow (myelophthisis) or paraneoplastic anemia, thrombocytopenia, or neutropenia. These could include fever, sepsis, anemia, and hemorrhage. Diffuse pulmonary infiltration is seen in 27% to 34% of dogs with the multicentric form, as detected by radiographic changes (Figure 32-3).<sup>97,98</sup> Based on bronchoalveolar lavage, the actual incidence of lung involvement may be higher.<sup>99,100</sup>



• **FIGURE 32-4** **A**, Facial edema in a dog with precaval syndrome secondary to mediastinal lymphoma. **B**, Forelimb edema in a dog with precaval syndrome secondary to mediastinal lymphoma. **C**, The dog in **B** 24 hours after radiation therapy to the cranial mediastinal mass, showing resolution of pitting edema.

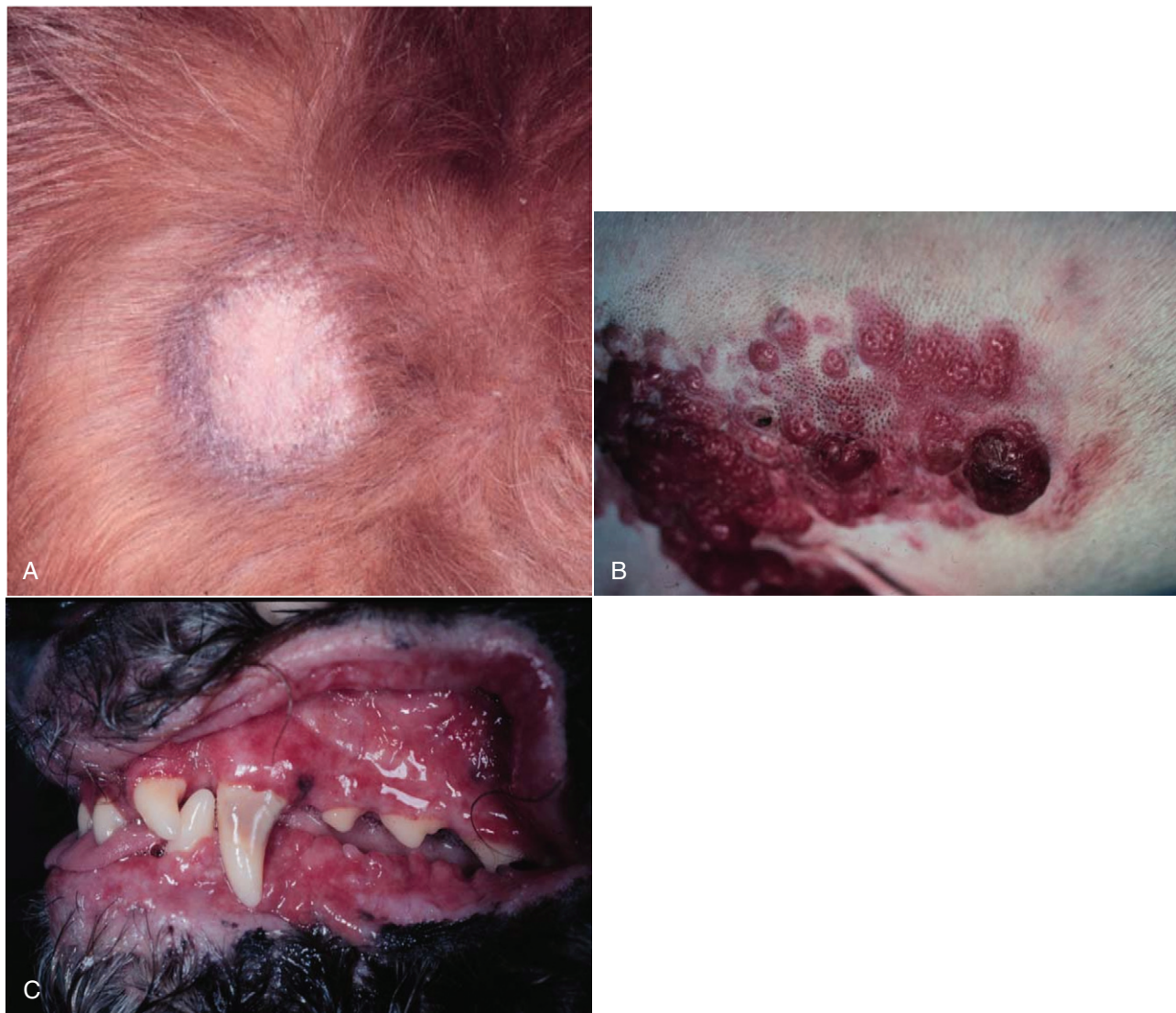Dogs with GI or alimentary lymphoma are usually presented with nonspecific GI signs, such as vomiting, diarrhea, weight loss, and malabsorption.<sup>47,101,102</sup> Mesenteric lymph nodes, spleen, and liver may be involved.

The mediastinal form of lymphoma is characterized by enlargement of the cranial mediastinal structures and/or thymus (see [Figure 32-2](#)), and clinical signs are associated with the extent of disease with resulting respiratory compromise or polydipsia/polyuria from hypercalcemia. Commonly, dogs are presented with respiratory distress caused by a space-occupying mass and pleural effusion, exercise intolerance, and possibly regurgitation. Additionally, dogs with mediastinal lymphoma may present with precaval

syndrome, characterized by pitting edema of the head, neck, and forelimbs secondary to tumor compression or invasion of the cranial vena cava ([Figure 32-4](#)).

Signs in dogs with extranodal lymphoma depend on the specific organ involved. Cutaneous lymphoma is usually generalized or multifocal.<sup>55-57</sup> Tumors occur as nodules, plaques, ulcers, and erythemic or exfoliative dermatitis with focal hypopigmentation and alopecia. Epitheliotropic T-cell lymphoma (e.g., mycosis fungoides) typically has a clinical course with three apparent clinical stages. Initially, there will be scaling, alopecia, and pruritus ([Figure 32-5, A](#)), which can mimic a variety of other skin conditions. As the disease progresses, the skin becomes more erythematous,





• **FIGURE 32-5** **A**, Early epitheliotropic cutaneous lymphoma in the scaly, plaque stage in a dog. **B**, Advanced epitheliotropic cutaneous lymphoma in the nodular stage in a dog. **C**, Oral mucosal epitheliotropic cutaneous lymphoma in a dog.

thickened, ulcerated, and exudative. The final stage is characterized by proliferative plaques and nodules with progressive ulceration (Figure 32-5, B). Oral involvement may also occur and this can appear as multicentric erythematous plaque-like lesions or nodules associated with the gum and lips (Figure 32-5, C). Extracutaneous involvement can also occur, most often in the lymph nodes, spleen, liver, and bone marrow. Nonepitheliotropic cutaneous lymphomas form single or multiple dermal or subcutaneous nodules or plaques; histologically, they spare the epidermis and papillary dermis and affect the middle and deep portions of the dermis and subcutis.<sup>55</sup>

Dogs with primary CNS lymphoma may be presented with either multifocal or solitary involvement.<sup>103-105</sup> Seizures, paralysis, and paresis may be noted. Ocular lymphoma is characterized by infiltration and thickening of the iris, uveitis, hypopyon, hyphema, posterior synechia, and glaucoma.<sup>106,107</sup> In one study of 94 cases of canine multicentric lymphoma, 37% had ocular changes consistent with lymphoma, and in a series of 102 cases of uveitis in dogs, 17% were secondary to lymphoma.<sup>107</sup> Anterior uveitis was most commonly seen in advanced stage of disease (stage V). Dogs with

intravascular lymphoma usually present with signs relative to CNS, PNS, or ocular involvement.<sup>66-71</sup> These include paraparesis, ataxia, hyperesthesia, seizures, blindness, lethargy, anorexia, weight loss, diarrhea, polyuria, polydipsia, and intermittent fever. Finally, dogs with pure hepatosplenic lymphoma usually are presented with non-specific signs of lethargy, inappetence, and weakness and often are icteric.<sup>64,65</sup>

The differential diagnosis of lymphadenopathy depends on the dog's travel history (i.e., relative to infectious disease) and the size, consistency, and location of affected lymph nodes. Other causes of lymphadenopathy include infections caused by bacteria, viruses, parasites (*Toxoplasma* sp., *Leishmania* sp.), rickettsial organisms (Salmon-poisoning, *Ehrlichia* sp.), and fungal agents (*Blastomyces* and *Histoplasma* sp.). The potential for hypercalcemia to accompany systemic fungal diseases may further complicate differentiation from lymphoma. Discrete, hard, asymmetric lymph nodes, particularly if they are fixed to underlying tissues, may indicate metastatic tumors such as mast cell tumor or carcinoma. Immune-mediated diseases (e.g., pemphigus, systemic lupus erythematosus) also may result in mild-to-moderately enlarged lymph nodes. The



• **TABLE 32-2** Differential Diseases or Conditions That Can Resemble Canine Lymphoma

FORM OF LYMPHOMA	OTHER DISORDERS
Multicentric	Disseminated infections: Bacterial, viral, rickettsial, parasitic, fungal Immune-mediated disorders: Dermatopathies, vasculitis, polyarthritis, lupus erythematosus Tumors metastatic to nodes Other hematopoietic tumors: Leukemia, multiple myeloma, malignant or systemic histiocytosis
Mediastinal	Other tumors: Thymoma, chemodectoma, ultimobranchial cyst, ectopic thyroid carcinoma, pleural carcinomatosis, pulmonary lymphomatoid granulomatosis* Infectious disease: Granulomatous disease, pyothorax Miscellaneous: Congestive heart failure, chylothorax, hemothorax
Alimentary	Other gastrointestinal tumors, foreign body, lymphangiectasia, lymphocytic-plasmacytic enteritis, systemic mycosis, gastroduodenal ulceration
Cutaneous	Infectious dermatitis: Advanced pyoderma Immune-mediated dermatitis: Pemphigus Other cutaneous neoplasms (in particular histiocytic disorders)
Extranodal	Variable, depending on organ/system involved

\*The existence of this disease is controversial; in most cases, the disease has been reclassified as a lymphoid neoplasm.

various differential diseases or conditions that can resemble canine lymphoma are listed in Table 32-2.

Canine lymphoma also may be associated with paraneoplastic syndromes (see Chapter 5). Anemia is the most common lymphoma-related paraneoplastic syndrome.<sup>108</sup> Paraneoplastic hypercalcemia is also common and is characterized clinically by anorexia, weight loss, muscle weakness, lethargy, polyuria, polydipsia, and rarely CNS depression and coma. Lymphoma-induced hypercalcemia in most cases results from parathyroid hormone-related peptide (PTHrP), elaborated by neoplastic cells; however, it can also be related to the production of several other humoral factors, including interleukin-1 (IL-1), tumor necrosis factor- $\alpha$  (TNF- $\alpha$ ), transforming growth factor- $\beta$  (TGF- $\beta$ ), and vitamin D analogs (e.g., 1,25-dihydroxyvitamin D).<sup>89,109,110</sup> As previously discussed, hypercalcemia is most commonly associated with the T-cell immunophenotype. Other paraneoplastic syndromes that may be encountered include monoclonal gammopathies, neuropathies, and cancer cachexia.

## Diagnosics and Clinical Staging

For dogs suspected of having lymphoma, the diagnostic evaluation should include a thorough physical examination; complete blood

count (CBC), with a differential cell count, including a platelet count; a serum biochemical profile; and urinalysis. Optimally, ionized calcium should be measured. Ultimately, obtaining tissue or cytologic specimens for a definitive diagnosis is essential.

### Physical Examination

A thorough physical examination should include palpation of all assessable lymph nodes, including a rectal examination; in the authors' experience, a significant proportion of dogs will have rectal polyps consisting of aggregates of neoplastic lymphocytes. Inspection of mucous membranes for pallor, icterus, petechiae, and ulceration should be undertaken as these signs may indicate anemia or thrombocytopenia secondary to myelophthisis or immune-mediated disease or may be evidence of major organ failure or uremia. Abdominal palpation may reveal organomegaly, intestinal wall thickening, or mesenteric lymphadenopathy. The presence of a mediastinal mass and/or pleural effusion can be suspected following thoracic auscultation. An ocular examination, including fundoscopic assessment, may reveal abnormalities (e.g., uveitis, retinal hemorrhage, ocular infiltration) in approximately one-third to one-half of dogs with lymphoma.<sup>107,111</sup>

### Complete Blood Count, Biochemistry Profile, and Urinalysis

Anemia, the most common lymphoma-related hematologic abnormality, is usually normochromic and normocytic (nonregenerative), consistent with anemia of chronic disease.<sup>108</sup> However, hemorrhagic and hemolytic anemias may also occur, and regenerative anemias may reflect concomitant blood loss or hemolysis. Additionally, if significant myelophthisis is present, anemia may be accompanied by thrombocytopenia and leukopenia.<sup>112,113</sup> In animals with anemia or evidence of bleeding, in addition to a platelet count, a reticulocyte count and coagulation testing may be indicated. Thrombocytopenia may be seen in 30% to 50% of cases, but bleeding is seldom a clinical problem. Neutrophilia can be seen in 25% to 40% of dogs and lymphocytosis occurs in approximately 20% of affected dogs.<sup>108</sup> Circulating atypical lymphocytes may be indicative of bone marrow involvement and leukemia. It is important to differentiate multicentric lymphoma with bone marrow involvement (i.e., stage V disease) from primary lymphoblastic leukemia (see later), as the prognosis for each is entirely different. Hypoproteinemia is observed more frequently in animals with alimentary lymphoma. In dogs with a high total protein or evidence of an increased globulin fraction on a chemistry profile, serum proteins may be evaluated by serum electrophoresis. Monoclonal gammopathies have been reported to occur in approximately 6% of dogs with lymphoma.<sup>114</sup>

Serum biochemical abnormalities often reflect the anatomic site involved, as well as paraneoplastic syndromes such as hypercalcemia. In cases of hypercalcemia of unknown origin, lymphoma should always be considered high on the differential disease list, and diagnostic testing directed at this possibility should be undertaken (see Chapter 5). In addition, the presence of hypercalcemia can serve as a biomarker for response to therapy and early recurrence. Increased urea nitrogen and creatinine concentrations can occur secondary to renal infiltration with tumor, hypercalcemic nephrosis, or prerenal azotemia from dehydration. Increases in liver-specific enzyme activities or bilirubin concentrations may result from hepatic parenchymal infiltration. Increased serum globulin concentrations, usually monoclonal, occur infrequently with B-cell lymphoma.

Urinalysis is part of the minimum database used to assess renal function and the urinary tract. For example, isosthenuria and

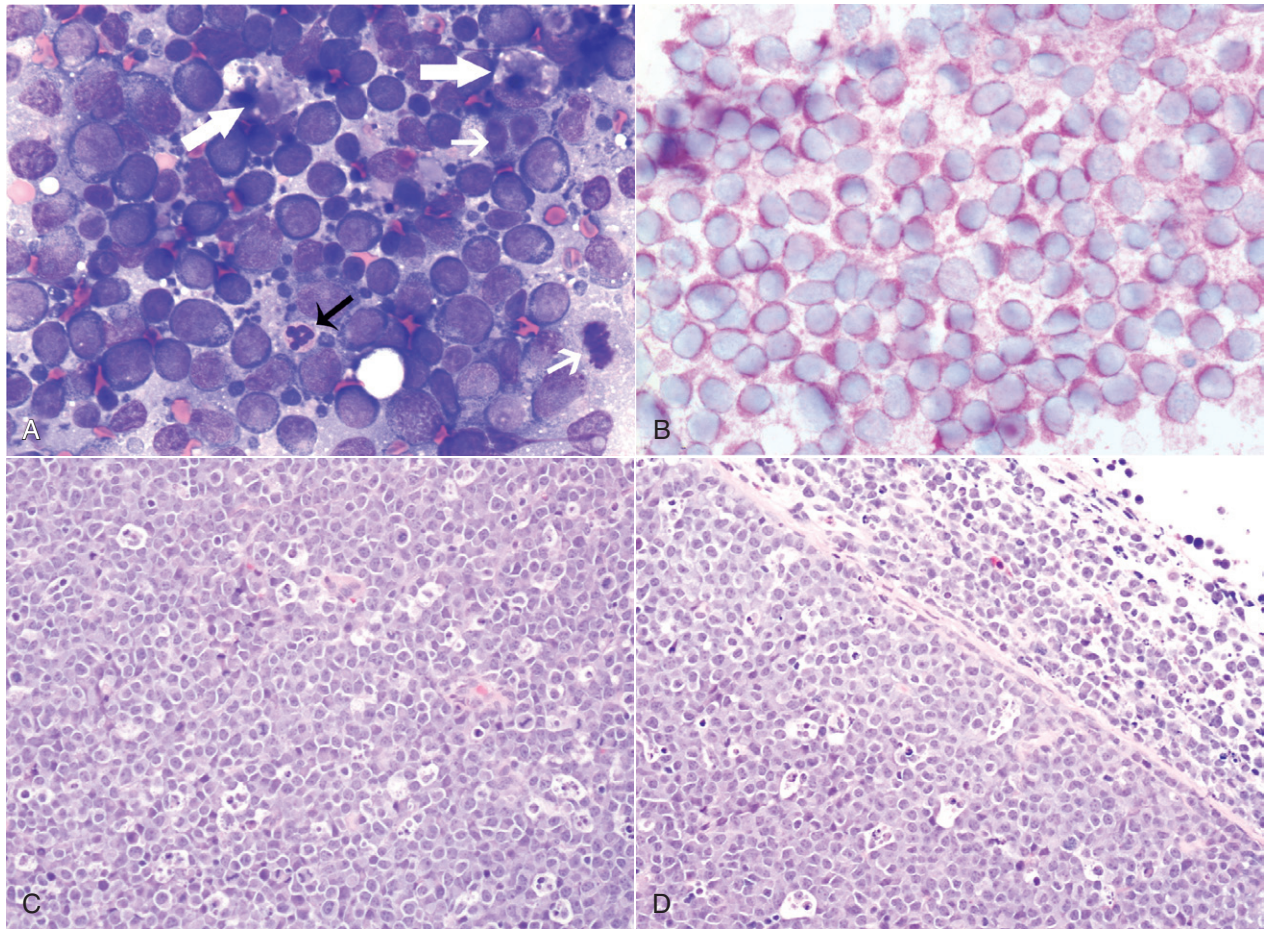
proteinuria in the absence of an active sediment may indicate renal disease, and hematuria may result from a hemostatic abnormality. It is important to remember that isosthenuria in azotemic dogs with hypercalcemia is not necessarily indicative of renal disease as the high calcium levels interfere with tubular concentration capabilities through disruption of antidiuretic hormone (ADH) control.

Several abnormalities in serum have been explored as biomarkers of lymphoma in the dog. Examples include alpha-fetoprotein, alpha-1 glycoprotein levels, zinc, chromium, iron, endostatin, vascular endothelial growth factor (VEGF), lactate dehydrogenase, C-reactive protein haptoglobin, and antioxidants/oxidative stress markers.<sup>115-122</sup> The clinical, biologic, and prognostic significance of these alterations is yet to be definitively characterized.

### Histologic and Cytologic Evaluation of Lymph Nodes

Morphologic examination of the tissue and cells that constitute the tumor is essential to the diagnosis of lymphoma. Care should be taken to avoid lymph nodes from reactive areas (e.g., mandibular lymph nodes), unless those nodes are the only ones enlarged; the

prescapular or popliteal lymph nodes are preferable if also involved. Also, lymphoid cells are fragile, and in preparing smears of aspirated material only gentle pressure should be applied in spreading material on the slides. In most cases, a diagnosis of lymphoma can be made on evaluation of fine-needle aspirates of affected lymph nodes or other tissues. Typically, most of the cells are large lymphoid cells (>2 times the diameter of a red blood cell [RBC] or larger than neutrophils), and they may have visible nucleoli and basophilic cytoplasm (Figure 32-6, A) or fine chromatin with indistinct nucleoli. Because tissue architecture is not maintained in cytologic specimens, effacement of the node or capsular disruption cannot be detected. Therefore marked reactive hyperplasia characterized by increased numbers of large lymphoid cells may be difficult to distinguish from lymphoma, and small cell lymphomas may have few cytologic clues that point to malignancy. Also, classification of lymphoma, which has been attempted using cytologic appearance and immunophenotypic analysis,<sup>123</sup> into subcategories that make up the low-, intermediate-, and high-grade forms is performed most accurately on histologic sections (discussed previously).



**FIGURE 32-6** Lymph nodes from dogs with lymphoma. **A**, Fine-needle aspirate. Note the homogenous population of large lymphoid cells with prominent nucleoli and basophilic cytoplasm. These cells are larger than the neutrophil (*black arrow*) in the field. Mitotic figures (*thin white arrows*) and tingible body macrophages (*thick white arrows*) also are present. (Wright's stain,  $\times 60$  objective.) **B**, Fine-needle aspirate stained for immunoreactivity for CD79a. Note that nearly all of the lymphocytes express CD79A. The diagnosis was B-cell lymphoma. (Alkaline phosphatase/fast red,  $\times 60$  objective.) **C**, Histologic section. Note effacement of normal architecture. The white spaces are macrophages, giving a "starry sky" appearance to the lymph node. (H&E,  $\times 20$  objective.) **D**, Histologic section. Note the presence of tumor cells outside the capsule of the lymph node. (H&E,  $\times 20$  objective.)



For accurate histopathologic evaluation, an entire lymph node, including the capsule, should be removed, placed in buffered formalin, and submitted to a pathologist. Although needle core biopsies may be satisfactory, it is important to avoid crush artifact or inadequate sample size. Most pathologists prefer whole node biopsies because they provide the maximal amount of information. Effacement of normal nodal architecture by neoplastic lymphocytes and capsular disruption are characteristic findings (Figure 32-6, C and D). Diagnostic ultrasonography and ultrasound-guided FNA or needle biopsy have been useful for evaluation of involvement of the liver, spleen, or abdominal lymph nodes.<sup>124-126</sup> Aspiration of ultrasonographically normal splenic tissue is rarely contributory to a diagnosis.<sup>124</sup> If possible, the diagnosis should be made by sampling peripheral nodes, avoiding percutaneous biopsies of the liver and spleen. However, if there is no peripheral node involvement, it is appropriate to biopsy affected tissues in the abdominal cavity.

### Histologic and Cytologic Evaluation of Extranodal Sites

When GI lymphoma is suspected, an open surgical wedge biopsy of the intestine is preferred in most cases to differentiate lymphoma from lymphocytic enteritis. If associated abdominal lymph nodes also appear involved, image-guided biopsies may be associated with less morbidity than intestinal biopsies. Multiple samples may be necessary to accurately diagnose segmental disease. Endoscopic biopsies may be inadequate as only a superficial specimen is obtained; however, more aggressive endoscopic biopsy techniques combined with more accurate histopathologic, immunophenotypic, and molecular assessments are improving the diagnostic yield of these less invasive techniques.<sup>127-130</sup> In many dogs with primary GI lymphoma, an inflammatory nonneoplastic infiltrate (i.e., LPE) may be misdiagnosed on biopsy specimens that are too superficial. The application of assays for clonal expansion (e.g., PARR—see next section on [molecular diagnostic techniques](#)) does not appear as yet to be as accurate for endoscopically derived intestinal biopsies as with other solid lymphoid tumors in dogs.

Cytologic examination of cerebrospinal fluid (CSF), thoracic fluid, or mass aspirates is indicated in animals with CNS disease, pleural effusion, or an intrathoracic mass, respectively. In one study of dogs with CNS involvement, CSF analysis was diagnostic in seven of eight dogs.<sup>103</sup> Characteristics of the CSF included an increased nucleated cell count in the seven dogs, and 95% to 100% of the cells were atypical lymphocytes. The CSF protein concentration was increased in five of the dogs, ranging from 34 to 310 mg/dL (reference interval: <25 mg/dL).

For cutaneous lymphoma, punch biopsies (4 to 8 mm) should be taken from the most representative and infiltrative, but not secondarily infected, skin lesions. Application of immunophenotypic and clonality assessments of cutaneous biopsies can aid in differentiating lymphoma from benign lymphocytic lesions.<sup>58,131,132</sup>

### Molecular Diagnostic Techniques

Molecular techniques can be used to establish a diagnosis of lymphoma or to further characterize the tumor after the initial diagnosis is made. Tissues and cells from peripheral blood, lymph nodes, nonlymphoid sites, and effusions can be analyzed by various molecular means to aid in cases that represent a more difficult diagnostic challenge, particularly in cases where reactive lymphocytosis and lymphoma are both possible based on standard histologic or cytologic assessment. These include histochemical and cytochemical, immunohistochemical and immunocytochemical, flow cytometric, and polymerase chain reaction (PCR) techniques. For example,

the immunophenotype (B-cell versus T-cell),<sup>93,133-140</sup> proliferation rate (e.g., expression of Ki67, proliferating cell nuclear antigen [PCNA] expression, argyrophilic nucleolar organizer regions [AgNOR]),<sup>53,133,141-145</sup> and clonality (PCR for antigen receptor gene rearrangement [PARR])<sup>146-154</sup> of the tumor can be determined. The availability of such analyses is increasing; however, at present, only immunophenotype and PARR clonality assays are routinely used in dogs to inform clinical decision making.

### Immunophenotyping

Immunophenotyping is used to determine the type of cells that comprise the tumor, but this technique also can be helpful for making the initial diagnosis.<sup>133-140,155</sup> When a heterogeneous population of lymphocytes is expected in a tissue, documentation of a homogeneous population of the same immunophenotype is supportive of a neoplastic process. The immunophenotype of a lymphocyte is identified by determining the expression of molecules specific for B-cells (e.g., CD79a, CD20) and T-cells (e.g., CD3). Although tumor cells sometimes have morphologic characteristics that typify a particular immunophenotype, exceptions occur, and morphologic appearance cannot be used as the sole determinant of immunophenotype. For example, in a series of nine high-grade T-cell lymphomas and leukemias in dogs, the cells had a plasmacytoid appearance, typically associated with B-cell lymphoma.<sup>156</sup> Similarly, anatomic location does not always predict the immunophenotype.

For accurate determination of immunophenotype, antibodies against lymphocyte markers are applied to tissue sections (immunohistochemistry), cytologic specimens (immunocytochemistry), or individual cells in a fluid medium (flow cytometry). Flow cytometric evaluation of cells obtained by needle aspiration is also feasible. For T-cells, markers include CD3 (pan T), CD4 (helper T), and CD8 (cytotoxic T); for B-cells, the markers are CD79a (Figure 32-6, B), CD20, and CD21. Increasingly, aberrant expression of CD molecules has been reported in canine lymphoma. In a study of 59 dogs with lymphoma, tumor cells from six dogs were positive for both T- and B-cell markers; however, a clonality assay (see later) revealed clonality either of the T-cell or the immunoglobulin receptor but not both. This indicates that in some cases, the malignant cells may co-express B- and T-cell markers.<sup>93</sup> Antibodies against these molecules are used to determine the immunophenotype; however, they also have potential utility as a therapeutic modality if tumor cells could be targeted using these antibodies.

### Other Immunohistochemical and Immunocytochemical Assessments

Assessments of markers of multidrug resistance and apoptotic pathways (e.g., P-glycoprotein, p53, Bcl-2 proteins) have been evaluated in dogs with lymphoma.<sup>19,79,142,156a,156b</sup> However, their clinical significance and utility await further evaluation.

### Clonality Assays

Occasionally, diagnosis of lymphoma and differentiation of malignant versus benign proliferation of lymphocytes are not possible based on standard histologic and cytologic criteria. In these cases, advanced molecular analyses may be helpful to confirm a diagnosis. Clonality is the hallmark of malignancy; that is, the malignant cell population theoretically should be derived from expansion of a single malignant clone characterized by a particular DNA region unique to that tumor. For example, in a dog with T-cell lymphoma, all the malignant cells theoretically should have the same DNA sequence for the variable region of the T-cell receptor gene.

Likewise, in a dog with B-cell lymphoma, the tumor cells should have identical DNA sequences in the variable region of the immunoglobulin (Ig) receptor gene. Conversely, in reactive lymphocytosis, the cells are polyclonal for their antigen receptors. Using this knowledge, investigators have used PCR technology to amplify the variable regions of the T-cell and immunoglobulin receptor genes to detect the presence of clonal lymphocyte populations in dogs (see Figure 8-4 of Chapter 8). These techniques are reviewed in Chapter 8 and elsewhere.<sup>150</sup> In physician-based medicine, such assays of clonality are approximately 70% to 90% sensitive and have a false-positive rate of approximately 5%, and recent studies report similar rates in dogs. False-negative and false-positive results can occur with clonality assays. For example, cells from a dog with lymphoma may be negative for clonality if the clonal segment of DNA is not detected with the primers used, if the malignant cells are natural killer (NK) cells (rare), or if the malignant cells are present in too low a frequency to be detected. False positives occur rarely in some infectious diseases (e.g., ehrlichiosis and Lyme disease). In these cases, a diagnosis should be made only after considering the results of all the diagnostic tests, including histologic/cytologic evaluation, immunophenotyping, and clonality studies in conjunction with signalment and physical examination findings. These molecular techniques, although helpful for diagnosis, could also have utility in detecting early recurrence and in determining more accurate clinical stage and so-called “molecular remission rates” because they are more sensitive than standard cytologic assessment of peripheral blood, bone marrow, or lymph nodes (covered subsequently in section on treatment response).

### Proteomics

Proteomics comprises, simplistically, methodologies that analyze the entire protein component or protein signature of cells (the proteome). Protein components of a cell (normal or malignant) change over time with upregulation and downregulation of gene expression in response to varied stimuli (e.g., growth factors, environmental cues). It may therefore be possible to use the field of proteomics to identify serum biomarkers of malignancy (i.e., cancer-specific protein markers) and to further analyze response to therapy or even to predict which therapies are appropriate for an individual patient's tumor. Although in its infancy in veterinary oncology, preliminary investigations of the proteome of dogs with lymphoma have been reported<sup>157-160</sup>; however, they have yet to reach the level of sophistication in which useful output would have an impact on clinical decision making.

### Staging

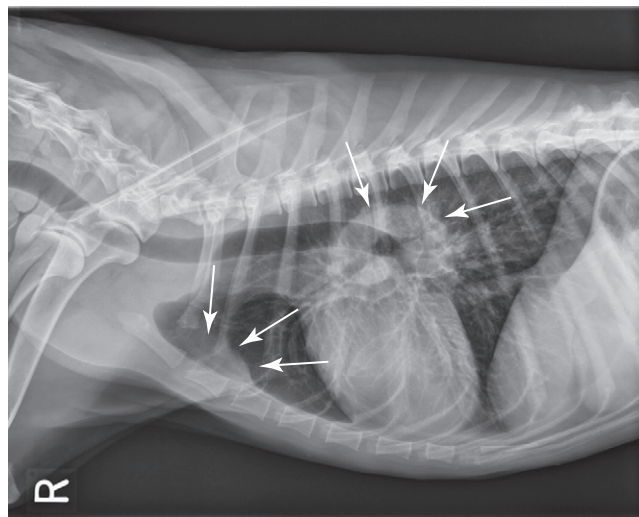
After a diagnosis has been established, the extent of disease should be determined and categorized by the clinical stage of disease. The WHO staging system routinely used to stage dogs with lymphoma is presented in Box 32-1. Most dogs (>80%) are presented in advanced stages (III to IV). Diagnostic imaging and assessment of bone marrow involvement may be indicated for staging. The degree to which thorough staging is implemented depends on whether the result will alter the treatment plan, whether relevant prognostic information is gleaned, and whether the clients need to know the stage prior to initiating (or declining) a treatment plan. Additionally, when comparing different treatment protocols with respect to efficacy, consistent and similar staging diagnostics should be used to avoid so-called “stage migration,” which results when one staging methodology is more accurate than another.<sup>161</sup> The impact of stage migration on prognosis should be considered when comparing different published outcomes.

### Bone Marrow Evaluation

A bone marrow aspirate or biopsy (from proximal humerus or iliac crest) is recommended for complete staging and prognostication and is indicated in dogs with anemia, lymphocytosis, peripheral lymphocyte atypia, or other peripheral cytopenias. In one study of 53 dogs with lymphoma, 28% had circulating malignant cells and were considered leukemic, whereas bone marrow examination indicated involvement in 57% of the dogs.<sup>162</sup> The presence of a few prolymphocytes and large lymphocytes with nucleoli in the circulation of dogs with lymphoma may indicate bone marrow involvement. It is important to remember these cells also can be seen with GI parasitism, immune-mediated hemolytic anemia, and other immune-mediated and infectious diseases. As discussed previously, tumor cells within the peripheral and bone marrow compartments can also be identified using clonality assays (PARR) that are more sensitive than routine microscopic examination in detecting malignant cells; however, the prognostic significance of the knowledge gained with more sensitive staging methodologies is yet to be determined. Although bone marrow evaluation may offer prognostically valuable information, it is not necessary to perform the procedure if the client is committed to treat regardless of stage.

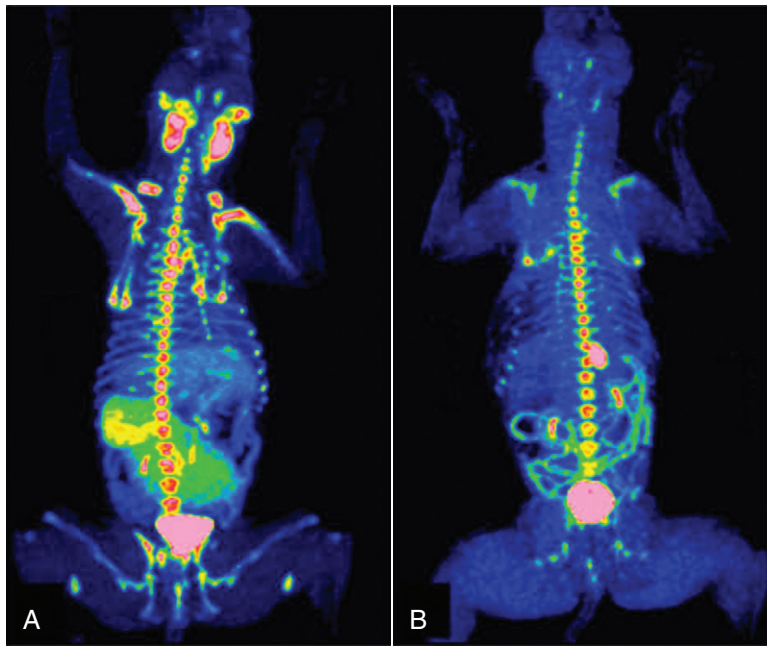
### Imaging

Evaluation of thoracic and abdominal radiographs may be important in determining the extent of internal involvement (Figure 32-7). Approximately 60% to 75% of dogs with multicentric lymphoma have abnormalities on thoracic radiographs, with one-third having evidence of pulmonary infiltrates (see Figure 32-3) and two-thirds having thoracic lymphadenopathy (sternal and tracheobronchial lymph nodes [see Figure 32-7]) and widening of the cranial mediastinum (see Figure 32-2).<sup>97,98</sup> Pulmonary infiltrates usually are represented by an interstitial and/or alveolar pattern; however, nodules (rarely) and bronchial infiltrates can also occur.<sup>163</sup> Pleural effusion may also be present. Cranial mediastinal lymphadenopathy is detected in 20% of dogs with lymphoma.<sup>97,163</sup> Abdominal radiographs reveal evidence of involvement of medial iliac (sublumbar) and/or mesenteric lymph node, spleen, or liver in approximately 50% of cases. In the authors' practice, for the typical cases of canine multicentric lymphoma, imaging is limited to thoracic



• **FIGURE 32-7** Lateral radiographic projection of a dog with sternal and hilar lymphadenopathy due to lymphoma.





**FIGURE 32-8** **A**, FLT-PET/CT image of a 3-year-old MN Hound cross illustrating FLT uptake in the peripheral nodes, bone marrow, kidneys, bladder, and spleen. **B**, FLT-PET/CT image of the same dog 3 weeks after his final dose of chemotherapy. The lymph nodes were small on CT with minimal FLT uptake on PET images. Note the persistent uptake in the bone marrow, kidneys, and bladder. (Reprinted with permission from Lawrence J, Vanderhoek M, Barbee D, et al: Use of 3'-deoxy-3'-[18F]fluorothymidine PET/CT for evaluating response to cytotoxic chemotherapy in dogs with non-Hodgkin's lymphoma, *Vet Radiol Ultrasound* 50:660–668, 2009.)

radiographs as there is no prognostic difference between dogs with stage III and IV disease (i.e., liver/spleen involvement), whereas the presence of cranial mediastinal lymphadenopathy is of prognostic significance (see [prognosis](#) section). However, if there are clinical signs attributable to abdominal disease or if complete staging is necessary (e.g., for clinical trial inclusion), further imaging of the abdomen is warranted. Abdominal ultrasonography can be important for obtaining ultrasound-guided intraabdominal samples for diagnosis. It may also be useful for the diagnosis of GI, abdominal nodal, and hepatosplenic lymphoma.<sup>125</sup> Ultrasonographic (including Doppler ultrasound) assessment of peripheral lymph nodes has also been explored<sup>126</sup>; however, its clinical applicability is questionable because cytologic assessment of peripheral nodes is easy, inexpensive, and of higher diagnostic utility.

Advanced imaging modalities, including computed tomography (CT), magnetic resonance imaging (MRI), positron emission tomography (PET), or PET/CT imaging, are becoming more commonplace in veterinary practice and their utility is only now being determined.<sup>164-169</sup> PET/CT imaging is the current standard of care for following and indeed predicting durability of treatment response in human patients with lymphoma, and both [18F]fluorothymidine (18FLT) PET/CT and [18F]fluoro-D-glucose (18FDG) PET imaging have been reported in dogs with lymphoma.<sup>164-166</sup> 18FLT-PET/CT functional and anatomic imaging shows promise for the evaluation of response to cytotoxic chemotherapy in dogs with lymphoma and for predicting relapse before standard clinical and clinicopathologic confirmation (Figure 32-8).

### Treatment of Multicentric Lymphoma

The therapeutic approach to a particular patient with lymphoma is determined by the stage and substage of disease, the presence or

absence of paraneoplastic disease, the overall physiologic status of the patient, financial and time commitment of the clients, and their level of comfort with respect to likelihood of treatment-related success and/or side effects.

Without treatment, most dogs with lymphoma will die of their disease in 4 to 6 weeks after diagnosis, although significant variability exists.<sup>114</sup> With few exceptions, canine lymphoma is considered a systemic disease and therefore requires systemic therapy in order to achieve remission and prolong survival. The majority of canine multicentric lymphomas are intermediate to high grade, and, currently, histopathologic and immunophenotypic characterization has not played a significant role in determining the initial treatment protocol. It is hoped that in the near future, sufficient data will emerge to better tailor treatment protocols chosen for dogs with lymphoma based on these and other yet to be characterized parameters. That being said, systemic multiagent chemotherapy continues to be the therapy of choice for canine lymphoma. In general, combination chemotherapy protocols are superior in efficacy to single-agent protocols. Single-agent protocols result in lower response rates that are not as durable as combination chemotherapy, which is summarized in Table 11-2 in Chapter 11. In rare cases in which lymphoma is limited to one site (especially an extranodal site), the animal can be treated with a local modality such as surgery or radiation therapy (RT) as long as the client and clinician are committed to diligent reevaluation to document subsequent progression to systemic involvement, should it occur.

### Multidrug Combination Protocols

Many chemotherapeutic protocols for dogs with lymphoma have been developed over the past 15 to 20 years (Table 32-3).<sup>91,170-190</sup> Significant limitations arise when comparing efficacy studies in the

• **TABLE 32-3** Summary of First Remission Outcomes of Combination or Single-Agent Doxorubicin Lymphoma Chemotherapy Protocols (Minimum of 30 Cases Required for Inclusion)\*

PROTOCOL	DOGS (NO)	REMISSION RATE (%)	MEDIAN REMISSION (MONTHS)	1-YEAR SURVIVAL (%)	REFERENCES
COP	77	75	6.0	19	170
A	37	59	4.4	NR	171
A <sup>†</sup>	121	85	4.3	NR	172
A	42	74	4.9	NR	173
A + piroxicam	33	79	4.3	NR	173
VMC-L	59	90	4.4	25	174
VMC-L	147	77	4.7	25	175
VCA-L	112	73	7.9	50	91
L-COPA	41	76	11.0 <sup>‡</sup>	48	176
L-COPA (II)	68	75	9.0 <sup>‡</sup>	27 (13 at 2 years)	177
COPLA/LVP	75	92 (80 <sup>‡</sup> )	5.8	17	178
VELCAP-SC	94	70	5.6	44	179
VLCAP-Long	98	69	12.5 <sup>‡</sup>	NR	180
L-VCAMP (UW-Madison)	55	84	8.4	50 (24% at 2 years)	181
L-VCAMP	96	79 (CR)	9	NR	182
(continuous maintenance)	86	90	6.8 <sup>‡</sup>	35 <sup>‡</sup>	183
L-VCAMP (± intensification)	130	94.6	7.3 <sup>§</sup>	NR	184
L-VCAP (25 weeks)	51	94	9.1	NR	185
L-VCAP-Mx <sup>  </sup>	65	94	10	NR	186
L-VCAP	71	88	9.7 <sup>‡</sup>	32 (13% at 2 years)	187
L-VCAP (12 weeks)	77	89	8.1 <sup>‡</sup>	28 <sup>‡</sup>	188
L-VCAP/CCNU/MOPrP	66	94	10.6 <sup>‡</sup>	46 (35% at 2 years)	187
COArP	71	92	3	NR	189
L-VCADP	39	100	11 <sup>§</sup>	NR	190

L, L-Asparaginase; V, vincristine; C, cyclophosphamide; M, methotrexate; Mx, mitoxantrone; O, Oncovin (vincristine); P, prednisone; A, Adriamycin (doxorubicin); D, dactinomycin; Pr, procarbazine; Ar, cytosine arabinoside; NR, not reported; CR, complete response.

\*Few of these protocols include sufficient numbers for adequate statistical power and fewer compare treatment protocols in a randomized prospective fashion. In addition, staging, inclusion, and response criteria vary considerably between protocols presented. Therefore evaluations of efficacy between the various protocols are subject to bias, making direct comparisons difficult and indeed precarious.

<sup>†</sup>With COP rescue.

<sup>‡</sup>Only durations of cases achieving CR reported.

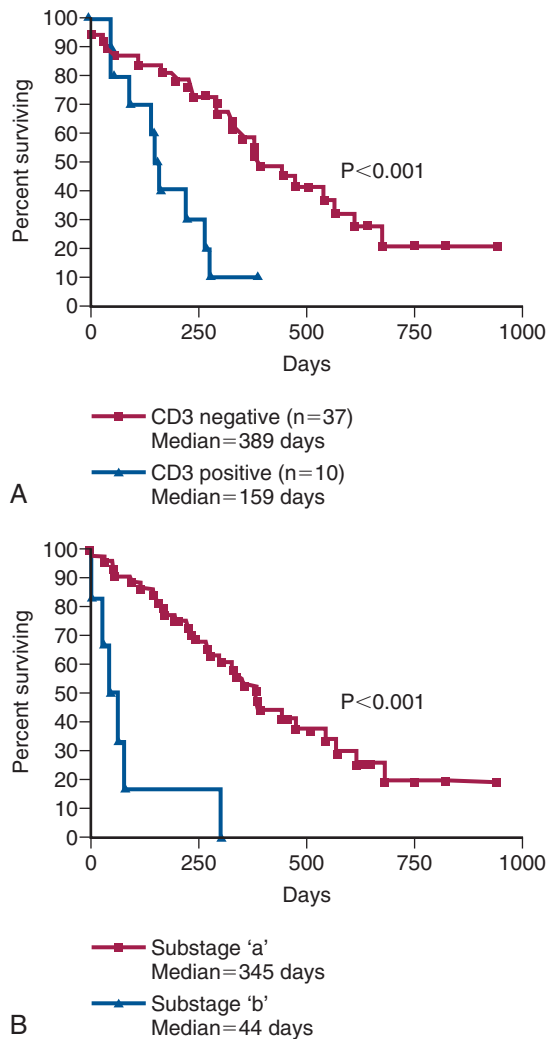
<sup>§</sup>Time to progression.

<sup>||</sup>Questionable (only one-third reportedly finished).

veterinary literature for the various published protocols. Few of these studies include sufficient numbers for adequate statistical power and even fewer compare treatment protocols in a randomized prospective fashion. In addition, staging, inclusion, and response criteria vary considerably between reports. Therefore evaluations of efficacy among various protocols are subject to substantial bias, making direct comparisons difficult and indeed precarious. A recurring theme in the concluding statement in most of these published protocols is some variation of “prospective randomized trials will be required to confirm these suggestive findings.” In an attempt to better standardize response criteria and outcome reporting of future trials, the Veterinary Cooperative Oncology Group (VCOG) has recently published response evaluation criteria (v1.0)<sup>169</sup> (see subsequent response evaluation section). The greatest obstacle to the performance of prospective randomized comparative lymphoma trials in veterinary oncology is financial;

that is, clinical trials are inherently costly, and because most of the known effective drugs are unregistered off-label human generic (i.e., off patent) drugs, the incentive for pharmaceutical-funded, sufficiently powered, randomized field trials is low, resulting in a general lack of comparative data.

Despite the plethora of available combination protocols, most are modifications of CHOP protocols initially designed for human oncologic use, and currently randomized prospective evidence does not exist to clearly recommend one over the other as long as the basic “CHOP” components are present. CHOP represents combinations of cyclophosphamide (C), doxorubicin (H, hydroxydaunorubicin), vincristine (O, Oncovin), and prednisone (P). Conventional CHOP-based chemotherapy induces remission in approximately 80% to 95% of dogs, with overall median survival times (MSTs) of 10 to 12 months. Approximately 20% to 25% of treated dogs will be alive 2 years after initiation of these protocols (Figure 32-9).



**FIGURE 32-9** **A**, Kaplan-Meier survival duration estimates for a group of 55 dogs with lymphoma treated with an identical CHOP-based combination chemotherapy protocol. Dogs with CD3 immunoreactive (T-cell) lymphoma had significantly shorter survival durations. **B**, Kaplan-Meier survival duration estimates for a group of 55 dogs with lymphoma treated with an identical CHOP-based combination chemotherapy protocol at the University of Wisconsin. Dogs with substage *b* disease (i.e., clinically ill) had significantly shorter survival durations. (From Vail DM: *Hematopoietic tumors*. In Ettinger SJ, Feldman EC, editors: *Textbook of veterinary internal medicine*, ed 6, St. Louis, 2005, Elsevier.)

Response rates and duration of response vary according to the presence or absence of prognostic factors discussed subsequently in the section on prognosis in this chapter. The relative cost of the various protocols to the client depends on the drug(s) selected, the size of the animal, the frequency of administration, and the laboratory tests required to monitor adverse events and response.

Dogs responding to chemotherapy and undergoing complete remission are usually free of clinical signs associated with lymphoma and subsequently return to a very good quality of life. Treating dogs with lymphoma is initially gratifying because a high percentage enjoy a complete response. Most dogs tolerate chemotherapy well, and although dose reductions and treatment breaks

(“treatment holidays”) are not uncommonly required in individual cases, only a minority of dogs develop significant adverse events requiring hospitalization.<sup>191,192</sup> Studies assessing client perceptions of medical treatment for cancer in general and lymphoma in particular report a positive experience; most owners feel treatment was worthwhile, that it resulted in improvement in the well-being of their pet, and that quality of life during treatment was good.<sup>193,194</sup> Very few clients express regret about treating lymphoma using a multidrug protocol.

With lymphoma, the fundamental goals of chemotherapy are to induce a complete durable (>6 months) first remission (termed *induction*), to reinduce a remission when the tumor recrudesces (or the patient relapses) following achievement of a remission (termed *reinduction*), and, finally, to induce remissions when the cancer fails to respond to induction or reinduction using drugs not present in the initial protocols (termed *rescue*).

An unanswered question in the treatment of lymphoma has been whether long-term maintenance chemotherapy is useful following an initial course of aggressive induction chemotherapy lasting 6 months or less. Long-term maintenance chemotherapy has not been shown to be of significant value in humans with most forms of NHL; however, in humans, the initial induction course of chemotherapy is much more aggressive than that used in veterinary patients. Although no randomized prospective studies have been performed to address the therapeutic benefit of long-term maintenance chemotherapy in dogs, most comparisons of dogs treated with CHOP-based protocols do not show any clear advantage for a maintenance or consolidation phase after induction therapy.\* Indeed, in most reports, dogs receiving shorter, less costly protocols that do not include a prolonged maintenance phase have comparable remission and progression-free survival (PFS) durations and appear to more readily achieve second remissions when they relapse following completion of chemotherapy than their counterparts receiving long-term maintenance. These data, taken together, suggest that maintenance therapy is not beneficial for most dogs with lymphoma. Until well-designed randomized prospective trials indicate otherwise, the author (DMV) prefers protocols that utilize an aggressive induction without maintenance.

### Single-Agent Chemotherapy with Known Activity for Dogs with Lymphoma

The most effective, currently available chemotherapeutic agents for canine lymphoma include doxorubicin, L-asparaginase, vincristine, cyclophosphamide, and prednisone—most of which are represented to one degree or another in most first-line multiagent chemotherapy protocols. Other drugs that have documented activity are often considered second-line agents and include lomustine, vinblastine, actinomycin-D, mitoxantrone, mustargen, chlorambucil, methotrexate, dacarbazine (DTIC), 9-aminocamptothecin, ifosfamide, cytosine arabinoside, and gemcitabine. Of these, cytosine arabinoside,<sup>199</sup> ifosfamide,<sup>200</sup> and gemcitabine<sup>201</sup> appear to have only minimal activity. With the exception of doxorubicin, induction therapy with single-agent chemotherapy does not typically result in durable remission durations when compared with standard combination protocols (see Table 11-2, Chapter 11). Incorporation of other standard cytotoxic drugs with single-agent activity into standard CHOP-based protocols has not resulted in significant gains, and most are reserved for subsequent rescue settings.

\*References 53, 177, 180, 182-186, 188, 190, 195-198.

## Overall Chemotherapy Recommendations for Multicentric Lymphoma (Author Preference)

Several factors should be considered and discussed with caregivers on a case-by-case basis when choosing the protocol to be used. These factors include cost, time commitment involved, efficacy, adverse event profiles, and experience of the clinician with the protocols under consideration.

### Induction in Treatment-Naïve Patients

It is now clearly established that “standard of care” combination protocols used in dogs with lymphoma are essentially variations of “CHOP” protocols (see Table 32-3). Specific details regarding dose and timing of the CHOP protocol currently preferred by the author (DMV) are outlined in Box 32-2. This protocol does not have a maintenance therapy arm, and all treatments cease at 19 weeks, provided the animal is in complete remission. Although several other CHOP-based protocols include L-asparaginase either at

initiation or at varying times throughout the protocol, several studies suggest this does not result in clinically relevant increases in remission rate, speed of attaining remission, or first-remission duration, and therefore the author reserves its use for rescue situations.<sup>172,195,202,203</sup>

If client or other considerations preclude a CHOP-based protocol, single-agent doxorubicin (30 mg/m<sup>2</sup>, intravenous [IV], every 3 weeks for 5 total treatments) is offered along with a 4-week tapering oral prednisone regimen (same prednisone regimen in Box 32-2) as a less aggressive and less costly approach. The expected CR rate will range from 50% to 75%, with an anticipated median survival of 6 to 8 months.<sup>171,172,204,205</sup> The addition of oral cyclophosphamide (50 mg/m<sup>2</sup> daily for 3 days starting on the same day as doxorubicin) to single-agent doxorubicin resulted in a numerically but not statistically superior outcome in a recent randomized trial<sup>205</sup> comparing doxorubicin/prednisone with doxorubicin/cyclophosphamide/prednisone (PFS of 5.6 months versus 8.2 months, respectively). This trial was only powered to detect a threefold difference in PFS; therefore larger trials should be undertaken to confirm any benefit.

If clients are reticent to include IV medications, the author often recommends a protocol of oral lomustine (CCNU; 70 mg/m<sup>2</sup> by mouth [PO] every 3 weeks for 5 treatments) and prednisone. This protocol has been associated with short median remissions (40 days) in only one small case series<sup>206</sup>; however, in the author’s experience, a subset of dogs have remained in remission for several months on this protocol when clients decline IV medication.

If financial or other client concerns preclude the use of systemic chemotherapy, prednisone alone (2 mg/kg PO, daily) will often result in short-lived remissions of approximately 1 to 2 months. In these cases, it is important to educate clients that, should they decide to pursue more aggressive therapy at a later date, dogs receiving single-agent prednisone therapy are more likely to develop multidrug resistance (MDR) and experience shorter remission and survival durations with subsequent combination protocols.<sup>207-209</sup> This is especially true following long-term prednisone use or in dogs that have experienced a recurrence while receiving prednisone. Therefore the earlier that clients opt for more aggressive therapy, the more likely a durable response will result.

A CBC should be performed prior to each chemotherapy treatment. A minimum of 1500 neutrophils/μL (some oncologists use a cut-off of 2000 neutrophils/μL) and 50,000 platelets/μL should be present prior to the administration of myelosuppressive chemotherapy. If the neutrophil count is lower than 1500/μL, it is best to wait 5 to 7 days and repeat the CBC; if the neutrophil count has increased to more than 1500 cells/μL, the drug can be safely administered. A caveat to these restrictions is that for dogs presented prior to initiation of chemotherapy with low neutrophil and platelet counts due to bone marrow effacement, myelosuppressive chemotherapy is instituted in the face of cytopenias in order to clear the bone marrow of neoplastic cells and allow hematopoiesis to normalize.

In those breeds likely to have *MDR1* gene mutations (e.g., collies; see Chapter 11) and therefore to be at risk for serious chemotherapeutic toxicity,<sup>210</sup> the author will initiate a CHOP protocol out of sequence, beginning with non-*MDR1*-associated drugs, such as cyclophosphamide. This ensures treatment of the lymphoma while allowing sufficient time for analysis of *MDR1* gene mutations prior to initiating *MDR1* substrate drugs. No specific protocols have been scrutinized for treating dogs that are double-mutant for *MDR1*; however, if using *MDR1* substrate drugs, the author initiates at a 40% dose reduction. Subsequent dose modifications (increased or decreased dosage) can be implemented,

### Box 32-2 Current Canine Lymphoma Protocol (UW-Madison-Short)

Week 1: Vincristine 0.7 mg/m<sup>2</sup> IV  
Prednisone 2 mg/kg PO, q24hr  
Week 2: Cyclophosphamide\* 250 mg/m<sup>2</sup> IV  
Prednisone 1.5 mg/kg PO, q24hr  
Week 3: Vincristine 0.7 mg/m<sup>2</sup> IV  
Prednisone 1.0 mg/kg PO, q24hr  
Week 4: Doxorubicin† 30 mg/m<sup>2</sup> IV  
Prednisone 0.5 mg/kg PO, q24hr  
Week 6: Vincristine 0.7 mg/m<sup>2</sup> IV  
Week 7: Cyclophosphamide\* 250 mg/m<sup>2</sup> IV  
Week 8: Vincristine 0.7 mg/m<sup>2</sup> IV  
Week 9: Doxorubicin† 30 mg/m<sup>2</sup> IV  
Week 11: Vincristine 0.7 mg/m<sup>2</sup> IV  
Week 12: Cyclophosphamide\* 250 mg/m<sup>2</sup> IV  
Week 13: Vincristine 0.7 mg/m<sup>2</sup> IV  
Week 14: Doxorubicin† 30 mg/m<sup>2</sup> IV  
Week 16: Vincristine 0.7 mg/m<sup>2</sup> IV  
Week 17: Cyclophosphamide\* 250 mg/m<sup>2</sup> IV  
Week 18: Vincristine 0.7 mg/m<sup>2</sup> IV  
Week 19: Doxorubicin† 30 mg/m<sup>2</sup> IV

IV, Intravenous; PO, by mouth.

\*Furosemide (1 mg/kg) is given IV, concurrent with cyclophosphamide to reduce incidence of sterile hemorrhagic cystitis.

†In dogs <15 kg in body weight, a doxorubicin dose of 1 mg/kg is substituted for 30 mg/m<sup>2</sup>.

- All treatments discontinued after week 19 if in complete remission (CR).
- A complete blood count (CBC) should be performed prior to each chemotherapy. If neutrophil count <1500 (some use 2000), wait 5-7 days and repeat CBC.
- If sterile hemorrhagic cystitis occurs on cyclophosphamide, discontinue and substitute chlorambucil (1.4 mg/kg PO) for subsequently scheduled cyclophosphamide injections.
- For acute lymphoblastic leukemia (ALL): Administer L-asparaginase 400 IU/kg subcutaneously (SQ) with each vincristine injection, until a CR is achieved.



depending on adverse event levels observed, particularly neutrophil counts at nadir.

## The Case for Treating T-Cell Lymphoma Differently

With some exceptions, multicentric T-cell lymphoma, when compared with multicentric B-cell lymphoma, is associated with similar initial response rates, but significantly lower response durability (e.g., PFS) following chemotherapy (including CHOP-based protocols).<sup>\*</sup> Additionally, the effectiveness of a single treatment of doxorubicin in the treatment of naïve dogs with lymphoma in one retrospective case series suggested a lower initial response rate for T-cell, compared with B-cell, immunophenotypes.<sup>213</sup> This has led many to question whether dogs diagnosed with T-cell lymphoma should be treated with standard CHOP-based protocols or with alternative protocols. This is a valid question; however, the answer remains elusive because adequately powered randomized controlled trials do not currently exist in the literature to show superiority for an alternate protocol in this scenario. A retrospective study of an L-asparaginase and MOPP (*M*, mechlorethamine; *O*, Oncovin; *P*, procarbazine; *P*, prednisone) protocol suggested improvement in PFS in dogs with either confirmed T-cell lymphoma or lymphoma with hypercalcemia and no immunophenotypic classification.<sup>214</sup> However, differences in determining PFS, response evaluation, and study population in this retrospective study did not definitively confirm superiority.<sup>211</sup> Further, some have advocated early inclusion of lomustine (CCNU) into protocols for treating multicentric T-cell lymphoma based on moderate success of lomustine-based rescue protocols in dogs failing CHOP. As yet, no randomized trials have documented superiority with this approach. Ultimately, superior protocol development for T-cell lymphoma awaits careful, randomized, prospective trial assessment. Until such time, the author prefers to initiate CHOP-based induction and switch to lomustine-based rescue at the first sign of progression.

## Treatment Response Evaluation for Lymphoma

VCOG has recently published response evaluation criteria (v1.0)<sup>169</sup> to standardize reporting of outcome results and comparisons among protocols for peripheral nodal disease. The most important of these outcome measures and the preferred temporal outcome criterion for assessing protocol activity is now considered to be PFS, which is defined as being from the time of treatment initiation until tumor progression or death from any cause. This brings veterinary outcome reporting more in line with human standards. Because the majority of dogs with lymphoma eventually experience recurrence following chemotherapy-induced remissions and because methodology for differentiating complete and partial responses is analysis dependent, PFS removes many sources of bias. Further, overall survival in published reports invariably includes patients who go on to receive varied rescue protocols that bias the overall result, making it a less comparable outcome. Widespread application of these standardized criteria should allow more suitable comparisons in the future.

Superior methods of detection of minimal residual disease (MRD) or early recurrence have been investigated in dogs with lymphoma and include advanced imaging and detection of

molecular and biologic markers of minimal disease. Advanced functional and anatomic imaging (i.e., PET/CT) are the current standard for assessing treatment response and early relapse of lymphoma in humans and have also been investigated in dogs (see Figure 32-8).<sup>164-166,168</sup> As this technology becomes available to a broader veterinary population, its clinical application will surely increase. Molecular detection of MRD applies clonality and PCR techniques previously discussed in this chapter. Beyond diagnostic applications, these techniques have been applied to determine cytoreductive efficacy of various chemotherapeutic drugs and to document and predict early relapse in patients prior to more conventional methods.<sup>215-219</sup> Regarding biomarkers of MRD, preliminary investigations have suggested serum lactate dehydrogenase activity,<sup>120</sup> thymidine kinase 1 activity,<sup>220</sup> and serum C-reactive protein<sup>221</sup> may be candidates in the dog.

As we become more proficient at defining MRD, the pressing clinical question becomes how we use this information. Theoretically, such information could suggest when more aggressive therapy or alternative therapy should be instituted in patients who have not achieved a “molecular remission” or who are undergoing early relapse; however, until we determine what these interventions should be, their clinical utility remains theoretical.

## Reinduction and Rescue Chemotherapy

Eventually, the majority of dogs that achieve a remission will relapse or experience recrudescence of lymphoma. This usually represents the emergence of tumor clones or tumor stem cells<sup>222</sup> (see Chapter 2) that are inherently more resistant to chemotherapy than the original tumor, the so-called MDR clones that either were initially drug resistant or became so following exposure to selected chemotherapy agents. Evidence suggests that in dogs with recurrent lymphoma, tumor cells are more likely to express the *MDR1* gene that encodes the protein transmembrane drug pump often associated with MDR.<sup>156a,156b,225</sup> *MDR1* represents only one of the plethora of mechanisms that lead to drug-resistant disease (see Chapter 11). Other causes for relapse following chemotherapy include inadequate dosing and frequency of administration of chemotherapy, failure to achieve high concentrations of chemotherapeutic drugs in certain sites such as the CNS, and initial treatment with prednisone alone.

At the first recurrence of lymphoma, it is recommended that reinduction be attempted first by reintroducing the induction protocol that was initially successful, provided the recurrence occurred temporally far enough from the conclusion of the initial protocol (e.g.,  $\geq 2$  months) to make reinduction likely. Attention must be given to the cumulative dose of doxorubicin that will result from reinduction, and baseline cardiac assessment, the use of cardioprotectants, alternative drug choices, and client education should all be considered. In general, the length of the reinduction will be half that encountered in the initial therapy; however, a subset of animals will enjoy long-term reinductions, especially if the dog completed the initial induction treatment protocol and was currently not receiving chemotherapy for several months when relapse occurred. Nearly 80% to 90% reinduction rates can be expected in dogs that have completed CHOP-based protocols and then relapse while not receiving therapy.<sup>185,226</sup> The duration of a second CHOP-based remission in one report was predicted by the duration of the interval between protocols and the duration of the first remission.<sup>226</sup>

If reinduction fails or the dog does not respond to the initial induction, the use of so-called “rescue” agents or “rescue” protocols may be attempted. These are single drugs or drug combinations that are typically not found in standard CHOP protocols and are

\*References 53, 86, 88, 91, 166, 188, 190, 209, 211-213.

• **TABLE 32-4** Summary of Response for Rescue Protocols (Minimum 25 Cases)\*

PROTOCOL	ANIMALS (NO)	OVERALL RESPONSE (%)	COMPLETE RESPONSE (%)	MEDIAN RESPONSE DURATION <sup>†</sup> (DAYS)	MEDIAN DURATION OF COMPLETE RESPONSE (DAYS)	REFERENCE
Actinomycin-D	25	0	0	0	0	227
Actinomycin-D	49 <sup>‡</sup>	41	41	129	129	228
Dacarbazine	40	35	3	43	144	229
Dacarbazine or temozolomide-anthracycline	63	71	55	45	NR	230
DMAC (dexamethasone, melphalan, actinomycin-D, cytosine arabinoside)	54	72	44	61	112	231
Lomustine (CCNU)	43	27	7	86	110	232
Lomustine-L-asparaginase-prednisone	48	77	65	70	90	233
Lomustine-L-asparaginase-prednisone	31	87	52	63	111	234
Lomustine-DTIC	57	35	23	62	83	235
Mitoxantrone	44	41	30	NR	127	236
MOPP (mechlorethamine, vincristine, procarbazine, prednisone)	117	65	31	61	63	237
MPP (mechlorethamine, procarbazine, prednisone)	41	34	17	56	238	238

NR, Not reported.

\*Few of these protocols include sufficient numbers for adequate statistical power and fewer compare treatment protocols in a randomized prospective fashion. In addition, staging, inclusion, and response criteria vary considerably between protocols presented. Therefore evaluations of efficacy between the various protocols are subject to bias, making direct comparisons difficult and indeed precarious.

<sup>†</sup>Various temporal response endpoints were used, including disease-free interval, time to progression, and progression-free survival.

<sup>‡</sup>Prednisone often used concurrently.

withheld for use in the drug-resistant setting. The most common rescue protocols used in dogs include single-agent use or a combination of actinomycin D, mitoxantrone, doxorubicin (if doxorubicin was not part of the original induction protocol), dacarbazine (DTIC), temozolomide, lomustine (CCNU), L-asparaginase, mechlorethamine, vincristine, vinblastine, procarbazine, prednisone, and etoposide. Some rescue protocols are easy and convenient single-agent treatments, whereas others are more complicated (and expensive) multiagent protocols, such as MOPP. Overall rescue response rates of 40% to 90% are reported; however, responses are usually not durable, with median responses of 1.5 to 2.5 months being typical, regardless of the complexity of the protocol. A small (<20%) subset of animals will enjoy longer rescue durations. Table 32-4 provides a summary of canine rescue protocols and published results.<sup>227-238</sup> Current published data from rescue protocols do not include sufficient numbers for adequate statistical power nor do they compare protocols in a randomized prospective fashion. Therefore evaluations of efficacy among various protocols are subject to substantial bias, making direct comparisons difficult and indeed precarious. Choice of a particular rescue protocol should depend on several factors, including cost, time commitment required, efficacy, toxicity, and experience of the clinician with the protocols in question. As the complexity of rescue protocols does not yet appear to be associated with significant gains in rescue durability, the author tends to choose simpler and less costly protocols (e.g., CCNU/L-asparaginase/prednisone) (Table 32-5). However, the use of multiple varied rescue protocols, switching as needed based on response, continues as long as clients are

comfortable with their dog's quality of life. This sequential application of several different rescue protocols can result in several months of extended survival with acceptable quality of life.

## Strategies to Enhance Effectiveness of Therapy in Lymphoma

Despite the plethora of published chemotherapeutic protocols for dogs with lymphoma, it appears we have achieved as much as we can from currently available chemotherapeutics in standard settings. The 12-month median survival "wall" and the 20% to 25% 2-year survival rates have not improved dramatically. Further advances in remission and survival durations await the development of new methods of delivering or targeting traditional chemotherapeutic drugs, new generations of chemotherapeutic drugs, or novel nonchemotherapeutic treatment modalities. Mechanisms of avoiding or abrogating MDR, enhancing tumor apoptosis (programmed cell death), tumor ablation, and immune-system reconstitution, as well as novel immunomodulatory therapies for lymphoma, are all active areas of investigation in both human and veterinary medicine.

### Mechanisms of Drug Resistance

Drug resistance can be inherent in cancer cells or develop following exposure to selected chemotherapeutic agents and often is associated with increased expression of members of the adenosine triphosphate (ATP)-binding cassette (ABC) transporter superfamily (e.g., P-glycoprotein pump), many of which efflux various

• TABLE 32-5 First-Line Rescue Protocol\*

## CYCLE 1

Week 1	<b>Baseline ALT</b> _____ U/L L-Asparaginase 400 U/kg SQ CCNU 70 mg/m <sup>2</sup> PO Prednisone 2mg/kg PO, once daily
Week 2	Prednisone 1.5 mg/kg PO, once daily
Week 3	Prednisone 1.0 mg/kg PO, once daily

## CYCLE 2

Week 1	<b>Optional ALT/</b> _____ U/L L-asparaginase 400 U/kg SQ CCNU 70 mg/m <sup>2</sup> PO Prednisone 1.0 mg/kg PO, EOD
Week 2	Prednisone 1.0 mg/kg PO, EOD
Week 3	Prednisone 1.0 mg/kg PO, EOD

## CYCLE 3 TO 5

Week 1	<b>Mandatory ALT</b> _____ U/L CCNU 70 mg/m <sup>2</sup> PO Prednisone 1.0 mg/kg PO, EOD
Week 2	Prednisone 1.0 mg/kg PO, EOD
Week 3	Prednisone 1.0 mg/kg PO, EOD

ALT, Alanine aminotransferase; SQ, subcutaneous; PO, by mouth; EOD, every other day.

\*Treatment discontinuation criteria:

1. After completion of protocol, two treatments beyond complete response (CR).
2. Progressive disease.
3. Increase in ALT activity >2× upper limit of normal (or 2× baseline if higher than upper limit of normal at initiation)—institute drug discontinuation and reinstatement/dose reduction depending on normalization of ALT.

chemotherapeutic compounds from cells (see Chapter 11).<sup>239</sup> P-glycoprotein is under the control of the *MDR1* gene. MDR has been reported in canine lymphoma following exposure to chemotherapy.<sup>156a,225,240</sup> Expression levels of mRNA encoding the canine *MDR1* gene have been characterized in canine cell lines and lymphomas. Although expression of *MDR1* mRNA correlated with in vitro drug sensitivity, it did not correlate with in vivo doxorubicin sensitivity in dogs with lymphoma in this study. Additionally, quantitative analysis of mRNA for 10 different drug-resistance factors was performed in 23 dogs with lymphoma.<sup>241</sup> These dogs were divided into drug “sensitive” and “resistant” categories based on response to a CHOP-based protocol; however, significant differences in expression were not observed in this small study.

### Altering Drug Pharmacokinetics

Methods of increasing the time that tumor cells are exposed to chemotherapeutics should theoretically enhance tumor killing. These methods could include long-term continuous infusions (impractical in many veterinary situations), increasing the frequency of treatments, or enhancing the circulation time of drugs used. In one study, dogs with lymphoma received lower dose doxorubicin weekly rather than a higher dose every 3 weeks (thereby decreasing  $C_{max}$ , which is associated with cardiotoxicity) in order to potentially increase the time of drug exposure.<sup>242</sup> No benefit was noted, and, in fact, remission rates were inferior. Studies evaluating pegylated long-circulating doxorubicin-containing liposome drug delivery systems in dogs with lymphoma have also been

performed.<sup>243,244</sup> Although efficacy was established, enhancement of remission or survival durations over equivalent doses of native doxorubicin was not observed.

## Treatment Approaches Using Immunologic or Biologic Agents

### Monoclonal Antibody Approaches

In the past decade, enhanced durability of first remissions in humans with non-Hodgkin's B-cell lymphoma has been achieved primarily through the institution of monoclonal antibody (MAB)-based therapies (so-called R-CHOP protocols); the “R” refers to rituximab, a recombinant chimeric murine/human antibody directed against the CD20 antigen, a hydrophobic transmembrane protein located on normal pre-B and mature B lymphocytes. Following binding, rituximab triggers a host cytotoxic immune response against CD20-positive cells. Unfortunately, rituximab does not have therapeutic activity in dogs due to a lack of external recognition of a similar antigen on canine lymphoma cells and the inherent antigenicity of human-derived antibodies in dogs.<sup>245,246</sup> Another immunotherapy approach involved MAB-231, a murine-derived anticanine MAB (IgG2a). It mediates antibody-dependent cellular cytotoxicity (ADCC) and complement-mediated cellular cytotoxicity (CMCC).<sup>247-249</sup> It also prevented outgrowth of canine lymphoma xenografts in nude mice. In a noncontrolled clinical study of 215 dogs treated with CHOP-based chemotherapy and MAB-231, enhanced overall survival was observed; however, the antibody was removed from the commercial market in the mid-1990s without definitive randomized trials being performed. Several laboratories throughout the world are currently working to characterize and develop effective MAB therapies for use in dogs.

### Antitumor Vaccine Approaches

Several antitumor vaccine approaches have been applied in dogs with lymphoma. A tumor vaccine extract using killed lymphoma cells combined with Freund's adjuvant was administered to a small number of dogs after remission induction with combination chemotherapy.<sup>250</sup> Prolongation of median survival was noted in the treatment group; however, a subsequent study revealed that prolongation was likely due to the Freund's adjuvant.<sup>251</sup> An autologous killed lymphoma tumor cell vaccine has been intralymphatically administered to dogs placed in remission using a combination chemotherapy protocol, and, although modest gains were reported in remission times, no survival advantage was found.<sup>252</sup> An exploratory vaccine study targeting telomerase<sup>253</sup> (see Chapter 14, Section D) and one using RNA-loaded CD40-activated B cells<sup>254</sup> in dogs with lymphoma have also been conducted. These studies involved small numbers of nonrandomized patients and lacked controlled populations for comparison. In a randomized study of 60 dogs with lymphoma comparing CHOP-based chemotherapy with CHOP-based chemotherapy and a human granulocyte-macrophage colony-stimulating factor (GM-CSF) DNA cationic-lipid complexed autologous whole tumor cell vaccine, a small measure of immunomodulation was documented by delayed-type hypersensitivity; however, significant improvement in clinical outcome was not noted.<sup>255</sup> Although little well-supported activity is reported to date with these immunomodulatory approaches, our basic understanding of methodologies is expanding.

### Surgery

Most dogs with lymphoma have multicentric disease and therefore require systemic chemotherapy to effectively treat their disease.

However, surgery has been used to treat solitary lymphoma (early stage I) or solitary extranodal disease. Careful staging is necessary in such cases to rule out multicentric involvement prior to treating local disease.

The benefit of surgical removal of the spleen in dogs with massive splenomegaly remains unclear.<sup>82,83,256</sup> In an older report, 16 dogs with lymphoma underwent splenectomy to remove a massively enlarged spleen and were subsequently treated with chemotherapy.<sup>256</sup> Within 6 weeks of splenectomy, 5 of the 16 dogs died of disseminated intravascular coagulation (DIC) and sepsis. The remaining 11 dogs (66%) had a CR, and 7 dogs had a MST of 14 months. No staging or histologic information was provided, so the information appears of limited usefulness, although those with follow-up lived approximately 1 year. In two reports of indolent nodular lymphoma of the spleen (marginal zone lymphoma [MZL] and mantle cell lymphoma [MCL]), outcome was available on seven MZL cases, including three cases that did not receive adjuvant chemotherapy after surgery,<sup>82,83</sup> and only one died of lymphoma following splenectomy. In a recent report of indolent lymphomas, four splenic lymphomas (three MZL and one MCL) underwent splenectomy alone and all survived greater than 1 year with none dying of their primary disease.<sup>84</sup> Splenectomy should be considered if the lymphoma is not documented in other sites following thorough staging, if lymphoma is an indolent form histologically, or if splenic rupture has occurred. Of note, no control population consisting of dogs that did not undergo splenectomy exists, so the natural history of indolent splenic lymphoma remains uncertain.

## Radiation Therapy

Radiation therapy, although its use is limited in the treatment of lymphoma, may be indicated in selected cases.<sup>257</sup> Indications are as follows:

1. Curative intent therapy for stage I lymph node and solitary extranodal disease (i.e., nasal, cutaneous, spinal lymphoma).
2. Palliation for local disease (e.g., mandibular lymphadenopathy, rectal lymphoma, mediastinal lymphoma where precaval syndrome is present, localized bone involvement).
3. Total body radiation combined with bone marrow or stem cell transplantation.
4. Whole or staged half-body RT following chemotherapy-induced remissions.

In the latter case, staged half-body irradiation sandwiched between chemotherapy cycles or following the attainment of remission by induction chemotherapy has been preliminarily investigated as a form of consolidation or maintenance.<sup>198,258-262</sup> Radiation therapy was delivered to either the cranial or the caudal half of the dog's body in 4 to 8 Gy fractions, and following a 2- or 4-week rest the other half of the body was irradiated in a similar fashion. Although these preliminary investigations were not randomized, they suggest that RT applied when dogs are in either complete or partial remission is safe and warrants further investigation to determine if a significant therapeutic gain can be realized. A pilot study of low-dose (1 Gy) single-fraction total body irradiation in seven dogs with relapsed drug-resistant lymphoma, although safely applied, resulted in only partial nondurable (1 to 4 week) remissions.<sup>263</sup>

Total body irradiation (and/or ablative chemotherapy) for complete or partial bone marrow ablation followed by reconstitution with bone marrow or stem-cell transplant in dogs, although a recognized model in comparative research settings,<sup>264,265</sup> is still in its early phases of development and application in clinical veterinary

practice.<sup>266,267</sup> Because of the high cost, limited accessibility to relatively sophisticated equipment, and management requirements, these types of procedures are limited to preliminary investigations at a few centers. Currently, long-term results in significant numbers of treated cases have yet to be presented.

## Treatment of Extranodal Lymphoma

In general, the veterinary literature suffers from a paucity of information on treating various extranodal forms of lymphoma in dogs, and our ability to predict outcome is thus limited. In general, it is recommended that, following extensive staging, in those cases where disease is shown to be localized to a solitary site, local therapies (e.g., surgery, local RT) can be used. In contrast, if multiple extranodal sites are involved or they are part of a more generalized process, systemic chemotherapy should be chosen.

### Alimentary Lymphoma

Most dogs with alimentary lymphoma are presented with diffuse involvement of the intestinal tract, and involvement of local lymph nodes and liver is common. Chemotherapy in dogs with diffuse disease has been reported to be unrewarding for the most part<sup>47,268,269</sup>; however, more aggressive CHOP-based protocols used extensively for multicentric lymphoma in dogs have resulted in durable remissions in a small subset of cases. Solitary alimentary lymphoma is rare in the dog; however, if the tumor is localized and can be surgically removed, results (with or without follow-up chemotherapy) can be encouraging.

### Primary Central Nervous System Lymphoma

CNS lymphoma in dogs usually results from extension of multicentric lymphoma. However, primary CNS lymphoma (PCNSL) has been reported.<sup>103-105</sup> If tumors are localized, local RT should be considered. Few studies have reported the use of chemotherapy. In one study, cytosine arabinoside (Ara-C) at a dosage of 20 mg/m<sup>2</sup> was given intrathecally; this treatment was combined with systemic chemotherapy and CNS radiation.<sup>103</sup> Overall, the response rates are low and of short duration (several weeks to months).

### Cutaneous Lymphoma

Treatment of cutaneous lymphoma depends on the extent of disease. Solitary lesions may be treated with surgical excision or RT. Fractionated RT (to a total dose of 30 to 45 Gy) has been associated with long-term control.<sup>270</sup> Diffuse cutaneous lymphoma is best managed with combination chemotherapy, although the rate and durability of response is generally less than in multicentric lymphoma. The most widely used protocols for epitheliotropic cutaneous T-cell lymphoma include CCNU (60 to 70 mg/m<sup>2</sup> PO, every 3 weeks) along with prednisone.<sup>271,272</sup> Although response rates approach 80%, median remission is approximately 3 months; occasionally, durable remissions are encountered. The author has added L-asparaginase to this protocol (see Table 32-5), and although anecdotally it appears to improve response, comparative data are not available. Sporadic reports of other therapies for cutaneous lymphoma in small numbers of cases include the use of COAP (cyclophosphamide, vincristine [Oncovin], Ara-C, and prednisone),<sup>273</sup> retinoic acid analogs (e.g., Accutane, etretinate),<sup>274</sup> L-asparaginase and pegylated L-asparaginase,<sup>275</sup> topical mechlorethamine (Mustargen),<sup>276</sup> and recombinant human  $\alpha$ -interferon.<sup>277</sup> All of these reports involved small numbers of cases and resulted in limited response rates with short durations.

A form of cutaneous lymphocytic infiltration has recently been characterized as an indolent T-cell lymphoma based on clonality.<sup>131</sup>



It is associated with slow progression and long-term survival following corticosteroid management; however, it does have the potential to progress to high-grade lymphoma.

## Prognosis

The prognosis for dogs with lymphoma is highly variable and depends on a wide variety of factors documented or presumed to affect response to therapy. Although rarely curable (<10% of cases), CRs and a good quality of life during extended remissions and survival are typical. Factors that have been shown to influence treatment response and survival are summarized in Tables 32-6\* and 32-7.† The two prognostic factors most consistently identified are immunophenotype and WHO substage (see Figure 32-9). Many reports have confirmed that dogs with CD3-immunoreactive tumors (i.e., T-cell derivation) are associated with significantly shorter remission and survival durations.‡ This holds true primarily for dogs with multicentric lymphoma because the immunophenotype of solitary or extranodal forms of lymphoma has not been thoroughly investigated with respect to prognosis. Additionally, it has been shown that dogs with B-cell lymphomas that express lower than normal levels of B5 antigen (expressed in 95% of nonneoplastic lymphocytes) also experience shorter remission and survival durations.<sup>54</sup> Recently, low levels of class II MHC expression on B-cell lymphoma predicted poor outcomes.<sup>279</sup> Dogs presented with WHO substage *b* disease (i.e., clinically ill) also do poorly when compared with dogs with substage *a* disease.<sup>53,86,91,181,278</sup> Dogs with stage I and II disease have a better prognosis than those dogs in more advanced stages (stage III, IV, and V).

Histologic grade (subtype) has been found to influence prognosis in some studies; however, our ability to predict outcome based on subtype is still quite limited. Dogs with lymphoma classified as intermediate or high grade (large cell, centroblastic, and immunoblastic) tend to respond to chemotherapy but can relapse early. Dogs with low-grade lymphomas (small lymphocytic or centrocytic) have a poorer response rate to chemotherapy, yet have a survival advantage over dogs with intermediate- and high-grade lymphomas (Figure 32-10) in that the disease may be more indolent. Several case compilations have documented that dogs with indolent lymphoma (e.g., MZL, MCL, T-zone) experience prolonged survivals, often in the absence of any or aggressive chemotherapy.<sup>82-84</sup> Proliferative assays such as analysis of bromodeoxyuridine (BrdU) uptake, Ki67 antibody reactivity, and argyrophilic nucleolar organizer region (AgNOR) indices to measure proliferative activity of tumor cells have been shown to provide prognostic information in dogs treated with combination chemotherapy. Results of different studies are contradictory, however. In two trials, dogs having tumors with short doubling times, high AgNOR frequencies, or high Ki67 immunoreactivity had a better prognosis than those with tumors with long doubling times or low AgNOR frequencies.<sup>53,142</sup> In other trials, the low-proliferating tumor groups were associated with a better prognosis.<sup>283,284</sup> Additionally, in one trial, the proportion of tumor cells undergoing apoptosis was mostly predictive of remission duration.<sup>142</sup>

The anatomic site of disease is also of considerable prognostic importance. Primary diffuse cutaneous, diffuse GI, hepatosplenic, and primary CNS lymphomas tend to be associated with a poor

\*References 53, 82-84, 89, 91, 97, 107, 142, 156a, 156b, 170, 175, 181, 204, 207-209, 217-219, 225, 278-285.

†References 91, 119, 120, 209, 220, 221, 286-290.

‡References 53, 54, 86, 88, 91, 209, 279.

Rights were not granted to include this figure in electronic media. Please refer to the printed publication.

• **FIGURE 32-10** Kaplan-Meier curves illustrating time to relapse adjusted for clinical stage and immunophenotype among dogs treated for low-grade (n = 17) (blue line) or high-grade (n = 51) (red line) Kiel classification lymphoma. (From Teske E, van Heerde P, Rutteman GR, et al: *Prognostic factors for treatment of malignant lymphoma in dogs*, J Am Vet Med Assoc 205:1722-1728, 1994.)

prognosis. Dogs with indolent cutaneous T-cell lymphocytic infiltration experience long-term survivals.<sup>131</sup> Sex has been shown to influence prognosis in some studies.<sup>175, 181</sup> Neutered females tend to have a better prognosis; male dogs may have a higher incidence of the T-cell phenotype, which may account for the poorer prognosis.

Reported biomarkers of prognosis, summarized in Table 32-7, include circulating levels of glutathione-S-transferase, thymidine kinase, lactate dehydrogenase, serum C-reactive proteins, and VEGF. Finally, one report suggests that a history of chronic inflammatory disease of several types predicts likelihood of early relapse.<sup>291</sup> These putative prognostic indicators require further confirmation in larger trials.

## Lymphocytic Leukemia

Lymphocytic leukemia is typically defined as proliferation of neoplastic lymphocytes in bone marrow. Neoplastic cells usually originate in the bone marrow, but occasionally in the spleen, and may or may not be circulating in the peripheral blood. Although our ability to diagnose lymphocytic leukemias using flow cytometric and molecular diagnostic techniques has increased significantly in the past decade, little information on treatment and prognosis is available except for chronic lymphocytic leukemia (CLL). Differentiating between true leukemia and stage V lymphoma can be difficult and arbitrary and is often based on lack of significant lymphadenopathy, degree of blood and bone marrow involvement, and immunophenotypic characteristics.

## Incidence, Risk Factors, and Etiology

Lymphocytic leukemia is more common than acute myeloid leukemia and myeloproliferative disorders (MPD), but the true incidence is unknown. German shepherd dogs and golden retrievers may be overrepresented.<sup>137,292</sup> Lymphocytic leukemia can occur in dogs of any age but typically occurs in middle-aged to older dogs (mean of 7 to 10 years); CLL usually occurs in older dogs (mean of 10 years).<sup>137,280,292,293</sup> A significant sex predilection is not reported. As with lymphoma, the etiology of lymphocytic leukemia is for the

• TABLE 32-6 Prognostic Factors for Lymphoma in Dogs

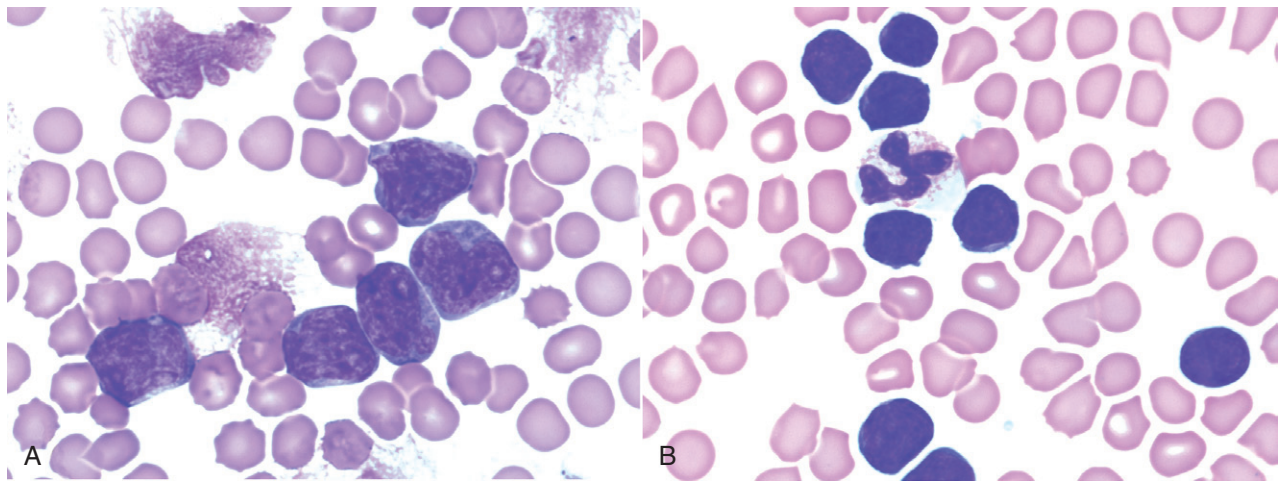
FACTOR	STRONG ASSOCIATION	MODEST ASSOCIATION REQUIRING FURTHER INVESTIGATION	COMMENTS	REFERENCES
WHO clinical stage		X	Stage I/II—favorable. Stage V with significant bone marrow involvement—unfavorable.	170, 204, 278
WHO clinical substage	X		Substage b (clinically ill)—associated with decreased survival.	53, 86, 91, 181, 278
Histopathology	X		High-grade/medium-grade—associated with high response rate but reduced survival. The indolent lymphomas generally experience prolonged survivals, often in the absence of systemic therapy.	82-84, 86, 87, 209
Immunophenotype	X		T-cell phenotype associated with reduced survival. Low MHC II expression on B-cell associated with reduced survival.	53, 54, 86, 88, 91, 209, 279
Flow cytometric characteristics of peripheral blood	X		Includes combined size and immunophenotypic analysis.	280
Sex		X	Some studies suggest females have a favorable prognosis.	175, 181
Anemia	X		Presence of anemia diminishes prognosis.	209, 281, 282
Molecular assessment of minimal residual disease (e.g., PARR)		X	Likely to become much more important when more “curative” therapeutic approaches are developed and instituted.	217-219
Measures of proliferation		X	Contradictory reports exist.	53, 142, 283, 284
Prolonged steroid pretreatment	X		Most reports suggest previous steroid use shortens response durations; however, length of exposure necessary is unknown.	207, 208
P-glycoprotein expression (drug resistance factors add)		X	May be associated with poor response rates and shortened remissions	223-225
Cranial mediastinal lymphadenopathy	X		Large compilation of cases reports shorter remission and survival durations.	97
Anatomic location	X		Leukemia, diffuse cutaneous and alimentary, hepatosplenic forms associated with unfavorable prognosis	See text for extra nodal sites
Chemotherapy-induced hematologic toxicity		X	Dogs experiencing grade III/IV neutropenia have prolonged first remission durations.	285

PARR, PCR for antigen receptor gene rearrangement.

• **TABLE 32-7** Circulating (Serum/Plasma) Biomarkers as Prognostic Indices in Dogs with Lymphoma

BIOMARKER	COMMENTS	REFERENCES
Lactate dehydrogenase activity	Increased activity predicted early recurrence.	120
Thymidine kinase activity	Increases associated with diminished prognosis.	220, 286
Serum VEGF levels	Small study suggests pretreatment levels predictive of remission duration.	119, 287
Glutathione-S-transferase	Increases associated with diminished prognosis.	288
Hypercalcemia	Negative factor if associated with T-cell subtype and reduced renal function.	91, 289, 290
Serum cobalamine	Hypocobalaminemia associated with poor outcome.	290
Serum C-reactive protein	Although it may be used to characterize remission status, variable levels preclude utility.	221

VEGF, Vascular endothelial growth factor.



• **FIGURE 32-11** **A**, Peripheral blood from a dog with acute lymphoblastic leukemia (ALL). Note the large lymphoid cells with visible nucleoli. Chromatin from disintegrated cells also is visible. (Wright's stain,  $\times 60$  objective.) **B**, Peripheral blood from a dog with chronic lymphocytic leukemia (CLL). Note the small lymphocytes of normal morphology (smaller than the neutrophil). (Wright's stain,  $\times 60$  objective.)

most part unknown. Genetic factors likely play a role and have been compared between dogs and humans.<sup>16</sup> Retroviruses have been implicated in diverse animal species such as cats, cattle, fish, snakes, birds, rodents, nonhuman primates, and humans; however, there is no proven evidence implicating a retroviral cause in dogs. In humans, acute lymphocytic leukemia (ALL) has been associated with genetic factors and exposure to radiation, benzene, phenylbutazone, and antineoplastic agents. Extrapolation of predisposing factors across species is not warranted; in fact, etiologic factors in dogs may be quite different from those for humans given the difference in the predominant immunophenotype of the neoplastic cells (see later).

## Pathology and Classification

Lymphocytic leukemias can be subdivided based on cell size, maturity, genetic aberrations, microRNA expression, and immunophenotype.\* The simplest classification divides leukemia into two groups: chronic (small cells with a mature cytologic phenotype) and

acute (large cells with an immature cytologic phenotype). Immunophenotypic assessment using flow cytometric and molecular assays can further characterize these two major subtypes; however, some discordance exists in the veterinary literature.

Three primary subtypes of CLL are reported in dogs, based primarily on immunophenotyping<sup>137,280,293</sup>: (1) T-CLL, which is the most common form, with cells in the majority of cases being CD8<sup>+</sup> granular lymphocytes; (2) B-CLL, which is the next most common subtype; and (3) atypical CLL, which represents a combination of immunophenotypes (CD3<sup>-</sup>, CD8<sup>+</sup>; CD3<sup>+</sup>, CD4<sup>-</sup>, CD8<sup>+</sup>; CD3<sup>+</sup>, CD4<sup>+</sup>, CD8<sup>+</sup>; and CD3<sup>+</sup> + CD21<sup>+</sup>). This is in contrast to CLL in humans, which is primarily a disease of B-cells. In CLL, lymphocytes often are indistinguishable morphologically from normal small lymphocytes (Figure 32-11) and have a low rate of proliferation; accumulation of lymphocytes likely results from their prolonged lifespan.

The immunophenotype of ALL typically is B-cell (CD21<sup>+</sup>, CD3<sup>-</sup>, CD4<sup>-</sup>, CD8<sup>-</sup>), although a smaller percentage (<10%) are of T-cell

\*References 16, 137, 150, 280, 292-294.

\*Note that either CD21 or CD79 can be used for assessing B-cell lineage in this context.



origin (CD3<sup>+</sup>, CD4<sup>-</sup>, CD8<sup>-</sup>, CD21<sup>-</sup>).<sup>137</sup> In general, these cells tend to be intermediate-sized or large cells with moderate amounts of basophilic cytoplasm. Perhaps the most distinguishing feature of lymphoblasts is the nuclear chromatin pattern, which typically is more condensed than the chromatin in myeloblasts. Lymphoblasts are larger than neutrophils, have a high nuclear:cytoplasmic ratio, and contain blue cytoplasm that in some cases is intensely basophilic (see Figure 32-11). Nucleoli, although present, are less prominent in lymphoblasts than in myeloblasts. Nevertheless, these cells cannot be distinguished easily from blast cells of other hematopoietic lineages, and identification of lineage-specific markers by immunocytochemical or flow cytometric analysis is required to ascertain the lineage. If the cells express CD34, a stem cell marker, an acute phenotype is implied<sup>137,280</sup>; however, both myeloid and lymphoid lineages express CD34, and our ability to differentiate ALL from acute myeloid leukemia (AML) relies on detection of other markers, including T- and B-cell markers and myeloperoxidase, a myeloid marker.

## History and Clinical Signs

Dogs with CLL are often asymptomatic, but some owners report lethargy and decreased appetite. Mild lymphadenopathy and splenomegaly may be present, although late in the disease splenomegaly may be marked.<sup>295</sup> The white blood cell (WBC) count is usually greater than 30,000 cells/ $\mu$ L but can vary from normal to greater than 100,000 cells/ $\mu$ L because of an increase in circulating mature lymphocytes. Lymphocytosis is persistent and granulocytes are usually present in normal numbers. Other than lymphocytosis, hemograms of dogs with CLL tend to have few abnormalities when lymphocytes are less than 30,000/ $\mu$ L.<sup>137,280,293</sup> In some dogs, the disease is identified incidentally when the animal is undergoing evaluation for an unrelated problem. Mild anemia, neutropenia, and thrombocytopenia are common but may become marked as the disease progresses and lymphocyte counts increase above 30,000/ $\mu$ L. Despite the well-differentiated appearance of the lymphocytes in CLL, these cells may function abnormally. Paraneoplastic syndromes include monoclonal gammopathies, immune-mediated hemolytic anemia, pure red cell aplasia, and, rarely, hypercalcemia.<sup>296,297</sup> In one report of 22 dogs with CLL, 68% had monoclonal gammopathies (usually IgM or IgA).<sup>296</sup> The immunophenotypes were not reported, but a monoclonal gammopathy would be more likely to occur in B-CLL.

Dogs with ALL usually are presented with clinical signs of anorexia, weight loss, and lethargy. Splenomegaly is typical and other physical abnormalities may include hemorrhage, lymphadenopathy, and hepatomegaly.<sup>298</sup> Infiltration of bone marrow by neoplastic lymphoblasts may be extensive, resulting in significant depression of normal hematopoietic elements or myelophthisis.<sup>137,280,292,298,299</sup> Anemia, neutropenia, and thrombocytopenia are typically much more severe than with CLL and may become life threatening. Infiltration of extramedullary sites such as the CNS, bone, and GI tract may also occur and can result in neuropathies, bone pain, and GI signs, respectively.

## Diagnostics and Clinical Staging

Consideration of signalment, history, physical findings, and morphologic appearance and immunophenotype of cells is essential in making an accurate diagnosis. It is helpful to know the profile of lymphocyte subsets in the peripheral blood of normal dogs to determine if a particular subset has expanded. Approximately 80% of circulating lymphocytes in normal dogs are T-cells, and about 15% are B-cells. NK cells and double-negative (CD4<sup>-</sup>, CD8<sup>-</sup>) T-cells

constitute the remaining fraction. In the T-cell fraction, helper T-cells (CD4<sup>+</sup>) outnumber cytotoxic T-cells (CD8<sup>+</sup>).<sup>296</sup> Lymphocytic leukemia should be a consideration if atypical lymphocytes are in circulation, the immunophenotype of the lymphocytes in circulation is homogenous as determined by flow cytometric analysis, a phenotype typically present in low frequency has increased, or if clonality is documented (e.g., by PARR analysis). Other differential diagnoses for lymphocytosis include infectious diseases, such as chronic ehrlichiosis, postvaccinal responses in young dogs, IL-2 administration, and transient physiologic or epinephrine-induced lymphocytosis. In some cases, reactive and neoplastic lymphocytosis are difficult to distinguish.

Expansion of neoplastic lymphocytes in bone marrow is the hallmark of ALL and, in most cases, CLL. Careful examination of peripheral blood and bone marrow by an experienced cytopathologist is important in establishing a diagnosis of lymphoid leukemia; in cases of marked lymphocytosis with atypia, peripheral blood can be used for analysis of immunophenotype and clonality, and examination of bone marrow is not essential. If diagnostic bone marrow cannot be adequately obtained by aspiration, bone marrow core biopsy should be performed. In ALL, lymphoblasts predominate in the bone marrow and are also present in peripheral blood, and other lineages are decreased. In B- and T-cell CLL, the lymphocytes are small mature cells that occur in excessive numbers in bone marrow ( $\geq 30\%$  of all nucleated cells) early in the disease.<sup>295</sup> In T-CLL, lymphocytes may contain pink granules. Infiltration becomes more extensive as the disease slowly progresses, and eventually the neoplastic cells replace normal marrow.

A separate clinical staging system has not been developed for lymphoid leukemia. Currently, all dogs with leukemia are classified as stage V based on the WHO Staging System for lymphoma as presented in Table 32-2.

## Treatment of Chronic Lymphocytic Leukemia

Because of the indolent and often asymptomatic nature of CLL, the decision to treat is often based on the clinical and laboratory findings in the individual dog. Most oncologists recommend active surveillance (monthly or bimonthly physical examination and CBC) over active therapy for patients when CLL is identified incidentally, there are no accompanying clinical signs, and other significant hematologic abnormalities are not identified. If the animal is significantly anemic or thrombocytopenic, is showing evidence of significant lymphadenopathy or hepatosplenomegaly, or has an excessively high lymphocyte count (e.g.,  $>60,000/\mu$ L), therapy should be instituted. The definition of "excessively high" varies among oncologists, and a standard has not been established in veterinary medicine. The author (DMV) prefers to base treatment decisions on the presence of significant constitutional signs and peripheral cytopenias. Currently, the most effective drug available for treatment of CLL is chlorambucil.<sup>295</sup> Chlorambucil is given orally at a dose of 0.2 mg/kg or 6 mg/m<sup>2</sup> PO once daily for 7 to 14 days; the dose can then be reduced to 0.1 mg/kg or 3 mg/m<sup>2</sup> PO daily. For long-term maintenance, a dose of 2.0 mg/m<sup>2</sup> every other day can be used. The dose is adjusted based on clinical response and bone marrow tolerance. Oral prednisone is used concurrently with chlorambucil at doses of 1 mg/kg daily for 1 to 2 weeks, then 0.5 mg/kg every other day thereafter. The addition of vincristine or the substitution of cyclophosphamide for chlorambucil has been advocated in animals that do not respond to chlorambucil.

Treatment of CLL is primarily palliative with rare complete remissions. Owing to the indolent nature of this disease, however, survival times have been in the range of 1 to 3 years with a good quality of life.<sup>295,300</sup> The phenotypic expression of CLL is usually stable over months to years. However, the disease may evolve into an acute phase, and some dogs will develop a form of lymphoma that is rapidly progressive and characterized by the presence of pleomorphic immunoblasts; in humans, this is termed *Richter's syndrome*.<sup>301</sup> The prognosis for response to treatment is poor for this form of lymphoma.

## Treatment of Acute Lymphoblastic Leukemia

Much of the morbidity in dogs with ALL results from effacement of bone marrow (myelophthisis) and subsequent life-threatening peripheral cytopenias. Neutropenia, thrombocytopenia, and anemia may be severe. Patients often require supportive therapy, such as fresh whole-blood transfusions, broad-spectrum antibiotics, fluid therapy, and nutritional support. Careful monitoring for sepsis, hemorrhage, and DIC is important. Specific treatment of ALL requires aggressive chemotherapy. Consistently efficacious protocols for ALL have not been developed in veterinary medicine, and there are few published reports. CHOP-based protocols, similar to those used for lymphoma (see Table 32-4), have been used by the author (DMV) for dogs with ALL; however, responses and durability of response are generally disappointing. The standard of care in humans with acute leukemia generally involves bone marrow ablative treatments with stem cell or marrow replacement, a protocol not generally available in veterinary oncology.

## Prognosis

In general, CLL is a slowly progressive disease, and some animals will not require therapy for some time after diagnosis; one dog was reported to survive almost 2 years without treatment.<sup>302</sup> For those dogs that are treated, normalization of lymphocyte counts can be expected in 70% of cases. In one report of 17 dogs treated with vincristine, chlorambucil, and prednisone, MST was approximately 12 months with an expected 30% survival at 2 years.<sup>295</sup> In larger compilations of cases that include immunophenotypic analysis, treatment protocols were poorly documented, although most received chlorambucil and prednisone; in 43 dogs with follow-up, for dogs with T-CLL, B-CLL, and atypical CLL, median survival was 930, 480, and only 22 days, respectively.<sup>293</sup> In this group of dogs, young age and anemia were also associated with a poor prognosis. In another series with limited treatment information, dogs with CLL of a CD8<sup>+</sup> immunophenotype that presented with less than 30,000 lymphocytes/ $\mu$ L or greater than 30,000 lymphocytes/ $\mu$ L had median survivals of 1098 and 131 days, respectively.

Prognosis for dogs with ALL is generally very poor. In a study of 21 dogs treated with vincristine and prednisone, the dogs achieving complete or partial remission (29%) had a MST of 120 days, and few dogs survived longer than 8 months with that protocol.<sup>298</sup> In one report of 46 cases of ALL with a CD34<sup>+</sup> phenotype, dogs had a median survival of 16 days (ranged from 3 to 128 days), even though the majority received a CHOP-based treatment protocol.<sup>280</sup> Additionally, dogs with B-cell ALL (CD21<sup>+</sup>) in which the lymphocytes were large cells (forward scatter lymphocyte/forward scatter neutrophil ratio of >0.58 by flow cytometric analysis) had a median survival of only 129 days, independent of treatment protocol.<sup>280</sup>

## REFERENCES

- Dorn CR, Taylor DON, Schneider R, et al: Survey of animal neoplasms in Alameda Contra Costa counties, California. II. Cancer morbidity in dogs and cats from Alameda County, *J Natl Cancer Inst* 40:307–318, 1968.
- Dorn CR, Taylor DON, Schneider R: The epidemiology of canine leukemia and lymphoma. In Dutcher RM, editor: *Comparative Leukemia Research Proceedings*. 4th International Symposium in Comparative Leukemia Research, Cherry Hill, NJ, *Bibl Haematol* 36:403–415, 1970.
- Merlo DF, Rossi L, Pellegrino C, et al: Cancer incidence in pet dogs: findings of the Animal Tumor Registry of Genoa, Italy, *J Vet Intern Med* 22:976–984, 2008.
- Kaiser HE: Animal neoplasia: a systemic review. In Kaiser HE, editor: *Neoplasms-comparative pathology in animals, plants and man*, Baltimore, 1981, Williams & Wilkins.
- Moulton JE, Harvey JW: Tumors of lymphoid and hematopoietic tissue. In Moulton JE, editor: *Tumors of domestic animals*, ed 3, 1990, University of California Press.
- Jemal A, Tiwari RC, Murray T, et al: Cancer statistics, 2004, *CA Cancer J Clin* 54:8, 2004.
- Villamil JA, Henry CJ, Hahn AW, et al: Hormonal and sex impact on the epidemiology of canine lymphoma, *J Cancer Epidemiol* 2009:591753. Epub 2010 Mar 14.
- Priester WA, McKay FW: The occurrence of tumors in domestic animal, *Nat Cancer Inst Monogr* 54:1–210, 1980.
- Edwards DS, Henley WE, Harding EF, et al: Breed incidence of lymphoma in a UK population of insured dogs, *Vet Comp Oncol* 1:200–206, 2003.
- Thomas R, Smith KC, Bould R, et al: Molecular cytogenetic analysis of a novel high-grade T-lymphoblastic lymphoma demonstrating co-expression of CD3 and CD79a cell markers, *Chromosome Res* 9:649–657, 2001.
- Thomas R, Smith KC, Ostrander EA, et al: Chromosome aberrations in canine multicentric lymphomas detected with comparative genomic hybridisation and a panel of single locus probes, *Br J Canc* 89:1530–1537, 2003.
- Thomas R, Fiegler H, Ostrander EA, et al: A canine acner-gene microarray for CGH analysis of tumors, *Cytogenet Genome Res* 102:254–260, 2003.
- Thomas R, Seiser EL, Motsinger-Reif A, et al: Refining tumor-associated aneuploidy through “genomic recording” of recurrent DNA copy number aberrations in 150 canine non-Hodgkin's lymphomas, *Leuk Lymphoma* 52:1321–1335, 2011.
- Starky MP, Murphy S: Using lymph node fine needle aspirates for gene expression profiling of canine lymphoma, *Vet Comp Oncol* 8:56–71, 2010.
- Devitt JJ, Maranon DG, Ehrhart EJ, et al: Correlations between numerical chromosomal aberrations in the tumor and peripheral blood in canine lymphoma, *Cytogenet Genome Res* 124:12–18, 2009.
- Breen M, Modiano JF: Evolutionarily conserved cytogenetic changes in hematological malignancies of dogs and humans—man and his best friend share more than companionship, *Chromosome Res* 16:145–154, 2008.
- Lindblad-Toh K, Wade CM, Mikkelsen TS, et al: Genome sequence, comparative analysis and haplotype structure of the domestic dog, *Nature* 438:803–819, 2005.
- Hahn KA, Richardson RC, Hahn EA, et al: Diagnostic and prognostic importance of chromosomal aberrations identified in 61 dogs with lymphosarcoma, *Vet Pathol* 31:528–540, 1994.
- Veldhoen N, Stewart J, Brown R, et al: Mutations of the p53 gene in canine lymphoma and evidence for germ line p53 mutations in the dog, *Oncogene* 16:249–255, 1998.
- Nasir L, Argyle DJ: Mutational analysis of the tumour suppressor gene p53 in lymphosarcoma in two bull mastiffs, *Vet Rec* 145:23–24, 1999.
- Sokolowski J, Cywinska A, Malicka E: p53 expression in canine lymphoma, *J Vet Med A Physiol Pathol Clin Med* 52:172–175, 2005.

22. Setoguchi A, Sakai T, Okuda M, et al: Aberrations of the p53 suppressor gene in various tumors in dogs, *Am J Vet Res* 62:433–439, 2001.
23. Sueiro FAR, Alessi AC, Vassallo J: Canine lymphomas: a morphological and immunohistochemical study of 55 cases, with observations on p53 immunoreactivity, *J Comp Pathol* 131:207–213, 2004.
24. Pelham JT, Irwin PJ, Kay PH: Genetic hypomethylation in neoplastic cells from dogs with malignant lymphoproliferative disorders, *Res Vet Sci* 74:101–104, 2003.
25. Modiano JF, Breen M, Burnett RC, et al: Distinct B-cell and T-cell lymphoproliferative disease prevalence among dog breeds indicates heritable risk, *Cancer Res* 65:5654–5661, 2005.
26. Nasir L, Devlin P, McKeivitt T, et al: Telomere lengths and telomerase activity in dog tissues, *Neoplasia* 3(4):351–359, 2001.
27. Carioto LM, Kruth SA, Betts DH, et al: Telomerase activity in clinically normal dogs and dogs with malignant lymphoma, *Am J Vet Res* 62:1442–1446, 2001.
28. Yazawa M, Okuda M, Kanaya N, et al: Molecular cloning of the canine telomerase reverse transcriptase gene and its expression in neoplastic and non-neoplastic cells, *Am J Vet Res* 64:1395–1400, 2003.
29. Milman G, Smith KC, Erles K: Serological detection of Epstein-Barr virus infection in dogs and cats, *Vet Microbiol* 150:15–20, 2011.
30. Farinha P, Gascoyne D: Helicobacter pylori and MALT lymphoma, *Gastroenterology* 128:1579–1605, 2005.
31. Rossi G, Ross M, Vitali CG, et al: A conventional beagle dog model for acute and chronic infection with Helicobacter pylori, *Infect Immun* 67:3112–3120, 1999.
32. Hayes HM, Tarone RE, Cantor KP, et al: Case-control study of canine malignant lymphoma: Positive association with dog owner's use of 2, 4-dichlorophenoxyacetic acid herbicides, *J Natl Cancer Inst* 83:1226–1231, 1991.
33. Carlo GL, Cole P, Miller AB, et al: Review of a study reporting an association between 2, 4-dichlorophenoxyacetic acid and canine malignant lymphoma: report of an expert panel, *Regul Toxicol Pharmacol* 16:245–252, 1992.
34. Garabrant DH, Philbert MA: Review of 2,4-dichlorophenoxyacetic acid (2,4-D) epidemiology and toxicology, *Crit Rev Toxicol* 32:233–257, 2002.
35. Kaneene JB, Miller R: Re-analysis of 2,4-D use and the occurrence of canine malignant lymphoma, *Vet Hum Toxicol* 41:164–170, 1999.
36. Reynolds PM, Reif JS, Ramsdell HS: Canine exposure to herbicide treated lawns and urinary excretion of 2, 4-dichlorophenoxyacetic acid, *Cancer Epidemiol Biomarkers Prev* 3:233–237, 1994.
37. Gavazza A, Presciuttini S, Barale R, et al: Association between canine malignant lymphoma, living in industrial areas, and use of chemicals by dog owners, *J Vet Intern Med* 15:190–195, 2001.
38. Reif JS, Lower KS, Ogilvie GK: Residential exposure to magnetic fields and risk of canine lymphoma, *Am J Epidemiol* 141:352–359, 1995.
39. Marconato L, Leo C, Girelli R, et al: Association between waste management and cancer in companion animals, *J Vet Intern Med* 23:564–569, 2009.
40. Pastor M, Chalvet-Monfray K, Marchal T, et al: Genetic and environmental risk indicators in canine non-Hodgkin's lymphomas: breed associations and geographic distribution of 608 cases diagnosed throughout France over 1 year, *J Vet Intern Med* 23:301–310, 2009.
41. Keller ET: Immune-mediated disease as a risk factor for canine lymphoma, *Cancer* 70:2334–2337, 1992.
42. Foster AP, Sturgess CP, Gould DJ, et al: Pemphigus foliaceus in association with systemic lupus erythematosus and subsequent lymphoma in a cocker spaniel, *J Small Anim Pract* 41:266–270, 2000.
43. Schmiedt CW, Grimes JA, Holzman G, et al: Incidence and risk factors for development of malignant neoplasia after feline renal transplantation and cyclosporine-based immunosuppression, *Vet Comp Oncol* 7:45–53, 2009.
44. Blackwood L, German AJ, Stell AJ, et al: Multicentric lymphoma in a dog after cyclosporine therapy, *J Small Anim Pract* 45:259–262, 2004.
45. Santoro D, Marsella R, Hernandez J: Investigation on the association between atopic dermatitis and the development of mycosis fungoides in dogs: a retrospective case-control study, *Vet Dermatol* 18:101–106, 2007.
46. Madewell BR, Thesen GH: Hematopoietic neoplasms, sarcomas and related conditions. In Theilen GH, Madewell BR, editors: *Veterinary cancer medicine*, ed 2, Philadelphia, 1987, Lea and Febiger.
47. Couto CG, Rutgers HC, Sherding RG, et al: Gastrointestinal lymphoma in 20 dogs: a retrospective study, *J Vet Intern Med* 3:73–78, 1989.
48. Ozaki K, Yamagami T, Nomura K, et al: T-cell lymphoma with eosinophilic infiltration involving the intestinal tract in 11 dogs, *Vet Pathol* 43:339–344, 2006.
49. Breitschwerdt EB, Waltman C, Hagstad HV, et al: Clinical and epidemiological characterization of a diarrheal syndrome in Basenji dog, *J Am Vet Med Assoc* 180:914–920, 1982.
50. Coyle KA, Steinberg H: Characterization of lymphocytes in canine gastrointestinal lymphoma, *Vet Pathol* 41:141–146, 2004.
51. Steinberg H, Dubielzig RR, Thomson J, et al: Primary gastrointestinal lymphosarcoma with epitheliotropism in three Shar-Pei and one Boxer dog, *Vet Pathol* 32:423–426, 1995.
52. Rosenberg MP, Matus RE, Patnaik AK: Prognostic factors in dogs with lymphoma and associated hypercalcemia, *J Vet Intern Med* 5:268–271, 1991.
53. Vail DM, Kisseberth WC, Obradovich JE, et al: Assessment of potential doubling time ( $T_{pot}$ ), argyrophilic nucleolar organizer regions (AgNOR), and proliferating cell nuclear antigen (PCNA) as predictors of therapy response in canine non-Hodgkin's lymphoma, *Experim Hematol* 24:807–815, 1996.
54. Ruslander DA, Gebhard DH, Tompkins MG, et al: Immunophenotypic characterization of canine lymphoproliferative disorders, *In Vivo* 11:169–172, 1997.
55. Gross TL, Ihrke PJ, Walder EJ, et al: Lymphocytic neoplasms. In *Skin diseases of the dog and cat*, ed 2, Oxford, 2005, Blackwell.
56. Fontaine J, Heimann M, Day MJ: Canine cutaneous epitheliotropic T-cell lymphoma: a review of 30 cases, *Vet Dermatol* 21:267–275, 2010.
57. Fontaine J, Bovens C, Bettenay S, et al: Canine cutaneous epitheliotropic T-cell lymphoma: a review, *Vet Comp Oncol* 7:1–14, 2009.
58. Moore PF, Affolter VK, Graham PS, et al: Canine epitheliotropic cutaneous T-cell lymphoma: an investigation of T-cell receptor immunophenotype, lesion topography and molecular clonality, *Vet Dermatol* 20:569–576, 2009.
59. Broder S, Muul L, Marshall S, et al: Neoplasms of immunoregulatory T-cells in clinical investigation, *J Invest Dermatol* 74:267–271, 1980.
60. Moore PF, Olivry T, Naydan D: Canine cutaneous epitheliotropic lymphoma (mycosis fungoides) is a proliferative disorder of CD+8 T-cells, *Am J Pathol* 144:421–429, 1994.
61. Thrall MA, Macy DW, Snyder SP, et al: Cutaneous lymphosarcoma and leukemia in a dog resembling Sézary's syndrome in man, *Vet Pathol* 21:182–186, 1984.
62. Schick RO, Murphy GF, Goldschmidt MH: Cutaneous lymphosarcoma and leukemia in a cat, *J Am Vet Med Assoc* 203:1155–1158, 1993.
63. Foster AP, Evans E, Kerlin RL, et al: Cutaneous T-cell lymphoma with Sézary syndrome in a dog, *Vet Clin Pathol* 26:188–192, 1997.
64. Fry MM, Vernau W, Pesavento PA, et al: Hepatosplenic lymphoma in a dog, *Vet Pathol* 40:556–562, 2003.
65. Cienava EA, Barnhart KF, Brown R, et al: Morphologic, immunohistochemical, and molecular characterization of hepatosplenic T-cell lymphoma in a dog, *Vet Clin Pathol* 33:105–110, 2004.
66. Bush WW, Throop JL, McManus PM, et al: Intravascular lymphoma involving the central and peripheral nervous systems in a dog, *J Am Anim Hosp Assoc* 39:90–96, 2003.



67. Dargent FJ, Fox LE, Anderson WI: Neoplastic angioendotheliomatosis in a dog: an angiotropic lymphoma, *Cornell Vet* 78:253–262, 1988.
68. Summers BA, deLahunta A: Cerebral angioendotheliomatosis in a dog, *Acta Neuropathol* 68:10–14, 1985.
69. Cullen CL, Caswell JL, Grahn BH: Intravascular lymphoma presenting as bilateral panophthalmitis and retinal detachment in a dog, *J Am Anim Hosp Assoc* 36:337–342, 2000.
70. McDonough SP, Van Winkle TJ, Balentine BA, et al: Clinicopathological and immunophenotypic features of canine intravascular lymphoma (malignant angioendotheliomatosis), *J Comp Path* 126:277–288, 2002.
71. Ridge L, Swinney G: Angiotropic intravascular lymphosarcoma presenting as bi-cavity effusion in a dog, *Aust Vet J* 82:616–618, 2004.
72. Hatoya S, Kumagai D, Takeda S, et al: Successful management with CHOP for pulmonary lymphomatoid granulomatosis in a dog, *J Vet Med Sci* 73:527–530, 2011.
73. Berry CR, Moore PF, Thomas WP, et al: Pulmonary lymphomatoid granulomatosis in seven dogs (1976–1987), *J Vet Intern Med* 4:157–166, 1990.
74. Park HM, Hwang DN, Kang BT, et al: Pulmonary lymphomatoid granulomatosis in a dog: Evidence of immunophenotypic diversity and relationship to human pulmonary lymphomatoid granulomatosis and pulmonary Hodgkin's disease, *Vet Pathol* 44:921–923, 2007.
75. Fitzgerald SD, Wolf DC, Carlton WW: Eight cases of canine lymphomatoid granulomatosis, *Vet Pathol* 28:241–245, 1991.
76. National Cancer Institute sponsored study of classifications of non-Hodgkin's lymphomas: summary and description of a working formulation for clinical usage. The Non-Hodgkin's Lymphoma Pathologic Classification Project, *Cancer* 49:2112–2135, 1982.
77. Lennert K, Feller A: *Histopathology of non-Hodgkin's lymphomas (based on the Updated Kiel Classification)*, ed 2, Berlin, 1990, Springer-Verlag.
78. Valli VE, Jacobs RM, Parodi AL, et al: *Histological classification of hematopoietic tumors of domestic animals*, Washington, DC, 2002, Armed Forces Institute of Pathology and The World Health Organization.
79. Sueiro FA, Alessi AC, Vassallo J: Canine lymphomas: a morphological and immunohistochemical study of 55 cases, with observations on p53 immunoreexpression, *J Comp Pathol* 131:207–213, 2004.
80. Vezzali E, Parodi AL, Marcato PS, et al: Histopathological classification of 171 cases of canine and feline non-Hodgkin lymphoma according to the WHO, *Vet Comp Oncol* 8:38–49, 2009.
81. Valli VE, Myint MS, Barthel A, et al: Classification of canine malignant lymphomas according to the World Health Organization criteria, *Vet Pathol* 48:198–211, 2011.
82. Stefanello D, Valenti P, Zini E, et al: Splenic marginal zone lymphoma in 5 dogs (2001–2008), *J Vet Intern Med* 25:90–93, 2011.
83. Valli VE, Vernau W, de Lorimier P, et al: Canine indolent nodular lymphoma, *Vet Pathol* 43:241–256, 2006.
84. Flood-Knapik KE, Durham AC, Gregor TP, et al: Clinical, histopathological, and immunohistochemical characterization of canine indolent lymphoma, *Vet Comp Oncol* 2012. Epub ahead of print.
85. Carter RF, Valli VE, Lumsden JH: The cytology, histology and prevalence of cell types in canine lymphoma classified according to the National Cancer Institute Working Formulation, *Can J Vet Res* 50:154–164, 1986.
86. Teske E, van Heerde P, Rutteman GR, et al: Prognostic factors for treatment of malignant lymphoma in dogs, *J Am Vet Med Assoc* 205:1722–1728, 1994.
87. Ponce F, Magnol JP, Ledieu D, et al: Prognostic significance of morphological subtypes in canine malignant lymphomas during chemotherapy, *Vet J* 167:158–166, 2004.
88. Appelbaum FR, Sale GE, Storb R, et al: Phenotyping of canine lymphoma with monoclonal antibodies directed at cell surface antigens: classification, morphology, clinical presentation and response to chemotherapy, *Hematol Oncol* 2:151–168, 1984.
89. Rosol TJ, Capen CC: Biology of disease: Mechanisms of cancer-induced hypercalcemia, *Lab Invest* 67:680–702, 1992.
90. Weir EC, Greelee P, Matus R, et al: Hypercalcemia in canine lymphosarcoma is associated with the T-cell subtype and with secretion of a PTH-like factor, *J Bone Miner Res* 3:S106 (abstract), 1988.
91. Greenlee PG, Filippa DA, Quimby FW, et al: Lymphoma in dogs: A morphologic, immunologic, and clinical study, *Cancer* 66:480–490, 1990.
92. Fournel-Fleury C, Ponce F, Felman P, et al: Canine T-cell lymphomas: A morphological, immunological and clinical study of 46 new cases, *Vet Pathol* 39:92–109, 2002.
93. Wilkerson MJ, Dolce K, Koopman T, et al: Lineage differentiation of canine lymphoma/leukemias and aberrant expression of CD molecules, *Vet Immunol Immunopathol* 106:179–196, 2005.
94. Rappaport H, Winter WJ, Hicks EB: Follicular lymphoma: A re-evaluation of its position in the scheme of malignant lymphoma, based on a survey of 253 cases, *Cancer* 9:792–821, 1956.
95. Rappaport H: Tumors of the hematopoietic system. In *Atlas of tumor pathology*, Section 3, Fascicle 8. Washington DC, 1966, Armed Forces Institute of Pathology.
96. Day MJ: Immunophenotypic characterization of cutaneous lymphoid neoplasia in the dog and cat, *J Comp Pathol* 112:79–96, 1995.
97. Starrak GS, Berry CR, Page RL, et al: Correlation between thoracic radiographic changes and remission/survival duration in 270 dogs with lymphosarcoma, *Vet Radiol Ultrasound* 38:411–418, 1997.
98. Blackwood L, Sullivan M, Lawson H: Radiographic abnormalities in canine multicentric lymphoma: A review of 84 cases, *J Small Anim Pract* 38:62–69, 1997.
99. Hawkins EG, Morrison WB, DeNicola DB, et al: Cytologic analysis of bronchoalveolar lavage fluid from 47 dogs with multicentric malignant lymphoma, *J Am Vet Med Assoc* 203:1418–1425, 1993.
100. Yohn SE, Hawkins EC, Morrison WB, et al: Confirmation of a pulmonary component of multicentric lymphosarcoma with bronchoalveolar lavage in two dogs, *J Am Vet Med Assoc* 204:97–101, 1994.
101. Leib MS, Bradley RL: Alimentary lymphosarcoma in a dog, *Compend Pract Vet Contin Educ* 9:809–815, 1987.
102. Gieger T: Alimentary lymphoma in cats and dogs, *Vet Clin North Am Small Anim Pract* 41:419–432, 2011.
103. Couto CG, Cullen J, Pedroia V, et al: Central nervous system lymphosarcoma in the dog, *J Am Vet Med Assoc* 184:809–813, 1984.
104. Dallman MJ, Saunders GK: Primary spinal cord lymphosarcoma in a dog, *J Am Vet Med Assoc* 189:1348–1349, 1986.
105. Rosin A: Neurologic diseases associated with lymphosarcoma in ten dogs, *J Am Vet Med Assoc* 181:50–53, 1982.
106. Swanson JF: Ocular manifestations of systemic disease in the dog and cat: recent development, *Vet Clin North Am (Small Anim Pract)* 20:849–867, 1990.
107. Krohne SDG, Vestre WA, Richardson RC, et al: Ocular involvement in canine lymphosarcoma: A retrospective study of 94 cases, *Am College Vet Ophth Proc* 68–84, 1987.
108. Madewell BR, Feldman BF: Characterization of anemias associated with neoplasia in small animals, *J Am Vet Med Assoc* 176:419–425, 1980.
109. Kubota A, Kano R, Mizuno T, et al: Parathyroid hormone-related protein (PTHrP) produced by dog lymphoma cells, *J Vet Med Sci* 64:835–837, 2002.
110. Gerger B, Hauser B, Reusch CE: Serum levels of 25-hydroxycholecalciferol and 1,25-dihydroxycholecalciferol in dogs with hypercalcemia, *Vet Res Commun* 28:669–680, 2004.
111. Massa KL, Gilger BC, Miller TL, et al: Causes of uveitis in dogs: 102 cases (1989–2000), *Vet Ophthalmol* 5:9–98, 2002.

112. Madewell BR: Hematological and bone marrow cytological abnormalities in 75 dogs with malignant lymphoma, *J Am Anim Hosp Assoc* 22:235–240, 1986.
113. Grindem CB, Breitschwadt, EB, Corbett WT, et al: Thrombocytopenia associated with neoplasia in dogs, *J Vet Intern Med* 8:400–405, 1994.
114. MacEwen, EG, Patnaik AK, Wilkins RJ: Diagnosis and treatment of canine hematopoietic neoplasms, *Vet Clin North Am (Small Anim Pract)* 7:105–118, 1977.
115. Lechowski R, Jagielski D, Hoffmann-Jagielska M, et al: Alpha-fetoprotein in canine multicentric lymphoma, *Vet Res Commun* 26:285–296, 2002.
116. Hahn KA, Freeman KP, Barnhill MA, et al: Serum alpha 1-acid glycoprotein concentrations before and after relapse in dogs with lymphoma treated with doxorubicin, *J Am Vet Med Assoc* 214:1023–1025, 1999.
117. Kazmeirski KJ, Ogilvie GK, Fettman MJ, et al: Serum zinc, chromium, and iron concentrations in dogs with lymphoma and osteosarcoma, *J Vet Intern Med* 15:585–588, 2001.
118. Rossmeis JH, Bright P, Tamarkin L, et al: Endostatin concentrations in healthy dogs and dogs with selected neoplasms, *J Vet Intern Med* 16:565–569, 2002.
119. Zizzo N, Patruno R, Zito FA, et al: Vascular endothelial growth factor concentrations from platelets correlate with tumor angiogenesis and grading in a spontaneous canine non-Hodgkin's lymphoma model, *Leuk Lymphoma* 51:291–296, 2010.
120. Marconato L, Crispino G, Finotello R, et al: Clinical relevance of serial determinations of lactate dehydrogenase activity used to predict recurrence in dogs with lymphoma, *J Am Vet Med Assoc* 236:969–974, 2010.
121. Winter JL, Freeman LG, Barber LG, et al: Antioxidant status and biomarkers of oxidative stress in dogs with lymphoma, *J Vet Intern Med* 23:311–316, 2009.
122. Mischke R, Waterston M, Eckersall PD: Changes in C-reactive protein and haptoglobin in dogs with lymphatic neoplasia, *Vet J* 174:188–192, 2007.
123. Sozmen M, Tasca S, Carli E, et al: Use of fine needle aspirates and flow cytometry for the diagnosis, classification, and immunophenotyping of canine lymphomas, *J Vet Diagn Invest* 17:323–330, 2005.
124. Crabtree AC, Spangler E, Beard D, et al: Diagnostic accuracy of gray-scale ultrasonography for the detection of hepatic and splenic lymphoma in dogs, *Vet Radiol Ultrasound* 51:661–664, 2010.
125. Kinns J, Mai W: Association between malignancy and sonographic heterogeneity in canine and feline abdominal lymph nodes, *Vet Radiol Ultrasound* 48:565–569, 2007.
126. Nyman HT, Lee MH, McEvoy FJ, et al: Comparison of B-mode and Doppler ultrasonographic findings with histologic features of benign and malignant superficial lymph nodes in dogs, *Am J Vet Res* 67:978–984, 2006.
127. Miura T, Maruyama H, Sakai M, et al: Endoscopic finding on alimentary lymphoma in 7 dogs, *J Vet Med Sci* 66:577–580, 2004.
128. Fukushima K, Ohno K, Koshino-Goto Y, et al: Sensitivity for the detection of a clonally rearranged antigen receptor gene in endoscopically obtained biopsy specimens from canine alimentary lymphoma, *J Vet Med Sci* 71:1673–1676, 2009.
129. Kaneko N, Yamamoto Y, Wada Y, et al: Application of polymerase chain reaction to analysis of antigen receptor rearrangements to support endoscopic diagnosis of canine alimentary lymphoma, *J Vet Med Sci* 71:555–559, 2009.
130. Kleinschmidt S, Meneses F, Noltel I, et al: Retrospective study on the diagnostic value of full-thickness biopsies from the stomach and intestines of dogs with chronic gastrointestinal disease symptoms, *Vet Pathol* 43:1000–1003, 2006.
131. Affolter VK, Gross TL, Moore PF: Indolent cutaneous T-cell lymphoma presenting as cutaneous lymphocytosis in dogs, *Vet Dermatol* 20:577–585, 2009.
132. Chaubert P, Baur-Chaubert AS, Sattler U, et al: Improved polymerase chain reaction-based method to detect early-stage epitheliotropic T-cell lymphoma (mycosis fungoides) in formalin-fixed, paraffin-embedded skin biopsy specimens of the dog, *J Vet Diagn Invest* 22:20–29, 2010.
133. Vail DM, Kravis LD, Kisseberth WC, et al: Application of rapid CD3 immunophenotype analysis and argyrophilic nucleolar organizer region (AgNOR) frequency to fine needle aspirate specimens from dogs with lymphoma, *Vet Clin Pathol* 26:66–69, 1997.
134. Fisher DJ, Naydan D, Werner LL, et al: Immunophenotyping lymphomas in dogs: A comparison of results from fine needle aspirate and needle biopsy samples, *Vet Clin Pathol* 24:118–123, 1995.
135. Culmsee K, Simon D, Mischke R, et al: Possibilities of flow cytometric analysis for immunophenotypic characterization of canine lymphoma, *J Vet Med A Physiol Pathol Clin Med* 48:199–204, 2001.
136. Comazzi S, Gelain ME: Use of flow cytometric immunophenotyping to refine the cytological diagnosis of canine lymphoma, *Vet J* 188:149–155, 2011.
137. Tasca S, Carli E, Caldin M, et al: Hematologic abnormalities and flow cytometric immunophenotyping results in dogs with hematopoietic neoplasia: 210 cases (2002–2006), *Vet Clin Pathol* 38:2–12, 2009.
138. Gelain ME, Mazzilli M, Riondato F, et al: Aberrant phenotypes and quantitative antigen expression in different subtypes of canine lymphoma by flow cytometry, *Vet Immunol Immunopathol* 121:179–188, 2008.
139. Lana S, Plaza S, Hampe K, et al: Diagnosis of mediastinal masses in dogs by flow cytometry, *J Vet Intern Med* 20:1161–1165, 2006.
140. Gibson D, Aubert I, Woods JP, et al: Flow cytometric immunophenotype of canine lymph node aspirates, *J Vet Intern Med* 18:710–717, 2004.
141. Fournel-Fleury C, Magnol JP, Chabanne L, et al: Growth fractions in canine non-Hodgkin's lymphomas as determined in situ by the expression of the Ki-67 antigen, *J Comp Pathol* 117:61–72, 1997.
142. Phillips BS, Kass PH, Naydan DK, et al: Apoptotic and proliferation indexes in canine lymphoma, *J Vet Diagn Invest* 12:111–117, 2000.
143. Hung LC, Pong VF, Cheng CR, et al: An improved system for quantifying AgNOR and PCNA in canine tumors, *Anticancer Res* 20:3273–3280, 2000.
144. Vajdovich P, Psader R, Toth ZA, et al: Use of the argyrophilic nucleolar region method for cytologic and histologic examination of the lymph nodes in dogs, *Vet Pathol* 41:338–345, 2004.
145. Bauer NB, Zervos D, Moritz A: Argyrophilic nucleolar organizing regions and Ki67 equally reflect proliferation in fine needle aspirates of normal, hyperplastic, inflamed and neoplastic canine lymph nodes (n = 101), *J Vet Intern Med* 21:928–935, 2007.
146. Burnett RC, Vernau W, Modiano JF, et al: Diagnosis of canine lymphoid neoplasia using clonal rearrangements of antigen receptor genes, *Vet Pathol* 40:32–41, 2003.
147. Keller RL, Avery AC, Burnett RC, et al: Detection of neoplastic lymphocytes in peripheral blood of dogs with lymphoma by polymerase chain reaction for antigen receptor gene rearrangement, *Vet Clin Pathol* 33:145–149, 2004.
148. Avery PR, Avery AC: Molecular methods to distinguish reactive and neoplastic lymphocyte expansions and their importance in transitional neoplastic states, *Vet Clin Pathol* 33:196–207, 2004.
149. Drietz MJ, Ogilvie G, Sim GK: Rearranged T lymphocyte antigen receptor genes as markers of malignant T cells, *Vet Immunol Immunopathol* 69:113–119, 1999.
150. Avery A: Molecular diagnostics of hematologic malignancies, *Top Companion Anim Med* 24:144–150, 2009.
151. Kaneko N, Tanimoto T, Morimoto M, et al: Use of formalin-fixed paraffin-embedded tissue and single-strand conformation

- polymorphism analysis for polymerase chain reaction of antigen receptor rearrangements in dogs, *J Vet Med Sci* 71:535–538, 2009.
152. Gentilini F, Calzolari C, Turba ME, et al: Gene scanning analysis of Ig/TCR gene rearrangements to detect clonality in canine lymphomas, *Vet Immunol Immunopathol* 127:47–56, 2009.
  153. Yagihara H, Tamura K, Isotani M, et al: Genomic organization of the T-cell receptor gamma gene and PCR detection of its clonal rearrangement in canine T-cell lymphoma/leukemia, *Vet Immunol Immunopathol* 115:375–382, 2007.
  154. Tamura K, Yagihara H, Isotani M, et al: Development of the polymerase chain reaction assay based on the canine genome database for detection of monoclonality in B cell lymphoma, *Vet Immunol Immunopathol* 110:163–167, 2006.
  155. Fournel-Fleury C, Magnol JP, Bricaire P, et al: Cystohistological and immunological classification of canine malignant lymphomas: comparison with human non-Hodgkin's lymphomas, *J Comp Pathol* 117:35–59, 1997.
  156. Ponce F, Magnol JP, Marchal T, et al: High-grade T-cell lymphoma/leukemia with plasmacytoid morphology: a clinical pathological study of nine cases, *J Vet Diagn Invest* 15:330–337, 2003.
  - 156a. Bergman PJ, Ogilvie GK, Powers BE: Monoclonal antibody C219 immunohistochemistry against P-glycoprotein: sequential analysis and predictive ability in dogs with lymphoma, *J Vet Intern Med* 10:354–359, 1996.
  - 156b. Moore AS, Leveille CT, Reimann KA, et al: The expression of P-glycoprotein in canine lymphoma and its association with multidrug resistance, *Cancer Invest* 13:475–479, 1995.
  157. Ratcliffe L, Mian S, Slater K, et al: Proteomic identification and profiling of canine lymphoma patients, *Vet Comp Oncol* 7:92–105, 2009.
  158. Wilson CR, Regnier FE, Knapp DW, et al: Glycoproteomic profiling of serum peptides in canine lymphoma and transitional cell carcinoma, *Vet Comp Oncol* 6:171–181, 2008.
  159. McCaw DL, Chan AS, Stegner AL, et al: Proteomics of canine lymphoma identifies potential cancer-specific protein markers, *Clin Cancer Res* 13:2496–2503, 2007.
  160. Gaines PJ, Powell TD, Walmsley SJ, et al: Identification of serum biomarkers for canine B-cell lymphoma by use of surface-enhanced laser desorption-ionization time-of-flight spectrometry, *Am J Vet Res* 68:405–410, 2007.
  161. Flory AB, Rassnick KM, Stokol T, et al: Stage migration in dogs with lymphoma, *J Vet Intern Med* 21:1041–1047, 2007.
  162. Raskin RE, Krehbiel JD: Prevalence of leukemic blood and bone marrow in dogs with multicentric lymphoma, *J Am Vet Med Assoc* 194:1427–1429, 1989.
  163. Geyer NE, Reichie JK, Valdes-Martinez A, et al: Radiographic appearance of confirmed pulmonary lymphoma in cats and dogs, *Vet Radiol Ultrasound* 51:386–390, 2010.
  164. Lawrence J, Vanderhoek M, Barbee D, et al: Use of 3'-deoxy-3'-[18F] fluorothymidine PET/CT for evaluating response to cytotoxic chemotherapy in dogs with non-Hodgkin's lymphoma, *Vet Radiol Ultrasound* 50:660–668, 2009.
  165. LeBlanc AK, Jakoby BW, Townsend DW, et al: 18FDG-PET imaging in canine lymphoma and cutaneous mast cell tumor, *Vet Radiol Ultrasound* 50(2):215–223, 2009.
  166. Vail DM, Thamm DH, Tumas DB, et al: Assessment of GS-9219 in a pet dog model of non-Hodgkin's lymphoma, *Clin Cancer Res* 15:3503–3510, 2009.
  167. Yoon J, Feeney DA, Cronk DE, et al: Computed tomographic evaluation of canine and feline mediastinal masses in 14 patients, *Vet Radiol Ultrasound* 45:542–546, 2004.
  168. Bassett CL, Daneil GB, Legendre AM, et al: Characterization of uptake of 2-deoxy-2-[18F] fluoro-D-glucose by fungal-associated inflammation: the standardized uptake value is greater for lesions of blastomycosis than for lymphoma in dogs with naturally occurring disease, *Mol Imaging Biol* 4:201–207, 2002.
  169. Vail DM, Michels GM, Khanna C, et al and the Veterinary Co-operative Oncology Group: Response evaluation criteria for peripheral nodal lymphoma in dogs (v1.0): A Veterinary Co-operative Oncology Group (VCOG) Consensus Document, *Vet Comp Oncol* 8(1):28–37, 2010.
  170. Cotter SM, Goldstein MA: Treatment of lymphoma and leukemia with cyclophosphamide, vincristine, and prednisone: I. Treatment of dog, *J Am Anim Hosp Assoc* 19:159–165, 1983.
  171. Postorino NC, Susaneck SJ, Withrow SJ, et al: Single agent therapy with Adriamycin for canine lymphosarcoma, *J Am Anim Hosp Assoc* 25:221–225, 1989.
  172. Valerius KD, Ogilvie GK, Mallinckrodt CH, et al: Doxorubicin alone or in combination with asparaginase, followed by cyclophosphamide, vincristine, and prednisone for treatment of multicentric lymphoma in dogs: 121 cases (1987–1995), *J Am Vet Med Assoc* 210:512–516, 1997.
  173. Mutsaers AJ, Blickman NW, DeNicola DB, et al: Evaluation of treatment with doxorubicin and piroxicam or doxorubicin alone for multicentric lymphoma in dogs, *J Am Vet Med Assoc* 220:1813–1817, 2002.
  174. MacEwen EG, Brown NO, Patnaik AK, et al: Cyclic combination chemotherapy of canine lymphosarcoma, *J Am Vet Med Assoc* 178:1178–1181, 1981.
  175. MacEwen EG, Hayes AA, Matus RE, et al: Evaluation of some prognostic factors for advanced multicentric lymphosarcoma in the dog: 147 cases (1978–1981), *J Am Vet Med Assoc* 190:564–568, 1987.
  176. Stone MS, Goldstein MA, Cotter SM: Comparison of two protocols for induction of remission in dogs with lymphoma, *J Am Anim Hosp Assoc* 27:315–321, 1991.
  177. Myers NC, Moore AS, Rand WM, et al: Evaluation of a multidrug chemotherapy protocol (ACOPA II) in dogs with lymphoma, *J Vet Intern Med* 11:333–339, 1997.
  178. Boyce KL, Kitchell BE: Treatment of canine lymphoma with COPLA/LVP, *J Am Anim Hosp Assoc* 36:395–403, 2000.
  179. Morrison-Collister KE, Rassnick KM, Northrup NC, et al: A combination chemotherapy protocol with MOPP and CCNU consolidation (Tufts VELCAP-SC) for the treatment of canine lymphoma, *Vet Comp Oncol* 1:180–190, 2003.
  180. Zemann BI, Moore AS, Rand WM, et al: A combination chemotherapy protocol (VELCAP-L) for dogs with lymphoma, *J Vet Intern Med* 12:465–470, 1998.
  181. Keller ET, MacEwen EG, Rosenthal RC: Evaluation of prognostic factors and sequential combination chemotherapy with doxorubicin for canine lymphoma, *J Vet Intern Med* 7:289–295, 1993.
  182. Kaiser CI, Fidel JL, Roos M, et al: Reevaluation of the University of Wisconsin 2-year protocol for treating canine lymphosarcoma, *J Am Anim Hosp Assoc* 43:85–92, 2007.
  183. Simon D, Moreno SN, Hirschberger J, et al: Efficacy of a continuous, multiagent chemotherapeutic protocol versus a short-term single-agent protocol in dogs with lymphoma, *J Am Vet Med Assoc* 232:879–885, 2008.
  184. Sorenmo K, Overley B, Krick E, et al: Outcome and toxicity associated with a dose-intensified, maintenance-free CHOP-based chemotherapy protocol in canine lymphoma: 130 cases, *Vet Comp Oncol* 8:196–208, 2010.
  185. Garrett LD, Thamm DH, Chun R, et al: Evaluation of a 6-month chemotherapy protocol with no maintenance therapy for dogs with lymphoma, *J Vet Intern Med* 16:704–709, 2002.
  186. Daters AT, Mauldin GE, Mauldin GN, et al: Evaluation of a multidrug chemotherapy protocol with mitoxantrone based maintenance (CHOP-MA) for the treatment of canine lymphoma, *Vet Comp Oncol* 8:11–22, 2010.
  187. Rassnick KM, Bailey DB, Malone EK, et al: Comparison between L-CHOP and an L-CHOP protocol with interposed treatments of CCNU and MOPP (L-CHOP-CCNU-MOPP) for lymphoma in dogs, *Vet Comp Oncol* 8:243–253, 2010.
  188. Simon D, Nolte I, Everle N, et al: Treatment of dogs with lymphoma using a 12-week, maintenance-free combination chemotherapy protocol, *J Vet Intern Med* 20:948–954, 2006.



189. Hosoya K, Kisseberth WC, Lord LK, et al: Comparison of COAP and UW-19 protocols for dogs with multicentric lymphoma, *J Vet Intern Med* 21:1355–1363, 2007.
190. Siedlecki CT, Kass PH, Jakubiak MJ, et al: Evaluation of an actinomycin-D-containing combination chemotherapy protocol with extended maintenance therapy for canine lymphoma, *Can Vet J* 47:52–59, 2006.
191. Vail DM: Cytotoxic chemotherapy agents, *Clin Brief* 8(4):18–22, 2010.
192. Tomiyasu H, Takahashi M, Fujino Y, et al: Gastrointestinal and hematologic adverse events after administration of vincristine, cyclophosphamide, and doxorubicin in dogs with lymphoma that underwent a combination multidrug chemotherapy protocol, *J Vet Med Sci* 72:1391–1397, 2010.
193. Mellanby RJ, Herrtage ME, Dobson JM: Owners' assessments of their dog's quality of life during palliative chemotherapy for lymphoma, *J Small Anim Pract* 44:100–103, 2003.
194. Bronden LB, Rutteman GR, Flagstad A, et al: Study of dog and cat owners' perceptions of medical treatment for cancer, *Vet Rec* 152:77–80, 2003.
195. Piek CJ, Rutteman GR, Teske E: Evaluation of the results of a L-asparaginase-based continuous chemotherapy protocol in dogs with malignant lymphoma, *Vet Q* 21:44–49, 1999.
196. Moore AS, Cotter SM, Rand WM, et al: Evaluation of discontinuous treatment protocol (VELCAP-s) for canine lymphoma, *J Vet Intern Med* 15:348–354, 2001.
197. Zenker I, Meichner K, Steinle K, et al: Thirteen-week dose-intensifying simultaneous combination chemotherapy protocol for malignant lymphoma in dogs, *Vet Rec* 167:744–748, 2010.
198. Rassnick KM, McEntee MC, Erb HN, et al: Comparison of 3 protocols for treatment after induction of remission in dogs with lymphoma, *J Vet Intern Med* 21:1364–1373, 2007.
199. Ruslander D, Moore AS, Gliatto JM, et al: Cytosine arabinoside as a single agent for the induction of remission in canine lymphoma, *J Vet Intern Med* 8:299–301, 1994.
200. Rassnick KM, Frimberger AE, Wood CA, et al: Evaluation of ifosfamide for treatment of various canine neoplasms, *J Vet Intern Med* 14:271–276, 2000.
201. Turner AI, Hahn KA, Rusk A, et al: Single agent gemcitabine chemotherapy in dogs with spontaneously occurring lymphoma, *J Vet Intern Med* 20:1384–1388, 2006.
202. MacDonald VS, Thamm DH, Kurzman ID, et al: Does L-asparaginase influence efficacy or toxicity when added to a standard CHOP protocol for dogs with lymphoma? *J Vet Intern Med* 19:732–736, 2005.
203. Jeffreys AB, Knapp DW, Carlton WW, et al: Influence of asparaginase on a combination chemotherapy protocol for canine multicentric lymphoma, *J Am Anim Hosp Assoc* 41:221–226, 2005.
204. Carter RF, Harris CK, Withrow SJ, et al: Chemotherapy of canine lymphoma with histopathological correlation: Doxorubicin alone compared to COP as first treatment regimen, *J Am Anim Hosp Assoc* 23:587–596, 1987.
205. Lon JC, Stein TJ, Thamm DH: Doxorubicin and cyclophosphamide for the treatment of canine lymphoma: a randomized, placebo-controlled study, *Vet Comp Oncol* 8:188–195, 2010.
206. Sauerbrey ML, Mullins MN, Bannink EO, et al: Lomustine and prednisone as a first-line treatment for dogs with multicentric lymphoma: 17 Cases (2004–2005), *J Am Vet Med Assoc* 230:1866–1869, 2007.
207. Khanna C, Lund EM, Redic KA, et al: Randomized controlled trial of doxorubicin versus dactinomycin in a multiagent protocol for treatment of dogs with malignant lymphoma, *J Am Vet Med Assoc* 213:985–990, 1998.
208. Price SG, Page RL, Fischer BM, et al: Efficacy and toxicity of doxorubicin/cyclophosphamide maintenance therapy in dogs with multicentric lymphosarcoma, *J Vet Intern Med* 5:259–262, 1991.
209. Marconato L, Stefanello D, Valenti P, et al: Predictors of long-term survival in dogs with high-grade multicentric lymphoma, *J Am Vet Med Assoc* 238:480–485, 2011.
210. Mealey KL, Fidel JM, Gay JA, et al: ABCB1-1Δ polymorphism can predict hematologic toxicity in dogs treated with vincristine, *J Vet Intern Med* 22:996–1000, 2008.
211. Rebhun RB, Kent MS, Borrofska SA, et al: CHOP chemotherapy for the treatment of canine multicentric T-cell lymphoma, *Vet Comp Oncol* 9:38–44, 2011.
212. Dobson JM, Blackwood LB, McInnes EF, et al: Prognostic variables in canine multicentric lymphosarcoma, *J Small Anim Pract* 42:377–384, 2001.
213. Beaver LM, Strottnner G, Klein MK: Response rate after administration of a single dose of doxorubicin in dogs with B-cell or T-cell lymphoma: 41 cases (2006–2008), *J Am Vet Med Assoc* 237:1052–1055, 2010.
214. Brodsky EM, Mauldin GN, Lachowicz JL, et al: Asparaginase and MOPP treatment of dogs with lymphoma, *J Vet Intern Med* 23:578–584, 2009.
215. Sato M, Yamazaki J, Goto-Koshino Y, et al: Evaluation of cytoreductive efficacy of vincristine, cyclophosphamide, and Doxorubicin in dogs with lymphoma by measuring the number of neoplastic lymphoid cells with real-time polymerase chain reaction, *J Vet Intern Med* 25:285–291, 2011.
216. Sato M, Yamazaki J, Goto-Koshino Y, et al: Increase in minimal residual disease in peripheral blood before clinical relapse in dogs with lymphoma that achieved complete remission after chemotherapy, *J Vet Intern Med* 25:292–296, 2011.
217. Yamazaki J, Takahashi M, Setoguchi A, et al: Monitoring of minimal residual disease (MRD) after multidrug chemotherapy and its correlation to outcome in dogs with lymphoma: a proof-of-concept pilot study, *J Vet Intern Med* 24:897–903, 2010.
218. Thilakarathne DN, Mayer MN, MacDonald VS, et al: Clonality and phenotyping of canine lymphomas before chemotherapy and during remission using polymerase chain reaction (PCR) on lymph node cytologic smears and peripheral blood, *Can Vet J* 51:79–84, 2010.
219. Yamazaki J, Baba K, Goto-Koshino Y, et al: Quantitative assessment of minimal residual disease (MRD) in canine lymphoma by using real-time polymerase chain reaction, *Vet Immunol Immunopathol* 126:321–331, 2008.
220. Von Euler HP, Rivera P, Aronsson AC, et al: Monitoring therapy in canine malignant lymphoma and leukemia with serum thymidine kinase 1 activity—evaluation of a new, fully automated non-radiometric assay, *Int J Oncol* 34:505–510, 2009.
221. Nielsen L, Toft N, Eckersall PD, et al: Serum C-reactive protein concentration as an indicator of remission status in dogs with multicentric lymphoma, *J Vet Intern Med* 21:1231–1236, 2007.
222. Ito D, Endicott MM, Jubala CM, et al: A tumor-related lymphoid progenitor population supports hierarchical tumor organization in canine B-cell lymphoma, *J Vet Intern Med* 25:890–896, 2011.
223. Reference deleted in pages.
224. Reference deleted in pages.
225. Lee JJ, Hughes CS, Fine RL, et al: P-glycoprotein expression in canine lymphoma, *Cancer* 77:1892–1898, 1986.
226. Flory AB, Rassnick KM, Erb HN, et al: Evaluation of factors associated with second remission in dogs with lymphoma undergoing retreatment with a cyclophosphamide, doxorubicin, vincristine and prednisone chemotherapy protocol: 95 cases (2000–2007), *J Am Vet Med Assoc* 238:501–506, 2011.
227. Moore AS, Ogilvie GK, Vail DM: Actinomycin D for reinduction of remission in dogs with resistant lymphoma, *J Vet Intern Med* 8:343–344, 1994.
228. Bannink EO, Sauerbrey ML, Mullins MN, et al: Actinomycin D as rescue therapy in dogs with relapsed or resistant lymphoma: 49 cases (1999–2006), *J Am Vet Med Assoc* 233:446–451, 2008.
229. Griessmayr PB, Payne SE, Winger JE, et al: Dacarbazine as single-agent therapy for relapsed lymphoma in dogs, *J Vet Intern Med* 23:1227–1231, 2009.

230. Dervisis NG, Dominguez PA, Sarbu L, et al: Efficacy of temozolomide or dacarbazine in combination with an anthracycline for rescue chemotherapy in dogs with lymphoma, *J Am Vet Med Assoc* 231:563–569, 2007.
231. Alvarez FJ, Kisseberth WC, Gallant SL, et al: Dexamethasone, melphalan, actinomycin D, cytosine arabinoside (DMAC) protocol for dogs with relapsed lymphoma, *J Vet Intern Med* 20:1178–1183, 2006.
232. Moore AS, London CA, Wood CA, et al: Lomustine (CCNU) for the treatment of resistant lymphoma in dogs, *J Vet Intern Med*, 13:395–398, 1999.
233. Saba CF, Hafeman SD, Vail DM, et al: Combination chemotherapy with continuous L-asparaginase, lomustine and prednisone for relapsed canine lymphoma, *J Vet Intern Med* 23:1058–1063, 2009.
234. Saba CF, Thamm DH, Vail DM: Combination chemotherapy with L-asparaginase, lomustine, and prednisone for relapsed or refractory canine lymphoma, *J Vet Intern Med* 21:127–132, 2007.
235. Flory AB, Rassnick KM, Al-Sarraf R, et al: Combination of CCNU and DTIC chemotherapy for treatment of resistant lymphoma in dogs, *J Vet Intern Med* 22:164–171, 2008.
236. Moore AS, Ogilvie GK, Ruslander D, et al: Evaluation of mitoxantrone for the treatment of lymphoma in dogs, *J Am Vet Med Assoc* 204:1903–1905, 1994.
237. Rassnick KM, Mauldin GE, Al-Sarraf R, et al: MOPP chemotherapy for treatment of resistant lymphoma in dogs: A retrospective study of 117 cases (1989–2000), *J Vet Intern Med* 16:576–580, 2002.
238. Northrup NC, Gieger TL, Kosarek CE, et al: Mechlorethamine, procarbazine and prednisone for the treatment of resistant lymphoma in dogs, *Vet Comp Oncol* 7:38–44, 2009.
239. Fletcher JL, Haber M, Henderson MJ, et al: ABC transporters in cancer: more than just efflux pumps, *Nature Rev Canc* 10:147–156, 2010.
240. Steingold SF, Sharp NJ, McGahan MC, et al: Characterization of canine MDR1 mRNA: its abundance in drug resistant cell lines and in vivo, *Anticancer Res* 18:393–400, 1998.
241. Tomiyasu H, Goto-Koshino Y, Takahashi M, et al: Quantitative analysis of mRNA for 10 different drug resistance factors in dogs with lymphoma, *J Vet Med Sci* 72:1165–1172, 2010.
242. Ogilvie GK, Vail DM, Klein MK, et al: Weekly administration of low-dose doxorubicin for treatment of malignant lymphoma in dogs, *J Am Vet Med Assoc* 198:1762–1764, 1991.
243. Vail DM, Kravis LD, Cooley AJ, et al: Preclinical trial of doxorubicin entrapped in sterically stabilized liposomes in dogs with spontaneously arising malignant tumors, *Cancer Chemother Pharmacol* 39:410–416, 1997.
244. Vail DM, Chun R, Thamm DH, et al: Efficacy of pyridoxine to ameliorate the cutaneous toxicity associated with doxorubicin containing pegylated (stealth) liposomes: a randomized, double-blind clinical trial using a canine model, *Clin Canc Res* 4:1567–1571, 1998.
245. Jubala CM, Wojcieszyn JW, Valli VE, et al: CD20 expression in normal canine B cells and in canine non-Hodgkin's lymphoma, *Vet Pathol* 42:468–476, 2005.
246. Impellizzeri JA, Howell K, McKeever KP, et al: The role of rituximab in the treatment of canine lymphoma: an ex vivo evaluation, *Vet J* 171:556–558, 2006.
247. Stepkowski Z, Jeglum KA, Rosales C, et al: Canine lymphoma-associated antigens defined by murine monoclonal antibodies, *Cancer Immunol Immunother* 24:197–201, 1987.
248. Rosales C, Jeglum KA, Obrocka M, et al: Cytolytic activity of murine anti-dog lymphoma monoclonal antibodies with canine effector cells and complement, *Cell Immunol* 115:420–428, 1988.
249. Stepkowski Z, Rosales C, Jeglum KA, et al: In vivo destruction of canine lymphoma mediated by murine monoclonal antibodies, *In Vivo* 4:231–234, 1990.
250. Crow SE, Theilen GH, Benjaminini E, et al: Chemotherapy for canine lymphosarcoma, *Cancer* 40:2102–2108, 1977.
251. Weller RE, Theilen GH, Madewell BR, et al: Chemotherapy for canine lymphosarcoma: A prospective evaluation of specific and nonspecific immunomodulation, *Am J Vet Res* 41:516–521, 1980.
252. Jeglum KA, Young KM, Barnsley K, et al: Chemotherapy versus chemotherapy with intralymphatic tumor cell vaccine in canine lymphoma, *Cancer* 61:2042–2050, 1988.
253. Peruzzi D, Gavazza A, Mesiti G, et al: A vaccine targeting telomerase enhances survival of dogs affected by B-cell lymphoma, *Mol Ther* 18:1559–1567, 2010.
254. Mason NJ, Coughlin CM, Overley B, et al: RNA-loaded CD40-activated B cells stimulate antigen-specific T-cell responses in dogs with spontaneous lymphoma, *Gene Ther* 15:955–965, 2008.
255. Turek MM, Thamm DH, Mitzey A, et al: hGM-CSF DNA Cationic-lipid complexed autologous tumor cell vaccination in the treatment of canine b-cell multicentric lymphoma, *Vet Comp Oncol* 5(4):219–231, 2007.
256. Brooks MB, Matus RE, Leifer CE, et al: Use of splenectomy in the management of lymphoma in dogs: 16 cases (1976–1985), *J Am Vet Med Assoc* 191:1008–1010, 1987.
257. Meleo KA: The role of radiotherapy in the treatment of lymphoma and thymoma, *Vet Clin North Am (Small Anim Pract)*, 27:115–129, 1997.
258. Williams LE, Johnson JL, Hauck ML, et al: Chemotherapy followed by half-body radiation therapy for canine lymphoma, *J Vet Intern Med* 18:703–709, 2004.
259. Gustavson NR, Lana SE, Mayer MN, et al: A preliminary assessment of whole-body radiotherapy interposed within a chemotherapy protocol for canine lymphoma, *Vet Comp Oncol* 2:125–131, 2004.
260. Lurie DM, Gordon IK, Theon AP, et al: Sequential low-dose rate half-body irradiation and chemotherapy for the treatment of canine multicentric lymphoma, *J Vet Intern Med* 23:1064–1070, 2009.
261. Lurie DM, Kent MS, Fry MM, et al: A toxicity study of low-dose rate half-body irradiation and chemotherapy in dogs with lymphoma, *Vet Comp Oncol* 6:257–267, 2008.
262. Axiak SM, Carreras JK, Hahn KA, et al: Hematologic changes associated with half-body irradiation in dogs with lymphoma, *J Vet Intern Med* 20:1398–1401, 2006.
263. Brown EM, Ruslander DM, Azuma C, et al: A feasibility study of low-dose total body irradiation for relapsed canine lymphoma, *Vet Comp Oncol* 4:75–83, 2006.
264. Gyurkocza B, Rezvani A, Storb RF: Allogeneic hematopoietic cell transplantation: the state of the art, *Expert Rev Hematol* 3:285–299, 2010.
265. Appelbaum FR, Deeg HJ, Storb R, et al: Marrow transplant studies in dogs with malignant lymphoma, *Transplant* 39:499–504, 1985.
266. Escobar C, Grindem C, Neel JA, et al: Hematologic changes after total body irradiation and autologous transplantation of hematopoietic peripheral blood progenitor cells in dogs with lymphoma, *Vet Pathol* 2011. [Epub ahead of print]
267. Frimberger AE, Moore AS, Rassnick KM, et al: A combination chemotherapy protocol with dose intensification and autologous bone marrow transplant (VELCAP-HDC) for canine lymphoma, *J Vet Intern Med* 20:355–364, 2006.
268. Rassnick KM, Moore AS, Collister KE, et al: Efficacy of combination chemotherapy for treatment of gastrointestinal lymphoma in dogs, *J Vet Intern Med* 23:317–322, 2009.
269. Frank JD, Reimer SB, Kass PH, et al: Clinical outcomes of 30 cases (1997–2004) of canine gastrointestinal lymphoma, *J Am Anim Hosp Assoc* 43:313–321, 2007.
270. DeBoer DJ, Turrel JM, Moore PF: Mycosis fungoides in a dog: Demonstration of T-cell specificity and response to radiotherapy, *J Am Anim Hosp Assoc*, 26:566–572, 1990.
271. Risbon RE, de Lorimier LP, Skorupski K, et al: Response of canine cutaneous epitheliotropic lymphoma to lomustine (CCNU):

- a retrospective study of 46 cases (1999-2004), *J Vet Intern Med* 20:1389-1397, 2006.
272. Williams LE, Rassnick KM, Power HT, et al: CCNU in the treatment of canine epitheliotropic lymphoma, *J Vet Intern Med* 20:136-143, 2006.
  273. Couto CG: Cutaneous lymphosarcoma, *Proceed Kal Kan Symp* 11:17-77, 1987.
  274. White SD, Rosychuk RAW, Scott KV, et al: Use of isotretinoin and etretinate for the treatment of benign cutaneous neoplasia and cutaneous lymphoma in dogs, *J Am Vet Med Assoc* 202:387-391, 1993.
  275. Moriello KA, MacEwen EG, Schultz KT: PEG-asparaginase in the treatment of canine epitheliotropic lymphoma and histiocytic proliferative dermatitis. In Ihrke PJ, Mason IS, White SD, editors: *Advances in veterinary dermatology*, New York, 1993, Pergamon Press.
  276. McKeever PJ, Grindem CB, Stevens JB, et al: Canine cutaneous lymphoma, *J Am Vet Med Assoc* 180:531-536, 1982.
  277. Tzannes S, Ibarrola P, Batchelor DJ, et al: Use of recombinant human interferon alpha-2a in the management of a dog with epitheliotropic lymphoma, *J Am Anim Hosp Assoc* 44:276-282, 2008.
  278. Jagielski D, Lechowski R, Hoffmann-Jagielska M, et al: A retrospective study of the incidence and prognostic factors of multicentric lymphoma in dogs (1998-2000), *J Vet Med A Physiol Pathol Clin Med* 49:419, 2002.
  279. Rao S, Lana S, Eickhoff J, et al: Class II major histocompatibility complex expression and cell size independently predict survival in canine B-cell lymphoma, *J Vet Intern Med* 25:1097-1105, 2011.
  280. Williams MJ, Avery AC, Lana SE, et al: Canine lymphoproliferative disease characterized by lymphocytosis: immunophenotypic markers of prognosis, *J Vet Intern Med* 22:596-601, 2008.
  281. Miller AG, Morley PS, Rao S, et al: Anemia is associated with decreased survival time in dogs with lymphoma, *J Vet Intern Med* 23:116-122, 2009.
  282. Abbo AH, Lucroy MD: Assessment of anemia as an independent predictor of response to chemotherapy and survival in dogs with lymphoma: 96 cases (1993-2006), *J Am Vet Med Assoc* 231:1836-1842, 2007.
  283. Kiupel M, Bostock D, Bergmann V: The prognostic significance of AgNOR counts and PCNA-positive cell counts in canine malignant lymphomas, *J Comp Pathol* 119:407-418, 1998.
  284. Larue SM, Fox MH, Ogilvie GK, et al: Tumour cell kinetics as predictors of response in canine lymphoma treated with chemotherapy alone or combined with whole body hyperthermia, *Int J Hyperthermia* 15:475-486, 1999.
  285. Vaughan A, Johnson JL, Williams LE: Impact of chemotherapeutic dose intensity and hematologic toxicity on first remission duration in dogs with lymphoma treated with a chemoradiotherapy protocol, *J Vet Intern Med* 21:1332-1339, 2007.
  286. von Euler H, Einarsson R, Olsson U, et al: Serum thymidine kinase activity in dogs with malignant lymphoma: a potent marker for prognosis and monitoring the disease, *J Vet Intern Med* 18:595-596, 2004.
  287. Gentilini F, Calzolari C, Turba ME, et al: Prognostic value of serum vascular endothelial growth factor (VEGF) and plasma activity of matrix metalloproteinase (MMP) 2 & 9 in lymphoma-affected dogs, *Leukemia Res* 29:1263-1269, 2005.
  288. Hahn KA, Barnhill MA, Freeman KP, et al: Detection and clinical significance of plasma glutathione-S-transferases in dogs with lymphoma, *In Vivo* 13:173-175, 1999.
  289. Weller RE, Holmberg CA, Theilen GH, et al: Canine lymphosarcoma and hypercalcemia: clinical, laboratory and pathologic evaluation of twenty-four cases, *J Small Anim Pract* 23:649-658, 1982.
  290. Cook AK, Wright ZM, Suchodolski JS, et al: Prevalence and prognostic impact of hypocobalaminemia in dogs with lymphoma, *J Am Vet Med Assoc* 235:1437-1441, 2009.
  291. Baskin GR, Couto CG, Wittum TE: Factors influencing first remission and survival in 145 dogs with lymphoma: A retrospective study, *J Am Anim Hosp Assoc* 36:404-409, 2000.
  292. Adam F, Villiers E, Watson S, et al: Clinical pathological and epidemiological assessment of morphologically and immunologically confirmed canine leukaemia, *Vet Comp Oncol* 7:181-195, 2009.
  293. Comazzi S, Gelain ME, Martini V, et al: Immunophenotype predicts survival time in dogs with chronic lymphocytic leukemia, *J Vet Intern Med* 25:100-106, 2011.
  294. Gioia G, Mortarino M, Gelain ME, et al: Immunophenotype-related microRNA expression in canine chronic lymphocytic leukemia, *Vet Immunol Immunopathol* 142:228-235, 2011.
  295. Leifer CE, Matus RE: Chronic lymphocytic leukemia in the dog: 22 cases (1974-1984), *J Am Vet Med Assoc* 189:214-217, 1986.
  296. Workman HC, Vernau W: Chronic lymphocytic leukemia in dogs and cats: the veterinary perspective, *Vet Clin North Am (Small Anim Pract)* 33:1397-1399, 2003.
  297. Kleiter M, Hirt R, Kirtz G, et al: Hypercalcaemia associated with chronic lymphocytic leukaemia in Giant Schnauzer, *Aust Vet J* 79:335-338, 2001.
  298. Matus RE, Leifer CE, MacEwen EG: Acute lymphoblastic leukemia in the dog: A review of 30 cases, *J Am Vet Med Assoc* 183:859-862, 1983.
  299. Adams J, Mellanby RJ, Viliers E, et al: Acute B cell lymphoblastic leukemia in a 12-week-old greyhound, *J Small Anim Pract* 45:553-557, 2004.
  300. Hodgkins EM, Zinkl JG, Madewell BR: Chronic lymphocytic leukemia in the dog, *J Am Vet Med Assoc* 117:704-707, 1980.
  301. Januszewicz E, Cooper IA, Pelkington G, et al: Blastic transformation of chronic lymphocytic leukemia, *Am J Hematol* 15:399-402, 1983.
  302. Harvey JW, Terrell TG, Hyde DM, et al: Well-differentiated lymphocytic leukemia in a dog: long-term survival without therapy, *Vet Pathol* 18:37-47, 1981.

## SECTION B

# Feline Lymphoma and Leukemia

DAVID M. VAIL

## Lymphoma

The lymphomas (malignant lymphoma or lymphosarcoma) are a diverse group of neoplasms that have in common their origin from lymphoreticular cells. They usually arise in lymphoid tissues such as lymph nodes, spleen, and bone marrow; however, they may arise in almost any tissue in the body. Lymphoma is one of the most common neoplasms seen in the cat.

## Incidence

Epidemiologic reports prior to 1990 suggested that lymphoma accounted for 50% to 90% of all hematopoietic tumors in the cat,<sup>1,2</sup> and since hematopoietic tumors (lymphoid and myeloid) represent approximately one-third of all feline tumors, it was estimated lymphoid neoplasia accounted for an incidence of 200 per 100,000 cats at risk.<sup>3</sup> In one series of 400 cats with hematopoietic tumors, 61% had lymphoma and 39% had leukemias and MPDs, of which 21% were categorized as undifferentiated leukemias, most likely myeloid in origin.<sup>4</sup> However, a significant change in the epidemiology and characteristics of lymphoma in cats coincides with the widespread integration of clinically relevant feline leukemia virus (FeLV) diagnostic assays and affected animal elimination regimens of the late 1970s and 1980s and was further enhanced by the commercially



available FeLV vaccines appearing in the late 1980s (see the later section on viral etiology). The decline in FeLV-associated lymphoma was mirrored by a decline in the overall prevalence per year of FeLV positivity in cats tested as characterized by reports, including the Tufts Veterinary Diagnostic Laboratory from 1989 to 1997,<sup>5,6</sup> and by the Louwerens group, who reported a decline in FeLV association in over 500 cases of lymphoma in cats presenting to the University of California at Davis veterinary teaching hospital.<sup>7</sup> In these reports, FeLV antigenicity declined to represent only 14% to 25% of cats presenting with lymphoma. Importantly, Louwerens' study revealed that despite a sharp drop in FeLV-associated lymphoma, the overall prevalence of lymphoma in cats is increasing. The increased prevalence appears due to an increase in the number and relative frequency of the alimentary (and in particular the intestinal) anatomic form of lymphoma in the species. This is supported by an epidemiologic survey of 619 cases of feline intestinal lymphoma; 534 (86%) were from the 20 years following 1985 and only 14% were from cases diagnosed in the 20 years prior to 1985.<sup>8</sup> The true annual incidence rate for lymphoma in cats is currently unknown. With respect to feline pediatric tumors, a study in the United Kingdom (n = 233 pathology specimens) found that 73 (31%) represented hematopoietic tumors, of which 51 (70%) were lymphoma—note that FeLV status was unavailable for this compilation of cases.<sup>9</sup>

The typical signalment for cats with lymphoma cannot be uniformly stated as it varies widely based on anatomic site and FeLV status and therefore will be discussed individually under site-specific discussions. In general, based on two large compilations (n = 700) of cases in North America,<sup>5,7</sup> Siamese cats appear overrepresented and although a 1.5:1 male to female ratio was observed in one, no association with sex or neutering status was observed in the other. In a large compilation of Australian cases, male cats and the Siamese/oriental breeds were overrepresented,<sup>10</sup> and similar breed findings have been observed in North America, although similar sex predilections have not been found. Within the Siamese/oriental breeds, there appears to be a predisposition for a

mediastinal form that is not FeLV associated and represents a younger population (median of 2 years).

## Etiology

### Viral Factors

FeLV was the most common cause of hematopoietic tumors in the cat in the so-called “FeLV era” of the 1960s through the 1980s when approximately two-thirds of lymphoma cases were associated with FeLV antigenemia. Several studies have documented the potential molecular means by which FeLV can result in lymphoid neoplasia (see Chapter 1, Section C). As one would predict, along with a shift away from FeLV-associated tumors came a shift away from traditional signalment and relative frequency of anatomic sites. This is also supported outside of North America by similar signalment and anatomic frequency data observed in Australia where FeLV infection is quite rare.<sup>10,11</sup> The median age of approximately 11 years now reported in North America is considerably higher than the median ages of 4 to 6 years reported in the FeLV era.<sup>1,2,5-7</sup> The median age of cats within various anatomic tumor groupings has not changed, and anatomic forms traditionally associated with FeLV such as the mediastinal form still occur in younger, FeLV antigenemic cats. Similarly, the alimentary form occurs most often in older, FeLV-negative cats. Table 32-8 presents an overview of the characteristics, including FeLV antigenemic status, of the various anatomic sites of lymphoma in cats. As our ability to interrogate FeLV associations on a molecular basis has improved (e.g., PCR amplification and fluorescent in-situ hybridization), several reports exist defining the role or potential role of FeLV in cats with and without FeLV antigenemia.<sup>12-17</sup> Collectively, these studies indicate FeLV proviral insertion exists in a significant proportion of feline lymphoma tissues and is more common in those of T-cell origin, particularly the thymic and peripheral lymph node anatomic forms. They also suggest that several common FeLV integration sites exist.

There is also evidence that feline immunodeficiency virus (FIV) infection can increase the incidence of lymphoma in cats.<sup>18-27</sup> In contrast to the direct role of FeLV in tumorigenesis, most evidence

• TABLE 32-8 General Characteristics of the Most Commonly Encountered Anatomic Forms of Lymphoma in Cats\*

ANATOMIC FORM <sup>†</sup>	RELATIVE FREQUENCY	MEDIAN AGE (YEARS)	FELV ANTIGENEMIC	B-CELL	T-CELL	GENERAL PROGNOSIS
Alimentary/Gastrointestinal <sup>‡</sup>						
Small cell/low grade	Common	13	Rare	Rare	Common	Good
Large cell/intermediate grade	Moderate	10	Rare	Common	Rare	Poor
Nasal	Uncommon	9.5	Rare	Common	Uncommon	Good
Mediastinal	Uncommon	2-4	Common	Uncommon	Common	Poor to fair
Peripheral nodal	Uncommon	7	Uncommon	Moderate	Moderate	Fair to poor
Laryngeal/tracheal	Rare	9	Rare	ID	ID	Good to fair
Renal	Rare	9	Rare	Common	Uncommon	Poor to fair
CNS	Rare	4-10	Rare	ID	ID	Poor
Cutaneous	Rare	10-13	Rare	Rare	Common	Fair
Hepatic (pure)	Rare	12	Rare	Uncommon	Common	Poor

FeLV, Feline leukemia virus; ID, insufficient data; CNS, central nervous system.

Common = >50% of clinical presentations; moderate = 20%-50% of clinical presentations; uncommon = 5%-20% of clinical presentation; rare = <5% of clinical presentations.

\*Data may include overlap or mixing of sites and represents the post-FeLV era.

<sup>†</sup>As the primary site of presentation, rather than extension or progression.

<sup>‡</sup>Includes those reported as “intraabdominal” in which intestinal is a documented component.

points toward an indirect role for FIV secondary to the immunosuppressive effects of the virus. Shelton<sup>18</sup> determined that FIV infection alone in cats was associated with a fivefold increased risk for development of lymphoma. Coinfection with FeLV will further potentiate the development of lymphoproliferative disorders. Experimentally, cats infected with FIV have developed lymphoma in the kidney, alimentary tract, liver, and multicentric sites. FIV-associated lymphoma is more likely that of the B-cell immunophenotype rather than the T-cell predominance associated with FeLV. It has been suggested that FIV infection may be associated more commonly with alimentary lymphoma of B-cell origin,<sup>28,29</sup> and this may be related to chronic dysregulation of the immune system or the activation of oncogenic pathways; however, FIV antigenemia was only rarely associated with alimentary lymphoma in other large compilations of cases.<sup>5,30-33</sup>

### Genetic and Molecular Factors

As discussed earlier in Section A, recent advances in molecular cytogenetics (see Chapter 1, Section A, and Chapter 8), including gene microarray techniques, have and are currently being applied to investigations of chromosomal aberrations in veterinary species with lymphoma. Indeed a predisposition of the oriental cat breeds to develop lymphoma suggests a genetic predisposition and indicates heritable risk.<sup>7,10</sup> Altered oncogene/tumor suppressor gene expression, epigenetic changes, signal transduction, and cell death-pathway alterations are common in lymphomas of humans and are likely also involved in the cat. Several genetic factors have already been discussed as they relate to FeLV associations. Additionally, *N-ras* aberrations have been implicated, although they are rare in cats.<sup>34</sup> Furthermore, telomerase activity (see Chapter 2) has been documented in feline lymphoma tissues.<sup>35,36</sup> Alterations in cellular proliferation and in cell-cycle and death (apoptosis) pathways, in particular the cyclin-dependent kinase cell-cycle regulators and the Bcl-2 family of proapoptotic and antiapoptotic governing molecules, have also been implicated in feline lymphoma.<sup>37-39</sup>

### Environmental Factors

Evidence for exposure to environmental tobacco smoke (ETS) as a risk factor for lymphoma in humans has prompted investigations in cats. In one report, the relative risk of developing lymphoma in cats with any exposure to ETS and with 5 or more years of exposure to ETS was 2.4 and 3.2, respectively.<sup>40</sup> A large European study documenting an association between proximity of waste management and cancer in dogs failed to show increased risk in cats.<sup>41</sup>

### Immunosuppression

Immune system alterations in the cat such as those accompanying FIV infection has been implicated in the development of lymphoma.<sup>18-20,25</sup> As is the case in immunosuppressed human organ transplantation patients, two reports of immunosuppressed feline renal transplant recipients document increased risk of lymphoma following transplant and associated immunosuppressive therapy.<sup>42,43</sup> In both studies, nearly 10% of transplanted cats developed de novo malignant lymphoma.

### Chronic Inflammation

Although definitive proof is lacking, there is a growing body of indirect evidence to suggest that lymphoma can be associated with the presence of chronic inflammation, which theoretically could be the case with intestinal and nasal lymphoma. In particular, an association has been suggested between intestinal lymphoma and inflammatory bowel disease<sup>7,44-46</sup>; however, others have not found

support for this concept.<sup>47</sup> Additionally, an association between gastric *Helicobacter* infection and gastric MALT lymphoma in cats is suggested in one study, and because this is a recognized syndrome in humans, it warrants further investigation.<sup>47a</sup>

### Diet and Intestinal Lymphoma

Although no direct evidence exists, a link between diet and the development of intestinal lymphoma in cats has been suggested.<sup>7</sup> Support is offered by the relative and absolute increase in the alimentary form of lymphoma in the past 20 years and the fact that several dietary modifications in cat food have occurred in a similar timeframe in response to diseases, such as urinary tract disease. Further investigation is warranted to prove or disprove such assertions.

### Pathology and Natural Behavior

Lymphoma can be classified based on anatomic location and histologic and immunophenotypic criteria; often, the two are intimately associated because certain histologic and immunophenotypic types are commonly associated with specific anatomic locations necessitating discussions within the individual anatomic categories that follow. The largest compilation of feline cases subjected to rigorous histologic classification was reported by Valli and others<sup>48</sup> using the NCI WF. WHO has also published a histologic classification system that uses the REAL system as a basis for defining histologic categories of hematopoietic tumors of domestic animals.<sup>49</sup> This system incorporates both histologic criteria and immunohistologic criteria (e.g., B- and T-cell immunophenotype). Regarding anatomic location, as discussed previously, a profound change in presentation, signalment, FeLV antigenemia, immunophenotype, and frequency of anatomic sites has occurred in cats with lymphoma in the “post-FeLV” era (see Table 32-8). Because of this shift, characteristics of feline lymphoma discussed in this chapter will be primarily limited to reports collected from cases presenting after 1995.

Several anatomic classifications exist for lymphoma in the cat, and some categorize the disease as mediastinal, alimentary, multicentric, nodal, leukemic, and individual extranodal forms. Others have combined various nodal and extranodal forms into categories of atypical, unclassified, and mixed, and others have combined intestinal, splenic, hepatic, and mesenteric nodal forms into one category termed *intraabdominal*. Some discrepancies in the discussion of frequency will inevitably result from the variations in classification used in the literature. The relative frequency of anatomic forms and their associated immunophenotype may also vary with geographic distribution and may be related to genetic and FeLV strain differences, as well as prevalence of FeLV vaccine use.

### Alimentary/Gastrointestinal Lymphoma

Alimentary/GI lymphoma can present as a purely intestinal infiltration or a combination of intestinal, mesenteric lymph nodes and liver involvement. The tumors can be solitary but more commonly diffuse throughout the intestines. Some reports limit the alimentary form to GI involvement with or without extension to the liver. Lymphoma is the most common tumor type found in the intestines of cats, representing 55% of cases in an epidemiologic survey of 1129 intestinal tumors in the species.<sup>8</sup> The Siamese breed is reported at increased risk.<sup>7,8</sup> While lymphoma may occur in cats of any age, it is primarily a disease of aged cats with a mean age of approximately 13 years for T-cell alimentary lymphoma and 12 years for B-cell lymphoma.<sup>7,8,50-52</sup> No consistent sex bias is noted. Anatomically, alimentary lymphoma is nearly 4 times more likely to occur in the small intestine than the large intestine.<sup>52</sup> In a series of colonic

neoplasia in cats, lymphoma was the second most common malignancy (41%), second only to adenocarcinoma.<sup>33</sup>

There is some discordance in the literature regarding the histologic type (primarily cell size: small versus large), immunophenotype, and architecture involved with GI lymphoma. While studies (often older or smaller reports) suggest a majority of B-cell immunophenotypes,<sup>5,53</sup> larger, more recent reports<sup>51,54,55</sup> indicate the majority represent mucosal low-grade T-cell immunophenotypes. Conversely, the vast majority of B-cell GI lymphomas in cats are large cells and intermediate or high grade.<sup>51,53</sup> The largest compilation to date (n = 120), by Moore and others,<sup>51</sup> classified GI lymphomas based on immunophenotype, then as either mucosal (infiltrate confined to mucosa and lamina propria with minimal submucosal extension) or transmural (significant extension into submucosa and muscularis propria). They then compared infiltration patterns with the WHO classification scheme,<sup>56</sup> as well as documenting anatomic location, cell size, presence of epitheliotropism, clonality, and outcome data. This information is summarized in Table 32-9. Of the 120 cases, none tested serologically positive for FeLV and only 3 for FIV. Four cats had concurrent large B-cell lymphoma (stomach, cecum, or colon) and small T-cell lymphoma of the small intestine. Topographically, T-cell variants are much more likely to occur in the small intestine (94%) and rarely in the stomach or large intestine. Conversely, B-cell variants were often multiple and often occurred simultaneously within the stomach, small intestine, and ileocecolic junction. The vast majority of T-cell variants were mucosal (equivalent to WHO enteropathy-associated T-cell lymphoma [WHO EATCL] type II), and the vast majority of B-cell tumors were transmural (equivalent to WHO EATCL type I classification). Regarding cell size, nearly all mucosal T-cell tumors were composed of small lymphocytes, and slightly more than half of transmural T-cell and all B-cell variants were composed of larger cells. Epitheliotropism is present in approximately 40% of T-cell tumors but is rare in B-cell tumors. Other abdominal organ involvement is common, and in one report of 29 cases of low-grade T-cell intestinal lymphoma, liver and mesenteric involvement was documented in 53% and 33% of cases, respectively.<sup>57</sup> Hepatic lymphoma can occur concurrently with GI lymphoma or be confined solely to the liver.<sup>52,58</sup> Most are T-cell and clonal or oligoclonal based on PCR analysis.

A less common, distinct form of alimentary lymphoma, large granular lymphoma (LGL), also occurs in older (median age 9 to 10 years) cats.<sup>51,53,59-61</sup> These granulated round cell tumors have been termed *globule leukocyte tumors*, although they are likely variations of the same disease. LGL is characterized by lymphoblasts described as 12 to 20  $\mu\text{m}$  in diameter with a round, clefted, or cerebriform nucleus; variably distinct nucleoli; finely granular to lacey chromatin; and a moderate amount of basophilic granular cytoplasm that was occasionally vacuolated.<sup>59</sup> Prominent magenta or azurophilic granules are characteristic (see Figure 7-34, Chapter 7). They are granzyme B positive by immunohistochemistry.<sup>51</sup> This population of cells includes cytotoxic T-cells and occasionally NK cell immunophenotypes—most are CD3<sup>+</sup>, CD8<sup>+</sup>, and CD20<sup>-</sup> and have T-cell receptor gene rearrangement.<sup>51,60</sup> In one report, nearly 60% expressed CD103 (integrin).<sup>60</sup> Approximately 10% express neither B- or T-cell markers and are thus classified as NK cells. These NK tumors commonly originate in the small intestine, especially the jejunum, are transmural, often exhibit epitheliotropism, and at least two-thirds present with other organs involved—most with mesenteric lymph node involvement and many with liver, spleen, kidney, peritoneal malignant effusions, and bone marrow infiltration. Also, thoracic involvement may occur

with malignant pleural effusion and a mediastinal mass present. Peripheral blood involvement was present in 10% of cases in one report<sup>59</sup> and 86% in another.<sup>60</sup> Affected cats are generally FeLV/FIV negative.

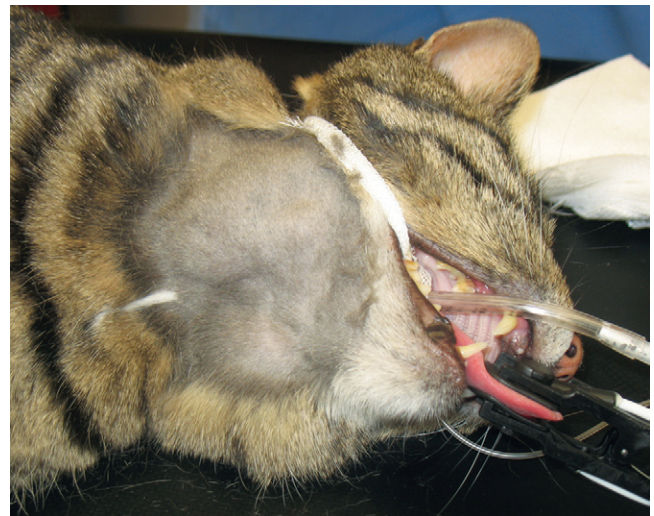
### Mediastinal Form

The mediastinal form can involve the thymus, mediastinal, and sternal lymph nodes. Pleural effusion is common. In two large compilations, 63% of cats with thymic disease and 17% of cats with pleural effusion were documented as having lymphoma.<sup>62,63</sup> Hypercalcemia occurs frequently with mediastinal lymphoma in dogs but is rare in cats. The majority of cats with mediastinal lymphoma are young (median age 2 to 4 years), FeLV positive, and the T-cell immunophenotype.<sup>5,7,9-11</sup> The disease is confined to the mediastinum in most cases.<sup>7</sup> There also exists a form of mediastinal lymphoma occurring primarily in young, FeLV-negative Siamese cats that appears to be less biologically aggressive and more responsive to chemotherapy than FeLV-associated forms.<sup>64</sup>

### Nodal Lymphoma

Involvement limited to peripheral lymph nodes is unusual in cats with lymphoma, representing approximately 4% to 10% of cases.<sup>5,7</sup> In contrast, approximately one-quarter of all other anatomic forms of lymphoma have some component of lymph node involvement. One-third of cats with nodal lymphoma are T-cell immunophenotype and FeLV antigenemic; however, complete categorizations have not occurred in the post-FeLV era and this may no longer be true.<sup>5,7,11,55</sup> Peripheral nodal lymphoma was the most common anatomic form of lymphoma reported in a recent compilation of cases in cats under the age of 1 year, representing a full third of cases in this age group.<sup>9</sup> As lymphoma progresses, bone marrow and hepatic infiltration may develop.

An uncommon and distinct form of nodal lymphoma in cats referred to as “Hodgkin’s-like” lymphoma has been reported.<sup>65,66</sup> This form typically involves solitary or regional nodes of the head and neck (Figure 32-12) and histologically resembles Hodgkin’s lymphoma in humans. Affected cats generally present with enlargement of one or two mandibular or cervical nodes initially, and tumors are immunophenotypically classified as T-cell–rich, B-cell lymphoma. One case each of inguinal node, multicentric nodal, and



• **FIGURE 32-12** A cat presented with mandibular lymphadenopathy that was confirmed to be Hodgkin’s-like lymphoma following histologic assessment.



• **TABLE 32-9** Characteristics of Feline Gastrointestinal Lymphoma

MAJOR CHARACTERISTIC	%*	CELL SIZE	EPITHELIOTROPISM	MEDIAN SURVIVAL	CLONAL OR OLIGOCLONAL	TOPOGRAPHY
<b>T-cell</b>	<b>83%</b>				<b>90%</b>	
Mucosal	81%		62%	29 months	91%	
WHO EATCL type II		Small (95%) Large (5%)		NR		
Transmural	19%		58%	1.5 months	90%	
WHO EATCL type I		Small (42%) Large† 58%		NR		
<b>B-cell</b>	<b>17%</b>				<b>50%‡</b>	
Mucosal	5%	All				
Transmural	95%	Large (100%)	<5%	3.5 months		

Data modified from Moore PF, Rodriguez-Bertos A, Kass PH: Feline gastrointestinal lymphoma: Mucosal architecture, immunophenotype and molecular clonality, *Vet Pathol* April 19, 2011. Epub ahead of print.

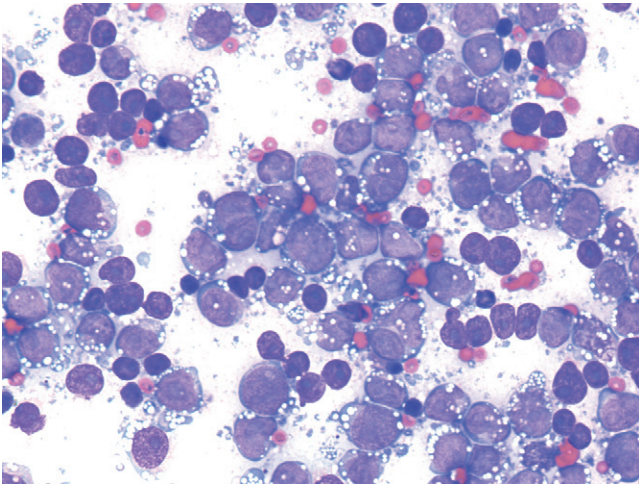
WHO EATCL, World Health Organization enteropathy-associated T-cell lymphoma; NR, not report

Numbers in figures indicate case incidence out of 103 reported cases.

\*3% of cats had both B- and T-cell immunophenotypes within the gastrointestinal tract.

†82% of transmural large T-cell lymphomas are large granular lymphoma subtype.

‡39% pseudo-clonal.



**FIGURE 32-13** Fine-needle aspirate of a lymph node in a cat with Hodgkin's-like lymphoma. The large lymphocytes have prominent nucleoli and smooth basophilic cytoplasm. Several binucleate lymphocytes are present.

conjunctival involvement have been reported.<sup>66,67</sup> Histologically, lymph nodes can be effaced by either nodular or diffuse small to blastic lymphocytes with characteristic bizarre or multinucleated cells (Reed-Sternberg-like cells) (Figure 32-13). No association with FeLV or FIV has been documented.

### Extranodal Lymphoma

The most common extranodal sites for lymphoma in cats include nasal (including nasopharyngeal and sinonasal), kidney, CNS, laryngeal and tracheal, ocular, retrobulbar, and skin.

Nasal lymphoma is the most common extranodal lymphoma in cats.<sup>68</sup> It is usually a localized disease; however, 20% have local extension or distant metastasis at necropsy.<sup>69</sup> The majority of non-viral nasal/paranasal disease in cats are neoplasias, and lymphoma represents nearly one-third to half of these cases.<sup>70-72</sup> It occurs primarily in older (median age 9 to 10 years; range 3 to 17 years) FeLV/FIV-negative cats and at least three-quarters are B-cell in origin, although T-cell and mixed B-cell/T-cell immunophenotypes can be seen in approximately 10% to 15% of cases.<sup>5,68,69,73</sup> Siamese cats appear overrepresented, and one report<sup>73</sup> observed a 2:1 male-to-female ratio. Most are of intermediate- or high-grade histology.<sup>69,73</sup> Epitheliotropism is common if the epithelium is present in the biopsy.

Renal lymphoma is the second most common form of extranodal lymphoma after the nasal form, occurring in approximately one-third of cases.<sup>68</sup> It can present as primary to kidney lymphoma or occur concurrent with alimentary lymphoma. In more contemporary reports, the median age at presentation is 9 years, although 6% occurred in cats under 1 year of age.<sup>68,69</sup> The vast majority of cases are not associated with either FeLV or FIV. The greater median age and lack of FeLV/FIV association are in contrast to reports compiled prior to the post-FeLV era; in earlier studies, the median age was approximately 7.5 years, 25% of cases were FeLV antigenemic, and the majority constituted a B-cell immunophenotype. Little contemporary information exists on the immunohistologic classification of renal lymphoma; however, in Australia where FeLV is not a significant problem, most renal lymphoma is B-cell and intermediate to high grade.<sup>11</sup> Extension to the CNS is a

frequent sequela to renal lymphoma and occurs in 40% to 50% of treated cats.<sup>74</sup>

CNS lymphoma can be intracranial, spinal, or both. CNS lymphoma made up 14% of 110 reported cases of extranodal lymphoma,<sup>68</sup> 15% to 31% of intracranial tumors,<sup>75,76</sup> and 39% of spinal cord tumors,<sup>77</sup> making it one of the most common malignancies encountered in the CNS in cats. Although some discordance exists in the literature, cats with CNS lymphoma are younger (median ages of 4 to 10.5 years reported), and 17% to 50% of cases are FeLV antigenemic.<sup>76-78</sup> Approximately two-thirds of intracranial cases are part of a multicentric, extracranial process, and approximately 40% of spinal lymphoma cases occur in multiple spinal cord sites with one-third also involving intracranial locations.<sup>76-78</sup> In a compilation of 160 cases of intracranial tumors in cats, diffuse cerebral and diffuse brainstem involvement was most common for lymphoid malignancies.<sup>76</sup> Spinal lesions are usually both extradural and intradural, although they can be limited to one or the other compartment.<sup>77</sup> Feline CNS lymphoma may be primary but more commonly (approximately 80%) represents a multicentric process (especially renal or bone marrow).<sup>76,78</sup> A paucity of information exists on the immunophenotype of CNS lymphoma.

Laryngeal lymphoma made up 10% of 110 cases of extranodal forms in one report and represented 11% of all laryngeal disease in the species.<sup>68,79</sup> It occurs in older cats (median age 9 years), is not associated with FeLV, and may be a solitary lesion or occur in the presence of other multicentric sites. No information on immunophenotype is available.

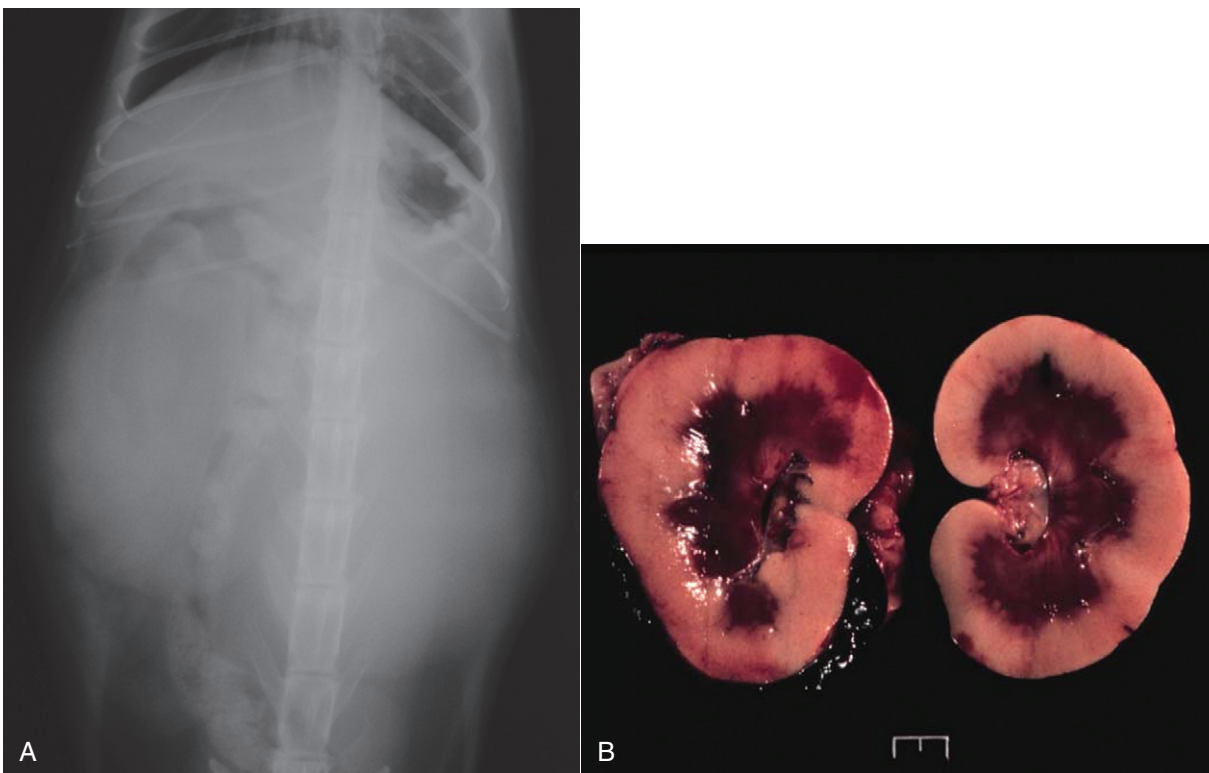
Cutaneous lymphoma is a rarely encountered anatomic form in the cat. It is usually seen in older cats (median age 10 to 13.5 years), with no sex or breed predominance, and is not associated with FeLV/FIV.<sup>80,81</sup> It can be solitary or generalized, often affecting the head and face and is generally a slow chronic disease. Two forms of cutaneous lymphoma have been distinguished histologically and immunohistochemically. Most reports in the cat are epitheliotropic and consist of T-cells, although unlike the disease in dogs, adnexal structures are often spared. A report of nonepitheliotropic cutaneous lymphoma in cats also found five of six cases to be of T-cell derivation.<sup>82</sup> Cutaneous "lymphocytosis," an uncommon disease histologically resembling well-differentiated lymphoma, was characterized in 23 cats.<sup>83</sup> Solitary lesions were most common, and all were composed primarily of T-cells, with two-thirds having some B-cell aggregates. Cutaneous lymphocytosis was characterized as a slowly progressive disorder; however, a few cases went on to develop internal organ infiltration. Two case reports exist of cats with cutaneous T-cell lymphoma and circulating atypical lymphocytes.<sup>84,85</sup> The circulating cells were lymphocytes with large, hyperchromatic, grooved nuclei, and one case was immunophenotyped as a CD3/CD8 population. In humans, cutaneous T-cell lymphoma with circulating malignant cells is termed *Sézary syndrome*.

Ocular lymphoma was identified in 5 of 110 cases of extranodal lymphoma in one report.<sup>68</sup> In a compilation of 75 cases of intraocular tumors, 15 (20%) were lymphoma (7 B-cell and 4 T-cell).<sup>86</sup> It was presumed but not proved that the majority were part of a systemic multicentric process.

### History, Clinical Signs, and Physical Examination Findings

The clinical signs associated with feline lymphoma are variable and depend on anatomic location and extent of disease.

The alimentary form is most commonly associated with non-specific signs associated with the intestinal tract. In the more



**FIGURE 32-14** **A**, Ventrodorsal projection of a cat with renal lymphoma. Massive, bilateral renomegaly is observed. **B**, Necropsy specimens of a cat with bilateral renal lymphoma illustrating the diffuse cortical nature of the disease that is most common.

common low-grade small cell forms, weight loss (83% to 100%), vomiting and/or diarrhea (73% to 88%), and anorexia (66%) are the most common findings, and icterus is uncommon (7%).<sup>50,52,87</sup> Abdominal palpation is abnormal in approximately 70% of cases, with half consisting of intestinal wall thickening and one-third having a palpable mass. Clinical signs are usually present for several months (median: 6 months).<sup>87</sup> In contrast, although the lymphoblastic high-grade forms tend to cause similar clinical signs, they progress more rapidly with signs present for days or weeks and are more likely to present with a palpable abdominal mass originating from the GI tract, enlarged mesenteric lymph nodes, or liver.<sup>31,50,88</sup> Icterus is also more common in large cell forms. Hematochezia and tenesmus may also be present if the colon is involved.<sup>33</sup> Rarely, cats may present with signs consistent with an acute abdomen due to intestinal obstruction or perforation and concurrent peritonitis. Cats with intestinal LGL are presented with anorexia, weight loss, lethargy, and vomiting.<sup>59,60</sup> A palpable abdominal mass is present in approximately half of LGL cases, and hepatomegaly, splenomegaly, and renomegaly are common. Abdominal effusions, pleural effusions, and icterus are observed in less than 10% of cases.

The clinical signs associated with the mediastinal form of lymphoma include dyspnea, tachypnea, and a noncompressible anterior mediastinum with dull heart and lung sounds.<sup>89</sup> Rarely, a Horner's syndrome and precaval syndrome may be observed. Pleural effusion is common and characterized by serohemorrhagic to chylous effusion, and in most cases, neoplastic cells (lymphoblasts) are identified.<sup>63,90</sup>

Cats with the nodal form of lymphoma present with variable clinical signs depending on the extent of disease; however, they are often depressed and lethargic. Peripheral lymphadenopathy, as the only physical finding, is an uncommon presentation. Cats with

Hodgkin's-like nodal lymphoma usually present without overt clinical signs.<sup>65,66</sup>

Cats with nasal lymphoma are typically presented with nasal discharge (60% to 85%), sneezing (20% to 70%), upper respiratory noise (stridor, stertor, wheezing; 20% to 60%), facial deformity (0% to 20%), anorexia (10% to 60%), epiphora (10% to 30%), and occasionally increased respiratory effort and coughing.<sup>68,69,73</sup> The nasal discharge is usually mucopurulent, although epistaxis is present in up to one-third of cases. Regional lymphadenopathy can also occur. The median duration of clinical signs prior to diagnosis is 2 months (range of 1 to 1800 days).

Cats with renal lymphoma present with signs consistent with renal insufficiency: inappetence, weight loss, and polyuria/polydipsia.<sup>68,74</sup> On physical examination, renomegaly (usually bilateral, lumpy, and irregular) is palpated in the majority of cases (Figure 32-14).

Cats with CNS lymphoma can present with constitutional signs (anorexia, lethargy) and signs referring to intracranial lesions, spinal lesions, or both.<sup>68,75-77,91,92</sup> Intracranial signs may include ataxia, altered consciousness, aggression, central blindness, and vestibular abnormalities. In a study of cats with seizures, of those diagnosed with intracranial lesions, 8% were due to lymphoma.<sup>75</sup> Clinical signs referring to spinal cord involvement may include paresis or paraplegia (>80%; tetraparesis in 20%), ataxia, pain, and constipation, and nonspecific constitutional signs (e.g., anorexia, lethargy, weight loss) are also common.<sup>77,92</sup> In cats with spinal cord involvement, neurologic examination may further reveal tetraparesis, lower or upper motor neuron bladder, tail flaccidity, and absent deep pain; approximately one-third of signs will be asymmetric and most refer to thoracolumbar involvement. The neurologic dysfunction may be insidious or progress rapidly.



Signs associated with laryngeal lymphoma in cats most commonly include dyspnea, dysphonia, stridor, gagging or retching, and rarely, coughing.<sup>68,79</sup>

Cutaneous lymphoma may be solitary or diffuse with a varied presentation.<sup>80,83</sup> In decreasing order of likelihood, lesions may include erythematous patches, alopecia, scaling, dermal nodules, or ulcerative plaques. Nasal hypopigmentation, miliary dermatitis, and mucosal lesions are rarely observed. Peripheral lymphadenopathy may also be present. In most cats, the duration of signs will be prolonged, lasting several months.

Cats with ocular lymphoma are presented with uveitis or iridial masses, as well as signs related to systemic involvement of disease.<sup>68</sup>

### Nonspecific Signs

All cats with lymphoma, regardless of site, may be presented with nonspecific constitutional signs that may include anorexia, weight loss, lethargy, or depression. Secondary bone marrow infiltration may lead to anemia—at least 50% of affected cats have moderate-to-severe nonregenerative anemia. Signs related to paraneoplastic hypercalcemia (PU/PD) can occur in cats, however, much less commonly than in the dog. In one survey of hypercalcemia in cats, approximately 10% were diagnosed with lymphoma of various anatomic types.<sup>93</sup>

## Diagnosis and Clinical Staging

For most cats with suspect lymphoma, the diagnostic evaluation should include a baseline assessment consisting of a CBC with differential cell count, platelet count, serum chemistry profile, urinalysis, and retroviral (FeLV/FIV) screen. Serum chemistry profiles can help establish the overall health of the animal, as well as, in some cases, suggest site-specific tumor involvement; for example, increased activities of liver enzymes may indicate hepatic infiltration and increased blood urea nitrogen (BUN) and creatinine may indicate renal lymphoma. For cats with alimentary lymphoma, hypoproteinemia and anemia are reported to occur in up to 23% and 76% of cases, respectively.<sup>31,52,94</sup> Hypercalcemia is rarely seen in cats but has been reported in cats with lymphoma at various anatomic sites. Hypoglycemia was reported in approximately one-third of cats with lymphoma in one Australian study.<sup>94</sup> In a series of cats with various anatomic forms of lymphoma, serum albumin concentrations were significantly lower and  $\beta$ -globulin concentrations (as measured by protein electrophoresis) were significantly higher than a healthy control population.<sup>95</sup>

The use of various imaging modalities in cats with lymphoma depends on the anatomic site and will be discussed in site-specific discussions to follow.

Cytopathologic or histopathologic evaluation of lymph node or involved organ tissue, procured via needle aspirate cytology (see Chapter 7), surgical, endoscopic, or needle-core biopsy (see Chapter 9) is required for a definitive diagnosis. FNA cytology alone may not be sufficient in some cases, owing to difficulties encountered in distinguishing lymphoma from benign hyperplastic or reactive lymphoid conditions. In such cases, whole lymph node excision and/or involved organ biopsy is preferred because orientation and information regarding invasiveness and architectural abnormalities may be necessary for diagnosis. Additionally, involved tissue, needle aspirate, and fluid samples can be further interrogated by various histochemical, immunohistochemical, flow cytometric analysis (e.g., size and immunophenotypic assessment), and molecular techniques (e.g., PARR to assess clonality) to further characterize the disease process and refine the diagnosis in equivocal cases.

The reader is referred to Chapter 8 for a general discussion of flow cytometric analysis and molecular diagnostic techniques, as well as the molecular diagnostic techniques section in Section A of this chapter for specific applications to lymphoma. PARR applications in cats have been described as being approximately 80% sensitive for the diagnosis of feline lymphoma<sup>96</sup>; however, assessment of specificity has not been clearly established. Clonality assessment tools (e.g., primers) for both Ig and T-cell receptor variable region genes have been developed in cats.<sup>97-100</sup>

Assessments of tumor proliferation rates (e.g., Ki67, PCNA, AgNOR), telomerase activity, and serum protein electrophoresis can also be performed on involved tissues in cats; however, consistent prognostic value across the anatomic, histopathologic, and immunophenotypic variants of lymphoma in cats is not well characterized. If these ancillary assays are helpful with respect to prognosis or diagnosis, they will be discussed in site-specific discussions to follow.

Thorough staging, including a bone marrow aspiration or biopsy, peripheral lymph node assessment (clinically normal or abnormal nodes), and thoracic and/or abdominal imaging, is indicated when (1) solitary site disease is suspected (in particular, extranodal sites) and a decision between locoregional therapy (i.e., surgery and/or RT) versus systemic therapy (i.e., chemotherapy) is being considered; (2) it provides prognostic information that will help a caregiver make treatment decisions; and (3) complete staging of the extent of disease is required as part of a clinical trial. Bone marrow evaluation may be of particular interest if anemia, cellular atypia, and leukopenia are present. A WHO staging system exists for the cat that is similar to that used in the dog (see Box 32-1); however, because of the high incidence of visceral/extranodal involvement in the feline species, a separate staging system has been evaluated and is often used (Box 32-3).<sup>101</sup> Because lymphoma in cats is more varied with respect to anatomic locations, staging systems are generally less helpful for predicting response.

### Anatomic Site-Specific Diagnostics

**Alimentary/Gastrointestinal Lymphoma** The diagnosis of large cell, high-grade alimentary/GI lymphoma is generally less complicated than for the more common low-grade GI type. The former (including LGL) is often diagnosed with physical examination, abdominal imaging (e.g., ultrasound), and cytologic or histologic assessment of needle aspirate or needle biopsy samples from intestinal masses, enlarged mesenteric lymph nodes, or liver because mass lesions and gross lymphadenopathy are more commonly present. If obvious abdominal masses are present on physical examination, transabdominal needle aspiration may be possible without the aid of abdominal imaging. Less commonly, abdominal exploration is necessary if lesions are more subtle or not amenable to transabdominal sampling. Further staging via thoracic imaging, peripheral lymph node aspiration, and bone marrow assessment may be performed, but rarely contributes prognostic information or alters treatment decisions because the disease is already widespread and systemic therapy is required.

In contrast, low-grade, small cell GI lymphoma is more commonly associated with modest (or palpably absent) intestinal thickening without mass effect and is clinically similar if not identical in presentation to benign inflammatory bowel disease (IBD). Cytologic assessment alone is often not sufficient for diagnosis; in one study, eight of nine cases in which mesenteric lymph nodes were confirmed histologically as lymphoma, cytologic assessment incorrectly indicated benign lymphoid hyperplasia.<sup>52</sup> The key elements necessary for the diagnosis of low-grade, small cell GI lymphoma

### Box 32-3 Clinical Staging System for Feline Lymphoma

#### Stage 1

- A single tumor (extranodal) or single anatomic area (nodal)
- Includes primary intrathoracic tumors

#### Stage 2

- A single tumor (extranodal) with regional lymph node involvement
- Two or more nodal areas on the same side of the diaphragm
- Two single (extranodal) tumors with or without regional lymph node involvement on the same side of the diaphragm
- A resectable primary gastrointestinal tract tumor, usually in the ileocecal area, with or without involvement of associated mesenteric nodes only

#### Stage 3

- Two single tumors (extranodal) on opposite sides of the diaphragm
- Two or more nodal areas above and below the diaphragm
- All extensive primary unresectable intraabdominal disease
- All paraspinal or epidural tumors, regardless of other tumor site or sites

#### Stage 4

- Stages 1-3 with liver and/or spleen involvement

#### Stage 5

- Stages 1-4 with initial involvement of CNS or bone marrow or both

Data from Terry A, Callanan JJ, Fulton R, et al: Molecular analysis of tumours from feline immunodeficiency virus (FIV)-infected cats: An indirect role for FIV, *Int J Cancer* 61:227–232, 1995.

(and differentiation from IBD) include abdominal imaging (usually ultrasound), procurement of tissue for histopathology, and if necessary, assessment of immunophenotype and clonality.

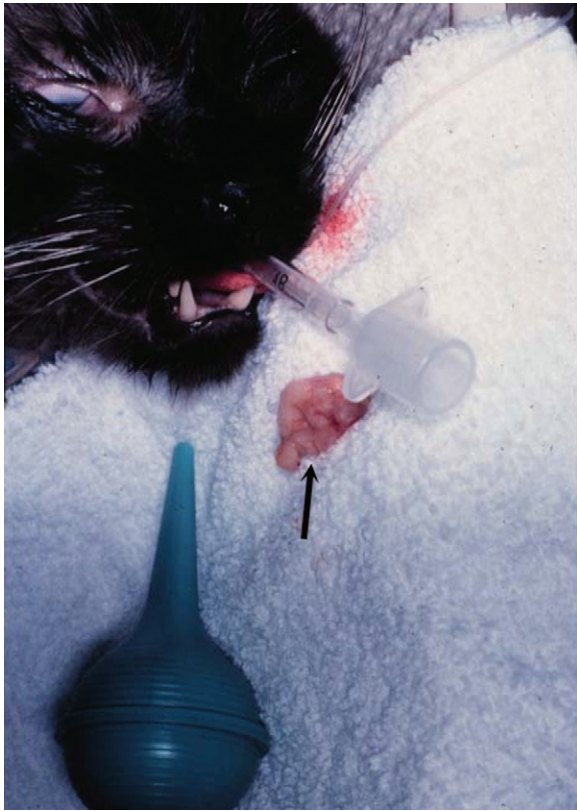
Abdominal ultrasound will be abnormal in approximately 60% to 90% of cats with low-grade, small cell GI lymphoma.<sup>31,52,102,103</sup> Diffuse small intestinal wall thickening is the most common finding; 50% to 70% of cats with lymphoma will have ultrasonic evidence of wall thickening, which predominantly involves the muscularis propria, and submucosa, although mucosal thickening can also occur. Focal mural masses are uncommon. Mesenteric lymphadenopathy is also common and reported in 45% to 80% of affected cats. These ultrasonographic findings are by no means pathognomonic for lymphoma, however, because 10% to 50% and 15% to 20% of cats with IBD also have ultrasonographic evidence of intestinal wall thickening and lymphadenopathy, respectively.<sup>102,103</sup> Mucosal thickening is more common, and muscularis propria thickening is less common in IBD than lymphoma. Less commonly, cats with low-grade intestinal lymphoma will have ultrasonographic abnormalities in other abdominal organs such as

the stomach, liver, spleen, colon, and pancreas, and occasionally, mild effusions are observed.

As mentioned previously, although aspirate cytology may be sufficient for diagnosis of large cell intermediate- or high-grade alimentary lymphoma in cats, it is rarely diagnostic for low-grade, small cell intestinal lymphoma, and tissue procurement for histologic and ancillary assessment is required for diagnosis (and differentiation from IBD). The debate still rages as to whether endoscopically obtained tissue is sufficient for diagnosis or if full-thickness tissue procured during laparotomy or laparoscopy is necessary in light of similarities with IBD.<sup>51,54,103,104</sup> As previously discussed, histologic features that help differentiate intestinal lymphoma from IBD include lymphoid infiltration of the intestinal wall beyond the mucosa, epitheliotropism (especially intraepithelial nests and plaques), heterogeneity, and nuclear size of lymphocytes.<sup>51,54</sup> Although the presence of transmural involvement is highly suggestive of lymphoma, the lack of transmural infiltration is not pathognomonic for IBD; transmural infiltration is common with B-cell and large T-cell (including LGL) intestinal lymphoma but is observed in the minority of low-grade T-cell intestinal lymphomas that represent the largest group in cats (see Table 32-9).<sup>51</sup> For these reasons, if the differentiation of lymphoma and IBD is equivocal after standard histopathologic assessment, the addition of immunophenotypic and PARR analysis in a stepwise fashion, as proposed by Kiupel and others,<sup>54</sup> may be ultimately necessary for a definitive diagnosis. Their study of 63 cats with either lymphoma or IBD found that, although standard histopathology was highly specific for diagnosis of lymphoma (99% specific, 72% sensitive), sensitivity was enhanced by the addition of immunophenotypic analysis (99% specific, 78% sensitive) and further enhanced by PARR analysis (99% specific, 83% sensitive).

**Mediastinal Lymphoma** For cats with mediastinal lymphoma, diagnostic suspicion may begin with a noncompressible cranial thorax on physical examination and confirmation of a mediastinal mass/pleural effusion on thoracic radiograph. FNA of the mass or cytologic evaluation of pleural fluid may be sufficient to establish a diagnosis. In most cats, the finding of a monotonous population of intermediate- or high-grade cells will establish a diagnosis. However, definitive diagnosis of lymphoma in cats with a mediastinal mass and concurrent chylothorax can be challenging. CT appearance may be helpful but generally does not contribute to a definitive diagnosis. If lymphoblasts are not identified in the pleural chylous effusion, then cholesterol and triglyceride concentrations can be measured.<sup>105</sup> In chylous effusions, the pleural fluid triglyceride concentration will be greater than in the serum; however, anorectic cats will have lower triglyceride levels in the pleural fluid. A major differential for mediastinal lymphoma is thymoma. The cytologic features of thymoma can be distinct from lymphoma in many cases, but the diagnosis can be challenging because of a preponderance of small lymphocytes in thymoma. Mast cells can also be seen in up to 50% of aspirations from thymomas. The addition of immunophenotypic and clonality assessment may be helpful in equivocal cases.

**Nasal Lymphoma** If nasal lymphoma is suspected, advanced imaging (CT, MRI), rhinoscopy, and biopsy are usually necessary for diagnosis (see Chapter 23, Section B). CT or MRI is useful to determine the extent of involvement and to help plan biopsy procurement and RT if that treatment option is pursued. CT characteristics associated with sinonasal tumors in cats include the presence of a unilateral or bilateral nasal/sinus mass or fluid, bulla



• **FIGURE 32-15** Flush biopsy of nasal lymphoma. Note the large sample (*arrow*) procured by retrograde flushing of saline through one nares while occluding the contralateral nares. The sample is flushed through the pharynx and out the mouth.

effusion, and lysis of associated bony structures.<sup>106,107</sup> A biopsy can be procured either by intranasal procurement (with or without rhinoscopy) or by flushing one hemicavity with a bulb syringe and saline while occluding the contralateral cavity and collecting samples flushed out of the nasopharynx (Figure 32-15). Thorough staging (i.e., regional node assessment, thoracic and abdominal staging, and bone marrow assessment) to ensure the disease is confined to the nasal passages is recommended, if local RT without systemic chemotherapy is being considered.

**Renal Lymphoma** In the case of renal lymphoma, physical examination findings of massive and often bilateral renomegaly will raise the index of suspicion. Radiographic appearance is smooth-to-irregular renomegaly (see Figure 32-14, A). Ultrasonographic imaging usually reveals bilateral (>80%), irregular renomegaly with hypoechoic subcapsular thickening.<sup>108</sup> Approximately one-third of cases will have ultrasonographic evidence of other abdominal organ involvement. The disease is usually diffuse throughout the renal cortex (see Figure 32-14, B) and transabdominal needle aspirate or core biopsy is diagnostic in most cases.

**Central Nervous System Lymphoma** In cats with suspected spinal lymphoma, survey radiographs of the spine will rarely reveal osseous lesions. Myelograms, CT, or MRI are indicated, and in approximately 75% of the cases, an extradural or intradural mass will be detected.<sup>76,77,91,92</sup> Most lesions occur at a thoracolumbar or lumbosacral location, and they are often found in more than one location. Image-guided needle aspiration of epidural lesions may

yield enough tissue for a cytologic diagnosis. CT or MR also reveals multifocal disease in the majority of cats with intracranial lymphoma.<sup>75,76</sup> CSF analysis may be helpful but is rarely definitive for lymphoma. One of 11 cats with confirmed spinal lymphoma in one study<sup>77</sup> and 6 of 17 with confirmed intracranial lymphoma in another<sup>76</sup> had evidence of lymphoblasts in the CNS, and an increased protein content was commonly found. In cats suspected of CNS lymphoma, bone marrow and renal involvement are often present, and cytologic assessment of these or other more accessible organs is generally more easily attainable than from spinal sites.

For cats suspected of cutaneous lymphoma, punch biopsies (4 to 8 mm) should be taken from the most representative and infiltrative sites, while avoiding overtly infected skin lesions. Immunophenotypic and PARR analysis often are helpful in definitive diagnosis. Complete staging to rule out systemic disease is also recommended for cats with cutaneous lymphoma because local therapies can be applied in cases of solitary disease.

## Treatment and Prognosis

Our knowledge base for treating cats with lymphoma is less well established, and outcomes are less predictable than that in dogs, primarily due to the greater variation in histologic type and anatomic location observed in the species. This is further complicated by the plethora of papers that “lump” very small numbers of cases representing multiple anatomic/immunophenotypic and histologic subtypes (e.g., small cell versus large cell variants) together when reporting survival analysis following chemotherapy. This provides only general observations rather than important specific outcome information (i.e., response rate and durability of response) that can vary significantly with respect to anatomic and histologic subtype. In general, canine lymphoma is most commonly intermediate-high grade and nodal, whereas cats more commonly present with GI or extranodal (±nodal extension), small cell, low-grade, and/or indolent forms. As will be discussed subsequently, the author bases most treatment decisions on assessment of whether the individual case represents a low-grade (e.g., indolent, small cell variants) versus an intermediate- or high-grade (e.g., large cell) lymphoma. Finally, much of the early work on chemotherapy protocol development for cats with lymphoma occurred during the FeLV era, and care should be exercised when applying this information in the post-FeLV era.

In general, cats tolerate chemotherapy for lymphoma quite well, most clients are happy with their choice to initiate treatment, and quality of life generally improves following commencement of therapy.<sup>109,110</sup> The chemotherapeutic agents used most commonly to treat intermediate- or high-grade lymphoma in cats are similar to those used for dogs and humans with lymphoma (see Section A in this chapter) and include doxorubicin, vincristine, cyclophosphamide, methotrexate, L-asparaginase, CCNU (lomustine), and prednisone. Most combination induction protocols currently employed in cats are modifications of CHOP protocols initially designed for human oncologic use.<sup>5,110-116</sup> CHOP represents combinations of cyclophosphamide (C), doxorubicin (H, hydroxydaunorubicin), vincristine (O, Oncovin) and prednisone (P). In general, CHOP-based protocols are appropriate for cats with large cell, intermediate- and high-grade lymphoma involving any anatomic site (e.g., peripheral nodal, mediastinal, and renal forms) but should not be first-line therapy for small cell, low-grade variants. As in the dog (see Section A in this chapter), a plethora of modifications are used with CHOP-based protocols, although virtually no quality comparative data exist to compare outcomes, and as such, the protocol used should be based on cost, ease, client/veterinarian preference, and level of comfort. The current CHOP-based protocol in use by



• **TABLE 32-10** The CHOP-Based Chemotherapy Protocol for Cats with Lymphoma Employed by the Author

TREATMENT WEEK	DRUG, DOSAGE, AND ROUTE
1	Vincristine 0.5-0.7 mg/m <sup>2</sup> IV L-Asparaginase 400 Units/kg SQ Prednisone 2.0 mg/kg PO, q24hr
2	Cyclophosphamide 200 mg/m <sup>2</sup> IV Prednisone 2.0 mg/kg PO, q24hr
3	Vincristine 0.5-0.7 mg/m <sup>2</sup> IV Prednisone 1.0 mg/kg PO, q24hr
4	Doxorubicin 25 mg/m <sup>2</sup> IV Prednisone 1.0 mg/kg PO*
6	Vincristine 0.5-0.7 mg/m <sup>2</sup> IV
7 <sup>†</sup>	Cyclophosphamide 200 mg/m <sup>2</sup> IV
8	Vincristine 0.5-0.7 mg/m <sup>2</sup> IV
9 <sup>‡</sup>	Doxorubicin 25 mg/m <sup>2</sup> IV
11	Vincristine 0.5-0.7 mg/m <sup>2</sup> IV
13 <sup>†</sup>	Cyclophosphamide 200 mg/m <sup>2</sup> IV
15	Vincristine 0.5-0.7 mg/m <sup>2</sup> IV
17	Doxorubicin 25 mg/m <sup>2</sup> IV
19	Vincristine 0.5-0.7 mg/m <sup>2</sup> IV
21 <sup>†</sup>	Cyclophosphamide 200 mg/m <sup>2</sup> IV
23	Vincristine 0.5-0.7 mg/m <sup>2</sup> IV
25 <sup>§</sup>	Doxorubicin 25 mg/m <sup>2</sup> IV

IV, Intravenous; SQ, subcutaneous; PO, by mouth.

\*Prednisone is continued (1 mg/kg PO) every other day from this point on.

<sup>†</sup>If renal lymphoma or central nervous system (CNS) lymphoma is present, substitute cytosine arabinoside (Ara-C) at 600 mg/m<sup>2</sup> divided SQ twice a day (BID) over 2 days at these treatments.

<sup>‡</sup>If in complete remission at week 9, continue to week 11.

<sup>§</sup>If in complete remission at week 25, therapy is discontinued and cat is rechecked monthly for recurrence.

NOTE: A complete blood count (CBC) should be performed prior to each chemotherapy. If neutrophils are <1500 cells/UL, wait 5 to 7 days, repeat CBC, then administer the drug if neutrophils have risen above the 1500 cell/UL cutoff.

the author is presented in Table 32-10. This protocol has been used in many cats with various forms of intermediate- and high-grade lymphoma and is generally well tolerated. At present, most canine lymphoma protocols (see Section A in this chapter) discontinue chemotherapy by the 25th week, and we have sufficient data to show shorter, maintenance-free protocols are as good if not superior to longer maintenance protocols; however, similar comparative data do not exist in the cat. Until such time as evidence to the contrary exists, the author presently recommends discontinuation of chemotherapy at week 25 in cats who have attained a complete remission. Doxorubicin alone (25 mg/m<sup>2</sup>, every 3 weeks for 5 total treatments) or palliative prednisone therapy is offered if clients decline more aggressive CHOP-based therapy. Cats are generally less tolerant of doxorubicin than are dogs; therefore a lower dosage (25 mg/m<sup>2</sup> IV or 1 mg/kg IV) is used (see Chapter 11). Cardiac toxicity does not appear to be a clinically significant problem in cats, although renal toxicity is more commonly encountered in the species<sup>117</sup> and renal function should be monitored (i.e., serial BUN, creatinine, and urine specific gravity) closely prior to and during therapy. The use of COP (i.e., CHOP without the addition of doxorubicin) is often

• **TABLE 32-11** COP Protocol for Lymphoma in Cats

DRUG	FREQUENCY OF DRUG DELIVERY
Cyclophosphamide 300 mg/m <sup>2</sup> IV	Given every 3 weeks on the day after vincristine. Discontinued if animal is in complete remission at 1 year.
Vincristine (Oncovin) 0.75 mg/m <sup>2</sup> IV	Given weekly on weeks 1, 2, 3, and 4, then given every 3 weeks thereafter on the day before cyclophosphamide, Discontinued if animal is in complete remission at 1 year.
Prednisone/ prednisolone 50 mg/m <sup>2</sup> orally	Given daily for 1 year.

NOTE: A complete blood count (CBC) should be performed prior to each treatment. If neutrophils are <1.5 × 10<sup>9</sup>/L, wait 5 to 7 days and repeat the CBC. Treat if neutrophils are ≥1.5 × 10<sup>9</sup>/L.

used in cats in Europe, and one compilation reported similar results to CHOP.<sup>64</sup> A COP protocol commonly employed in cats is presented in Table 32-11. Some studies with relatively few case entries have reported limited activity for doxorubicin as a single agent in cats with lymphoma<sup>118,119</sup>; however, larger studies using combination protocols have more consistently reported the addition of doxorubicin as necessary for the attainment of more durable responses.<sup>5,114</sup> Interestingly, in a report of 23 cats having relapsed following COP-based protocols (without doxorubicin), only 22% responded subsequently to doxorubicin-containing rescue therapy.<sup>120</sup> A small number of cats with lymphoma have been treated with single-agent oral CCNU (lomustine) at a dosage range of 30 to 60 mg/m<sup>2</sup> every 3 to 6 weeks.<sup>121,122</sup> Whereas activity was noted, only partial responses were reported. L-asparaginase, which is often included in protocols for lymphoma in cats, has a much shorter asparagine-depleting effect in cats (lost by 7 days) than in dogs and in one study in 13 cats with lymphoma resulted in only a 30% response rate.<sup>123</sup>

In general, cats with intermediate- and high-grade lymphoma treated with CHOP-based or COP protocols do not enjoy the same level of success as dogs. Bearing in mind that these reports group together a wide variety of subtypes having dissimilar prognoses (see subsequent site-specific treatment sections), the overall response rates tend to be in the 50% to 80% range with median remission and survival durations of 4 and 6 months, respectively.<sup>5,64,110-116,124</sup>

### Anatomic Site-Specific Treatment

**Alimentary/Gastrointestinal Lymphoma** Representing the most common presentation for cats with lymphoma, the large majority have the small cell, mucosal, T-cell variant that carries a good prognosis, often with less aggressive chemotherapy protocols (e.g., oral chlorambucil and prednisone).<sup>51,52,87,125</sup> Chlorambucil (20 mg/m<sup>2</sup> PO, every 2 weeks [preferred by the author] or 2 mg PO every other day) and prednisone or prednisolone (initially 1 to 2 mg/kg PO daily, reduced to 0.5 to 1.0 mg/kg every other day over several weeks) results in response rates (i.e., resolution of clinical signs) of greater than 90% and median survivals of approximately 2 years or longer.<sup>52,87,125</sup> Cats who relapse with this protocol often will subsequently respond to alternative alkylators, such as cyclophosphamide or lomustine.<sup>125</sup> Anecdotally, many will also respond

to vinblastine chemotherapy if they no longer are responsive to alkylators.

In contrast, cats with B-cell or large T-cell (including LGL) or small T-cell lymphoma that is transmural typically do not enjoy a durable response to therapy and survivals are much shorter.<sup>31,51,59,60</sup> Median survivals range from 45 to 100 days, even in cats treated with more aggressive COP-based protocols. In the author's experience, these variants are more likely to respond to CHOP-based protocols than chlorambucil/prednisone; however, durable responses occur only in a minority of cases. In particular, LGL appears to carry a grave prognosis<sup>59,60</sup>; in 2 compilations of 66 cats with LGL, median survivals of approximately 2 months were reported, including 23 cats receiving either COP or CHOP-based protocols, which resulted in only a 30% response rate.

Nutritional support is especially important for cats with GI lymphomas. It may be necessary to place a feeding tube in cats undergoing chemotherapy, particularly if prolonged anorexia is present (see Chapter 15, Section B).

Recently, two preliminary studies evaluated RT, either as rescue following recurrence or in addition to chemotherapy for the treatment of intestinal lymphoma in cats.<sup>126,127</sup> Eleven cats (6 small cell, 4 large cell, and 1 LGL) that progressed following chemotherapy received abdominal radiation (8 Gy in 2 fractions over 2 days) and resulted in a median survival of 7 months, although numbers were small and 40% were lost to follow-up.<sup>127</sup> A second report of eight cats (seven with large cell lymphoma) underwent 6 weeks of CHOP-based combination chemotherapy, followed 2 weeks later by whole abdomen radiation consisting of 10 daily 1.5 Gy fractions.<sup>126</sup> Although three cats died within 3 weeks of RT, five enjoyed durable remissions. These preliminary promising outcomes warrant further investigation.

**Mediastinal Lymphoma** Mediastinal lymphoma in young FeLV-positive cats is generally associated with a poor prognosis, and survival times of approximately 2 to 3 months are expected following CHOP- or COP-based protocols.<sup>5,116</sup> In contrast, young FeLV-negative Siamese cats with mediastinal lymphoma experience remission rates approaching 90%, and responses tend to be more durable (median ≈9 months).<sup>64</sup>

**Nodal Lymphoma** The treatment choice for peripheral nodal lymphoma in cats depends on whether the individual case represents a low-grade (e.g., indolent, small cell variants) versus an intermediate- or high-grade (e.g., large cell) lymphoma; the latter are best treated with CHOP- or COP-based protocols and carry a less favorable prognosis, whereas the former generally respond to less aggressive chlorambucil/corticosteroid protocols and enjoy durable responses. Less is known regarding the treatment of Hodgkin's-like lymphoma involving solitary or regional nodes of the head and neck.<sup>65,66</sup> Clinical outcome following surgical extirpation of the affected node (or nodes if a reasonable number) is often associated with long-term, disease-free intervals and survivals of approximately 1 year, suggesting it is a more indolent form of lymphoma. Eventual recurrence in distal nodes following surgical excision is common, and the author currently offers clients the option of adjuvant chlorambucil/corticosteroids following surgery—this theoretically may have benefit; however, insufficient data exist to document a survival advantage with this approach.

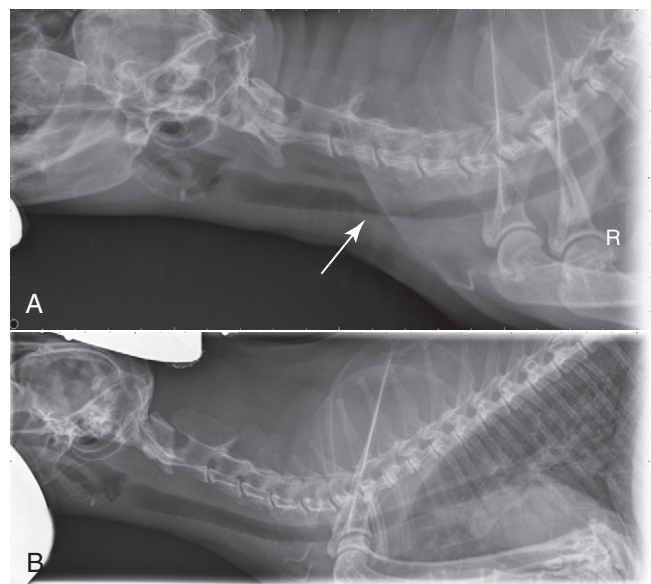
**Nasal Lymphoma** Cats with nasal lymphoma generally enjoy durable remissions following therapy and lengthy overall survival durations.<sup>5,68,73,128,129</sup> If disease is documented as confined to the

nasal cavity following thorough staging (node cytology, thoracic and abdominal imaging, bone marrow aspiration), then RT is the treatment of choice. CRs in the order of 75% to 95% are reported, with reports of median survivals following RT of 1.5 to 3 years.<sup>73,129</sup> Cats that do not achieve a CR with RT have a median survival of approximately 4.5 months. Total radiation dosage does affect survival durations, and a total dose greater than 32 Gy is recommended.<sup>73</sup> The addition of chemotherapy has not been shown to enhance survival for cats with locally confined disease; combinations of RT and chemotherapy result in similar response rates and survival times.<sup>73,128,129</sup> Chemotherapy (COP- or CHOP-based protocols) used in the absence of RT is a reasonable alternative, with complete response rates of approximately 75% and median survivals of approximately 2 years reported for cats achieving CR.<sup>68</sup> The author's preference is to initiate systemic chemotherapy only for (1) cases that have confirmed disease beyond the nasal passage, (2) cases that relapsed following RT, or (3) cases in which RT is unavailable or declined.

**Central Nervous System Lymphoma** Very few cases involving treatment for CNS lymphoma exist, and although an occasional case experienced durable response to systemic chemotherapy, generally less than 50% will respond and median survivals of 1 to 2 months can be expected.<sup>68,76,77</sup>

**Laryngeal/Tracheal Lymphoma** The vast majority of cats with laryngeal or tracheal lymphoma respond to either RT (if localized) or systemic chemotherapy (90% CR to COP- or CHOP-based protocols) (Figure 32-16).<sup>68</sup> Whereas the authors experience is that most have durable responses and survival durations typically approach or exceed 1 year, the only case series (n = 8) reported a median survival of 5.5 months following achievement of a CR.

**Cutaneous Lymphoma** Very little has been published regarding the treatment of cutaneous lymphoma or mycosis fungoides in cats<sup>80</sup>; however, a report of a CR to lomustine exists.<sup>130</sup> Cats with a solitary disease could theoretically be treated with surgical excision



**FIGURE 32-16** **A**, Lateral radiographic projection of a cat with tracheal lymphoma prior to treatment. **B**, The same cat 6 weeks following initiation of CHOP-based chemotherapy protocol.

or RT, although clinical staging is necessary to rule out possible further systemic involvement. For multiple sites, combination chemotherapy may be considered.

### General Summary of Prognosis for Cats with Lymphoma

As previously discussed, the prediction of outcomes in cats with lymphoma is not generalizable due to the wide spectrum of histologic and anatomic subtypes encountered. Much has been mentioned in the previous treatment sections, and Tables 32-8 and Table 32-9 summarize prognostic parameters for lymphoma in cats.

## Feline Leukemias, Myeloproliferative Disorders, and Myelodysplasia

For a complete discussion of leukemias and MPDs, including a general discussion of hematopoiesis, etiologies, lineage classification and descriptions, see Section C of this chapter. The classification of leukemias in cats is difficult because of the similarity of clinical and pathologic features and the transition, overlap, or mixture of cell types involved.<sup>131-135</sup> Most case-series reports are from the FeLV era and generally only single case reports exist from the more contemporary post-FeLV era, which further confuses our understanding of the biology and outcome. For this reason, only a simplistic discussion, primarily relating to the lymphoid leukemias will be presented here and the interested reader is again referred to Section C for a general discussion of nonlymphoid leukemia.

For cats with suspected leukemia, peripheral blood assessment (e.g., CBC with differential, flow cytometric analysis for size and immunophenotype, and PARR [for lymphoid leukemias]), and bone marrow aspiration or biopsy may contribute to a diagnosis. The preferred sites for bone marrow aspiration are the proximal humerus or iliac crest. Cats with acute leukemia are likely to have malignant cellular infiltrates in organs other than bone marrow.<sup>134</sup> A bone marrow aspirate with greater than 30% abnormal blast cells is sufficient to make a diagnosis of an acute leukemia. In cats with suspected CLL, infiltration of the bone marrow with more than 20% mature lymphocytes helps confirm the diagnosis. All cats with leukemia should be tested for FeLV/FIV. Determining the lineage of some leukemias can be challenging; most can be distinguished from one another by histologic appearance, histochemical stains, or immunohistochemical or flow cytometric analysis of the leukemic cells for cellular antigens that identify their lineage (see Chapter 8 and Section C in this chapter).<sup>131,133,136</sup> In addition, examination of blast cells by electron microscopy may reveal characteristic ultrastructural features. The French-American-British (FAB) classification system is considered useful in cats with myelodysplastic syndromes and almost all will be FeLV antigenemic.<sup>136,137</sup>

### Lymphoid Leukemia

ALL was the most commonly encountered type of leukemia in cats in the FeLV era; however, it is much less common today. ALL is characterized by poorly differentiated lymphoblasts and prolymphocytes in blood and bone marrow. Approximately 60% to 80% of cats with ALL were FeLV positive, and most malignant cells have T-cell immunophenotypes<sup>138</sup>; however, little information is available in the contemporary literature.

CLL is rarely reported in cats and is characterized by well-differentiated, small, mature lymphocytes in peripheral blood and

bone marrow. Whereas most are of the T-cell lineage, B-cell CLL has also been reported.<sup>136,139,140</sup> Most cats have increased WBC counts greater than 50,000/ $\mu$ l, and most are FeLV negative.

### Treatment of Leukemias

The use of chemotherapy to treat ALL has been disappointing. Using COP-based protocols, Cotter<sup>124</sup> reported a 27% CR rate. CLL can be treated with chlorambucil (0.2 mg/kg PO or 2 mg/cat QOD) and prednisone (1 mg/kg PO daily); however, little information exists regarding outcome. As in humans and dogs, if significant clinical signs or profound cytopenias are not present, treatment can be withheld—one cat with CLL remained stable without chemotherapy for over a year.<sup>140</sup> The prognoses for acute nonlymphoblastic leukemias are generally very poor, although some exceptions exist in case report form in the historic literature.

### REFERENCES

- Couto CG: Oncology. In Sherding RG, editor: *The cat: diseases and clinical management*, New York, 1989, Churchill Livingstone.
- Hardy WD Jr: Hematopoietic tumors of cats, *J Am Anim Hosp Assoc* 17:921-940, 1981.
- Essex M, Francis DP: The risk to humans from malignant diseases of their pets: An unsettled issue, *J Am Anim Hosp Assoc* 12:386-390, 1976.
- Theilen GH, Madewell BR: Feline hematopoietic neoplasms. In Theilen GH, Madewell BR, editors: *Veterinary cancer medicine*, ed 2, Philadelphia, 1987, Lea & Febiger.
- Vail DM, Moore AS, Ogilvie GK, et al: Feline lymphoma (145 cases): Proliferation indices, CD3 immunoreactivity and their association with prognosis in 90 cats receiving therapy, *J Vet Intern Med* 12:349-354, 1998.
- Cotter SM: Feline viral neoplasia. In Greene CE, editor: *Infectious diseases of the dog and cat*, ed 3, Philadelphia, 1998, WB Saunders.
- Louwerens M, London CA, Pedersen NC, et al: Feline lymphoma in the post-feline leukemia virus era, *J Vet Intern Med* 19:329-335, 2005.
- Rissetto K, Villamil JA, Selting KA, et al: Recent trends in feline intestinal neoplasia: an epidemiologic study of 1,129 cases in the veterinary medical database from 1964 to 2004, *J Am Anim Hosp Assoc* 47:28-36, 2011.
- Schmidt JM, North SM, Freeman KP, et al: Feline paediatric oncology: retrospective assessment of 233 tumours from cats up to one year (1993 to 2008), *J Small Anim Pract* 51:306-311, 2010.
- Gabor LJ, Malik R, Canfield PJ: Clinical and anatomical features of lymphosarcoma in 118 cats, *Aust Vet J* 76:725-732, 1998.
- Gabor LJ, Canfield PJ, Malik R: Immunophenotypic and histological characterization of 109 cases of feline lymphosarcoma, *Aust Vet J* 77:436-441, 1999.
- Stutzer B, Simon K, Lutz H, et al: Incidence of persistent viraemia and latent feline leukaemia virus infection in cats with lymphoma, *J Feline Med Surg* 13:81-87, 2011.
- Weiss AT, Klopffleisch R, Gruber AD: Prevalence of feline leukaemia provirus DNA in feline lymphomas, *J Feline Med Surg* 12:929-935, 2010.
- Ahmad S, Levy LS: The frequency of occurrence and nature of recombinant feline leukemia viruses in the induction of multicentric lymphoma by infection of the domestic cat with FeLV-945, *Virology* 403:103-111, 2010.
- Fuhino Y, Satoh H, Ohno K, et al: Molecular cytogenetic analysis of feline leukemia virus insertions in cat lymphoid tumor cells, *J Virol Methods* 163:344-352, 2010.
- Fujino Y, Liao CP, Zhao YS, et al: Identification of a novel common proviral integration site, flit-1, in feline leukemia virus induced thymic lymphoma, *Virology* 30:16-22, 2009.



17. Fujino Y, Ohno K, Tsujimoto H: Molecular pathogenesis of feline leukemia virus-induced malignancies: insertional mutagenesis, *Vet Immunol Immunopathol* 123:138–143, 2008.
18. Shelton GH, Grant CK, Cotter SM, et al: Feline immunodeficiency virus (FIV) and feline leukemia virus (FeLV) infections and their relationship to lymphoid malignancies in cats: a retrospective study (1968–1988), *J Acquir Immune Def Synd* 3:623–630, 1990.
19. Hutson CA, Rideout BA, Pederson NC: Neoplasia associated with feline immunodeficiency virus infection in cats of southern California, *J Am Vet Med Assoc*. 199:1357–1362, 1991.
20. Endo Y, Cho KW, Nishigaki K, et al: Molecular characteristics of malignant lymphomas in cats naturally infected feline immunodeficiency virus, *Vet Immun Immunopath* 57:153–167, 1997.
21. Terry A, Callanan JJ, Fulton R, et al: Molecular analysis of tumours from feline immunodeficiency virus (FIV)-infected cats: an indirect role for FIV, *Int J Cancer* 61:227–232, 1995.
22. Wang J, Kyaw-Tanner M, Lee C, et al: Characterisation of lymphosarcomas in Australian cats using polymerase chain reaction and immunohistochemical examination, *Aust Vet J* 79:41–46, 2001.
23. Beatty JA, Lawrence CE, Callanan JJ, et al: Feline immunodeficiency virus (FIV)-associated lymphoma: a potential role for immune dysfunction in tumorigenesis, *Vet Immunol Immunopathol* 23:309–322, 1998.
24. Gabor LJ, Love DN, Malik R, et al: Feline immunodeficiency virus status of Australian cats with lymphosarcoma, *Aust Vet J* 79:540–545, 2001.
25. Beatty J, Terry A, MacDonald J, et al: Feline immunodeficiency virus integration in B-cell lymphoma identifies a candidate tumor suppressor gene on human chromosome 15q15, *Cancer Res* 62:7175–7180, 2002.
26. Poli A, Abramo F, Baldinotti F, et al: Malignant lymphoma associated with experimentally induced feline immunodeficiency virus infection, *J Comp Pathol* 110:319–328, 1994.
27. Callanan JJ, McCandlish IA, O'Neil B, et al: Lymphosarcoma in experimentally induced feline immunodeficiency virus infection, *Vet Rec* 130:293–295, 1992.
28. Rosenberg MP, Hohenhaus AE, Matus RE: Monoclonal gammopathy and lymphoma in a cat infected with feline immunodeficiency virus, *J Am Anim Hosp Assoc* 27:335–337, 1991.
29. Buracco P, Guglielmino R, Abate O, et al: Large granular lymphoma in a FIV-positive and FeLV-negative cat, *J Small Anim Pract* 33:279–284, 1992.
30. Zwahlen CH, Lucroy MD, Kraegel SA, et al: Results of chemotherapy for cats with alimentary malignant lymphoma: 21 cases (1993–1997), *J Am Vet Med Assoc* 213:1144–1149, 1998.
31. Mahony OM, Moore AS, Cotter SM, et al: Alimentary lymphoma in cats: 28 cases (1988–1993), *J Am Vet Med Assoc* 207:1593–1598, 1995.
32. Rassnick KM, Mauldin GN, Moroff SD, et al: Prognostic value of argyrophilic nucleolar organizer region (AgNOR) staining in feline intestinal lymphoma, *J Vet Intern Med* 13:187–190, 1999.
33. Slawiński MJ, Mauldin GE, Mauldin GN, et al: Malignant colonic neoplasia in cats: 46 cases (1990–1996), *J Am Vet Med Assoc* 211:878–881, 1997.
34. Mayr B, Winkler G, Schaffner G, et al: N-ras mutations in a feline lymphoma: Low frequency of N-ras mutations in a series of feline, canine and bovine lymphomas, *Vet J* 163:326–328, 2002.
35. Cadile CD, Kitchell BE, Biller BJ, et al: Telomerase activity as a marker for malignancy in feline tissues, *Am J Vet Res* 62:1578–1581, 2001.
36. Yazawa M, Okuda M, Uyama R, et al: Molecular cloning of the feline telomerase reverse transcriptase (TERT) gene and its expression in cell lines and normal tissues, *J Vet Med Sci* 65:573–577, 2003.
37. Kano R, Sato E, Okamura T, et al: Expression of Bcl-2 in feline lymphoma cell lines, *Vet Clin Pathol* 37:57–60, 2008.
38. Madewell B, Griffey S, Walls J, et al: Reduced expression of cyclin-dependent kinase inhibitor p27<sup>Kip1</sup> in feline lymphoma, *Vet Pathol* 38:698–702, 2001.
39. Dank G, Lucroy MD, Griffey SM, et al: Bcl-2 and MIB-1 labeling indexes in cats with lymphoma, *J Vet Intern Med* 16:720–725, 2002.
40. Bertone ER, Snyder LA, Moore AS: Environmental tobacco smoke and risk of malignant lymphoma in pet cats, *Am J Epidemiol* 156:268–273, 2002.
41. Marconato L, Leo C, Girelli R, et al: Association between waste management and cancer in companion animals, *J Vet Intern Med* 23:564–569, 2009.
42. Schmiedt CW, Grimes JA, Holzman G, et al: Incidence and risk factors for development of malignant neoplasia after feline renal transplantation and cyclosporine-based immunosuppression, *Vet Comp Oncol* 7:45–53, 2009.
43. Wooldridge JD, Gregory CR, Mathews KG, et al: The prevalence of malignant neoplasia in feline renal-transplant recipients, *Vet Surg* 31:94–97, 2002.
44. Carreas JK, Goldschmidt M, Lamb M, et al: Feline epitheliotropic intestinal malignant lymphoma: 10 cases(1997–2000), *J Vet Intern Med* 17:326–331, 2003.
45. Ragaini L, Aste G, Cavicchioli L, et al: Inflammatory bowel disease mimicking alimentary lymphosarcoma in a cat, *Vet Res Commun* 27(Suppl 1):791–793, 2003.
46. Tams TR: *Inflammatory bowel disease*, Philadelphia, 1991, WB Saunders, pp 409–414.
47. Hart JF, Shaker E, Patnaik AK, et al: Lymphocytic-plasmacytic enterocolitis in cats: 60 cases (1988–1990), *J Am Anim Hosp Assoc* 30:505–514, 1994.
- 47a. Bridgeford ED, Marini RP, Feng Y, et al: Gastric helicobacter species as a cause of feline gastric lymphoma: a viable hypothesis, *Vet Immunol Immunopathol* 1123:106–113, 2008.
48. Valli VE, Jacobs RM, Norris A, et al: The histologic classification of 602 cases of feline lymphoproliferative disease using the National Cancer Institute working formulation, *J Vet Diagn Invest* 12:295–306, 2000.
49. Valli VE, Jacobs RM, Parodi AL, et al: *Histological classification of hematopoietic tumors of domestic animals*, Washington, DC, 2002, Armed Forces Institute of Pathology and The World Health Organization.
50. Gieger T: Alimentary lymphoma in cats and dogs, *Vet Clin North Am Small Anim Pract* 41:419–432, 2011.
51. Moore PF, Rodriguez-Bertos A, Kass PH: Feline gastrointestinal lymphoma: Mucosal architecture, immunophenotype and molecular clonality, *Vet Pathol* 2011. [Epub ahead of print]
52. Lingard AE, Briscoe K, Beatty JA, et al: Low-grade alimentary lymphoma: clinicopathological findings and response to treatment in 17 cases, *J Feline Med Surg* 11:692–700, 2009.
53. Pohlman LM, Higginbotham ML, Welles EG, et al: Immunophenotypic and histologic classification of 50 cases of feline gastrointestinal lymphoma, *Vet Pathol* 46:259–268, 2009.
54. Kiupel M, Scedley RC, Pfent C, et al: Diagnostic algorithm to differentiate lymphoma from inflammation in feline small intestinal biopsy samples, *Vet Pathol* 48:212–222, 2011.
55. Vezzali E, Parodi AL, Marcato PS, et al: Histopathologic classification of 171 cases of canine and feline non-Hodgkin lymphoma according to the WHO, *Vet Comp Oncol* 8:38–49, 2010.
56. Swerdlow SH, Campo E, Harris NL, et al: *WHO classification of tumors of the haematopoietic and lymphoid tissues*, ed 4, Lyon, France, 2008, International Agency for Research on Cancer (IARC).
57. Briscoe KA, Krockenberger M, Beatty JA, et al: Histopathological and immunohistochemical evaluation of 53 cases of feline lymphoplasmacytic enteritis and low-grade alimentary lymphoma, *J Comp Pathol* 145:187–198, 2011.
58. Warren A, Center S, McDonough S, et al: Histopathologic features, immunophenotyping, clonality, and eubacterial fluorescence in situ hybridization in cats with lymphocytic cholangitis/ cholangiohepatitis, *Vet Pathol* 48:627–641, 2011.

59. Krick EL, Little L, Patel R, et al: Description of clinical and pathological findings, treatment and outcome of feline large granular lymphocyte lymphoma (1996-2004), *Vet Comp Oncol* 6:102-111, 2008.
60. Roccabianca P, Vernau W, Caniatti M, et al: Feline large granular lymphocyte (LGL) lymphoma with secondary leukemia: primary intestinal origin with predominance of a CD3/CD8(alpha)(alpha) phenotype, *Vet Pathol* 43:15-28, 2006.
61. Ezura K, Nomura I, Takahashi T, et al: Natural killer-like T cell lymphoma in a cat, *Vet Rec* 28:268-270, 2004.
62. Day MJ: Review of thymic pathology in 30 cats and 36 dogs, *J Small Anim Pract* 38:393-403, 1997.
63. Davies C, Forrester SD: Pleural effusion in cats: 82 cases (1987 to 1995), *J Small Anim Pract* 37:217-224, 1996.
64. Teske E, Sraten GV, van Noort R, et al: Chemotherapy with cyclophosphamide, vincristine and prednisolone (COP) in cats with malignant lymphoma: New results with an old protocol, *J Vet Intern Med* 16:179-186, 2002.
65. Day MJ, Kyaw-Tanner M, Silkstone MA, et al: T-cell-rich B-cell lymphoma in the cat, *J Comp Pathol* 120:155-167, 1999.
66. Walton RM, Hendrick MJ: Feline Hodgkin's-like lymphoma: 20 cases (1992-1999), *Vet Pathol* 38:504-511, 2001.
67. Holt E, Goldschmidt MH, Skorupski K: Extranodal conjunctival Hodgkin's-like lymphoma in a cat, *Vet Ophthalmol* 9:141-144, 2006.
68. Taylor SS, Goodfellow MR, Browne WJ, et al: Feline extranodal lymphoma: response to chemotherapy and survival in 110 cats, *J Small Anim Pract* 50:584-592, 2009.
69. Little L, Patel R, Goldschmidt M: Nasal and nasopharyngeal lymphoma in cats: 50 cases (1989-2005), *Vet Pathol* 44:885-892, 2007.
70. Henderson SM, Bradley K, Day MJ, et al: Investigation of nasal disease in the cat - a retrospective study of 77 cases, *J Feline Med Surg* 6:245-257, 2004.
71. Mukaratirwa S, van der Linde-Sipman JS, Gruys E, et al: Feline nasal and paranasal sinus tumours: clinicopathological study, histomorphological description and diagnostic immunohistochemistry of 123 cases, *J Feline Med Surg* 3:235-245, 2001.
72. Demko JL, Cohn LA: Chronic nasal discharge in cats: 75 cases (1993-2004), *J Am Vet Med Assoc* 230:1032-1037, 2007.
73. Haney SM, Beaver L, Turrel J, et al: Survival analysis of 97 cats with nasal lymphoma: a multi-institutional retrospective study (1986-2006), *J Vet Intern Med* 23:287-294, 2009.
74. Mooney SC, Hayes AA, Matus RE, et al: Renal lymphoma in cats: 28 cases (1977-1984), *J Am Vet Med Assoc* 191:1473-1477, 1987.
75. Tomek A, Cizinauskas S, Doherr M, et al: Intracranial neoplasia in 61 cats: localization, tumour types and seizure patterns, *J Feline Med Surg* 8:243-253, 2006.
76. Troxel MT, Vite CH, Van Winkle TJ, et al: Feline intracranial neoplasia: retrospective review of 160 cases (1985-2001), *J Vet Intern Med* 17:850-859, 2003.
77. Marioni-Henry K, Van Winkle TJ, Smith SH, et al: Tumors affecting the spinal cord of cats: 85 cases (1980-2005), *J Am Vet Med Assoc* 232:237-243, 2008.
78. Marioni-Henry K, Vite CH, Newton AL, et al: Prevalence of diseases of the spinal cord of cats, *J Vet Intern Med* 18:851-858, 2004.
79. Taylor SS, Harvey AM, Bar FJ, et al: Laryngeal disease in cats: a retrospective study of 35 cases, *J Feline Med Surg* 11:954-962, 2009.
80. Fontaine J, Heimann M, Day MJ: Cutaneous epitheliotropic T-cell lymphoma in the cat: a review of the literature and five new cases, *Vet Dermatol* 22:454-461, 2011.
81. Caciolo PL, Nesbitt GH, Patnaik AK, et al: Cutaneous lymphosarcoma in the cat: a report of nine cases, *J Am Anim Hosp Assoc* 20:491-496, 1984.
82. May MJ: Immunophenotypic characterization of cutaneous lymphoid neoplasia in the dog and cat, *J Comp Pathol* 112:79-96, 1995.
83. Gilbert S, Affolter VK, Gross TL, et al: Clinical, morphological and immunohistochemical characterization of cutaneous lymphocytosis in 23 cats, *Vet Dermatol* 15:3-12, 2004.
84. Wood C, Almes K, Bagladi-Swanson M, et al: Sézary syndrome in a cat, *J Am Anim Hosp Assoc* 44:144-148, 2008.
85. Schick RO, Murphy GF, Goldschmidt MH: Cutaneous lymphosarcoma and leukemia in a cat, *J Am Vet Med Assoc* 203:1155-1158, 1993.
86. Grahn BH, Peiffer RL, Cullen CL, et al: Classification of feline intraocular neoplasms based on morphology, histochemical staining and immunohistochemical labeling, *Vet Ophthalmol* 9:395-403, 2006.
87. Kiselow MA, Rassnick KM, McDonough SP, et al: Outcome of cats with low-grade lymphocytic lymphoma: 41 cases (1995-2005), *J Am Vet Med Assoc* 232:405-410, 2008.
88. Fondacaro JV, Richter KP, Carpenter JL, et al: Feline gastrointestinal lymphoma: 67 cases (1988-1996), *Eur J Comp Gastroenterol* 4:1999.
89. Court EA, Watson ADJ, Peaston AE: Retrospective study of 60 cases of feline lymphosarcoma, *Aust Vet J* 75:424-427, 1997.
90. Forrester SD, Fossum TW, Rogers KS, et al: Diagnosis and treatment of chylothorax associated with lymphoblastic lymphosarcoma in four cats, *J Am Vet Med Assoc* 198:291-294, 1991.
91. Spodnick GJ, Berg J, Moore FM, et al: Spinal lymphoma in cats: 21 cases (1976-1989), *J Am Vet Med Assoc* 200:373-376, 1992.
92. Lane SB, Kornegay JN, Duncan JR, et al: Feline spinal lymphosarcoma: a retrospective evaluation of 23 cats, *J Vet Intern Med* 8:99-104, 1994.
93. Savary KCM, Price GS, Vaden SL: Hypercalcemia in cats: A retrospective study of 71 cases (1991-1997), *J Vet Intern Med* 14:184-189, 2000.
94. Gabor LJ, Canfield PJ, Malik R: Haematological and biochemical findings in cats in Australia with lymphosarcoma, *Aust Vet J* 78:456-461, 2000.
95. Gerou-Ferriani M, McBrearty AR, Burchmore RJ, et al: Agarose gel serum protein electrophoresis in cats with and without lymphoma and preliminary results of tandem mass fingerprinting analysis, *Vet Clin Pathol* 40:159-173, 2011.
96. Avery A: Molecular diagnostics of hematologic malignancies, *Top Companion Anim Med* 24:144-150, 2009.
97. Werner JA, Woo JC, Vernau W, et al: Characterization of feline immunoglobulin heavy chain variable region genes for the molecular diagnosis of B-cell neoplasia, *Vet Pathol* 42:596-607, 2005.
98. Moore PF, Woo JC, Vernau W, et al: Characterization of feline T cell receptor gamma (TCRG) variable region genes for the molecular diagnosis of feline intestinal T cell lymphoma, *Vet Immunol Immunopathol* 106:167-178, 2005.
99. Weiss AT, Klopffleisch R, Gruber AD: T-cell receptor  $\gamma$  chain variable and joining region genes of subgroup 1 are clonally rearranged in feline B- and T-cell lymphoma, *J Comp Pathol* 144:123-134, 2011.
100. Henrich M, Hecht W, Weiss AT, et al: A new subgroup of immunoglobulin heavy chain variable region genes for the assessment of clonality in feline B-cell lymphomas, *Vet Immunol Immunopathol* 130:59-69, 2009.
101. Mooney SC, Hayes AA: Lymphoma in the cat: An approach to diagnosis and management, *Sem Vet Med Surg (Small Anim)* 1:51-57, 1986.
102. Zwingenberger AL, Marks SL, Baker TW, et al: Ultrasonographic evaluation of the muscularis propria in cats with diffuse small intestinal lymphoma or inflammatory bowel disease, *J Vet Intern Med* 24:289-292, 2010.
103. Evans SE, Bonczynski JJ, Broussard JD, et al: Comparison of endoscopic and full-thickness biopsy specimens for diagnosis of inflammatory bowel disease and alimentary tract lymphoma in cats, *J Am Vet Med Assoc* 229:1447-1450, 2006.
104. Kleinschmidt S, Harder J, Nolte I, et al: Chronic inflammatory and non-inflammatory diseases of the gastrointestinal tract in cats: diagnostic advantage of full-thickness intestinal and extraintestinal biopsies, *J Feline Med Surg* 12:97-103, 2010.

105. Fossum TW, Jacobs RM, Birchard SJ: Evaluation of cholesterol and triglyceride concentrations in differentiating chylous and nonchylous pleural effusions in dogs and cats, *J Am Vet Med Assoc* 188:49–51, 1986.
106. Tromblee TC, Jones JC, Etue AE, et al: Association between clinical characteristics, computed tomography characteristics, and histologic diagnosis for cats with sinonasal disease, *Vet Radiol Ultrasound* 47:241–248, 2006.
107. Detweiler DA, Johnson LR, Kass PH, et al: Computed tomographic evidence of bulla effusions in cats with sinonasal diseases: 2001–2004, *J Vet Intern Med* 20:1080–1084, 2006.
108. Valdes-Martinez A, Cianciolo R, Mai W: Association between renal hypoechoic subcapsular thickening and lymphosarcoma in cats, *Vet Radiol Ultrasound* 48:357–360, 2007.
109. Tzannes S, Hammond MF, Murphy S, et al: Owners' perception of their cats' quality of life during COP chemotherapy for lymphoma, *J Feline Med Surg* 10:73–81, 2008.
110. Malik R, Gabor LJ, Foster SE, et al: Therapy for Australian cats with lymphosarcoma, *Aust Vet J* 79:808–817, 2001.
111. Hadden AG, Cotter SM, Rand W, et al: Efficacy and toxicosis of VECAP-C treatment of lymphoma in cats, *J Vet Intern Med* 22:153–157, 2008.
112. Simon D, Eberle N, Laacke-Singer L, et al: Combination chemotherapy in feline lymphoma: Treatment, outcome, tolerability and duration in 23 cats, *J Vet Intern Med* 22:394–400, 2008.
113. Milner RJ, Peyton J, Cooke K, et al: Response rates and survival times for cats with lymphoma treated with the University of Wisconsin-Madison chemotherapy protocol: 38 cases (1996–2003), *J Am Vet Med Assoc* 227:1118–1122, 2005.
114. Moore AS, Cotter SM, Frimberger AE, et al: A comparison of doxorubicin and COP for maintenance of remission in cats with lymphoma, *J Vet Intern Med* 10:372–375, 1996.
115. Mooney SC, Hayes AA, MacEwen EG, et al: Treatment and prognostic factors in lymphoma in cats: 103 cases (1977–1981), *J Am Vet Med Assoc* 194:696–699, 1989.
116. Jeglum KA, Whereat A, Young K: Chemotherapy of lymphoma in 75 cats, *J Am Vet Med Assoc* 190:174–178, 1987.
117. Poirier VJ, Thamm DH, Kurzman ID, et al: Liposome-encapsulated doxorubicin (Doxil) and doxorubicin in the treatment of vaccine-associated sarcoma in cats, *J Vet Intern Med* 16:726–731, 2002.
118. Peaston AE, Maddison JE: Efficacy of doxorubicin as an induction agent for cats with lymphosarcoma, *Aust Vet J* 77:442–444, 1999.
119. Kristal O, Lana SE, Ogilvie GK, et al: Single agent chemotherapy with doxorubicin for feline lymphoma: a retrospective study of 19 cases (1994–1997), *J Vet Intern Med* 15:125–130, 2001.
120. Oberthaler KT, Mauldin E, McManus PM, et al: Rescue therapy with doxorubicin-based chemotherapy for relapsing or refractory feline lymphoma: a retrospective study of 23 cases, *J Feline Med Surg* 11:259–265, 2009.
121. Fan TM, Kitchell BE, Dhaliwal RS, et al: Hematological toxicity and therapeutic efficacy of lomustine in 20 tumor-bearing cats: critical assessment of a practical dosing regimen, *J Am Anim Hosp Assoc* 38:357–363, 2002.
122. Rassnick KM, Gieger TL, Williams LE, et al: Phase I evaluation of CCNU (lomustine) in tumor-bearing cats, *J Vet Intern Med* 15:196–199, 2001.
123. LeBlanc AK, Cox SK, Kirk CA, et al: Effects of L-asparaginase on plasma amino acid profiles and tumor burden in cats with lymphoma, *J Vet Intern Med* 21:760–763, 2007.
124. Cotter SM: Treatment of lymphoma and leukemia with cyclophosphamide, vincristine, and prednisone: II. Treatment of cats, *J Am Anim Hosp Assoc* 19:166–172, 1983.
125. Stein TJ, Pellin M, Steinberg H, et al: Treatment of feline gastrointestinal small-cell lymphoma with chlorambucil and glucocorticoids, *J Am Anim Hosp Assoc* 46:413–417, 2010.
126. Williams LE, Pruitt AF, Thrall DE: Chemotherapy followed by abdominal cavity irradiation for feline lymphoblastic lymphoma, *Vet Radiol Ultrasound* 51:681–687, 2010.
127. Parshley DL, LaRue SM, Kitchell B, et al: Abdominal irradiation as a rescue therapy for feline gastrointestinal lymphoma: a retrospective study of 11 cats (2001–2008), *J Feline Med Surg* 13:63–68, 2011.
128. Sfiligoi GA, Theon AP, Kent MS: Response of 19 cats with nasal lymphoma to radiation therapy and chemotherapy, *Vet Rad Ultrasound* 48:388–392, 2007.
129. Elmslie RE, Ogilvie GK, Gillette EL, et al: Radiotherapy with and without chemotherapy for localized lymphoma in 10 cats, *Vet Radiol* 32:277–280, 1991.
130. Komori S, Nakamura S, Takahashi K, et al: Use of lomustine to treat cutaneous nonepitheliotropic lymphoma in a cat, *J Am Vet Med Assoc* 226:237–239, 2005.
131. Grindem CB: Ultrastructural morphology of leukemia cells in the cat, *Vet Pathol* 22(2):147–155, 1988.
132. Gorman NT, Evans RJ: Myeloproliferative disease in the dog and cat: clinical presentations, diagnosis and treatment, *Vet Rec* 121:490–496, 1987.
133. Grindem CB, Perman V, Stevens JB: Morphological and clinical and pathological characteristics of spontaneous leukemia in 10 cats, *J Am Anim Hosp Assoc* 21:227, 1985.
134. Blue JT, French TW, Scarlett-Kranz J: Non-lymphoid hematopoietic neoplasia in cats: a retrospective study of 60 cases, *Cornell Vet* 78:21–42, 1988.
135. Facklam NR, Kociba GJ: Cytochemical characterization of feline leukemic cells, *Vet Pathol* 23:155–161, 1986.
136. Weiss DJ: Differentiating benign and malignant causes of lymphocytosis in feline bone marrow, *J Vet Intern Med* 19:855–859, 2005.
137. Hisasue M, Okayama H, Okayama T, et al: Hematologic abnormalities and outcome of 16 cats with myelodysplastic syndromes, *J Vet Intern Med* 15:471–477, 2001.
138. Essex ME: Feline leukemia: a naturally occurring cancer of infectious origin, *Epidemiol Rev* 4:189–203, 1982.
139. Workman HC, Vernau W: Chronic lymphocytic leukemia in dogs and cats: the veterinary perspective, *Vet Clin North Am Small Anim Pract* 33:1379–1399, 2003.
140. Tebb A, Cave T, Barron R, et al: Diagnosis and management of B cell chronic lymphocytic leukaemia in a cat, *Vet Rec* 154:430–433, 2004.

## SECTION C

# Canine Acute Myeloid Leukemia, Myeloproliferative Neoplasms, and Myelodysplasia

KAREN M. YOUNG AND DAVID M. VAIL

Myeloproliferative disorders (MPDs) are a group of neoplastic diseases of bone marrow in which there are clonal disorders of hematopoietic stem cells.<sup>1</sup> Aberrant proliferation of cells with defective maturation and function leads to reduction of normal hematopoiesis and invasion of other tissues. These disorders have been classified based on biologic behavior, degree of cellular differentiation, and lineage of the neoplastic cells (granulocytic, monocytic, erythroid, megakaryocytic, or mixed). Newer classification systems in humans have incorporated genetics and molecular genetic analysis; these are currently areas of active investigation in the study of animal leukemias.<sup>2</sup> In 1991 the Animal Leukemia Study Group made recommendations for classifying nonlymphoid leukemias in dogs and cats.<sup>3</sup> More recently, the Oncology Committee of the American College of Veterinary Pathologists (ACVP) has been reexamining criteria for a classification system and spearheading large multiinstitutional studies to validate the criteria. Long-term



objectives of these studies are to define molecular lesions, establish prognostic markers, and target effective therapeutic approaches.<sup>4</sup>

## Incidence and Risk Factors

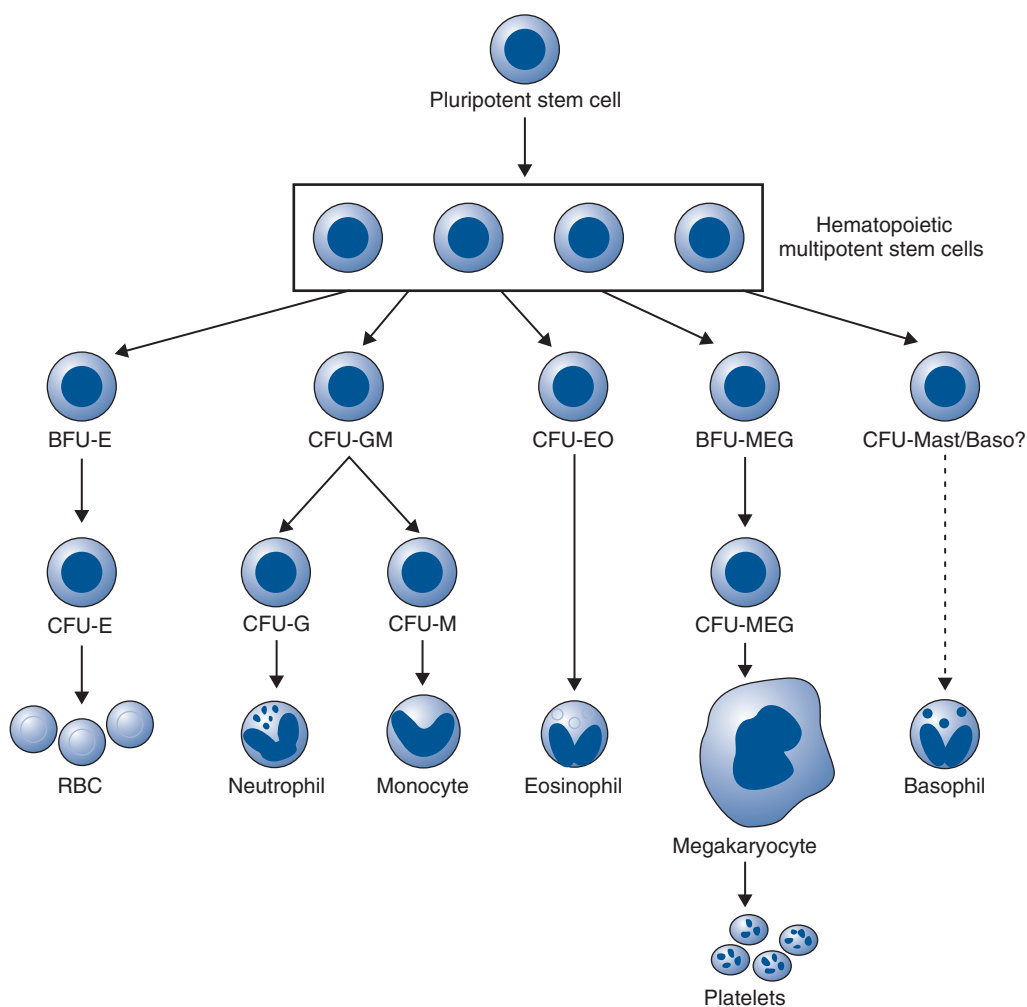
Myeloid neoplasms are uncommon or rare in the dog and occur 10 times less frequently than lymphoproliferative disorders.<sup>5</sup> Accurate information about incidence and other epidemiologic information await consistent use of a uniform classification system (see later discussion). There is no known age, breed, or sex predisposition, although in some retrospective studies, large-breed dogs have been overrepresented.<sup>6-14</sup> In dogs, the etiology of spontaneously occurring leukemia is unknown. It is likely that genetic and environmental factors (including exposure to radiation, drugs, or toxic chemicals) play a role. In humans, acquired chromosomal derangements lead to clonal overgrowth with arrested development.<sup>15</sup> At the end of the last century, chromosomal abnormalities were reported in dogs with AML, chronic myelogenous leukemia (CML), and lymphoid leukemia.<sup>16,17</sup> However, because karyotyping is difficult to perform in dogs because of the large number and morphologic similarity of their chromosomes and their resistance to banding, defining genetic factors in canine myeloid neoplasms has awaited application of molecular technologies and use of the canine genome map.<sup>2,18-21</sup> Certain forms of leukemia in dogs have been

produced experimentally following irradiation.<sup>22-24</sup> In contrast to MPDs in cats, no causative viral agent has been demonstrated in dogs, although retrovirus-like budding particles were observed in the neoplastic cells of a dog with granulocytic leukemia.<sup>25</sup>

## Pathology and Natural Behavior

A review of normal hematopoiesis will aid in understanding the various manifestations of MPDs. Hematopoiesis is the process of proliferation, differentiation, and maturation of stem cells into terminally differentiated blood cells. A simplified scheme is presented in Figure 32-17. Pluripotent stem cells differentiate into either lymphopoietic or hematopoietic multipotent stem cells.<sup>26</sup> Under the influence of specific regulatory and microenvironmental factors, multipotent stem cells in bone marrow differentiate into progenitor cells committed to a specific hematopoietic cell line, for example, erythroid, granulocytic-monocytic, or megakaryocytic. Maturation results in the production of terminally differentiated blood cells—erythrocytes, granulocytes, monocytes, and platelets—that are delivered to the circulation. In some cases, as in the maturation of reticulocytes to erythrocytes, final development may occur in the spleen.

Proliferation and differentiation of hematopoietic cells are controlled by a group of regulatory growth factors.<sup>26,27</sup> Of these,



• **FIGURE 32-17** A simplified scheme of hematopoiesis. *BFU*, Blast-forming units; *CFU*, colony-forming units; *E*, erythroid; *GM*, granulocytic-monocytic; *EO*, eosinophil; *MEG*, megakaryocyte.

erythropoietin is the best characterized; it regulates erythroid proliferation and differentiation and is produced in the kidney, where changes in oxygen tension are detected. The myeloid compartment depends on a group of factors, collectively referred to as *colony-stimulating factors* (CSFs). These factors act at the level of the committed progenitor cells but also influence the functional capabilities of mature cells. Some of these factors have a broad spectrum of activity; others are more restricted in their target cells and actions. CSFs are produced in vitro by a multitude of cell types, including monocytes, macrophages, lymphocytes, and endothelial cells, and these cells likely play a role in the production and regulation of these factors in vivo. The gene for thrombopoietin also has been cloned, and it appears that this hormone alone can induce differentiation of megakaryocytes and platelet production.<sup>28</sup> Recombinant forms of many of these hormones are increasingly available.

Clonal disorders of bone marrow include myeloaplasia (usually referred to as *aplastic anemia*), myelodysplasia, and myeloproliferation. A preleukemic syndrome, characterized by peripheral pancytopenia and bone marrow hyperplasia with maturation arrest, is more correctly termed *myelodysplasia* because the syndrome does not always progress to overt leukemia. This syndrome has been described in cats, usually in association with FeLV infection but has only rarely been recognized in dogs.<sup>29-32</sup> These clonal disorders may be manifested by abnormalities in any or all lineages because hematopoietic cells share a common stem cell. In addition, transformation from one form to another may occur.<sup>33</sup>

Myeloid neoplasms are classified in several ways. The terms *acute* and *chronic* refer to the degree of cellular differentiation of the leukemic cells, but these terms also correlate with the biologic behavior of the neoplasm.<sup>34</sup> Disorders resulting from uncontrolled proliferation or decreased apoptosis of cells incapable of maturation lead to the accumulation of poorly differentiated or “blast” cells. These disorders are included under the umbrella term, *acute myeloid leukemia* (AML). Disorders resulting from unregulated proliferation of cells that exhibit progressive, albeit incomplete and defective, maturation lead to the accumulation of differentiated cells. These disorders are termed *myeloproliferative neoplasms* (MPN) and include polycythemia vera, CML and its variants, essential thrombocythemia, and possibly primary myelofibrosis. Myeloid neoplasms are further classified by the lineage of the dominant cell type(s), defined by Romanowsky stains, special cytochemical stains, ultrastructural features, flow cytometric analysis, and immunologic cell markers, and they have been classified into subtypes (see later discussion).

AML has a more sudden onset and is more aggressive. In both acute and chronic disorders, however, abnormalities in proliferation, maturation, and functional characteristics can occur in any hematopoietic cell line.<sup>1</sup> In addition, normal hematopoiesis is adversely affected. Animals with leukemia usually have decreased numbers of circulating normal cells. The pathogenesis of the cytopenias is complex and may result in part from production of inhibitory factors. Eventually, neoplastic cells displace normal hematopoietic cells, and this is termed *myelophthisis*. Anemia and thrombocytopenia are particularly common. Neutropenia and thrombocytopenia result in infection and hemorrhage, which may be more deleterious to the animal than the primary disease process.

## Acute Myeloid Leukemia

AML is rare and is characterized by aberrant proliferation and/or decreased apoptosis of a clone of cells without maturation. This results in accumulation of immature blast cells in bone marrow and

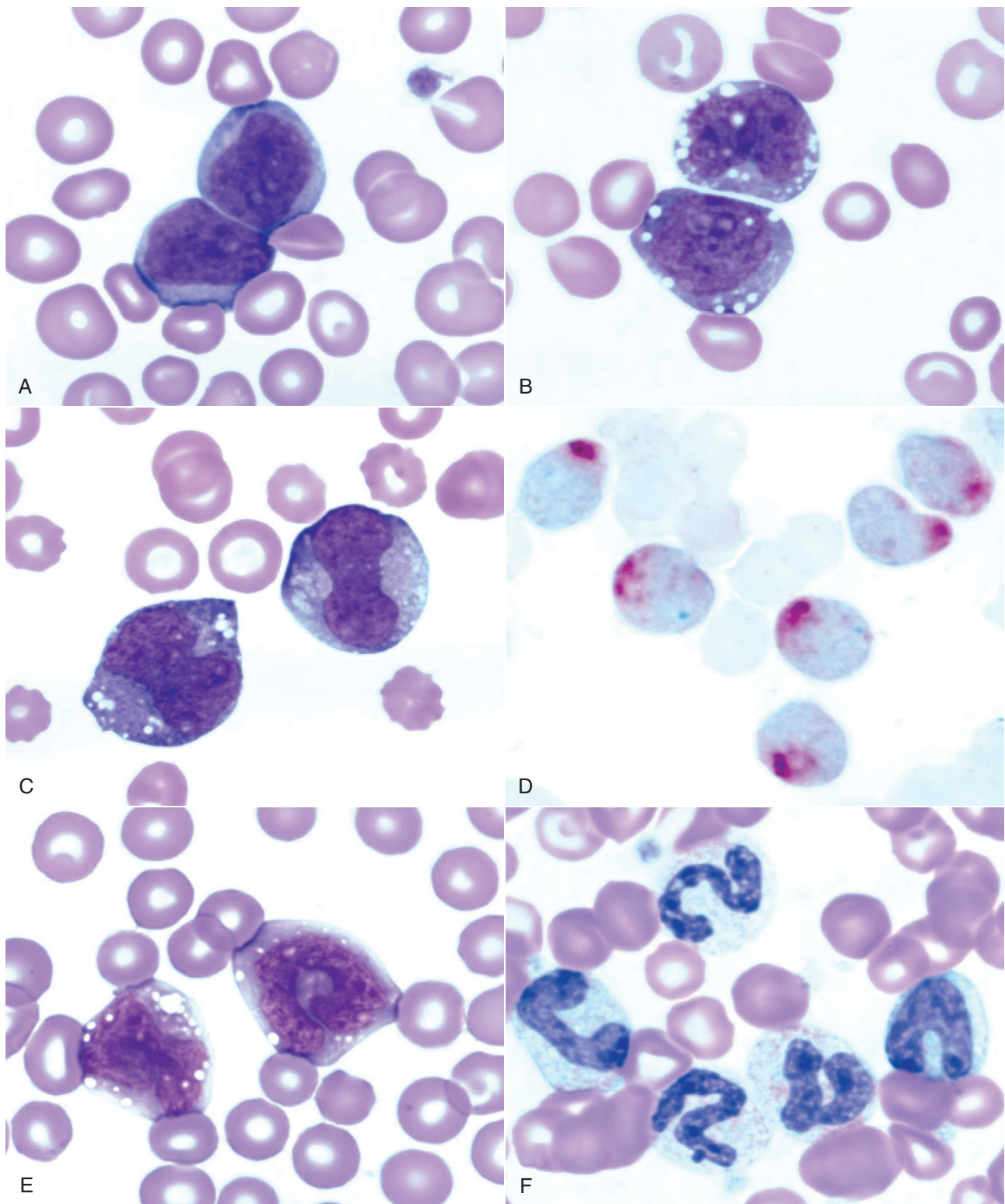
peripheral blood (Figure 32-18, A to E). The WBC count is variable and ranges from leukopenia to counts up to 150,000/ $\mu$ L. Spleen, liver, and lymph nodes are frequently involved, and other tissues, including tonsils, kidney, heart, and the CNS, may be infiltrated as well. There is no characteristic age, and even very young dogs may be affected.<sup>35</sup> The clinical course of these disorders tends to be rapid. Production of normal peripheral blood cells is usually diminished or absent, and anemia, neutropenia, and thrombocytopenia are common with infection and hemorrhage occurring as frequent sequelae. Occasionally, neoplastic blasts are present in bone marrow but not in peripheral blood. This is termed *aleukemic* leukemia, whereas *subleukemic* suggests a normal or decreased WBC count with some neoplastic cells in circulation.

In 1985 the Animal Leukemia Study Group was formed under the auspices of the American Society for Veterinary Clinical Pathology to develop specific morphologic and cytochemical criteria for classifying acute nonlymphocytic leukemias. Recognition of specific subtypes of leukemia is required to compile accurate and useful information about prognosis and response to treatment, as well as to compare studies from different sites. In 1991, this group proposed a classification system following adaptation of the French-American-British (FAB) system and criteria established by the NCI Workshop.<sup>3</sup> Group members examined blood and bone marrow from 49 dogs and cats with myeloid neoplasms. Romanowsky-stained specimens were examined first to identify blast cells and their percentages. Lineage specificity was then determined using cytochemical markers. The percentage of blasts and the information about lineage specificity were used in combination to classify disorders as acute undifferentiated leukemia (AUL), acute myeloid leukemia (AML, subtypes M1 to M5 and M7), and erythroleukemia with or without erythroid predominance (M6 and M6Er). A description of these subtypes is presented in Table 32-12.

Canine karyotyping is difficult, but with advancements in molecular cytogenetic analysis, chromosome painting, and genomic hybridization, AML in dogs can now be analyzed at the base-pair level,<sup>18,19</sup> and missense mutations in *FLT3*, *C-KIT*, and *RAS* sequences have been identified in dogs with AML, similar to what has been found for human AML.<sup>36</sup> In addition to serving as diagnostic and prognostic markers, cytogenetic lesions may be therapeutic targets. As cytogenetic abnormalities continue to be identified, this information will need to be incorporated into classification schemes.

With the exception of acute promyelocytic leukemia or M3, all of these subtypes have been described in dogs. However, because this modified FAB system has been adopted only recently, the names given to these disorders in the literature vary considerably. In addition, in the absence of cytochemical staining, immunophenotyping, or electron microscopic evaluation, the specific subtype of leukemia has often been uncertain, making retrospective analysis of epidemiologic information, prognosis, and response to therapy confusing at best. Although defining specific subtypes may seem to be an academic exercise owing to the uniformly poor prognosis of acute leukemias, this information is critical to improving the management of these diseases. Because of the low incidence of AML, national and international cooperative efforts will be required to accumulate information on the pathogenesis and response to different treatment modalities of specific subtypes. Utilization of a uniform classification system is an essential first step.

Different forms of AML are demonstrated in Figure 32-18, A to E. The most frequently reported forms of AML in the dog are acute myeloblastic leukemia (M1 and M2) and acute myelomonocytic



**FIGURE 32-18** Peripheral blood from dogs with myeloid neoplasms. All diagnoses were confirmed by cytochemical staining. Note how similar the blast cells appear in **A** to **C**. **A**, Acute myeloblastic leukemia (M1). (Wright's stain,  $\times 100$  objective.) **B**, Acute myelomonocytic leukemia (M4). (Wright's stain,  $\times 100$  objective.) **C**, Acute monocytic leukemia (M5a); Wright's stain. **D**, Acute monocytic leukemia (M5a). (Cytochemical stain: a-naphthyl butyrate esterase [nonspecific esterase] with red reaction product.) **E**, Acute monocytic leukemia with some differentiation (M5b). (Wright's stain,  $\times 100$  objective.) **F**, Chronic myelogenous leukemia (CML). (Wright's stain,  $\times 100$  objective.)



• **TABLE 32-12** Subtypes of Leukemias and Dysplasias Adapting the FAB System

SUBTYPE	DESCRIPTION
<b>Acute Leukemias</b>	
AUL	Acute undifferentiated leukemia (formerly called <i>reticuloendotheliosis</i> )
M1	Myeloblastic leukemia, without differentiation
M2	Myeloblastic leukemia, with some neutrophilic differentiation
M3	Promyelocytic leukemia (not recognized in animals)
M4	Myelomonocytic leukemia
M5a	Monocytic leukemia, without differentiation
M5b	Monocytic leukemia, with some monocytic differentiation
M6	Erythroleukemia
M6Er	Variant of M6, with erythroblasts constituting the erythroid component
M7	Megakaryoblastic leukemia
<b>Chronic Myeloid Leukemias</b>	
CML	Chronic myelogenous leukemia
CMML	Chronic myelomonocytic leukemia
CMoL	Chronic monocytic leukemia
<b>Hematopoietic Dysplasia</b>	
MDS	Myelodysplastic syndrome
MDS-Er	Myelodysplastic syndrome with erythroid predominance

leukemia (M4).<sup>\*</sup> Megakaryoblastic leukemia (M7) also is well recognized in dogs<sup>10,47-58</sup> and may be associated with platelet dysfunction.<sup>51</sup> Monocytic leukemias have likely included those with and without monocytic differentiation (M5a and M5b),<sup>11,59</sup> but in some cases the diagnosis may have been chronic myelomonocytic or chronic monocytic leukemia (see later discussion). There are few reports in dogs of spontaneously occurring erythroleukemia (M6) in which the leukemic cells include myeloblasts, monoblasts, and erythroid elements.<sup>60-62</sup> AULs have uncertain lineages because they are negative for all cytochemical markers. These leukemias should be distinguished from lymphoid leukemias by flow cytometric analysis of the leukemic cells for cellular antigens that identify their lineage.<sup>63</sup> In addition, examination of blast cells by electron microscopy may reveal characteristic ultrastructural features.

## Myeloproliferative Neoplasms

MPNs, previously termed *chronic myeloproliferative disorders*, are characterized by excessive production of differentiated bone marrow cells, resulting in the accumulation of erythrocytes (polycythemia vera), granulocytes and/or monocytes (CML and its variants), or platelets (essential thrombocythemia). Primary myelofibrosis as a clonal disorder of marrow stromal cells, characterized by proliferation of megakaryocytes and granulocytic precursors with accumulation of collagen in bone marrow, has been

recognized only rarely in animals. Myelofibrosis is considered a response to injury and may occur secondary to other neoplasms, systemic inflammation, drug exposure, or FeLV infection in cats.

## Polycythemia Vera

Polycythemia vera (PV) is a clonal disorder of stem cells, although whether the defect is in the pluripotent stem cell or the hematopoietic multipotent stem cell is still not clear. In humans, progenitor cells have an increased sensitivity to insulin-like growth factor 1, which stimulates hematopoiesis.<sup>64</sup> It is not known whether this hypersensitivity is the primary defect or is secondary to another gene mutation. In any case, the result is overproduction of red blood cells (RBCs). The disease is rare and must be distinguished from more common causes of polycythemia, including relative and secondary absolute polycythemia (see later discussion). In PV, there is neoplastic proliferation of the erythroid series with terminal differentiation to RBCs. The disease has been reported in dogs that tend to be middle-aged with no breed or sex predilection<sup>65-73</sup> and is characterized by an increased RBC mass evidenced by an increased packed cell volume (PCV), RBC count, and hemoglobin concentration. The PCV is typically in the range of 65% to 85%. The bone marrow is hyperplastic, although the myeloid:erythroid (M:E) ratio tends to be normal. In contrast to the disease in humans, other cell lines do not appear to be involved, and transformation to other MPNs has not been reported. The disease in dogs may be more appropriately termed *primary erythrocytosis*. In humans, acquired *JAK2* gene mutations are identified in 90% of patients with primary polycythemia, and recently an identical mutation in the *JAK2* gene of one of five dogs with primary polycythemia was reported.<sup>74</sup>

## Chronic Myelogenous Leukemia

In dogs, CML is more similar to chronic neutrophilic leukemia, a rare form of MPN in humans, than to CML in humans because it is a neoplastic proliferation of the neutrophil series, although concurrent eosinophilic and basophilic differentiation can occur. CML can occur in dogs of any age.<sup>35,75-79</sup> Neutrophils and neutrophilic precursors accumulate in bone marrow and peripheral blood as well as in other organs. The peripheral WBC count is usually, but not always, greater than 100,000/ $\mu$ L. Both immature and mature neutrophils are present, as demonstrated in Figure 32-18, F. Mature forms are usually more numerous, but sometimes an “uneven” left shift is present. Signs of dysplasia may be evident, including hypersegmentation, ringed nuclei, and giant forms. Eosinophils and basophils may also be increased. The bone marrow is characterized by granulocytic hyperplasia, and morphologic abnormalities may not be present. Erythroid and megakaryocytic lines may be affected, resulting in anemia, thrombocytopenia, or less commonly, thrombocytosis. This disorder must be distinguished from severe neutrophilic leukocytosis and “leukemoid reactions” caused by inflammation or immune-mediated diseases. Leukemoid reactions can also occur as a paraneoplastic syndrome. In humans with CML, characteristic cytogenetic abnormalities are present in all bone marrow cells, signifying a lesion at the level of an early multipotent stem cell. Typically, these individuals have a chromosomal translocation, resulting in the Philadelphia chromosome or BCR-ABL translocation between chromosomes 9 and 22.<sup>80</sup> The analogous chromosomes in dogs are chromosomes 9 and 26, and BCR-ABL mutations have now been reported in three cases of CML in dogs.<sup>2</sup> Variants of CML are chronic myelomonocytic leukemia (CMML) and chronic monocytic leukemia (CMoL).<sup>81-83</sup> These diagnoses are made based on the percentage of monocytes in the leukemic cell

\*References 5-9, 23-34, 37-46.

population. BCR-ABL translocation has also been reported in a dog with CMoL.<sup>45</sup>

In addition to accumulating in bone marrow and peripheral blood, leukemic cells also are found in the red pulp of the spleen, the periportal and sinusoidal areas of the liver, and sometimes lymph nodes. Other organs such as the kidney, heart, and lung are less commonly affected. In addition, extramedullary hematopoiesis may be present in the liver and spleen. Death is usually due to complications of infection or hemorrhage secondary to neutrophil dysfunction and thrombocytopenia. In some cases, CML may terminate in “blast crisis,” in which there is a transformation from a predominance of well-differentiated granulocytes to excessive numbers of poorly differentiated blast cells in peripheral blood and bone marrow. This phenomenon is well documented in the dog.<sup>75,76,78</sup>

### Basophilic and Eosinophilic Leukemia

Basophilic leukemia, although rare, has been reported in dogs and is characterized by an increased WBC count with a high proportion of basophils in peripheral blood and bone marrow.<sup>84-86</sup> Hepatosplenomegaly, lymphadenopathy, and thrombocytosis may be present. All the dogs have been anemic. Basophilic leukemia should be distinguished from mast cell leukemia (mastocytosis). Whether dogs develop eosinophilic leukemia remains in question. Reported cases have had high blood eosinophil counts and eosinophilic infiltrates in organs.<sup>87,88</sup> One dog responded well to treatment with corticosteroids. The distinction between neoplastic proliferation of eosinophils and idiopathic hypereosinophilic syndrome remains elusive. Disorders associated with eosinophilia such as parasitism, skin diseases, or diseases of the respiratory and GI tracts should be considered first in an animal with eosinophilia. One distinguishing feature should be clonality, with reactive eosinophilia comprising polyclonal cells and the neoplastic condition arising from a single clone. As clonality assays become more available, this discrepancy may be resolved.

### Essential Thrombocythemia

In humans, essential thrombocythemia, or primary thrombocytosis, is characterized by platelet counts that are persistently greater than 600,000/ $\mu$ L. There are no blast cells in circulation, and marked megakaryocytic hyperplasia of the bone marrow without myelofibrosis is present. Thrombosis and bleeding are the most common sequelae, and most patients have splenomegaly. Other MPDs, especially PV, should be ruled out, and importantly, there should be no primary disorders associated with reactive thrombocytosis.<sup>89</sup> These include inflammation, hemolytic anemia, iron deficiency anemia, malignancies, recovery from severe hemorrhage, rebound from immune-mediated thrombocytopenia, and splenectomy. In addition, certain drugs such as vincristine can induce thrombocytosis. Essential thrombocythemia has been recognized in dogs.<sup>33,90-93</sup> In one dog, the platelet count exceeded 4 million/ $\mu$ L and bizarre giant forms with abnormal granulation were present. The bone marrow contained increased numbers of megakaryocytes and megakaryoblasts, but circulating blast cells were not seen. Other findings included splenomegaly, GI bleeding, and increased numbers of circulating basophils. Causes of secondary or reactive thrombocytosis were ruled out.<sup>90</sup> Basophilia was also reported in a more recent case.<sup>92</sup> In another dog, primary thrombocytosis was diagnosed and then progressed to CML.<sup>33</sup> In some cases reported in the literature as essential thrombocythemia, the dogs had microcytic hypochromic anemias. Because iron deficiency anemia is associated with reactive or secondary thrombocytosis, care must be taken to rule

out this disorder. However, spurious microcytosis may be reported if a dog has many giant platelets that are counted by an analyzer as small RBCs.<sup>93</sup> Microscopic review of the blood film may be helpful in these cases.

## Other Bone Marrow Disorders

### Myelofibrosis

Primary myelofibrosis has been reported only rarely in dogs and is usually a secondary, or reactive, process.<sup>94,95</sup> In humans, myelofibrosis is characterized by collagen deposition in bone marrow and increased numbers of megakaryocytes and granulocytic precursors, many of which exhibit morphologic abnormalities. In fact, breakdown of intramedullary megakaryocytes and subsequent release of factors that promote fibroblast proliferation or inhibit collagen breakdown may be the underlying pathogenesis of the fibrosis.<sup>96</sup> Focal osteosclerosis is sometimes present. Anemia, thrombocytopenia, splenomegaly, and myeloid metaplasia (production of hematopoietic cells outside the bone marrow) are consistent features.

In dogs, myelofibrosis occurs secondary to MPDs, radiation damage, and congenital hemolytic anemias.<sup>97-100</sup> In some cases, the inciting cause is unknown (idiopathic myelofibrosis). There may be concurrent marrow necrosis in cases of ehrlichiosis, septicemia, or drug toxicity (estrogens, cephalosporins), and there is speculation that fibroblasts proliferate in response to release of inflammatory mediators associated with the necrosis.<sup>94</sup> Myeloid metaplasia has been reported to occur in the liver, spleen, and lung.<sup>100</sup> Extramedullary hematopoiesis is ineffective in preventing or correcting the pancytopenia that eventually develops.

### Myelodysplastic Syndrome

Dysfunction of the hematopoietic system can be manifested by a variety of abnormalities that constitute myelodysplastic syndrome (MDS). In dogs, in which the syndrome is rare, there usually are cytopenias in two or three lines in the peripheral blood (anemia, neutropenia, and/or thrombocytopenia). Other blood abnormalities can include macrocytic erythrocytes and metarubricytosis. The bone marrow is typically normocellular or hypercellular, and dysplastic changes are evident in several cell lines. If blast cells are present, they make up less than 30% of all nucleated cells,<sup>2</sup> although this threshold is being changed to less than 20%.<sup>4,20</sup> Myelodysplasia is sometimes referred to as *preleukemia* because, in some cases, it may progress to acute leukemia.<sup>29-31</sup> Based on reported cases, poor prognostic indices include increased percentage of blast cells, cytopenias involving more than one lineage, and cellular atypia. Primary MDSs are clonal disorders and are considered neoplastic. Complex classification schemes for human MDS, based on percentages of blasts in bone marrow, cytogenetic analysis, cytopenias, need for transfusions, and other variables, comprise at least nine subtypes; their applicability to veterinary medicine is unknown.<sup>5</sup> Three subtypes are proposed for dogs and cats and include MDS with excessive blasts (MDS-EB), in which blast percentages are greater than 5% and less than 20%, and progression to AML may occur; MDS with refractory cytopenia (MDS-RC) with blast percentages less than 5% and cytopenias in one or more lineages; and MDS with erythroid predominance (MDS-ER) in which the M:E ratio is less than 1 and prognosis is poor.<sup>4</sup> Larger studies are needed to determine the utility of this classification scheme and other potential prognostic indices, such as sex, age, and FeLV positivity. In addition to accumulating enough cases, another confounding factor to studying and classifying MDS is the presence of reversible MDS

that occur secondary to immune-mediated, infectious, and other diseases in both dogs and cats.

## History and Clinical Signs

Dogs with myeloid neoplasms have similar presentations regardless of the specific disease entity, although animals with AML have a more acute onset of illness and a more rapid clinical course. A history of lethargy, inappetence, and weight loss is common. Clinical signs include emaciation, persistent fever, pallor, petechiation, hepatosplenomegaly, and, less commonly, lymphadenopathy and enlarged tonsils. Shifting leg lameness, ocular lesions, and recurrent infections are also seen. Vomiting, diarrhea, dyspnea, and neurologic signs are variable features. Serum biochemical analytes may be within the reference intervals but can change if significant organ infiltration occurs. Animals with MDS may be lethargic and anorectic and have pallor, fever, and hepatosplenomegaly. In PV, dogs often have erythema of mucous membranes owing to the increase in RBC mass. Some dogs are polydipsic. In addition, neurologic signs such as disorientation, ataxia, or seizures may be present and are thought to be the result of hyperviscosity or hypervolemia.<sup>69</sup> Hepatosplenomegaly is usually absent.

Peripheral blood abnormalities are consistently found. In addition to the presence of neoplastic cells, other abnormalities, including cytopenias of any lineage, may be present. Low numbers of nucleated RBCs are present in the blood of about half the dogs with acute nonlymphocytic leukemia.<sup>3</sup> Nonregenerative anemia and thrombocytopenia are present in most cases. Anemia is usually normocytic and normochromic, although macrocytic anemia is sometimes present. Pathogenic mechanisms include effects of inhibitory factors leading to ineffective hematopoiesis, myelophthisis, immune-mediated anemia secondary to neoplasia, and hemorrhage secondary to thrombocytopenia, platelet dysfunction, or DIC. Anemia is most severe in AML, although both anemia and thrombocytopenia may be milder in animals with the M5 subtype (acute monocytic leukemia). In myelofibrosis, the anemia is characterized by anisocytosis and poikilocytosis. In addition, pancytopenia and leukoerythroblastosis, in which immature erythroid and myeloid cells are in circulation, may be present. These phenomena probably result from replacement of marrow by fibrous tissue with resultant shearing of red cells and escape of immature cells normally confined to bone marrow. In PV, the PCV is increased, usually in the range of 65% to 85%. The bone marrow is hyperplastic, and the M:E ratio is usually in the normal range.

Neoplastic cells are often defective functionally. Platelet dysfunction has been reported in a dog with acute megakaryoblastic leukemia (M7),<sup>51</sup> and in CML, neutrophils have decreased phagocytic capacity and other abnormalities. One exception to this was a report of CML in a dog in which the neutrophils had enhanced phagocytic capacity and superoxide production.<sup>101</sup> The authors hypothesized that increased synthesis of GM-CSF resulted from a lactoferrin deficiency in the neoplastic neutrophils and mediated the enhanced function of these cells.

## Diagnostic Techniques and Work-Up

In all cases of myeloid neoplasms, diagnosis depends on examination of peripheral blood and bone marrow. AML is diagnosed on the basis of finding blast cells with clearly visible nucleoli in blood and bone marrow. Most dogs with acute leukemia have circulating blasts. These cells may be present in low numbers in peripheral blood, and a careful search of the smear, especially at the feathered edge, should be made. Even if blasts are not detected in circulation, indications of bone marrow disease such as nonregenerative anemia

or thrombocytopenia are usually present. Occasionally, neoplastic cells can be found in cerebrospinal fluid in animals with invasion of the CNS. Smears of aspirates from tissues such as the lymph nodes, spleen, or liver may contain blasts but usually contribute little to the diagnostic work-up.

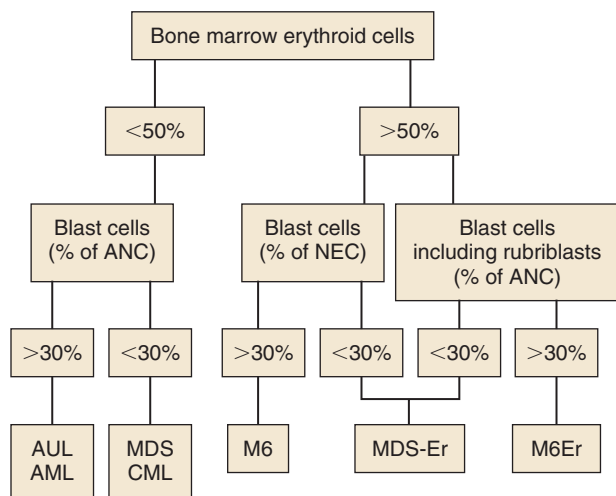
Examination of blasts stained with standard Romanowsky stains may give clues as to the lineage of the cells (Figure 32-18, A to C and E). In myelomonocytic leukemia, the nuclei of the blasts are usually pleomorphic, with round to lobulated forms. In some cells, the cytoplasm may contain large azurophilic granules or vacuoles. Blasts in megakaryocytic leukemia may contain vacuoles and have cytoplasmic blebs. In addition, bizarre macroplatelets may be present. Although these distinguishing morphologic features may suggest a definitive diagnosis, cytochemical staining or immunophenotyping are usually required to define the lineage of the blasts. Several investigators have reported modification of diagnoses following cytochemical staining.<sup>102,103</sup> It is especially important to distinguish AML from lymphocytic leukemia in order to provide accurate prognostic information to the owner and institute appropriate therapy.

The Animal Leukemia Group has recommended the following diagnostic criteria, summarized in Figure 32-19.<sup>3</sup> Using well-prepared Romanowsky-stained blood and bone marrow films, a minimum of 200 cells are counted to determine the leukocyte differential in blood and the percentage of blast cells in bone marrow and/or blood. In bone marrow, blast cells are calculated both as a percentage of all nucleated cells (ANC) and nonerythroid cells (NEC) and are further characterized using cytochemical markers.<sup>102-104</sup> Neutrophil differentiation is identified by positive staining of blasts for peroxidase, Sudan Black B, and chloracetate esterase. Nonspecific esterases (alpha-naphthyl acetate esterase or alpha-naphthyl butyrate esterase), especially if they are inhibited by sodium fluoride, mark monocytes. Canine monocytes may also contain a few peroxidase-positive granules. Acetylcholinesterase is a marker for megakaryocytes in dogs and cats. In addition, positive immunostaining for von Willebrand's factor (factor VIII-related antigen) and platelet glycoproteins on the surface of blasts identifies them as megakaryocyte precursors.<sup>10,49-53</sup> Alkaline phosphatase (AP) only rarely marks normal cells in dogs and cats but is present in blast cells in acute myeloblastic and myelomonocytic leukemias. However, owing to reports of AP activity in lymphoid leukemias in dogs, its specificity as a marker for myeloid cells is not certain. Omega exonuclease is a specific marker for basophils, which are also positive for chloracetate esterase activity.<sup>86</sup>

Blood and bone marrow differential counts and cytochemical staining should be performed and interpreted by experienced veterinary cytopathologists. If erythroid cells are less than 50% of ANC and the blast cells are greater than 30%, a diagnosis of AML or AUL is made. If erythroid cells are greater than 50% of ANC and the blast cells are greater than 30%, a diagnosis of erythroleukemia (M6) is made. If rubriblasts are a significant proportion of the blast cells, a diagnosis of M6Er, or erythroleukemia with erythroid predominance, can be made. It should be noted that in the human AML classification system, the blast threshold has been lowered to 20% and similar recommendations are being made for AML in dogs and cats.

In some cases, electron microscopy is required to identify the lineage of the blast cells. For example, megakaryocyte precursors are positive for platelet peroxidase activity and contain demarcation membranes and alpha granules.<sup>49,53</sup> Both of these features are detected at the ultrastructural level. Immunophenotyping, used to identify cell lineages in human patients, awaits development of





**FIGURE 32-19** A scheme to classify myeloid neoplasms and myelodysplastic syndromes in dogs and cats. (*Blast cells*, Myeloblasts, monoblasts, and megakaryoblasts; *ANC*, all nucleated cells in bone marrow, including lymphocytes, plasma cells, macrophages, and mast cells; *NEC*, nonerythroid cells in bone marrow; *AUL*, acute undifferentiated leukemia; *AML*, acute myeloid leukemias M1 to M5 and M7; *CML*, chronic myeloid leukemias, including chronic myelogenous, chronic myelomonocytic, and chronic monocytic leukemias; *MDS*, myelodysplastic syndrome; *MDS-Er*, myelodysplastic syndrome with erythroid predominance; *M6*, erythroleukemia; *M6Er*, erythroleukemia with erythroid predominance.) (From Jain NC, Blue JT, Grindem CB, et al: Proposed criteria for classification of acute myeloid leukemia in dogs and cats, *Vet Clin Pathol* 20(3):63–82, 1991.)

appropriate markers for animal species (see later). Increasingly, cytogenetic abnormalities are being identified in animal leukemias; cytogenetic analysis may yield important diagnostic and prognostic information and become a valuable tool for identifying targeted therapeutic approaches.

Although morphologic and cytochemical analyses have formed the mainstay of cell identification, newer technologies now are routinely used to classify leukemias by using monoclonal antibodies to detect antigens associated with certain cell types. Cells can be immunophenotyped using flow cytometric analysis or immunocytochemistry.<sup>20,63,105–108</sup> Cells from both acute lymphoid leukemia and AML are positive for CD34. Many lymphocyte markers, including CD3, CD4, CD8, CD18, CD21, CD45, CD79, and IgG, are available for dogs and can be used to rule out lymphoblastic leukemia in dogs with acute leukemias.<sup>63,105</sup> Other markers include myeloperoxidase (MPO) and CD11b for myeloid cells and CD41 for megakaryoblasts. There is some overlap in expression of these cellular antigens. For example, canine (but not human) granulocytes express CD4. It is best to use a panel of antibodies (similar to using a battery of cytochemical stains) because antigens are often expressed on multiple lineages, and lineage infidelity can occur. These tests have become more valuable with the availability of canine reagents. Currently, the ACVP Oncology Committee recommends that the following immunophenotyping panel be done on bone marrow and/or blood smears to characterize animal leukemias: for B lymphocytes, CD79a; for T lymphocytes, CD3; for myeloid cells, MPO and CD11b; for megakaryoblasts, CD41; for dendritic cells, CD1c; and for acute leukemias, CD34.<sup>20</sup>

Because of the degree of differentiation of cells in MPN, these disorders must be distinguished from nonneoplastic causes of

increases in these cell types. In order to make a diagnosis of PV, it must first be established that the polycythemia is absolute rather than relative. In relative polycythemias, plasma volume is decreased from hemoconcentration, dehydration, or hypovolemia, and the absolute RBC mass is not increased. Splenic contraction can also result in relative polycythemia. Absolute polycythemia, in which RBC mass is increased, is usually secondary to tissue hypoxia, causing appropriate increased production of erythropoietin. Rarely, erythropoietin may be produced inappropriately by a tumor (e.g., renal cell carcinoma) or in renal disease (pyelonephritis) or localized renal hypoxia.<sup>109–111</sup> These causes of polycythemia should be eliminated by appropriate laboratory work, thoracic radiographs, arterial blood gas analysis, and renal ultrasonography. In humans with PV, plasma erythropoietin (EPO) levels are low. EPO levels in dogs with PV tend to be low or low-normal, whereas in animals with secondary absolute polycythemia, the levels are high.<sup>112,113</sup> Samples for determination of EPO concentrations should be taken prior to therapeutic phlebotomy used to treat hyperviscosity and, owing to fluctuations in EPO levels, should be repeated if results are incongruous with other information.

There are no pathognomonic features of CML in dogs, and other common causes for marked leukocytosis with a left shift (“leukemoid reaction”) and granulocytic hyperplasia of bone marrow must be eliminated. These include infections, especially pyogenic ones; immune-mediated diseases; and other malignant neoplasms. In CML, maturation sometimes appears disorderly, and there may be variation in the size and shape of neutrophils at the same level of maturation. In addition, neoplastic leukocytes may disintegrate more rapidly and appear vacuolated.<sup>35</sup> Because of the invasive nature of CML, biopsy of liver or spleen may also help to distinguish true leukemia from a leukemoid reaction, assuming the animal can tolerate the procedure. If characteristic cytogenetic abnormalities can be found in dogs with CML, this analysis may be helpful.

Basophilic leukemia is diagnosed by finding excessive numbers of basophils in circulation and in bone marrow. Basophilic leukemia must be differentiated from mastocytosis based on the morphology of the cell type present. Basophils have a segmented nucleus and variably sized granules, whereas mast cells have a round-to-oval nucleus that may be partially or totally obscured by small, round, metachromatic-staining granules. This distinction is usually easy to make; however, in basophilic leukemia, changes in the morphology of the nucleus and granules make the distinction less clear.<sup>85</sup>

Essential thrombocythemia has been diagnosed based on finding persistent and excessive thrombocytosis (>600,000/ $\mu$ L) without circulating blast cells and in the absence of another MPD (e.g., PV), myelofibrosis, or disorders known to cause secondary thrombocytosis.<sup>89</sup> These include iron deficiency anemia, chronic inflammatory diseases, recovery from severe hemorrhage, rebound from immune-mediated thrombocytopenia, and absence of a spleen. Thrombocytosis is transient in these disorders or abates with resolution of the primary disease. In essential thrombocythemia, platelet morphology may be abnormal, with bizarre giant forms and abnormal granulation.<sup>90</sup> In the bone marrow, megakaryocytic hyperplasia is a consistent feature, and dysplastic changes may be evident in megakaryocytes.<sup>93</sup> Spurious hyperkalemia may be present in serum samples from dogs with thrombocytosis from any cause due to the release of potassium from platelets during clot formation.<sup>114</sup> Measuring potassium in plasma is recommended in these cases and usually demonstrates a potassium concentration within reference interval. Platelet aggregability has been

variably reported as impaired<sup>90</sup> or enhanced.<sup>93</sup> In the one dog in which it was measured, the plasma thrombopoietin (TPO) concentration was normal.<sup>92</sup> It is unclear whether TPO plays a role in essential thrombocythemia or is suppressed by the high platelet mass. Elucidation of the pathogenesis of this disorder should be aided by the recent cloning of the genes for thrombopoietin and its receptor, the proto-oncogene *mpl*.<sup>115</sup>

In MDS, abnormalities in two or three cell lines are usually manifested in peripheral blood as neutropenia with or without a left shift, nonregenerative anemia, or thrombocytopenia. Other changes include macrocytosis and metarubricytosis. The bone marrow is typically normocellular or hypercellular with an increased M:E ratio, and blasts cells, although increased, constitute less than 20% of nucleated cells; in a report of 13 dogs with primary or secondary MDS, in all but one dog the blast cell percentage was less than 20%.<sup>116</sup> Dysplastic changes can be detected in any cell line. Dyserythropoiesis is characterized by asynchronous maturation of erythroid cells typified by large hemoglobinized cells with immature nuclei (megaloblastic change). If the erythroid component is dominant, the MDS is called *MDS-Er* (see Table 32-12).<sup>3,32</sup> In dysgranulopoiesis, giant neutrophil precursors and abnormalities in nuclear segmentation and cytoplasmic granulation can be seen. Finally, dysthrombopoiesis is characterized by giant platelets and micromegakaryocytes.

Myelofibrosis should be suspected in animals with nonregenerative anemia or pancytopenia, abnormalities in erythrocyte morphology (especially shape), and leukoerythroblastosis. Bone marrow aspiration is usually unsuccessful, resulting in a “dry tap.” This necessitates a bone marrow biopsy taken with a Jamshidi needle.<sup>117</sup> The specimen is processed for routine histopathologic examination, and if necessary, special stains for fibrous tissue can be used. Because myelofibrosis occurs secondary to other diseases of bone marrow such as chronic hemolytic anemia or bone marrow necrosis, the clinician should look for a primary disease process.

## Treatment

### Acute Myeloid Leukemia

Treatment of acute nonlymphocytic leukemias has been unrewarding to date. However, we have little information on the response of specific subtypes of leukemia to uniform chemotherapeutic protocols, in part due to the rarity of these disease processes and the paucity of cases in the literature. The veterinarian is advised to contact a veterinary oncologist for advice on new protocols and appropriate management of these cases.

The therapeutic goal is to eradicate leukemic cells and reestablish normal hematopoiesis. Currently, this is best accomplished by cytoreductive chemotherapy, and the agents most commonly utilized include a combination of Ara-C plus an anthracycline, such as doxorubicin or cyclophosphamide, vincristine, and prednisone.\* In humans, the introduction of cytosine arabinoside has been the single most important development in the therapy of acute nonlymphocytic leukemia.<sup>120</sup> In dogs, Ara-C, 100 to 200 mg/m<sup>2</sup>, given by slow infusion (12 to 24 hrs) daily for 3 days and repeated weekly, has been used, as well as several other variations using subcutaneous injections of cytosine (see Chapter 11). Doxorubicin, 30 mg/m<sup>2</sup> IV every 2 to 3 weeks, can be administered at intervals alternating with Ara-C. If remission is achieved, as evidenced by normalization of the hemogram, the COAP protocol (cyclophosphamide, vincristine (Oncovin), Ara-C, and prednisone), as described for canine

• TABLE 32-13 Protocol for the Treatment of Acute Myeloproliferative Disorders

DRUG	DOSAGE	ROUTE
<b>Remission Induction</b>		
Cytosine arabinoside (Ara-C)	100 mg/m <sup>2</sup> /day	IV over 60 minutes every 12 hours
6-Thioguanine	40 mg/m <sup>2</sup>	PO for 4 days
Doxorubicin	10-15 mg/m <sup>2</sup>	IV daily for 3 days
<b>Maintenance</b>		
Ara-C	100 mg/m <sup>2</sup> /day	SQ or IV once or twice/week
6-Thioguanine	40 mg/m <sup>2</sup>	PO twice weekly
Doxorubicin	30 mg/m <sup>2</sup>	IV every 3 weeks

Data from Mears EA, Raskin RE, Legendre AM: Basophilic leukemia in a dog, *J Vet Intern Med* 11(2):92-94, 1997.  
IV, Intravenous; PO, by mouth; SQ, subcutaneous.

lymphoma, could be used as maintenance therapy.<sup>9,118</sup> Another protocol that has been used in treating acute myeloblastic leukemia is presented in Table 32-13.

Regardless of the chemotherapy protocol used, significant bone marrow suppression will develop, and intensive supportive care will be necessary. Transfusions of whole blood or platelet-rich plasma may be required to treat anemia and thrombocytopenia, and infection should be managed with aggressive antibiotic therapy. Because of the generally poor response, the major thrust of therapy may be to provide palliative supportive care.

### Polycythemia Vera

In treating PV, therapy is directed at reducing RBC mass. The PCV should be reduced to 50% to 60% or by one-sixth of its starting value; phlebotomies should be performed as needed, administering appropriate colloid and crystalloid solutions to replace lost electrolytes; 20 mL of whole blood/kg of body weight can be removed at regular intervals.<sup>67</sup> In humans, phlebotomy continues to be the therapeutic approach used most frequently.

Radiophosphorus (<sup>32</sup>P) has been shown to provide long-term control but can only be used in specialized centers.<sup>121</sup> The chemotherapeutic drug of choice is hydroxyurea, an inhibitor of DNA synthesis. This drug should be administered at an initial dose of 30 mg/kg for 10 days and then reduced to 15 mg/kg PO daily.<sup>69</sup> The major goal of treatment is to maintain the PCV as close to normal as possible.

### Chronic Myelogenous Leukemia

CML is best managed with chemotherapy to control the proliferation of the abnormal cell line and improve the quality of life. Hydroxyurea is the most effective agent for treating CML during the chronic phase.<sup>75,122</sup> The initial dosage is 20 to 25 mg/kg twice daily. Treatment with hydroxyurea should continue until the leukocyte count falls to 15,000 to 20,000 cells/ $\mu$ L.<sup>75,79,84</sup> Then the dosage of hydroxyurea can be reduced by 50% on a daily basis or to 50 mg/kg given biweekly or triweekly. In humans, the alkylating agent busulfan can be used as an alternative.<sup>123</sup> An effective dosage has not been established in the dog, but following human protocols, 0.1 mg/kg/day PO is given until the leukocyte count is reduced to 15,000 to 20,000 cells/ $\mu$ L.

\*References 9, 12, 29, 39, 118, 119.

Despite response to chemotherapy and control for many months, most dogs with CML will eventually enter a terminal phase of their disease. In one study of seven dogs with CML, four underwent terminal phase blast crisis.<sup>75</sup> In humans, blast crisis may be lymphoid or myeloid.<sup>124</sup> In dogs, it is usually difficult to determine the cell of origin. These dogs have a poor prognosis, and the best treatment to consider, if any, would be that listed in Table 32-13.

It has now been documented that a subset of CML in dogs may be associated with a BCR-ABL chromosomal abnormality (the so-called “Raleigh chromosome”) similar to the “Philadelphia chromosome” translocation responsible for a large majority of CML in humans.<sup>2</sup> While imatinib mesylate (Gleevec) is known to be an effective therapy for CML in humans, BCR-ABL kinase inhibitors have, as yet, not been investigated for this subset of CML in dogs.

### Essential Thrombocythemia

Few cases have been reported, but one dog was treated successfully with a combination chemotherapy protocol that included vincristine, Ara-C, cyclophosphamide, and prednisone.<sup>91</sup> Treatment is controversial in humans because of the lack of evidence that asymptomatic patients benefit from chemotherapy. Patients with thrombosis or bleeding are given cytoreductive therapy. Hydroxyurea is the drug of choice for initially controlling the thrombocytosis.<sup>89</sup>

### Myelodysplastic Syndrome

There is no standard therapeutic regime for MDS. Often, humans receive no treatment if the cytopenias do not cause clinical signs. Transfusions are given when necessary, and patients with fever are evaluated aggressively to detect infections. Growth factors, such as EPO, GM-CSF, G-CSF, and IL-3, are sometimes used in patients who require frequent transfusions to increase their blood cell counts and enhance neutrophil function.<sup>125,126</sup> In one case report, human EPO was administered (100 U/kg SQ, every 48 hours) to a dog with MDS because of profound anemia. The rationale for use of EPO was to promote terminal differentiation of dysplastic erythrocytes. The PCV increased from 12% to 34% by day 19 of EPO treatment. This dog remained in remission for more than 30 months.<sup>32</sup> Other factors that induce differentiation of hematopoietic cells include retinoic acid analogs,<sup>127</sup> 1,25 dihydroxyvitamin D<sub>3</sub>,<sup>128</sup> interferon- $\alpha$ , and conventional chemotherapeutic agents, such as 6-thioguanine and Ara-C.<sup>129</sup> The propensity of these factors to enhance progression to leukemia is not known in many cases, but the potential risk exists.

### Prognosis

In general, the prognosis for animals with MPN is better than for dogs with AML, in which it is grave. The prognosis for PV and CML is guarded, but significant remissions have been achieved with certain therapeutic regimes and careful monitoring. Animals commonly survive a year or more.<sup>75,84</sup> Development of blast crisis portends a grave prognosis.

### Comparative Aspects

The pathophysiology and therapy of nonlymphocytic leukemia in humans are being studied intensively. Myeloid neoplasms have been demonstrated to be clonal, with abnormalities evident in all hematopoietic cell lines. Leukemogenesis is likely caused by mutation or amplification of proto-oncogenes in a two-step process that initially involves a single cell and is followed by additional chromosomal alterations that may involve oncogenes.<sup>1,15</sup> These alterations are manifested as cytogenetic abnormalities. Environmental factors known to cause leukemia are exposure to high-dose radiation,

benzene (chronic exposure), and alkylating agents.<sup>130</sup> New classification systems have incorporated genetic mutations, more accurately reflect prognoses, and facilitate use of consistent categorization among institutions.<sup>131</sup>

Therapeutic modalities under investigation or development include combination chemotherapy, immunotherapy, cytokine therapy, drug-resistance modulators, proapoptotic agents, antiangiogenic factors, signal transduction-active agents, and bone marrow transplantation. The prognosis for MPN is better than for AML. For acute nonlymphocytic leukemias, the prognosis is better for children than adults, with only 10% of adults receiving chemotherapy maintaining remissions for more than 5 years.<sup>130</sup> The spontaneous canine diseases probably occur too infrequently to serve as useful models. Myeloid neoplasms have been induced experimentally in the dog by irradiation and transplantation in an attempt to create models for study. Many similarities between human and canine myeloid neoplasms exist, and veterinary medicine may benefit from any therapeutic advances made in the human field.

### REFERENCES

- Lichtman MA: Classification and clinical manifestations of the clonal myeloid disorders. In: Lichtman MA, Kipps TJ, Seligsohn U, et al, editors: *Williams hematology*, ed 8, New York, 2010, McGraw-Hill. <http://www.accessmedicine.com/content.aspx?aID=6121127>. Accessed December 23, 2011.
- Breen M, Modiano JF: Evolutionarily conserved cytogenetic changes in hematologic malignancies of dogs and humans—man and his best friend share more than companionship. *Chromosome Res* 16(1):145–154, 2008.
- Jain NC, Blue JT, Grindem CB, et al: A report of the animal leukemia study group. Proposed criteria for classification of acute myeloid leukemia in dogs and cats. *Vet Clin Pathol* 20(3):63–82, 1991.
- Juopperi TA, Bienzle D, Bernreuter DC, et al: Prognostic markers for myeloid neoplasms: a comparative review of the literature and goals for future investigation. *Vet Pathol* 48(1):182–197, 2011.
- Nielsen SW: Myeloproliferative disorders in animals. In Clarke WJ, Howard EB, Hackett PL, editors: *Myeloproliferative disorders in animals and man*, Oak Ridge, Tenn, 1970, USAEC Division of Technical Information Extension.
- Christopher MM, Metz AL, Klausner J, et al: Acute myelomonocytic leukemia with neurologic manifestations in the dog. *Vet Pathol* 23(2):140–147, 1986.
- Keller P, Sager P, Freudiger U, et al: Acute myeloblastic leukemia in a dog. *J Comp Pathol* 95(4):619–632, 1985.
- Clark P, Swenson CL, Drenen CM: A 6-year-old Rottweiler with weight loss. *Aust Vet J* 75(10):709, 714–715, 1997.
- Graves TK, Swenson CL, Scott MA: A potentially misleading presentation and course of acute myelomonocytic leukemia in a dog. *J Am Anim Hosp Assoc* 33:37–41, 1997.
- Colbatzy F, Hermanns W: Acute megakaryoblastic leukemia in one cat and two dogs. *Vet Pathol* 30(2):186–194, 1993.
- Latimer KS, Dykstra MJ: Acute monocytic leukemia in a dog. *J Am Vet Med Assoc* 184:852–854, 1984.
- Hamlin RH, Duncan RC: Acute nonlymphocytic leukemia in a dog. *J Am Vet Med Assoc* 196:110–112, 1990.
- Grindem CB, Stevens JB, Perman V: Morphologic classification and clinical and pathological characteristics of spontaneous leukemia in 17 dogs. *J Am Anim Hosp Assoc* 21:219–226, 1985.
- Modiano JF, Smith R III, Wojcieszyn J, et al: The use of cytochemistry, immunophenotyping, flow cytometry, and in vitro differentiation to determine the ontogeny of a canine monoblastic leukemia. *Vet Clin Pathol* 27:40–49, 1998.
- Jandl JH: Hematopoietic malignancies. In *Blood: pathophysiology*, Boston, 1991, Blackwell Scientific Publications.



16. Grindem CB, Buoen LC: Cytogenetic analysis of leukemic cells in the dog: A report of 10 cases and a review of the literature, *J Comp Pathol* 96:623–635, 1986.
17. Reimann N, Bartnitzke S, Bullerdiek J, et al: Trisomy 1 in a canine acute leukemia indicating the pathogenetic importance of polysomy 1 in leukemias of the dog, *Cancer Genet Cytogenet* 101:49–52, 1997.
18. Breen M: Canine cytogenetics—from band to base pair, *Cytogenet Genome Res* 120(1-2):50–60, 2008.
19. Breen M: Update on genomics in veterinary oncology, *Top Companion Anim Med* 24(3):113–121, 2009.
20. McManus PM: Classification of myeloid neoplasms: a comparative review, *Vet Clin Pathol* 34:189–212, 2005.
21. Reimann N, Bartnitzke S, Nolte I, et al: Working with canine chromosomes: current recommendations for karyotype description, *J Hered* 90:31–34, 1999.
22. Anderson AC, Johnson RM: Erythroblastic malignancy in a beagle, *J Am Vet Med Assoc* 141:944–946, 1962.
23. Seed TM, Tolle DV, Fritz TE, et al: Irradiation-induced erythroleukemia and myelogenous leukemia in the beagle dog: Hematology and ultrastructure, *Blood* 50:1061–1079, 1977.
24. Tolle DV, Seed TM, Fritz TE, et al: Acute monocytic leukemia in an irradiated beagle, *Vet Pathol* 16:243–254, 1979.
25. Sykes GP, King JM, Cooper BC: Retrovirus-like particles associated with myeloproliferative disease in the dog, *J Comp Pathol* 95(4):559–564, 1985.
26. Quesenberry PJ: Hemopoietic stem cells, progenitor cells, and cytokines. In Beutler E, Lichtman MA, Coller BS, et al, editors: *Williams hematology*, ed 5. New York, 1995, McGraw-Hill.
27. Metcalf D: *The hemopoietic colony stimulating factors*, New York, 1984, Elsevier.
28. Lok S, Kaushansky K, Holly RD, et al: Cloning and expression of murine thrombopoietin cDNA and stimulation of platelet production in vivo, *Nature* 369:565–568, 1994.
29. Couto CG, Kallet AJ: Preleukemic syndrome in a dog, *J Am Vet Med Assoc* 184:1389–1392, 1984.
30. Couto CG: Clinicopathologic aspects of acute leukemias in the dog, *J Am Vet Med Assoc* 186(7):681–685, 1985.
31. Weiss DJ, Raskin R, Zerbe C: Myelodysplastic syndrome in two dogs, *J Am Vet Med Assoc* 187(10):1038–1040, 1985.
32. Boone LI, Knauer KW, Rapp SW, et al: Use of human recombinant erythropoietin and prednisone for treatment of myelodysplastic syndrome with erythroid predominance in a dog, *J Am Vet Med Assoc* 213(7):999–1001, 1998.
33. Degen MA, Feldman BF, Turrel JM, et al: Thrombocytosis associated with a myeloproliferative disorder in a dog, *J Am Vet Med Assoc* 194(10):1457–1459, 1989.
34. Evans JR, Gorman NT: Myeloproliferative disease in the dog and cat: Definition, aetiology and classification, *Vet Rec* 121:437–443, 1987.
35. Jain NC: The leukemia complex. In *Schalch's veterinary hematology*, ed 4, Philadelphia, 1986, Lea & Febiger.
36. Usher SG, Radford AD, Villiers EJ, et al: RAS, FLT3, and C-KIT mutations in immunophenotyped canine leukemias, *Exp Hematol* 37(1):65–77, 2009.
37. Barthel CH: Acute myelomonocytic leukemia in a dog, *Vet Pathol* 11:79–86, 1974.
38. Green RA, Barton CL: Acute myelomonocytic leukemia in a dog, *J Am Anim Hosp Assoc* 13:708–712, 1977.
39. Jain NC, Madewell BR, Weller RE, et al: Clinical-pathological findings and cytochemical characterizations of myelomonocytic leukaemia in 5 dogs, *J Comp Pathol* 91:17–31, 1981.
40. Linnabary RD, Holscher MA, Glick AD, et al: Acute myelomonocytic leukemia in a dog, *J Am Anim Hosp Assoc* 14:71–75, 1978.
41. Moulton JE, Dungworth DL: Tumors of the lymphoid and hemopoietic tissues. In Moulton JE, editor: *Tumors in domestic animals*, ed 2, Berkeley, 1978, University of California Press.
42. Ragan HA, Hackett PL, Dagle GE: Acute myelomonocytic leukemia manifested as myelophthistic anemia in a dog, *J Am Vet Med Assoc* 169:421–425, 1976.
43. Rohrig KE: Acute myelomonocytic leukemia in a dog, *J Am Vet Med Assoc* 182:137–141, 1983.
44. Madewell BR, Jain NC, Munn RJ: Unusual cytochemical reactivity in canine acute myeloblastic leukemia, *Comp Haematol Int* 1(2):117–120, 1991.
45. Hayashi A, Tanaka H, Kitamura M, et al: Acute myelomonocytic leukemia (AML-M4) in a dog with the extradural lesion, *J Vet Med Sci* 73:419–422, 2011.
46. Hisasue M, Nishimura T, Neo S, et al: A dog with acute myelomonocytic leukemia, *J Vet Med Sci* 70:619–621, 2008.
47. Holscher MA, Collins RD, Glick AD, et al: Megakaryocytic leukemia in a dog, *Vet Pathol* 15:562–565, 1978.
48. Canfield PJ, Church DB, Russ IG: Myeloproliferative disorder involving the megakaryocytic line, *J Small Anim Pract* 34(6):296–301, 1993.
49. Bolon B, Buergelt CD, Harvey JW, et al: Megakaryoblastic leukemia in a dog, *Vet Clin Pathol* 18(3):69–72, 1989.
50. Shull RM, DeNovo RC, McCracken MD: Megakaryoblastic leukemia in a dog, *Vet Pathol* 23(4):533–536, 1986.
51. Cain GR, Feldman BF, Kawakami TG, et al: Platelet dysplasia associated with megakaryoblastic leukemia in a dog, *J Am Vet Med Assoc* 188(5): 529–530, 1986.
52. Cain GR, Kawakami TG, Jain NC: Radiation-induced megakaryoblastic leukemia in a dog, *Vet Pathol* 22(6):641–643, 1985.
53. Mesick J, Carothers M, Wellman M: Identification and characterization of megakaryoblasts in acute megakaryoblastic leukemia in a dog, *Vet Pathol* 27(3):212–214, 1990.
54. Comazzi S, Gelain ME, Belfanti U, et al: Acute megakaryoblastic leukemia in a dog : a report of 3 cases and review of the literature, *J Am Anim Hosp Assoc* 46:327–335, 2010.
55. Willan M, Mulaire L, Schwendenwein I, et al: Chemotherapy in canine acute megakaryoblastic leukemia: a case report and review of the literature, *In Vivo* 23:911–918, 2009.
56. Ferreira HM, Smith SH, Schwartz AM, et al: Myeloperoxidase-positive acute megakaryoblastic leukemia in a dog, *Vet Clin Pathol* 40:530–537, 2011.
57. Suter SE, Vernau W, Fry MM, et al: CD34+, CD41+ acute megakaryoblastic leukemia in a dog, *Vet Clin Pathol* 36:288–292, 2007.
58. Park HM, Doster AR, Tashbaeva RE, et al: Clinical, histopathological and immunohistochemical findings in a case of megakaryoblastic leukemia in a dog, *J Vet Diagn Invest* 18:287–291, 2006.
59. Mackey LJ, Jarrett WFH, Lauder IM: Monocytic leukaemia in the dog, *Vet Rec* 96:27–30, 1975.
60. Capelli JL: Erythroleukemia in a dog, *Pratique Medicale and Chirurgicale de l'Animal de Compagnie* 26(4):337–340, 1990.
61. Hejlasz Z: Three cases of erythroleukemia in dogs, *Medycyna Weterynaryjna* 42(6):346–349, 1986.
62. Tomiyasu H, Fujino Y, Takahashi M, et al: Spontaneous erythroblastic leukaemia (AML-M6Er) in a dog, *J Small Anim Pract* 52:445–457, 2011.
63. Grindem CB: Blood cell markers, *Vet Clin North Am* 26(5):1043–1064, 1996.
64. Prchal J: Primary polycythemia. In Adamson JW, editor: *Current opinion in hematology*, Philadelphia, 1995, Current Science.
65. Bush BM, Fankhauser R: Polycythaemia vera in a bitch, *J Small Anim Pract* 13:75–89, 1972.
66. Carb AV: Polycythemia vera in a dog, *J Am Vet Med Assoc* 154:289–297, 1969.
67. McGrath CJ: Polycythemia vera in dogs, *J Am Vet Med Assoc* 164:1117–1122, 1974.
68. Miller RM: Polycythemia vera in a dog, *Vet Med/Small Anim Clin* 63:222–223, 1968.
69. Peterson ME, Randolph JK: Diagnosis of canine primary polycythemia and management with hydroxy-urea, *J Am Vet Med Assoc* 180:415–418, 1982.

70. Quesnal AD, Kruth SA: Polycythemia vera and glomerulonephritis in a dog, *Can Vet J* 33(10):671–672, 1992.
71. Meyer HP, Slappendel RJ, Greydanus-van-der-Putten SWM: Polycythaemia vera in a dog treated by repeated phlebotomies, *Vet Q* 15(3):108–111, 1993.
72. Wysoke JM, Van Heerden J: Polycythaemia vera in a dog, *J S Afr Vet Assoc* 61(4):182–183, 1990.
73. Holden AR: Polycythaemia vera in a dog, *Vet Rec* 120(20):473–475, 1987.
74. Beurlet S, Krief P, Sansonetti A, et al: identification of JAK2 mutations in canine primary polycythemia, *Exp Hematol* 39:542–545, 2011.
75. Leifer CE, Matus RE, Patnaik AK, et al: Chronic myelogenous leukemia in the dog, *J Am Vet Med Assoc* 183:686–689, 1983.
76. Pollet L, Van Hove W, Matheeuws D: Blastic crisis in chronic myelogenous leukaemia in a dog, *J Small Anim Pract* 19:469–475, 1978.
77. Grindem CB, Stevens JB, Brost DR, et al: Chronic myelogenous leukaemia with meningeal infiltration in a dog, *Comp Haematol Int* 2(3):170–174, 1992.
78. Dunn JK, Jeffries AR, Evans RJ, et al: Chronic granulocytic leukaemia in a dog with associated bacterial endocarditis, thrombocytopenia and preretinal and retinal hemorrhages, *J Small Anim Pract* 28(11):1079–1086, 1987.
79. Fine DM, Tvedten HW: Chronic granulocytic leukemia in a dog, *J Am Vet Med Assoc* 214(2):1809–1812, 1999.
80. Liesveld JL, Lichtman MA: Chronic myelogenous leukemia and related disorders. In Lichtman MA, Kipps TJ, Seligsohn U, et al, editors. *Williams hematology*, ed 8, New York, 2010, McGraw-Hill.
81. Cruz Cardona JA, Milner R, Alleman AR: BCR-ABL translocation in a dog with chronic monocytic leukemia, *Vet Clin Pathol* 40(1):40–47, 2011.
82. Rossi G, Gelain ME, Foroni S, et al: Extreme monocytosis in a dog with chronic monocytic leukaemia, *Vet Rec* 165:54–56, 2009.
83. Hiraoka H, Hisasue M, Nagashima N, et al: A dog with myelodysplastic syndrome: chronic myelomonocytic leukemia, *J Vet Med Sci* 69:665–668, 2007.
84. MacEwen EG, Drazner FH, McClellan AJ, et al: Treatment of basophilic leukemia in a dog, *J Am Vet Med Assoc* 166:376–380, 1975.
85. Mahaffey EA, Brown TP, Duncan JR, et al: Basophilic leukemia in a dog, *J Comp Pathol* 97(4):393–399, 1987.
86. Mears EA, Raskin RE, Legendre AM: Basophilic leukemia in a dog, *J Vet Intern Med* 11(2):92–94, 1997.
87. Jensen AL, Nielsen OL: Eosinophilic leukemoid reaction in a dog, *J Small Anim Pract* 33(7):337–340, 1992.
88. Ndiukuwera J, Smith DA, Obwolo MJ, et al: Chronic granulocytic leukaemia/eosinophilic leukaemia in a dog, *J Small Anim Pract* 33(11):553–557, 1992.
89. Beer PA, Green AR: Essential thrombocythemia. In Lichtman MA, Kipps TJ, Seligsohn U, et al, editors. *Williams hematology*, ed 8, New York, 2010, McGraw-Hill. <http://www.accessmedicine.com/content.aspx?aID=6136261>. Accessed December 23, 2011.
90. Hopper PE, Mandell CP, Turrel JM, et al: Probable essential thrombocythemia in a dog, *J Vet Intern Med* 3(2):79–85, 1989.
91. Simpson JW, Else RW, Honeyman P: Successful treatment of suspected essential thrombocythemia in the dog, *J Small Anim Pract* 31(7):345–348, 1990.
92. Bass MC, Schultze AE: Essential thrombocythemia in a dog: Case report and literature review, *J Am Anim Hosp Assoc* 34:197–203, 1998.
93. Dunn JK, Heath MF, Jeffries AR, et al: Diagnostic and hematologic features of probable essential thrombocythemia in two dogs, *Vet Clin Pathol* 28(4):131–138, 1999.
94. Reagan WJ: A review of myelofibrosis in dogs, *Toxicol Pathol* 21(2):164–169, 1993.
95. Weiss DJ: A retrospective study of the incidence and the classification of bone marrow disorders in the dog at a veterinary teaching hospital (1996–2004), *J Vet Intern Med* 20(4):955–961, 2006.
96. Castro-Malaspina H: Pathogenesis of myelofibrosis: Role of ineffective megakaryopoiesis and megakaryocyte components. In Berk PD, Castro-Malaspina H, Wasserman LR, editors: *Myelofibrosis and the biology of connective tissue*, New York, 1984, Alan R. Liss.
97. Rudolph R, Huebner C: Megakaryozytenleukose beim hund, *Kleintier-Praxis* 17:9–13, 1972.
98. Dungworth DL, Goldman M, Switzer JW, et al: Development of a myeloproliferative disorder in beagles continuously exposed to <sup>90</sup>Sr, *Blood* 34:610–632, 1969.
99. Prasse KW, Crouser D, Beutler E, et al: Pyruvate kinase deficiency anemia with terminal myelofibrosis and osteosclerosis in a beagle, *J Am Vet Med Assoc* 166:1170–1175, 1975.
100. Thompson JC, Johnstone AC: Myelofibrosis in the dog: Three case reports, *J Small Anim Pract* 24(9):589–601, 1983.
101. Thomsen MK, Jensen AL, Skak-Nielsen T, et al: Enhanced granulocyte function in a case of chronic granulocytic leukemia in a dog, *Vet Immunol Immunopathol* 28(2):143–165, 1991.
102. Grindem CB, Stevens JB, Perman V: Cytochemical reactions in cells from leukemic dogs, *Vet Pathol* 23:103–109, 1986.
103. Facklam NR, Kociba GJ: Cytochemical characterization of leukemic cells from 20 dogs, *Vet Pathol* 22:363–369, 1986.
104. Goldman EE, Graham JC: Clinical diagnosis and management of acute nonlymphoid leukemias and chronic myeloproliferative disorders. In Feldman BF, Zinkl JG, Jain NC, editors: *Schalm's veterinary hematology*, ed 5, Philadelphia, 2000, Lippincott Williams & Wilkins.
105. Cobbold S, Metcalfe S: Monoclonal antibodies that define canine homologues of human CD antigens: Summary of the First International Canine Leukocyte Antigen Workshop (CLAW), *Tissue Antigens* 43(3):137–154, 1994.
106. Tasca C, Carli E, Caldin M, et al: Hematologic abnormalities and flow cytometric immunophenotyping results in dogs with hematopoietic neoplasia: 210 cases (2002–2006), *Vet Clin Pathol* 38:2–12, 2009.
107. Villiers E, Baines S, Law AM, et al: Identification of acute myeloid leukemia in dogs using flow cytometry with myeloperoxidase, MAC387, and a canine neutrophil-specific antibody, *Vet Clin Pathol* 35:55–71, 2006.
108. Comazzi S, Gelain ME, Spagnolo V, et al: Flow cytometric patterns in blood from dogs with non-neoplastic and neoplastic hematologic diseases using double labeling for CD18 and CD45, *Vet Clin Pathol* 35:47–54, 2006.
109. Peterson ME, Zanjani ED: Inappropriate erythropoietin production from a renal carcinoma in a dog with polycythemia, *J Am Vet Med Assoc* 179:995–996, 1981.
110. Scott RC, Patnaik AK: Renal carcinoma associated with secondary polycythemia in a dog, *J Am Anim Hosp Assoc* 8:275–283, 1972.
111. Waters DJ, Prueter JC: Secondary polycythemia associated with renal disease in the dog: Two case reports and review of literature, *J Am Anim Hosp Assoc* 24:109–114, 1988.
112. Cook SM, Lothrop CD: Serum erythropoietin concentrations measured by radioimmunoassay in normal, polycythemic, and anemic dogs and cats, *J Vet Intern Med* 8(1):18–25, 1994.
113. Giger U: Serum erythropoietin concentrations in polycythemic and anemic dogs. *Proceedings of the 9th Annual Vet Med Forum (ACVIM)*, 1991, pp. 143–145.
114. Reimann KA, Knowlen CG, Tvedten HW: Factitious hyperkalemia in dogs with thrombocytosis, *J Vet Intern Med* 3:47–52, 1989.
115. Kaushansky K: Thrombopoietin: The primary regulator of platelet production, *Blood* 86(2):419–431, 1995.
116. Weiss DJ, Aird B: Cytologic evaluation of primary and secondary myelodysplastic syndromes in the dog, *Vet Clin Pathol* 30:67–75, 2001.
117. Friedrichs KR, Young KM: How to collect diagnostic bone marrow samples, *Vet Med* 8:578–588, 2005.
118. Theilen GH, Madewell BR, Gardner MB: Hematopoietic neoplasms, sarcomas and related conditions. In Theilen GH, Madewell BR,

- editors: *Veterinary cancer medicine*, ed 2, Philadelphia, 1987, Lea & Febiger.
119. Gorman NT, Evans RJ: Myeloproliferative disease in the dog and cat: Clinical presentations, diagnosis and treatment, *Vet Rec* 121:490–496, 1987.
  120. Mayer RJ: Current chemotherapeutic treatment approaches to the management of previously untreated adults with de novo acute myelogenous leukemia, *Semin Oncol* 14:384–396, 1987.
  121. Smith M, Turrel JM: Radiophosphorus (<sup>32</sup>P) treatment of bone marrow disorders in dogs: 11 cases (1970–1987), *J Am Vet Med Assoc* 194:98–102, 1982.
  122. Lyss AP: Enzymes and random synthetics. In Perry MC, editor: *The chemotherapy source book*, Baltimore, 1992, Williams & Wilkins, pp. 398–412.
  123. Bolin RW, Robinson WA, Sutherland J, et al: Busulfan versus hydroxyurea in long-term therapy of chronic myelogenous leukemia, *Cancer* 50:1683–1686, 1982.
  124. Rosenthal S, Canellos GP, Whang-Pang J, et al: Blast crisis of chronic granulocytic leukemia: Morphologic variants and therapeutic implications, *Am J Med* 63:542–547, 1977.
  125. Liesveld JL, Lichtman MA: Myelodysplastic syndromes (clonal cytopenias and oligoblastic myelogenous leukemia). In Lichtman MA, Kipps TJ, Seligsohn U, et al, editors. *Williams hematology*, ed 8, New York, 2010, McGraw-Hill. <http://www.accessmedicine.com/content.aspx?aID=6139818>. Accessed December 23, 2011.
  126. Ganser A, Hoelzer D: Treatment of myelodysplastic syndromes with hematopoietic growth factors, *Hematol Oncol Clin North Am* 6:633–653, 1992.
  127. Ohno R, Noe T, Hirano M, et al: Treatment of myelodysplastic syndromes with all-trans retinoic acid, *Blood* 81:1152–1154, 1993.
  128. Kelsey SM, Newland AC, Cunningham J, et al: Sustained haematological response to high dose oral alfacalcidol in patients with myelodysplastic syndrome [Letter], *Lancet* 340:316, 1992.
  129. Jacobs A: Treatment for the myelodysplastic syndromes, *Hematologica* 72:477–480, 1987.
  130. Liesveld JL, Lichtman MA: Acute myelogenous leukemia. In Lichtman MA, Kipps TJ, Seligsohn U, et al, editors. *Williams hematology*, ed 8, New York, 2010, McGraw-Hill. <http://www.accessmedicine.com/content.aspx?aID=6140629>. Accessed December 23, 2011.
  131. Vardiman JW, Thiele J, Arber DA, et al: The 2008 revision of the World Health Organization (WHO) classification of the myeloid neoplasms and acute leukemia: rationale and important changes, *Blood* 114(5):937–951, 2009.

## SECTION D

### Myeloma-Related Disorders

DAVID M. VAIL

Myeloma-related disorders (MRDs) arise when a cell of the plasma cell or immunoglobulin-producing B-lymphocyte precursor lineage transforms and proliferates to form a neoplastic population of similar cells. This population is believed in most instances to be monoclonal (i.e., derived from a single cell) because they typically produce homogenous immunoglobulin, although some examples of biclonal and polyclonal MRD neoplasms exist. A wide variety of clinical syndromes are represented by MRDs, including multiple myeloma (MM), extramedullary plasmacytoma (EMP [both cutaneous and noncutaneous]), IgM (Waldenström's) macroglobulinemia, solitary osseous plasmacytoma (SOP), and Ig-secreting lymphomas and leukemias (including plasma cell leukemia). MM is the most important MRD based on clinical incidence and severity. There appears to be some discordance and

blurring of the distinction between MM and multicentric noncutaneous EMP in cats and these two MRDs will be discussed together in this species.

## Multiple Myeloma

### Incidence and Etiology

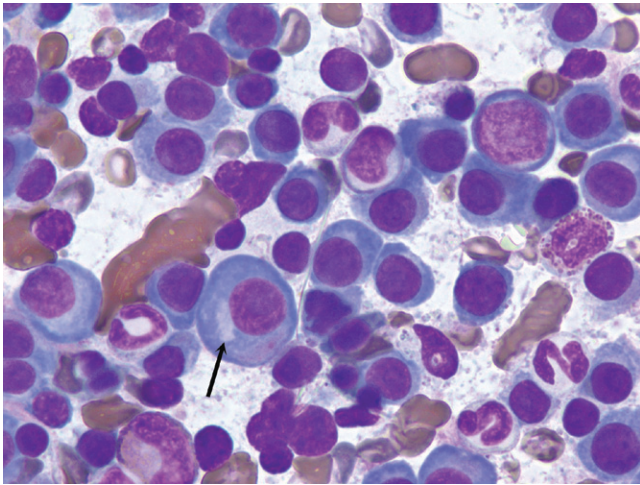
Although MM represents less than 1% of all malignant tumors in animals, it is responsible for approximately 8% of all hematopoietic tumors and 3.6% of all primary and secondary tumors affecting bone in dogs.<sup>1,2</sup> In a compilation of bone marrow disorders in dogs (n = 717), MM represented 4.4% and 19.8% of all abnormal samples and neoplastic processes, respectively.<sup>3</sup> Further, in a compilation of serum protein electrophoretic samples (n = 147 dogs), MM accounted for 4.3% of abnormal and 28.5% of neoplastic processes encountered, respectively.<sup>4</sup> Early studies suggested a male predisposition,<sup>5</sup> although subsequent reports have not supported this.<sup>1,6</sup> Older dogs are affected with an average age of between 8 and 9 years.<sup>1,5,6</sup> In one large case series, German shepherd dogs were over-represented based on the hospital population.<sup>1</sup> The true incidence of MM in the cat is unknown; however, it is a more rare diagnosis than in the dog, representing only 1 of 395 and 4 of 3248 tumors in two large compilations of feline malignancies and 0.9% of all malignancies and 1.9% of hematologic malignancies in another report.<sup>7–9</sup> MM represented 1.4% and 14% of abnormal and malignant serum protein electrophoretic samples, respectively, in a compilation of 155 feline samples.<sup>10</sup> MM occurs in aged cats (median age 12 to 14 years), most commonly in domestic short hairs and no sex predilection has been consistently reported, although a male preponderance may exist.<sup>6,9,11,12</sup> MM has not been associated with corona virus or FeLV or FIV infections.

The etiology of MM is for the most part unknown. Genetic predispositions, molecular aberrations (e.g., c-Kit), viral infections, chronic immune stimulation, and exposure to carcinogen stimulation have all been suggested as contributing factors.<sup>6,13–18</sup> Suggestion of a familial association in cats follows cases reported among siblings.<sup>12</sup> Evidence exists that molecular mechanisms of cellular control, including overexpression of cell cycle control components like cyclin D1 (see Chapter 2) and receptor tyrosine kinase dysregulation may be involved in canine myeloma and plasma cell tumors.<sup>17,18</sup> In rodent models, chronic immune stimulation and exposure to implanted silicone gel have been associated with development of MM,<sup>13,14</sup> as have chronic infections and prolonged hyposensitization therapy in humans.<sup>15</sup> Viral Aleutian disease of mink results in monoclonal gammopathies in a small percentage of cases.<sup>16</sup> Exposure to the agricultural industry, petroleum products, and irradiation are known risk factors for development in humans.<sup>19–21</sup> Additionally, progression of solitary plasma cell tumors to MM has been reported in both dogs and cats, and a single case of a B-cell lymphoma progressing to MM exists in the dog.<sup>22,23</sup>

### Pathology and Natural Behavior

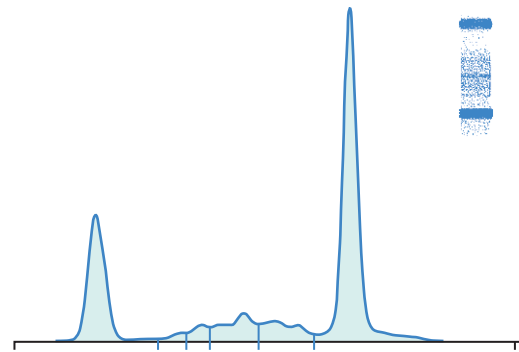
Multiple myeloma is a systemic proliferation of malignant plasma cells or their precursors arising as a clone of a single cell that usually involves multiple bone marrow sites in dogs. In cats, as previously stated, a blurring of the distinction of MM and multicentric noncutaneous EMP within the MRD occurs because widespread abdominal organ involvement without significant bone marrow infiltration has been described in a significant proportion of cases in European compilations.<sup>11,24</sup> Because both MM and multicentric noncutaneous EMP have a similar clinical course and widespread systemic involvement with hyperglobulinemia in cats, they will be





• **FIGURE 32-20** Bone marrow aspirate from a dog with multiple myeloma showing an overabundance of large neoplastic plasma cells with characteristic paranuclear clear zone representing the Golgi apparatus (*arrow*). (Dif-quick stain,  $\times 100$  objective.)

discussed as MM in this chapter. Malignant plasma cells can have a varied appearance on histologic sections and cytologic preparations. The degree of differentiation ranges from those resembling normal plasma cells in late stages of differentiation (Figure 32-20) to very large anaplastic round cells (often referred to as *plasmablasts*), with a high mitotic index representing early stages of differentiation.<sup>5,6,9,24,25</sup> Binucleate and multinucleate cells are often present (see Figure 7-32, Chapter 7). In 16 cats with MM in a North American case series, the majority (83%) of plasma cells were immature and had marked atypia, including increased size, multiple nuclei, clefted nuclei, anisocytosis, anisokaryosis, variable N:C ratios, decreased chromatin density, and variable nucleoli; nearly one-quarter had “flame cell” morphology characterized by peripheral eosinophilic cytoplasmic processes.<sup>9</sup> However, in a European compilation of feline multicentric noncutaneous MRD cases ( $n = 17$ ), 78% had well-differentiated morphologies.<sup>24</sup> The authors of this latter case series developed a grading system dependent on the percentage of plasmablasts within the neoplastic cells in which well-differentiated, intermediate-grade, and poorly differentiated have less than 15%, 15% to 49%, and 50% or more plasmablasts, respectively. Malignant plasma cells typically produce an overabundance of a single type of or component of immunoglobulin, which is referred to as the *M component* (Figure 32-21). The M component can be represented by any class of the entire immunoglobulin or only a portion of the molecule, such as the light chain (Bence Jones protein) or heavy chain (heavy chain disease) of the molecule. In the dog, the M component is usually represented by either IgA or IgG immunoglobulin types in nearly equal incidence, whereas the ratio of IgG:IgA in cats is approximately 5:1 in some reports and approximately 1:1 in others.<sup>1,5-9,24,26</sup> That being said, in the author’s (DMV) experience, the vast majority of canine cases are of the IgA type. If the M component is the IgM type, the term *macroglobulinemia* (Waldenström’s) is often applied. Several cases of biclonal gammopathy in dogs and cats have been reported.<sup>9,11,12,27-32</sup> Several cases of nonsecretory MM have been reported in dogs.<sup>33,34</sup> Rarely, cryoglobulinemia occurs in dogs with MM and IgM macroglobulinemia and has been reported in a cat with IgG myeloma.<sup>6,35-37</sup> Cryoglobulins are paraproteins that are insoluble at temperatures



**Animal protein electrophoresis**

Fractions	%	Conc.	Ref. Conc.
Albumin	24.4	2.54 L	2.60 - 4.00
Alpha 1	1.6	0.17	0.11 - 0.35
Alpha 2	3.0	0.31 L	0.92 - 1.66
Beta 1	8.7	0.90 H	0.22 - 0.61
Beta 2	7.8	0.81 H	0.08 - 0.50
Gamma	54.5	5.67 H	0.66 - 2.48

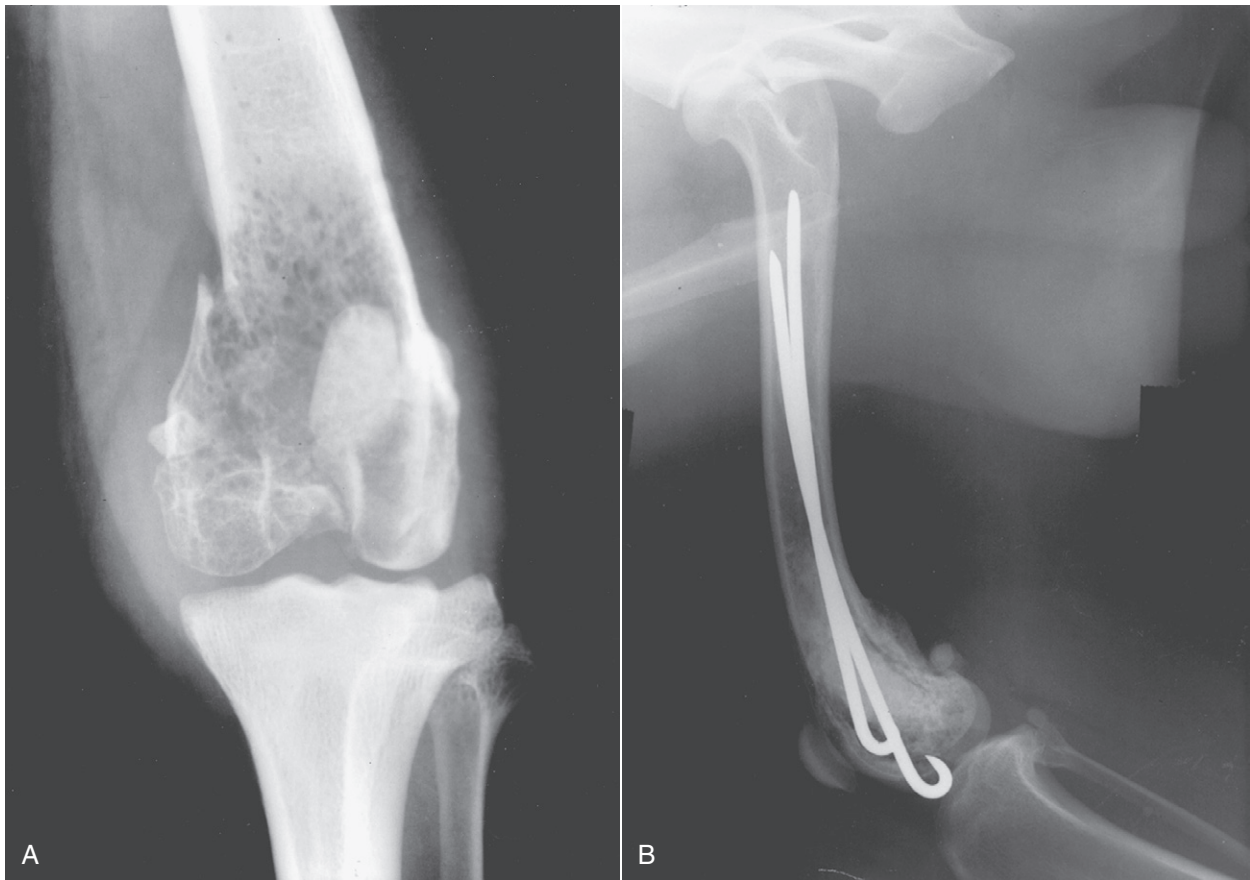
• **FIGURE 32-21** Serum protein electrophoresis from a cat with multiple myeloma. Stained cellulose acetate electrophoretic strip (*upper right corner*) with accompanying densitogram. Note large M-component spike (representing an IgG monoclonal gammopathy) present in the gamma region. (Courtesy Dr. Frances Moore, Marshfield Laboratories, Marshfield, WI.)

below 37° C and require blood collection and clotting to be performed at 37° C prior to serum separation. If whole blood is allowed to clot at temperatures below this, the protein precipitates in the clot and is lost. Pure light-chain M component is rare but has been reported in both dogs and cats.<sup>38,39</sup>

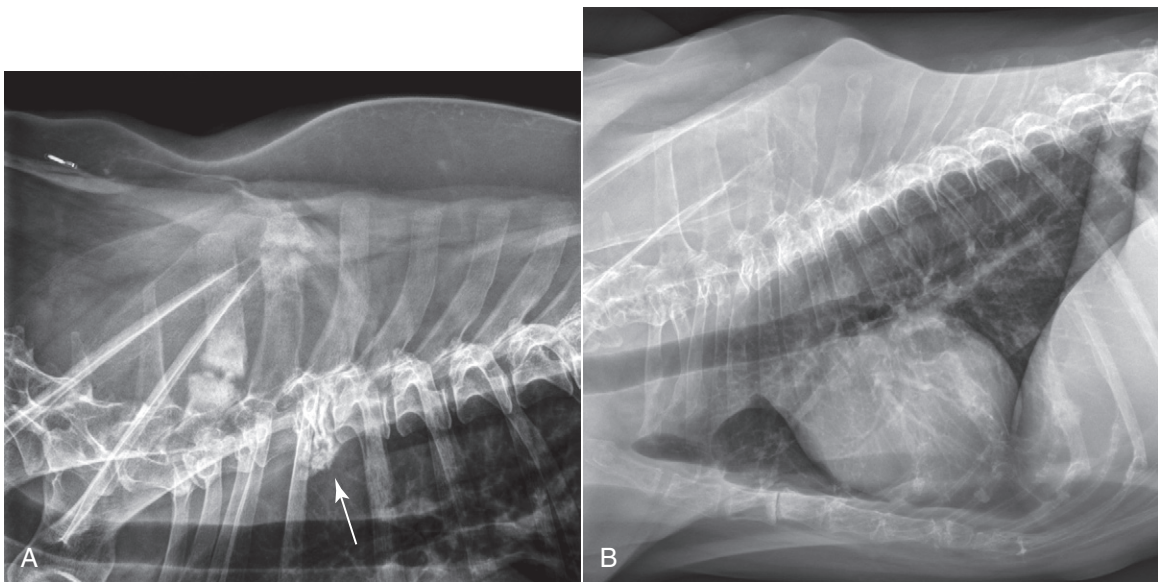
The pathology associated with MM is a result of either high levels of circulating M component, organ or bone infiltration with neoplastic cells, or both. Associated pathologic conditions include bone disease, bleeding diathesis, hyperviscosity syndrome, renal disease, hypercalcemia, immunodeficiency (and subsequent susceptibility to infections), cytopenias secondary to myelophthisis, and cardiac failure.

Bone lesions can be isolated, discrete osteolytic lesions (including pathologic fractures) (Figure 32-22, A) or diffuse osteopenias, or both (Figure 32-23). Approximately one-quarter to two-thirds of dogs with MM have radiographic evidence of bony lysis or diffuse osteoporosis.<sup>1,5,6</sup> The incidence of radiographic skeletal lesions in cats varies tremendously within reports, from as few as 8% in European case series to as high as 65% in North American case series.<sup>8,9,11,12,26</sup> Those bones engaged in active hematopoiesis are more commonly affected and include the vertebrae, ribs, pelvis, skull, and proximal or distal long bones. Skeletal lesions are rare with IgM (Waldenström’s) macrogammaglobulinemia, in which malignant cells often infiltrate the spleen, liver, and lymph tissue rather than bone.<sup>6,40-42</sup>

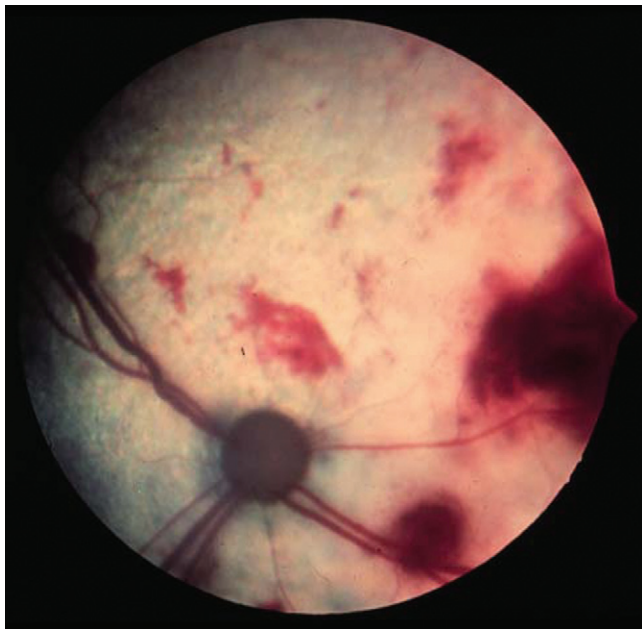
Bleeding diathesis can result from one or a combination of events. M components may interfere with coagulation by (1) inhibiting platelet aggregation and the release of platelet factor-3; (2) causing adsorption of minor clotting proteins; (3) generating abnormal fibrin polymerization; and (4) producing a functional decrease in calcium.<sup>6,43,44</sup> Approximately one-third of dogs and



• **FIGURE 32-22** **A**, Radiograph of a distal femur in a dog demonstrating severe osteolysis and a pathologic fracture secondary to a plasma cell tumor. **B**, Radiograph of the same pathologic fracture after surgical repair with Rush rods and bone cement. Local site was treated with adjuvant radiation. The dog was continued on chemotherapy for 2 more years and did well.



• **FIGURE 32-23** **A**, Lateral thoracic radiographs of a dog showing multiple expansile lytic lesions and pathologic fractures of the dorsal spinous processes and collapse fracture (*arrow*) of the third thoracic vertebral body. **B**, Lateral thoracic radiographs of a dog with diffuse osteopenia secondary to multiple myeloma. Note the overall decreased opacity of the lumbar vertebrae and dorsal spinous processes secondary to diffuse marrow involvement causing loss of bone trabeculae and thinning of the cortices.



• **FIGURE 32-24** Multiple retinal hemorrhages on the fundus in a cat with hyperviscosity syndrome secondary to multiple myeloma.

one-quarter of cats have clinical evidence of hemorrhage.<sup>1,9,11,12</sup> In dogs, nearly half have abnormal prothrombin (PT) and partial thromboplastin (PTT) times. Thrombocytopenia may also play a role if bone marrow infiltration is significant (i.e., myelophthisis).

Hyperviscosity syndrome (HVS) represents one of a constellation of clinicopathologic abnormalities resulting from greatly increased serum viscosity. The magnitude of viscosity changes is related to the type, size, shape, and concentration of the M component in the blood. HVS is more common with IgM macroglobulinemias due to the high molecular weight of this class of immunoglobulin. IgA-secreting myelomas (usually present as a dimer in the dog), may undergo polymerization resulting in increased serum viscosity.<sup>1,6,45</sup> IgG-associated HVS can also occur, albeit less frequently. High serum viscosity occurs in approximately 20% of dogs with MM and can result in bleeding diathesis, neurologic signs (e.g., dementia, depression, seizure activity, coma), ophthalmic abnormalities (e.g., dilated and tortuous retinal vessels, retinal hemorrhage [Figure 32-24], retinal detachment), and increased cardiac workload with the potential for subsequent development of cardiomyopathy.\* These consequences are thought to be a result of sludging of blood in small vessels, ineffective delivery of oxygen and nutrients, and coagulation abnormalities. HVS has been reported in cats with IgG-, IgA-, and IgM-secreting tumors.<sup>6,8,49-53</sup> In several of these cases, relative serum viscosity was increased above control ranges.

Renal disease is present in approximately one-third to one-half of dogs with MM, and azotemia was observed in one-third of cats in one report.<sup>1,5,9,11</sup> The pathogenesis of renal failure is often multifactorial and can ensue as a result of Bence Jones (light-chain) proteinuria, tumor infiltration into renal tissue, hypercalcemia, amyloidosis, diminished perfusion secondary to hyperviscosity syndrome, dehydration, or ascending urinary tract infections.<sup>1,6,43,44</sup> Normally, heavy- and light-chain synthesis is well balanced in

nonneoplastic immunoglobulin production. In the case of MM, an unbalanced excess of light-chain products may be produced. Light chains are of low molecular weight and are normally filtered by the renal glomerulus, and their presence in urine can result in protein precipitates and subsequent renal tubular injury. The presence of light chains in urine without a concomitant monoclonal spike in serum, although rare, is indicative of pure light-chain disease.<sup>38</sup> Tubules become obstructed by large laminated casts containing albumin, immunoglobulin, and light chains.<sup>6,38,43,44</sup> Bence Jones proteinuria occurs in approximately 25% to 40% of dogs with MM.<sup>1,5,6</sup> Bence Jones proteinuria is reported to occur in approximately 40% of cats with MM/MRD.<sup>9,11</sup> Hypercalcemia is reported in 15% to 20% of dogs with MM and is thought to result primarily from the production of osteoclast-activating factor by neoplastic cells.<sup>1,6,54</sup> Other factors, including increased levels of various cytokines, TNF, IL-1, and IL-6 have been implicated in human MM. In two dogs with MM and hypercalcemia, serum elevations in circulating N-terminal PTHrP were noted.<sup>55</sup> Hypercalcemia may also be exacerbated by associated renal disease. Hypercalcemia, initially thought to be a rare event in cats with MM, occurred in 10% to 25% of recently reported cases.<sup>9,11,12,56</sup>

Susceptibility to infection and immunodeficiency have long been associated with MM and are often the ultimate cause of death in affected animals.<sup>1,6,26</sup> Infection rates in humans with MM are fifteen times higher than normal and usually represent pneumonia or urinary tract infections.<sup>57</sup> Response to vaccination has also been shown to be suppressed in humans with MM.<sup>57</sup> Immunoglobulin levels are often severely depressed in affected animals.<sup>6</sup> In addition, leukopenias may be present secondary to myelophthisis.

Variable cytopenias may be observed in association with MM. A normocytic, normochromic, nonregenerative anemia is encountered in approximately two-thirds of dogs with MM.<sup>1,5,6</sup> This can result from marrow infiltration (myelophthisis), blood loss from coagulation disorders, anemia of chronic disease, or increased erythrocyte destruction secondary to high serum viscosity. Rare erythrophagocytic forms of MM have also been reported in both dogs and cats and may contribute to anemia.<sup>58,59</sup> Similar factors lead to thrombocytopenia and leukopenia in nearly one-third and one-quarter of dogs with MM, respectively. In cats, approximately two-thirds, half, and one-third will be anemic, thrombocytopenic, and neutropenic, respectively.<sup>9,11,12</sup>

Cardiac disease if present is usually a result of excessive cardiac workload and myocardial hypoxia secondary to hyperviscosity.<sup>43,45,53</sup> Myocardial infiltration with amyloid and anemia may be complicating factors. Nearly half of cats with MM in one report presented with a cardiac murmur, the etiology of which was not established.<sup>9</sup> Three cats with HVS presented with congestive heart failure, murmurs, and echocardiographic signs consistent with hypertrophic cardiomyopathy.<sup>53</sup>

## History and Clinical Signs

Clinical signs of MM may be present up to a year prior to diagnosis with a median duration of one month reported in dogs.<sup>1,9</sup> In one cat, M-component elevations were detected 9 years prior to clinical presentation. In this latter case, the M-component elevation was consistent with monoclonal gammopathy of unknown significance (MGUS). MGUS (i.e., benign, essential, or idiopathic monoclonal gammopathy) is a benign monoclonal gammopathy that is not associated with osteolysis, bone marrow infiltration, or Bence Jones proteinuria. MGUS has also been reported in dogs.<sup>60,61</sup> Signs of MM can be variable based on the wide range of pathologic effects

\*References 1, 6, 40, 42, 45-48.



• **TABLE 32-14** Frequency of Clinical Signs Reported for Dogs with Multiple Myeloma (n = 60)

CLINICAL SIGN	FREQUENCY REPORTED (%)
Lethargy and weakness	62
Lameness	47
Bleeding diathesis	37
Funduscopy abnormalities	35
Polyuria/polydipsia	25
CNS deficits	12

Data from Matus RE, Leifer CE, MacEwen EG, et al: Prognostic factors for multiple myeloma in the dog, *J Am Vet Med Assoc* 188:1288–1291, 1986. CNS, Central nervous system.

possible. Tables 32-14 and 32-15 list the relative frequencies of clinical signs observed in the dog and cat, respectively, based on a compilation of several reports.\* Bleeding diathesis is usually represented by epistaxis and gingival bleeding. Funduscopy abnormalities may include retinal hemorrhage (see Figure 32-24), venous dilatation with sacculations and tortuosity, retinal detachment, and blindness.† CNS signs may include dementia, seizure activity, tremors, and deficiencies in midbrain or brain-stem localizing reflexes secondary to HVS or extreme hypercalcemia. Signs reflective of transverse myelopathies secondary to vertebral column infiltration, pathologic fracture, or extradural mass compression can also occur.<sup>1,6,35,62,63</sup> One case of ataxia and seizure activity in a dog with EMP secondary to tumor-associated hypoglycemia has been reported.<sup>64</sup> Additionally, paraneoplastic polyneuropathy has been reported in a dog with MM.<sup>65</sup> A history of chronic respiratory infections and persistent fever may also be present in cats. Hepatosplenomegaly and renomegaly can occur due to organ infiltration. Bleeding diathesis due to HVS is less common in the cat; however, epistaxis, pleural and peritoneal hemorrhagic effusions, retinal hemorrhage, and central neurologic signs have been reported.<sup>6,8,49-53</sup> Polydipsia and polyuria can occur secondary to renal disease or hypercalcemia, and dehydration may develop. Hindlimb paresis secondary to osteolysis of lumbar vertebral bodies or extradural compression has been reported in cats.<sup>12,66</sup>

## Diagnosis and Staging

The diagnosis of MM in dogs usually follows the demonstration of bone marrow plasmacytosis (see Figure 32-20), the presence of osteolytic bone lesions (see Figures 32-22 and 32-23), and the demonstration of serum or urine myeloma proteins (M component) (see Figure 32-21). In the absence of osteolytic bone lesions, a diagnosis can also be made if marrow plasmacytosis is associated with a progressive increase in the M component. In the cat, because the degree of bone marrow infiltration may not be as marked, it has been suggested that consideration of plasma cell morphology and visceral organ infiltration (Figure 32-25) be given in cases with demonstrable M-component disease in the absence of marked (<20%) marrow plasmacytosis.<sup>9,11,24</sup>

All animals suspected of plasma cell tumors should receive a minimal diagnostic evaluation including a CBC, platelet count,

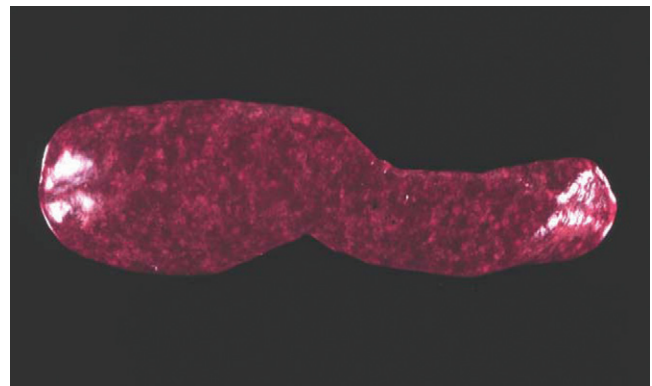
\*References 1, 6, 9, 11, 12, 26.

†References 1, 6, 11, 45, 46-48.

• **TABLE 32-15** Approximate Frequency of Clinical Signs Reported for Cats with Myeloma-Related Disorders (n = 53)

CLINICAL SIGN	FREQUENCY RANGE REPORTED (%)
Lethargy and weakness	40-100
Anorexia	33-100
Pallor	30-100
Polyuria/polydipsia	13-40
Vomiting/diarrhea	20-30
Dehydration	20-30
Palpable organomegaly	20-25
Lameness	10-25
Heart murmur	0-45
Hind limb paresis/paralysis	0-45
Bleeding diathesis	0-40
CNS signs	13-30
Concurrent cutaneous plasma cell tumor	0-30
Fundic changes	13
Lymphadenopathy	0-10

Data from MacEwen EG, Hurvitz AI: Diagnosis and management of monoclonal gammopathies, *Vet Clin N Am Small Anim Pract* 7:119–132, 1977; Patel RT, Caceres A, French AF, et al: Multiple myeloma in 16 cats: a retrospective study, *Vet Clin Pathol* 34:341–352, 2005; Mellor PJ, Haugland S, Murphy S, et al: Myeloma-related disorders in cats commonly present as extramedullary neoplasms in contrast to myeloma in human patients: 24 cases with clinical follow-up, *J Vet Intern Med* 20:1376–1383, 2006; Hanna F: Multiple myelomas in cats, *J Feline Med Surg* 7:275–287, 2005; and Drazner FH: Multiple myeloma in the cat, *Comp Cont Ed Pract Vet* 4:206–216, 1982. CNS, Central nervous system.



• **FIGURE 32-25** Necropsy specimen of a spleen from a cat with multiple myeloma showing diffuse plasma cell infiltration.

serum biochemistry profile, and urinalysis. Particular attention should be paid to renal function and serum calcium levels. If clinical hemorrhage is present, a coagulation assessment (e.g., platelet count, PT, PTT) and serum viscosity measurements are indicated. All animals should undergo a careful funduscopy examination. Serum electrophoresis and immunoelectrophoresis are performed to determine the presence of a monoclonal M component (see Figure 32-21) and to categorize the immunoglobulin class involved. Heat precipitation and electrophoresis of urine may be performed to determine presence of Bence Jones proteinuria

because commercial urine dipstick methods are not capable of this determination. Definitive diagnosis usually follows the performance of a bone marrow aspiration in the dog. A bone marrow core biopsy or multiple aspirations may be necessary due to the possibility of uneven clustering or infiltration of plasma cells in the bone marrow. Normal marrow contains less than 5% plasma cells, whereas myelomatous marrow often greatly exceeds this level. Current recommendations require more than 20% marrow plasmacytosis to be present, although a 10% cutoff in cats has been recently recommended with special attention to cellular atypia.<sup>9</sup> Even the 10% threshold is problematic in cats, and cellular atypia and visceral organ involvement (assessed through needle aspiration cytology or tissue biopsy) should be considered equally important in the species.<sup>9,11,24</sup> Rarely, biopsy of osteolytic lesions (i.e., Jamshidi core biopsy; see Chapter 24) is necessary for diagnosis in the dog. In one case of MM in a dog, splenic aspirates were diagnostically helpful.<sup>67</sup> Overall frequencies of clinical diagnostic abnormalities for dogs and cats with MM are compiled from published series having at least five cases each and are listed in Table 32-16.

### Immunohistochemical and Molecular Diagnostics

Histochemical and immunohistochemical analyses of cells or tissues suspected of MRD are more often applied in the case of solitary plasmacytomas or where EMP is suspected in the absence of marrow involvement and will be discussed in subsequent sections; however, they have been occasionally useful in the diagnosis of MM. Molecular diagnostic techniques for MM have received limited use thus far in veterinary oncology; however, determining clonality of the immunoglobulin heavy chain variable region gene has been performed in feline plasmacytoma and myeloma using PARR techniques (see Chapter 8),<sup>68</sup> and use of this technology in cases where diagnosis is not straightforward awaits further investigation. The author has used PARR analysis both before treatment and after clinical remission in a small number of dogs with MM involved in clinical trials and documented its utility (1) for initial diagnosis and (2) to characterize molecular remission.

### Imaging

Routine thoracic and abdominal radiographs are recommended in suspected cases. Occasionally, bony lesions can be observed in skeletal areas on these standard films, and organomegaly (liver, spleen, kidney) is observed in the majority of cats.<sup>9,11</sup> Abdominal ultrasound is recommended in all cats suspected of MM because this modality reveals involvement of one or more abdominal organs in the majority of cases.<sup>9,11</sup> These include splenomegaly with or without nodules, diffuse hyperechoic hepatomegaly with or without nodules, renomegaly, and iliac lymph node enlargement. In one case series in cats, 85% of organs with ultrasonographic abnormalities were subsequently confirmed to have plasma cell infiltration.<sup>11</sup> Skeletal survey radiographs are recommended to determine presence and extent of osteolytic lesions, which may have diagnostic, prognostic, and therapeutic implications. Although nuclear scintigraphy (bone scan) for clinical staging of dogs with MM has been performed, due to the predominant osteolytic activity with osteoblastic inactivity present, scans seldom give positive results and are therefore not useful for routine diagnosis.<sup>69</sup> In physician-based oncology, bone mineral density analysis (dual-energy x-ray absorptiometry [DEXA] scan) to document osteoporosis, MRI scan of bone marrow, and PET/CT are commonly used for staging; however, these modalities have not been applied consistently in the veterinary literature. A clinical staging system for canine MM has been suggested<sup>1</sup>; however, at present, no prognostic significance has been attributed to it.

• **TABLE 32-16** Approximate Frequency of Clinical Diagnostic Abnormalities for Dogs and Cats\* with Multiple Myeloma (n = 53 cats, 82 dogs)

ABNORMALITY	FREQUENCY RANGE REPORTED (%)	
	DOGS	CATS
Increased M component	100	94
Monoclonal	100	77-83
Biclonal	<5% <sup>†</sup>	16-23
IgG	46	84
IgA	54	16
Noncutaneous extramedullary extension	NR	65-100 <sup>‡</sup>
Marrow plasmacytosis (>10%)	100	50-97
CBC abnormalities		
Anemia (nonregenerative)	68	50-64
Thrombocytopenia	33	50
Neutropenia	25	37
Circulating plasma cells (leukemia)	10	5-25
Hypoalbuminemia	65	36
Hypocholesterolemia	NR	68
Proteinuria	35	71
Bence Jones proteinuria	38	40-59
Bone lysis	51	5-45
Serum hyperviscosity	32	35-44
Azotemia	33	22-40
Hypercalcemia	16	10-25
Increased activities of liver enzymes	NR	43-50

NR, Not reported; CBC, complete blood count.

\*Includes noncutaneous extramedullary plasmacytoma (EMP) cases from Mellor.<sup>11</sup>

<sup>†</sup>Several single case reports exist for biclonal gammopathy in dogs with MM.

<sup>‡</sup>11 of 11 in one report had evidence of infiltration in either spleen, lymph node, or liver.

Data from Matus RE, Leifer CE, MacEwen EG, et al: Prognostic factors for multiple myeloma in the dog. *J Am Vet Med Assoc* 188:1288-1291, 1986; MacEwen EG, Hurvitz AI: Diagnosis and management of monoclonal gammopathies, *Vet Clin N Am Small Anim Pract* 7:119-132, 1977; Patel RT, Caceres A, French AF, et al: Multiple myeloma in 16 cats: a retrospective study, *Vet Clin Pathol* 34:341-352, 2005; Mellor PJ, Haugland S, Murphy S, et al: Myeloma-related disorders in cats commonly present as extramedullary neoplasms in contrast to myeloma in human patients: 24 cases with clinical follow-up, *J Vet Intern Med* 20:1376-1383, 2006; Hanna F: Multiple myelomas in cats, *J Feline Med Surg* 7:275-287, 2005; and Drazner FH: Multiple myeloma in the cat, *Comp Cont Ed Pract Vet* 4:206-216, 1982.

### Differential Diagnosis of MM

Disease syndromes other than plasma cell tumors can be associated with monoclonal gammopathies and should be considered in any list of differentials. These include other lymphoreticular tumors (B-cell lymphoma, extramedullary plasmacytoma, chronic and acute B-lymphocytic leukemia), chronic infections (e.g., ehrlichiosis, leishmaniasis, FIP), and MGUS.\*

\*References 5, 9, 60, 61, 70-73.

## Treatment

### Initial Therapy of Multiple Myeloma

Therapy for MM is directed at both the tumor cell mass and the secondary systemic effects they elicit. All diagnostic procedures should be completed before initiating primary therapy to ensure a diagnosis is complete and baseline values are procured for monitoring response. Chemotherapy is effective at reducing myeloma cell burden, relieving bone pain, allowing for skeletal healing, and reducing levels of serum immunoglobulins in the majority of dogs with MM and will greatly extend both the quality and quantity of most patients' lives. MM in dogs is initially a gratifying disease to treat for both the clinician and the companion animal owner, although complete elimination of neoplastic myeloma cells is rarely achieved and eventual relapse is to be expected. Unlike dogs, only one-half of cats with MM will respond to chemotherapy and most responses will be short-lived; however, several long-term responses (i.e., >1 year) have been reported and treatment should be attempted when educated clients decide on a therapeutic option.\*

Melphalan, an alkylating agent, is the chemotherapeutic of choice for the treatment of multiple myeloma.<sup>1,6</sup> In the dog, an initial starting dose of 0.1 mg/kg PO, once daily for 10 days, is then reduced to 0.05 mg/kg PO, once daily continuously. The addition of prednisone therapy is thought to increase the efficacy of melphalan therapy. Prednisone is initiated at a dosage of 0.5 mg/kg PO, once daily for 10 days, then reduced to 0.5 mg/kg every other day prior to discontinuation after 60 days of therapy. Melphalan, however, is continued at 0.05 mg/kg/day until clinical relapse occurs or myelosuppression necessitates a dose reduction. The vast majority of dogs on melphalan and prednisone combination therapy tolerate the regimen well. The most clinically significant toxicity of melphalan is myelosuppression, in particular a delayed thrombocytopenia. CBCs, including platelet counts, should be performed biweekly for 2 months of therapy and monthly thereafter. If significant myelosuppression occurs (usually thrombocytopenia or neutropenia), reduction of the dosage or treatment frequency may be necessary. An alternative pulse-dosing regimen for melphalan (7 mg/m<sup>2</sup> PO, daily for 5 consecutive days every 3 weeks) has been used successfully by the author in a small number of cases in which myelosuppression was limiting more conventional continuous low-dose therapy. This pulse-dose regimen is now being used first-line by the author with the caveat that long-term response data are currently lacking.

Melphalan and prednisone therapy can also be used in cats with multiple myeloma; however, it appears this protocol is more myelosuppressive than in the dog and careful monitoring is required. In the cat, a dosing schedule similar to the dog has been reported<sup>11,26</sup>; 0.1 mg/kg (approximately 0.5 mg, or one-quarter of a 2 mg tablet) once daily for 10 to 14 days, then every other day until clinical improvement or leukopenia develop. Long-term continuous maintenance (0.1 mg/kg, once every 7 days) has been advocated.<sup>12</sup> An alternative protocol advocated in the cat uses melphalan at 2 mg/m<sup>2</sup>, once every 4 days continuously, and appears to be well tolerated.<sup>11</sup>

Cyclophosphamide has been used as an alternative alkylating agent or in combination with melphalan in dogs and cats with MM.<sup>1,6,11</sup> There is no evidence to suggest it is superior to melphalan therapy. In the author's practice, cyclophosphamide is limited to those cases presenting with severe hypercalcemia or with widespread systemic involvement in which a faster acting alkylating

agent may more quickly alleviate systemic effects of the disease. Cyclophosphamide is initiated at a dosage of 200 mg/m<sup>2</sup> IV, once, at the same time oral melphalan therapy is started. Because cyclophosphamide is less likely to affect thrombocytes, it may be substituted in those patients in which thrombocytopenia has developed secondary to long-term melphalan use.

Chlorambucil, another alkylating agent, has been used successfully for the treatment of IgM macroglobulinemia in dogs at a dosage of 0.2 mg/kg PO, once daily.<sup>6,40</sup> Little or no clinical signs of toxicity result from this dosing schedule. Chlorambucil has also been used in cats with MRD.<sup>11</sup>

Lomustine (CCNU), yet another alkylating agent, has been used in a limited number of cats with MM and a partial response has been reported following dosing at 50 mg/m<sup>2</sup> PO, every 21 days.<sup>74</sup>

### Evaluation of Response to Therapy

Evaluation of response to systemic therapy for multiple myeloma is based on improvement in clinical signs, clinicopathologic parameters, and radiographic improvement of skeletal lesions or ultrasonographic improvement of organ involvement.<sup>1,6,11</sup> Subjective improvement in clinical signs of bone pain, lameness, lethargy, and anorexia should be evident within 3 to 4 weeks following initiation of therapy. Objective laboratory improvement, including reduction in serum globulin, immunoglobulin, and calcium, along with normalization of the hemogram, is usually noted within 3 to 6 weeks (Figure 32-26). Radiographic improvement in osteolytic bone lesions may take months and resolution may only be partial. Ophthalmic complications (including long-standing retinal detachments) and paraneoplastic neuropathies can be expected to resolve along with tumor mass.<sup>48,65</sup> In cats responding to chemotherapy, clinical improvement is noted in 2 to 4 weeks and serum protein and radiographic bone abnormalities were greatly improved by 8 weeks.<sup>11,12</sup>

As previously discussed, complete resolution of MM does not generally occur and a good response is defined as a reduction in measured M component (i.e., immunoglobulin or Bence Jones proteins) of at least 50% of pretreatment values.<sup>6</sup> Reduction in serum immunoglobulin levels may lag behind reductions in Bence Jones proteinuria because the half-lives are 15 to 20 days and 8 to 12 hours, respectively.<sup>75</sup> For routine follow-up, quantification of the increased serum globulin, immunoglobulin, or urine Bence Jones protein is performed monthly until a good response is noted and then every 2 to 3 months thereafter. Repeat bone marrow aspiration or imaging (in the case of visceral disease) for evaluation of plasma cell infiltration may be occasionally necessary. Bone marrow reevaluation is particularly prudent when cytopenias develop during chemotherapy, and drug-induced myelosuppression must be differentiated from myelophthisis due to neoplastic marrow recurrence.

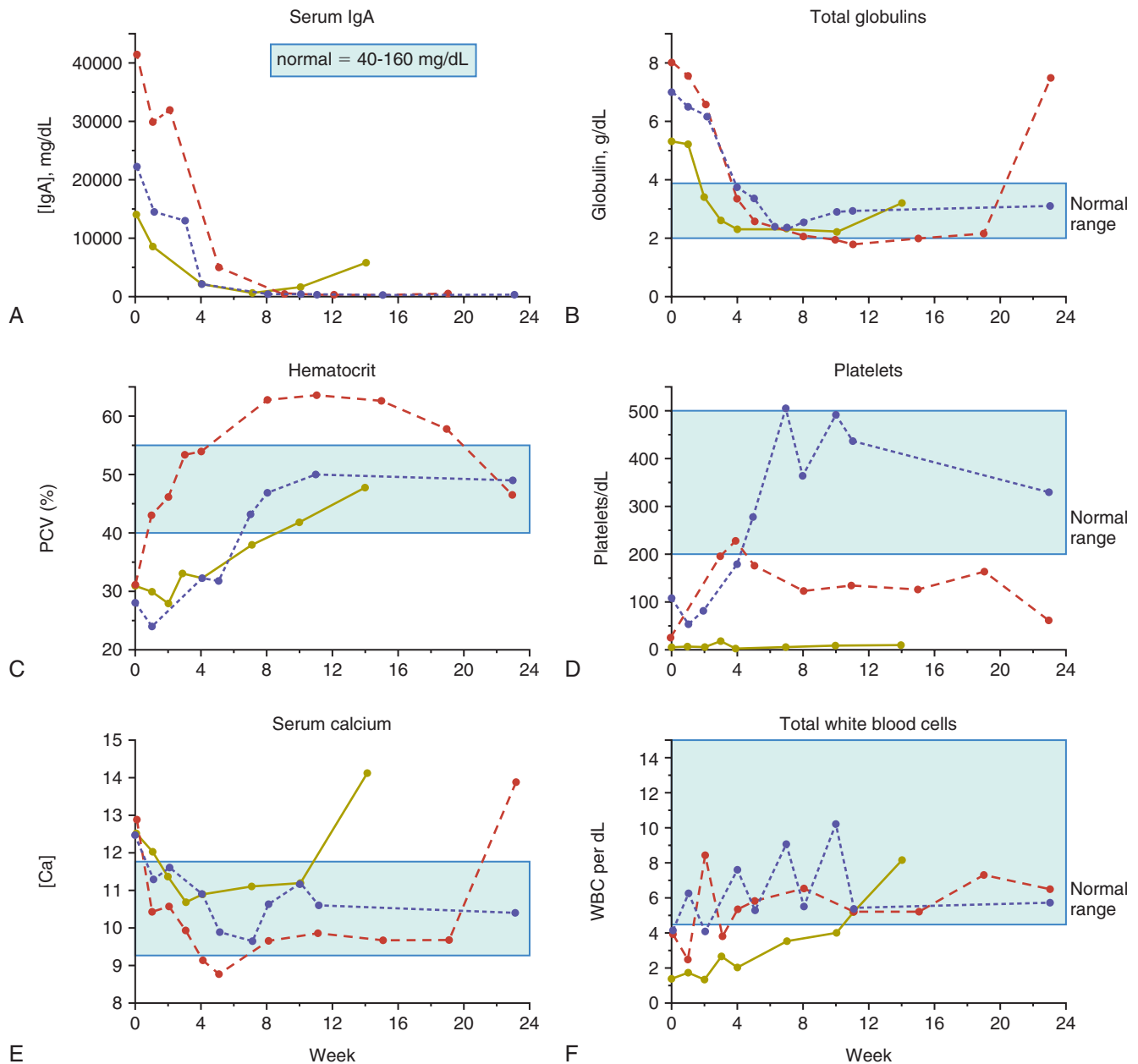
### Therapy Directed at Complications of Multiple Myeloma

The long-term control of complications, including hypercalcemia, HVS, bleeding diathesis, renal disease, immunosuppression, ophthalmic complications, and pathologic skeletal fractures, depend on controlling the primary tumor mass. Therapy directed more specifically at these complications may, however, be indicated in the short term.

If hypercalcemia is marked and significant clinical signs exist, standard therapies, including fluid diureses, with or without pharmacologic agents (e.g., calcitonin), may be indicated (see Chapter 5). Moderate hypercalcemia will typically resolve within 2 to 3 days following initiation of melphalan/prednisone chemotherapy.

\*References 6, 9, 11, 12, 31, 26.





**FIGURE 32-26** Clinicopathologic data changes over time (weeks) after initiation of cytotoxic chemotherapy in three dogs with IgA multiple myeloma. Light blue area, Normal reference range. **A**, Serum IgA (mg/dL); **B**, total globulins (g/dL); **C**, hematocrit (%); **D**, platelets/dL; **E**, serum calcium (mg/dL); **F**, total white blood cells/dL.

HVS is best treated in the short term by plasmapheresis.\* Whole blood is collected from the patient and centrifuged to separate plasma from packed cells. Packed red cells are resuspended in normal saline or other crystalloid and reinfused into the patient. Bleeding diathesis will usually resolve along with HVS; however, platelet-rich plasma transfusions may be necessary in the face of thrombocytopenia.

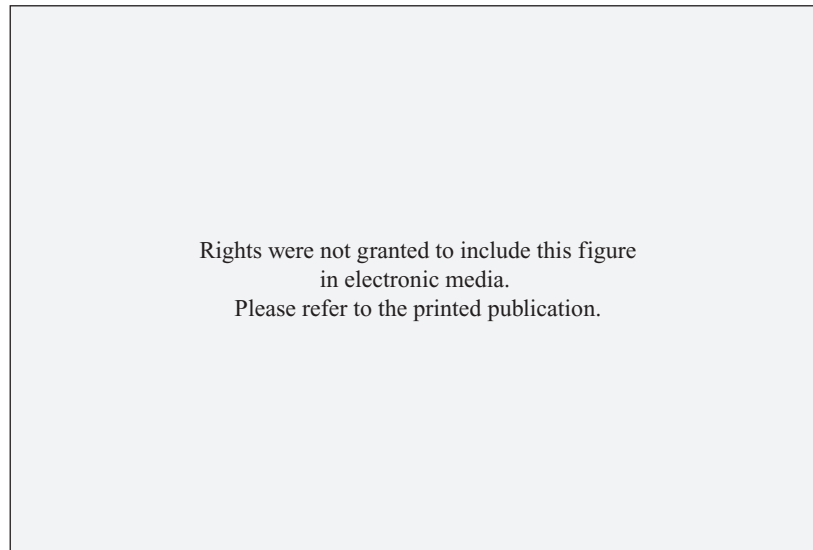Renal impairment may necessitate aggressive fluid therapy in the short term and maintenance of adequate hydration in the long term. Careful attention to secondary urinary tract infections and appropriate antimicrobial therapy is indicated. Ensuring adequate

water intake at home is important, and occasionally, educating owners in subcutaneous fluid administration is indicated. Continued monitoring of renal function is recommended along with follow-up directed at tumor response.

Patients with MM can be thought of as immunologically impaired. Some have recommended prophylactic antibiotic therapy in dogs with MM<sup>6</sup>; however, in humans, no benefit for this approach over diligent monitoring and aggressive antimicrobial management when indicated has been observed.<sup>43</sup> Cidal antimicrobials are preferred over static drugs, and avoidance of nephrotoxic antimicrobials is recommended.

Pathologic fractures of weight-bearing long bones and vertebrae resulting in spinal cord compression may require immediate surgical intervention in conjunction with systemic chemotherapy.

\*References 6, 45, 53, 72, 76, 77.



• **FIGURE 32-27** Survival curve of 37 dogs with multiple myeloma treated with chemotherapy. The median survival time (MST) is 540 days. (From Matus RE, Leifer CE, MacEwen EG, et al: *Prognostic factors for multiple myeloma in the dog*, J Am Vet Med Assoc 188:1288–1292, 1986.)

Orthopedic stabilization of fractures should be undertaken and may be followed with external-beam RT (see Figure 32-22). Recently, inhibition of osteoclast activity by bisphosphonate drugs has been shown to reduce the incidence and severity of skeletal complications of MM in humans.<sup>69</sup> This class of drugs may hold promise for use in dogs and cats with various skeletal tumors; however, they have not been adequately evaluated in MRD.<sup>78</sup>

### Rescue Therapy

When MM eventually relapses in dogs and cats undergoing melphalan therapy or in the uncommon case that is initially resistant to alkylating agents, rescue therapy may be attempted. The author has had success with VAD, which is a combination of doxorubicin (30 mg/m<sup>2</sup> IV, every 21 days), vincristine (0.7 mg/m<sup>2</sup> IV, days 8 and 15), and dexamethasone sodium phosphate (1.0 mg/kg IV, once a week on days 1, 8, and 15), given in 21-day cycles. Whereas most dogs initially respond to this rescue protocol, the duration of response tends to be short, lasting only a few months. High-dose cyclophosphamide (300 mg/m<sup>2</sup> IV, every 7 days) has also been used with limited success as a rescue agent. Liposomal doxorubicin has produced a long-term remission in a dog with MM previously resistant to native doxorubicin.<sup>79</sup>

### Investigational Therapies

MM is ultimately a uniformly fatal disease in most species, including humans, and thus significant effort is being placed on investigational therapies for this disease. Currently, bone marrow ablative therapy and marrow or stem cell rescue, thalidomide (and other antiangiogenic therapies), bortezomib (a proteasome inhibitor), arsenic trioxide, the bisphosphonates, and several molecular targeting therapies are under investigation; however, their use in veterinary species is limited or completely absent at present. The promise of molecular targeted therapies is, however, foreshadowed by a case of a dog with MM that was resistant to melphalan, prednisone, and doxorubicin that subsequently achieved a partial response to tyrosine kinase inhibitor therapy (toceranib; see Chapter 14, Section B) that was maintained for 6 months.<sup>18</sup>

### Prognosis

The prognosis for dogs with MM is good for initial control of tumor and a return to good quality of life. In a group of 60 dogs with MM, approximately 43% achieved a complete remission (i.e., serum immunoglobulins normalized), 49% achieved a partial remission (i.e., immunoglobulins <50% pretreatment values), and only 8% did not respond to melphalan and prednisone chemotherapy.<sup>1</sup> Long-term survival is the norm, with a median of 540 days reported (Figure 32-27). The presence of hypercalcemia, Bence Jones proteinuria, and extensive bony lysis are known negative prognostic indices in the dog.<sup>1</sup> The long-term prognosis for dogs with MM is poor because recurrence of tumor mass and associated clinical signs is expected. Eventually, the tumor is no longer responsive to available chemotherapeutics and death follows from renal failure, sepsis, or euthanasia for intractable bone or spinal pain.<sup>1,6</sup>

The prognosis for MM in the cat is not as favorable in the short term as it is in the dog.<sup>6,9,11,12,26</sup> Whereas most cats (approximately 60%) transiently respond to melphalan/prednisone or COP-based protocols, most responses are partial and not durable. Typically, cats with MM succumb to their disease within 4 months.<sup>8,9,12,26</sup> However, long-term survivors (>1 year) have been occasionally reported.\* In one European case series, seven cats undergoing melphalan or COP-based therapy had a median survival of 9.5 months.<sup>11</sup> One investigator grouped MM in cats into two prognostic categories (Table 32-17) based on criteria known to predict behavior in dogs.<sup>12</sup> Although no rigorous statistical analysis was performed on this small group of nine cats, the median survival for cats in “aggressive” and “nonaggressive” categories was 5 days and 387 days, respectively.

Experience in dogs with IgM macroglobulinemia is limited.<sup>6,40-42</sup> Response to chlorambucil is to be expected, and in nine treated dogs, 77% achieved remission with a median survival of 11 months.<sup>6</sup>

\*References 9, 11, 12, 26, 31, 56.

• **TABLE 32-17** Classification of Multiple Myeloma in Cats Based on Clinical and Diagnostic Criteria Suspected of Predicting Prognosis

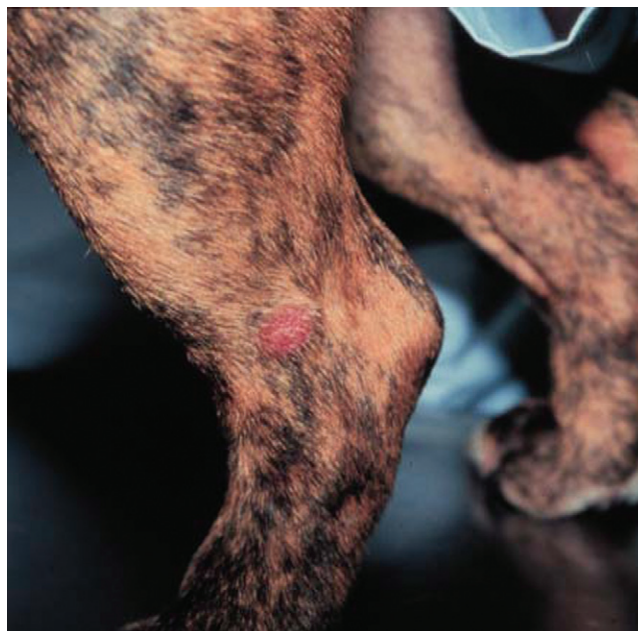BEHAVIOR CATEGORY	CRITERIA
Aggressive	Hypocalcemia, presence of bony lesions with pathological fracture, low packed cell volume (PCV), presence of light-chain Bence Jones protein in urine, azotemia, hypercreatinemia, persistence of high serum protein level after 8 weeks of treatment, little or no clinical improvement.
Less aggressive	Normal serum calcium, normal creatinine, blood urea nitrogen (BUN), PCV levels, presence of bony lesions without pathological fractures, absence of light-chain Bence Jones protein, normalization of serum protein level after 8 weeks of treatment.

Data from Hanna F: Multiple myelomas in cats, *J Feline Med Surg* 7:275–287, 2005.

## Solitary and Extramedullary Plasmacytic Tumors

Solitary collections of monoclonal plasmacytic tumors can originate in soft tissues or bone and are referred to as *extramedullary plasmacytoma* (EMP) and *solitary osseous plasmacytoma* (SOP), respectively. The systemic, multicentric, biologically aggressive EMP syndrome encountered in cats<sup>11,24</sup> has been discussed in the MM section and will not be included in this discussion. A number of large case compilations of cutaneous plasmacytoma have been reported in the dog.<sup>17,80-86</sup> The most common locations for EMP in the dog are cutaneous (86%; **Figure 32-28**), the mucous membranes of the oral cavity and lips (9%; **Figure 32-29**), and the rectum and colon (4%). The skin of the limbs and head (including the ears) are most frequently reported cutaneous sites. Other sites accounted for only 1% of the remaining cases and can include stomach, spleen, genitalia, eye, uterus, liver, larynx, trachea, third eyelid, sinonasal cavity, and intracranial sites.<sup>87-94</sup> The American cocker spaniel, English cocker spaniel, and West Highland white terrier (and perhaps Yorkshire terriers, Boxers, German shepherds, and Aire-dale terriers) are at increased risk for developing plasmacytomas and the median age of affected dogs is 9 to 10 years of age.<sup>86</sup>

Cutaneous and oral EMP in dogs are typically benign tumors that are highly amenable to local therapy. There exists, however, a rare form of multiple cutaneous plasmacytomas in dogs that is part of a more generalized biologically aggressive MM process.<sup>95,96</sup> The natural behavior of noncutaneous/nonoral EMP appears to be somewhat more aggressive in the dog. GI EMP have been reported on a number of occasions in the veterinary literature, including the esophagus,<sup>91</sup> stomach,<sup>97,98</sup> and small<sup>99</sup> and large intestine.<sup>98-101</sup> Metastasis to associated lymph nodes is more common in these cases; however, bone marrow involvement and monoclonal gammopathies are less commonly encountered. Colorectal EMPs tend



• **FIGURE 32-28** A cutaneous plasmacytoma on the limb of a dog.

to be of low biologic aggressiveness, and most do not recur following surgical excision.<sup>100</sup> Conversely, the majority of SOPs eventually progress to systemic MM; however, the time course from local tumor development to systemic MM may be many months to years.<sup>33,102</sup> SOPs have been reported in the dog involving the appendicular skeleton, as well as the zygomatic arch, and ribs.<sup>33</sup>

SOPs are less common in cats, and fewer reports exist in the literature.<sup>11,22,103-107</sup> They occur in older cats (mean ages 9 to 14 years), with no significant sex predilection. The skin is the most common site; however, other sites include the oral cavity, eye, GI tract, liver, subcutaneous tissues, and brain. Reports exist of cutaneous EMP in cats that progressed to systemic MRD.<sup>11,22,105</sup>

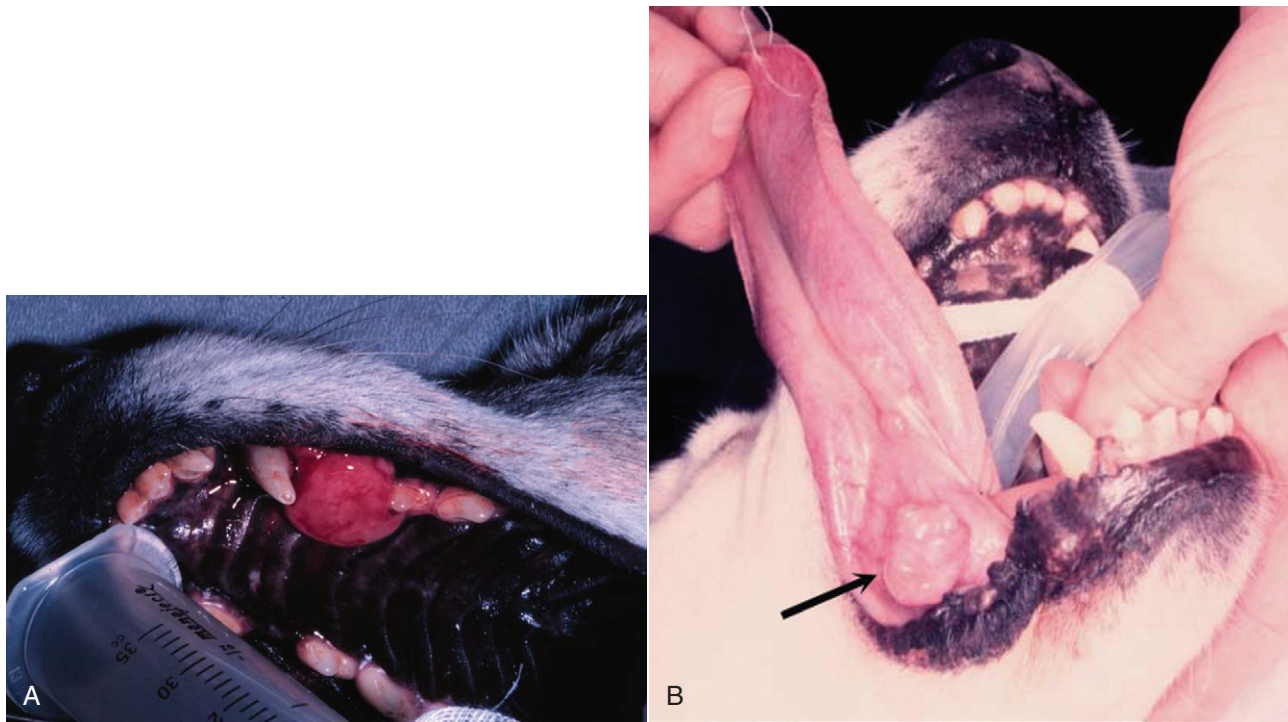
### Clinical Signs

Clinical signs associated with SOPs relate to the location of involvement, or in those rare cases with high levels of M component, HVS may occur. Most cutaneous plasmacytomas are solitary, smooth, raised pink nodules from 1 to 2 cm in diameter (see **Figure 32-28**), although tumors as large as 10 cm have been reported. Combining large series, greater than 95% occur as solitary masses and less than 1% occur as part of a systemic MM process.<sup>17,80-86,95,96</sup> Cutaneous and oral EMPs usually have a benign course with no related clinical signs. GI EMP, however, typically presents with relatively nonspecific signs, which may suggest alimentary involvement. Colorectal plasmacytomas usually present with rectal bleeding, hematochezia, tenesmus, and rectal prolapse.<sup>100</sup> One case of ataxia and seizure activity in a dog with EMP secondary to tumor-associated hypoglycemia has been reported.<sup>64</sup> SOP is usually associated with pain and lameness if the appendicular skeleton is affected or neurologic signs if vertebral bodies are involved.

### Diagnosis for Solitary Plasmacytic Tumors

The diagnosis of SOP and EMP usually requires tissue biopsy or FNA for diagnosis. Cells making up solitary plasmacytic tumors in both cats and dogs have been histologically classified into mature, hyaline, cleaved, asynchronous, monomorphous blastic and





**FIGURE 32-29** Examples of oral solitary plasmacytoma in dogs; one involving the maxilla (A), the other involving the underside of the tongue (B). Both dogs were cured following surgical excision.

polymorphous blastic cell types; however, no prognostic significance has been observed following classification, although it has been suggested that the polymorphous-blastic type may act more aggressively in the dog.<sup>17,86,103</sup> A different classification was proposed for EMP in cats based on percentage of plasmablasts (see previous section), and some prognostic importance has been documented.<sup>24</sup> In the case of poorly differentiated plasmacytic tumors, immunohistochemical studies, directed at detecting immunoglobulin, light- and heavy-chains, MM-1/interferon regulatory factor-4 (MUM1/IRF4), and thioflavin T, may be helpful in differentiation from other round cell tumors.<sup>33,85,86,106-110</sup> Immunoreactivity has been demonstrated for canine IgG F(ab)<sub>2</sub> and vimentin.<sup>82</sup> A variant characterized by an IgG-reactive amyloid interspersed with the neoplastic cells has also been described.<sup>83</sup> A panel of MAbs (recognizing tryptase, chymase, serotonin, CD1a, CD3, CD79a, CD18, MHC class II) in association with a histochemical stain (naphthol AS-D chloroacetate) has been advocated for use on formalin-fixed, paraffin-embedded sections of cutaneous round cell tumors to help classify poorly differentiated round cell tumors (mast cell tumors, histiocytomas, lymphomas, and plasmacytomas).<sup>109</sup> Additionally, clonality of the immunoglobulin heavy chain variable region gene can be performed in plasmacytomas and myelomas using PCR technology, and this may have some diagnostic utility in difficult cases.

It is important to thoroughly stage dogs and cats with plasmacytomas that are at higher risk for systemic spread if contemplating local or locoregional therapy without systemic therapy. This should include bone marrow aspiration, serum electrophoresis, abdominal ultrasound, and skeletal survey radiographs to ensure the disease is confined to a local site prior to initiation of therapy. This is most important in cases of SOP and GI EMP due to their relatively high metastatic rate and less important for cutaneous, oral, and colorectal plasmacytomas because of their more typical benign behavior.

For GI EMP (including colorectal EMP), endoscopic evaluation of the entire GI tract is recommended. A single case report of the use of PET/CT imaging for extramedullary splenic plasmacytoma in a dog exists; however, its utility remains unknown.<sup>111</sup>

### Therapy for Solitary Plasmacytic Tumors

Cutaneous and oral plasma cell tumors in the dog are almost always benign and carry an excellent prognosis following conservative surgical excision.<sup>17,81-86,100,112</sup> EMPs of the trachea, liver, and uterus have also been reported in dogs, and all had a benign course following local resection.<sup>92-94</sup> Successful therapy with melphalan and prednisone has been rarely applied for a local recurrence or incomplete margins in dogs and cats. RT has been used infrequently for cases that are nonsurgical, including the application of strontium-90 plesiotherapy for lingual plasmacytoma in a dog.<sup>113</sup> Surgery is recommended in combination with radiotherapy for those cases of SOP in which the lesion results in an unstable, long bone fracture (see Figure 32-22), or the patient is nonambulatory from neurologic compromise resulting from a vertebral body SOP. In the latter case, spinal cord decompression, mass excision, and possibly spinal stabilization may be necessary.<sup>63</sup> Radiotherapy can be used alone (i.e., without surgery) in those cases where fractures are stable, as a palliative measure for bone pain, or in the case of vertebral SOP if the patient is ambulatory and stable. Good local control is usually achieved; however, most go on to develop systemic multiple myeloma.<sup>33,63,102</sup> SOP of the axial skeleton can be managed by excision or radiotherapy alone. There is controversy as to whether systemic chemotherapy should be initiated at the time of local therapy for SOP when systemic involvement is not documented. Systemic spread may not occur for many months to even years beyond primary SOP diagnosis in humans and dogs, and studies in humans reveal no benefit derived from initiation of systemic chemotherapy prior to documentation of subsequent systemic spread.<sup>44,63</sup> Two

cases of SOP in cats were recently reported; one was treated with external-beam RT and one managed with melphalan chemotherapy and both enjoyed durable remissions of greater than 4 years.<sup>114</sup> Similarly, EMP of the GI tract in humans are treated most commonly by surgical excision and thorough staging of disease. Systemic therapy is not initiated unless systemic involvement is documented. Systemic chemotherapy has been used following gastric EMP in a cat; however, the utility of adjuvant therapy in the species is unknown.<sup>115</sup>

Long-term follow-up of patients with SOP is indicated in order to recognize both recurrence of disease and systemic spread. Careful attention is given to serum globulin levels, bone pain, and radiographic appearance of bone healing in cases of SOP. Restaging of disease, including bone marrow evaluation, is indicated if systemic spread is suspected.

Prognosis for solitary plasma cell tumors is generally good. Cutaneous and mucocutaneous plasmacytomas are usually cured following surgical excision.<sup>17,86,112</sup> In large compilations of cases in dogs, the local recurrence rate was approximately 5%, and nodal or distant metastasis occurred in only 7 of 349 cases (2%).<sup>17,80-82,86</sup> New cutaneous plasmacytomas at sites distant from the primary developed in less than 2% of cases. Neither tumor cell proliferation rate (as measured by Ki67 immunohistochemistry) in the dog nor histopathologic grading in dogs and cats were prognostic in large compilations of cases, although it has been suggested that the polymorphous-blastic and plasmablastic type may act more aggressively in the dog and cat.<sup>17,24,86</sup> The presence of amyloid and overexpression of cyclin D1 (prognostic in human plasmacytomas) were not shown to be of prognostic value in dogs.<sup>17</sup> Dogs with EMP of the alimentary tract and other abdominal organs (e.g., liver, uterus) treated by surgical excision alone or in combination with systemic chemotherapy (if metastasis is present) can enjoy long-term survival in the majority of cases.\* In a compilation of nine dogs with colorectal plasmacytoma, two dogs had local recurrence at 5 and 8 months following surgery, and the overall median survival was 15 months following surgery alone.<sup>100</sup> DNA ploidy and c-myc oncoprotein expression in biopsy samples were determined to be prognostic for EMPs in dogs; however, those that were malignant were all from noncutaneous sites (i.e., lymph node, colon, spleen). Therefore location appears to be as predictive.<sup>116</sup> As previously discussed, the majority of cases of SOP will eventually develop systemic disease; however, long disease-free periods usually precede the event.

The prognosis in cats is less well-defined because of the paucity of reported cases. If disease is confined to a local site and/or regional nodes, surgical excision and chemotherapy can result in long-term control; however, early, widespread metastasis and progression to MM is also reported in cats.†

## REFERENCES

- Matus RE, Leifer CE, MacEwen EG, et al: Prognostic factors for multiple myeloma in the dog, *J Am Vet Med Assoc* 188:1288-1291, 1986.
- Liu S-K, Dorfman HD, Hurvitz AI, et al: Primary and secondary bone tumors in the dog, *J Small Anim Pract* 18:313-326, 1977.
- Weiss DJ: A retrospective study of the incidence and the classification of bone marrow disorders in the dog at a veterinary teaching hospital (1996-2004), *J Vet Intern Med* 20:955-961, 2006.
- Tappin SW, Taylor SS, Tasker S, et al: Serum protein electrophoresis in 147 dogs, *Vet Rec* 168:456, 2011.
- Osborne CA, Perman V, Sautter JH, et al: Multiple myeloma in the dog, *J Am Vet Med Assoc* 153:1300-1319, 1968.
- MacEwen EG, Hurvitz AI: Diagnosis and management of monoclonal gammopathies, *Vet Clin North Am Small Anim Pract* 7:119-132, 1977.
- Engle GC, Brodey RS: A retrospective study of 395 feline neoplasms, *J Am Anim Hosp Assoc* 5:21-31, 1969.
- Carpenter JL, Andrews LK, Holzworth J: Tumors and tumor like lesions. In Holzworth J, editor: *Diseases of the cat: medicine and surgery*, Philadelphia, 1987, WB Saunders.
- Patel RT, Caceres A, French AF, et al: Multiple myeloma in 16 cats: a retrospective study, *Vet Clin Pathol* 34:341-352, 2005.
- Taylor SS, Tappin SW, Dodkin SJ, et al: Serum protein electrophoresis in 155 cats, *J Feline Med Surg* 12:643-653, 2010.
- Mellor PJ, Haugland S, Murphy S, et al: Myeloma-related disorders in cats commonly present as extramedullary neoplasms in contrast to myeloma in human patients: 24 cases with clinical follow-up, *J Vet Intern Med* 20:1376-1383, 2006.
- Hanna F: Multiple myelomas in cats, *J Feline Med Surg* 7:275-287, 2005.
- Potter M: A resume of the current status of the development of plasma cell tumors in mice, *Cancer Res* 28:1891-1896, 1968.
- Potter M, Morrison S, Weiner F, et al: Induction of plasmacytomas with silicone gel in genetically susceptible strains of mice, *J Natl Cancer Inst* 86:1058-1065, 1994.
- Imahori S, Moore GE: Multiple myeloma and prolonged stimulation of RES, *N Y State J Med* 72:1625-1628, 1972.
- Porter DD: The development of myeloma-like condition in mink with Aleutian disease, *Blood* 25:736-741, 1967.
- Cangul IT, Wunen M, van Garderen E, et al: Clinicopathological aspects of canine cutaneous and mucocutaneous plasmacytomas, *J Vet Med A Physiol Pathol Clin Med* 49:307-312, 2002.
- London CA, Hannah AL, Zadovskaya R, et al: Phase I dose-escalating study of SU11654, a small molecule receptor tyrosine kinase inhibitor, in dogs with spontaneous malignancies, *Clin Cancer Res* 9:2755-2768, 2003.
- Bourget CC, Grufferman S, Delzell E, et al: Multiple myeloma and family history of cancer, *Cancer* 56:2133-2139, 1985.
- Cuzick J, DeStavola B: Multiple myeloma: A case control study, *Br J Cancer* 57:516-520, 1988.
- Linnet MS, Sioban DH, McLaughlin JK: A case-control study of multiple myeloma in whites: chronic antigenic stimulation, occupation and drug use, *Cancer Res* 47:2978-2981, 1987.
- Radhakrishnan A, Risbon RE, Patel RT, et al: Progression of a solitary, malignant cutaneous plasma-cell tumour to multiple myeloma in a cat, *Vet Comp Oncol* 2:36-42, 2004.
- Burnett RC, Blake MK, Thompson LJ, et al: Evolution of a B-cell lymphoma to multiple myeloma after chemotherapy, *J Vet Intern Med* 18:768-771, 2004.
- Mellor PJ, Haugland S, Smith KC, et al: Histopathologic, immunohistochemical, and cytologic analysis of feline myeloma-related disorders: further evidence for primary extramedullary development in the cat, *Vet Pathol* 45:159-173, 2008.
- Valli VE, Jacobs RM, Parodi AL, et al: *Histological classification of hematopoietic tumors of domestic animals*, Washington, DC, 2002, Armed Forces Institute of Pathology and The World Health Organization.
- Drazner FH: Multiple myeloma in the cat, *Comp Cont Ed Pract Vet* 4:206-216, 1982.
- Jacobs RM, Couto CG, Wellman ML: Biclinal gammopathy in a dog with myeloma and cutaneous lymphoma, *Vet Pathol* 23:211-213, 1986.
- Peterson EN, Neining AC: Immunoglobulin A and immunoglobulin G biclinal gammopathy in a dog with multiple myeloma, *J Am Anim Hosp Assoc* 33:45-47, 1997.

\*References 33, 91-94, 97-99, 101.

†References 11, 22, 84, 103, 104, 107, 115.

29. Ramaiah SK, Sequin MA, Carwile HF, et al: Biclinal gammopathy associated with immunoglobulin A in a dog with multiple myeloma, *Vet Clin Pathol* 31:83–89, 2002.
30. Giraudel JM, Pages JP, Guelfi JF: Monoclonal gammopathies in the dog: A retrospective study of 18 cases (1986-1999) and literature review, *J Am Anim Hosp Assoc* 38:135–147, 2002.
31. Bienzle D, Silverstein DC, Chaffin K: Multiple myeloma in cats: Variable presentation with different immunoglobulin isotypes in two cats, *Vet Pathol* 37:364–369, 2000.
32. Facchini RV, Bertazzolo W, Zuliani D, et al: Detection of biclonal gammopathy by capillary zone electrophoresis in a cat and a dog with plasma cell neoplasia, *Vet Clin Pathol* 39:440–446, 2010.
33. MacEwen EG, Patnaik AK, Hurvitz AI, et al: Nonsecretory multiple myeloma in two dogs, *J Am Vet Med Assoc* 184:1283–1286, 1984.
34. Seelig DM, Perry JA, Avery AC, et al: Monoclonal gammopathy without hyperglobulinemia in 2 dogs with IgA secretory neoplasm, *Vet Clin Pathol* 39:447–453, 2010.
35. Braund KG, Everett RM, Bartels JE, et al: Neurologic complications of IgA multiple myeloma associated with cryoglobulinemia in a dog, *J Am Vet Med Assoc* 174:1321–1325, 1979.
36. Hurvitz AI, MacEwen EG, Middaugh CR, et al: Monoclonal cryoglobulinemia with macroglobulinemia in a dog, *J Am Vet Med Assoc* 170:511–516, 1977.
37. Hickford FH, Stokol T, vanGessel YA, et al: Monoclonal immunoglobulin G cryoglobulinemia and multiple myeloma in a domestic shorthair cat, *J Am Vet Med Assoc* 217:1029–1033, 2000.
38. Cowgill ES, Meel JA, Ruslander D: Light-chain myeloma in a dog, *J Vet Intern Med* 18:119–121, 2004.
39. Yamada O, Tamura K, Yagihara H, et al: Light-chain multiple myeloma in a cat, *J Vet Diagn Invest* 19:443–447, 2007.
40. Gentilini F, Calzolari C, Buonacucina A, et al: Different biological behaviour of Waldenstrom macroglobulinemia in two dogs, *Vet Comp Oncol* 3:87–97, 2005.
41. Hill RR, Clatworthy RH: Macroglobulinemia in the dog, the canine analogue of gamma M monoclonal gammopathy, *J S Afr Vet Med Assoc* 42:309–313, 1971.
42. Hurvitz AI, Haskins SC, Fischer CA: Macroglobulinemia with hyperviscosity syndrome in a dog, *J Am Vet Med Assoc* 157:455–460, 1970.
43. Anderson K: Plasma cell tumors. In Holland JF, Frei E, Bast RC, et al, editors: *Cancer medicine*, ed 3, Philadelphia, 1993, Lea & Febiger.
44. Salmon SE, Cassady JR: Plasma cell neoplasms. In DeVita VT, Hellman S, Rosenberg SA, editors: *Cancer: principles and practice of oncology*, ed 5, Philadelphia, 1997, JB Lippincott.
45. Shull RM, Osborne CA, Barrett RE, et al: Serum hyperviscosity syndrome associated with IgA multiple myeloma in two dogs, *J Am Anim Hosp Assoc* 14:58–70, 1978.
46. Center SA, Smith JF: Ocular lesions in a dog with hyperviscosity secondary to an IgA myeloma, *J Am Vet Med Assoc* 181:811–813, 1982.
47. Kirschner SE, Niyo Y, Hill BL, et al: Blindness in a dog with IgA-forming myeloma, *J Am Vet Med Assoc* 193:349–350, 1988.
48. Hendrix DV, Gelatt KN, Smith PJ, et al: Ophthalmic disease as the presenting complaint in five dogs with multiple myeloma, *J Am Anim Hosp Assoc* 34:121–128, 1998.
49. Hawkins EC, Feldman BF, Blanchard PC: Immunoglobulin A myeloma in a cat with pleural effusion and serum hyperviscosity, *J Am Vet Med Assoc* 188:876–878, 1986.
50. Williams DA, Goldschmidt MH: Hyperviscosity syndrome with IgM monoclonal gammopathy and hepatic plasmacytoid lymphosarcoma in a cat, *J Small Anim Pract* 23:311–323, 1982.
51. Forrester SD, Greco DS, Relford RL: Serum hyperviscosity syndrome associated with multiple myeloma in two cats, *J Am Vet Med Assoc* 200:79–82, 1992.
52. Hribernik TN, Barta O, Gaunt SD, et al: Serum hyperviscosity syndrome associated with IgG myeloma in a cat, *J Am Vet Med Assoc* 181:169–170, 1982.
53. Boyle TE, Holowaychuk MK, Adams AK, et al: Treatment of three cats with hyperviscosity syndrome and congestive heart failure using plasmapheresis, *J Am Anim Hosp Assoc* 47:50–55, 2011.
54. Mundy GR, Bertolini DR: Bone destruction and hypercalcemia in plasma cell myeloma, *Semin Oncol* 13:291–297, 1986.
55. Rosol TJ, Nagode LA, Couto CG, et al: Parathyroid hormone (PTH)-related protein, PTH, and 1,25-dihydroxyvitamin D in dogs with cancer associated hypercalcemia, *Endocrinology* 131:1157–1164, 1992.
56. Sheafor SE, Gamblin RM, Couto CG: Hypercalcemia in two cats with multiple myeloma, *J Am Animal Hosp Assoc* 32:503–508, 1996.
57. Twomey JJ: Infections complicating multiple myeloma and chronic lymphocytic leukemia, *Arch Intern Med* 132:562–565, 1973.
58. Webb J, Chary P, Northrup N, et al: Erythrophagocytic multiple myeloma in a cat, *Vet Clin Pathol* 37:302–307, 2008.
59. Yearly JH, Stanton C, Olivry T, et al: Phagocytic plasmacytoma in a dog, *Vet Clin Pathol* 36:293–296, 2007.
60. Hoenic M, O'Brien JA: A benign hypergammaglobulinemia mimicking plasma cell myeloma, *J Am Anim Hosp Assoc* 24:688–690, 1988.
61. Dewhirst MW, Stamp GL, Hurvitz AI: Idiopathic monoclonal (IgA) gammopathy in a dog, *J Am Vet Med Assoc* 170:1313–1316, 1977.
62. Van Bree H, Pollet L, Cousemont W, et al: Cervical cord compression as a neurologic complication in an IgG multiple myeloma in a dog, *J Am Anim Hosp Assoc* 19:317–323, 1983.
63. Rusbridge C, Wheeler SJ, Lamb CR, et al: Vertebral plasma cell tumors in 8 dogs, *J Vet Intern Med* 13:126–133, 1999.
64. DiBartola SP: Hypoglycemia and polyclonal gammopathy in a dog with plasma cell dyscrasia, *J Am Vet Med Assoc* 180:1345–1348, 1982.
65. Villiers E, Dobson J: Multiple myeloma with associated polyneuropathy in a German shepherd dog, *J Small Anim Pract* 39:249–251, 1998.
66. Mitcham SA, McGillivray SR, Haines DM: Plasma cell sarcoma in a cat, *Can Vet J* 26:98–100, 1985.
67. O'Keefe DA, Couto CG: Fine-needle aspiration of the spleen as an aid in the diagnosis of splenomegaly, *J Vet Intern Med* 1:102–109, 1987.
68. Werner JA, Woo JC, Vernau W, et al: Characterization of feline immunoglobulin heavy chain variable region genes for the molecular diagnosis of B-cell neoplasia, *Vet Pathol* 42:596–607, 2005.
69. Munshi NC, Anderson KC: Plasma cell neoplasms. In DeVita VT, Hellman S, Rosenberg SA, editors: *Cancer principles & practice of oncology*, ed 7, Philadelphia, 2005, Lippincott Williams & Wilkins.
70. Matus RE, Leifer CE, Jurvitz AI: Use of plasmapheresis and chemotherapy for treatment of monoclonal gammopathy associated with *Ehrlichia canis* infection in a dog, *J Am Vet Med Assoc* 190:1302–1304, 1987.
71. Breitschwerdt EB, Woody BJ, Zerbe CA, et al: Monoclonal gammopathy associated with naturally occurring canine ehrlichiosis, *J Vet Intern Med* 1:2–9, 1987.
72. MacEwen EG, Hurvitz AI, Hayes A: Hyperviscosity syndrome associated with lymphocytic leukemia in three dogs, *J Am Vet Med Assoc* 170:1309–1312, 1977.
73. Font A, Closa JM, Mascort J: Monoclonal gammopathy in a dog with visceral leishmaniasis, *J Vet Intern Med* 8:233–235, 1994.
74. Fan TM, Kitchell BE, Dhaliwal RS, et al: Hematological toxicity and therapeutic efficacy of lomustine in 20 tumor-bearing cats: critical assessment of a practical dosing regimen, *J Am Anim Hosp Assoc* 38:357–363, 2002.
75. Ferhangi M, Osseman EF: The treatment of multiple myeloma, *Sem Hematol* 10:149–161, 1973.
76. Bartges JW: Therapeutic plasmapheresis, *Sem Vet Med Surg* 12:170–177, 1997.
77. Farrow BRH, Penny R: Multiple myeloma in a cat, *J Am Vet Med Assoc* 158:606–611, 1971.
78. Milner RJ, Farese J, Henry CJ, et al: Bisphosphonates and cancer, *J Vet Intern Med* 18:597–604, 2004.



79. Kisseberth WC, MacEwen EG, et al: Response to liposome-encapsulated doxorubicin (TLC D-99) in a dog with myeloma, *J Am Vet Med Assoc* 9:425–428, 1995.
80. Clark GN, Berg J, Engler SJ, et al: Extramedullary plasmacytomas in dogs: results of surgical excision in 131 cases, *J Am Anim Hosp Assoc* 28:105–111, 1992.
81. Rakich PM, Latimer KS, Weiss R, et al: Mucocutaneous plasmacytomas in dogs: 75 cases (1980–1987), *J Am Vet Med Assoc* 194:803–810, 1989.
82. Baer KE, Patnaik AK, Gilbertson SR, et al: Cutaneous plasmacytomas in dogs: A morphologic and immunohistochemical study, *Vet Pathol* 26:216–221, 1989.
83. Rowland PH, Valentine BA, Stebbins KE, et al: Cutaneous plasmacytomas with amyloid in six dogs, *Vet Pathol* 28:125–130, 1991.
84. Lucke VM: Primary cutaneous plasmacytomas in the dog and cat, *J Small Anim Pract* 28:49–55, 1987.
85. Kyriazidou A, Brown PJ, Lucke VM: An immunohistochemical study of canine extramedullary plasma cell tumours, *J Comp Pathol* 100:259–266, 1989.
86. Platz SJ, Breuer W, Pflieger S, et al: Prognostic value of histopathological grading in canine extramedullary plasmacytomas, *Vet Pathol* 36:23–27, 1999.
87. Witham A, French A, Hill K: Extramedullary laryngeal plasmacytoma in a dog, *N Z Vet J* 60:61–64, 2012.
88. Hayes AM, Gregory SP, Murphy S, et al: Solitary extramedullary plasmacytoma of the canine larynx, *J Small Anim Pract* 48:288–291, 2007.
89. Perlmann E, Dagli ML, Martins MC, et al: Extramedullary plasmacytoma of the third eyelid gland in a dog, *Vet Ophthalmol* 12:102–105, 2009.
90. Schoniger S, Bridger N, Allenspach K, et al: Sinonasal plasmacytoma in a cat, *J Vet Diagn Invest* 19:573–577, 2007.
91. Van Wettere AJ, Linder KE, Suter SE, et al: Solitary intracerebral plasmacytoma in a dog: microscopic, immunohistochemical, and molecular features, *Vet Pathol* 46:949–951, 2009.
92. Chaffin K, Cross AR, Allen SW, et al: Extramedullary plasmacytoma in the trachea of a dog, *J Am Vet Med Assoc* 212:1579–1581, 1998.
93. Choi YK, Lee JY, Park JL, et al: Uterine extramedullary plasmacytoma in a dog, *Vet Rec* 154:699–700, 2004.
94. Aoki M, Kim T, Shimada T, et al: A primary hepatic plasma cell tumor in a dog, *J Vet Med Sci* 66:445–447, 2004.
95. Fukumoto S, Hanazono K, Kawasaki N, et al: Anaplastic atypical myeloma with extensive cutaneous involvement in a dog, *J Vet Med Sci* 2011. Epub ahead of print.
96. Mayer MN, Kerr ME, Grier CK, et al: Immunoglobulin A multiple myeloma with cutaneous involvement in a dog, *Can Vet J* 49:694–702, 2008.
97. Hamilton TA, Carpenter JL: Esophageal plasmacytoma in a dog, *J Am Vet Med Assoc* 204:1210–1211, 1994.
98. MacEwen EG, Patnaik AK, Johnson GF, et al: Extramedullary plasmacytoma of the gastrointestinal tract in two dogs, *J Am Vet Med Assoc* 184:1396–1398, 1984.
99. Jackson MW, Helfand SC, Smedes SL, et al: Primary IgG secreting plasma cell tumor in the gastrointestinal tract of a dog, *J Am Vet Med Assoc* 204:404–406, 1994.
100. Kupanoff PA, Popovitch CA, Goldschmidt MH: Colorectal plasmacytomas: A retrospective study of nine dogs, *J Am Anim Hosp Assoc* 42:37–43, 2006.
101. Trevor PB, Saunders GK, Waldron DR, et al: Metastatic extramedullary plasmacytoma of the colon and rectum in a dog, *J Am Vet Med Assoc* 203:406–409, 1993.
102. Meis JM, Butler JJ, Osborne BM, et al: Solitary plasmacytomas of bone and extramedullary plasmacytomas, *Cancer* 59:1475–1485, 1987.
103. Majzoub M, Breuer W, Platz SJ, et al: Histopathologic and immunophenotypic characterization of extramedullary plasmacytomas in nine cats, *Vet Pathol* 40:249–253, 2003.
104. Michau TM, Proulx DR, Rushton SD, et al: Intraocular extramedullary plasmacytoma in a cat, *Vet Ophthalmol* 6:177–181, 2003.
105. Carothers MA, Johnson GC, DiBartola SP, et al: Extramedullary plasmacytoma and immunoglobulin-associated amyloidosis in a cat, *J Am Vet Med Assoc* 195:1593–1597, 1989.
106. Kyriazidou A, Brown PJ, Lucke VM: Immunohistochemical staining of neoplastic and inflammatory plasma cell lesions in feline tissues, *J Comp Pathol* 100:337–341, 1989.
107. Breuer W, Colbatzky F, Platz S, et al: Immunoglobulin-producing tumours in dogs and cats, *J Comp Pathol* 109:203–216, 1993.
108. Brunnert SR, Altman NH: Identification of immunoglobulin light chains in canine extramedullary plasmacytomas by thioflavine T and immunohistochemistry, *J Vet Diagn Invest* 3:245–251, 1991.
109. Fernandez NJ, West KH, Jackson ML, et al: Immunohistochemical and histochemical stains for differentiating canine cutaneous round cell tumors, *Vet Pathol* 42:437–445, 2005.
110. Ramos-Vara JA, Miller MA, Valli VE: Immunohistochemical detection of multiple myeloma 1/interferon regulatory factor 4 (MUM1/IRF-4) in canine plasmacytoma: comparison with CD79a and CD20, *Vet Pathol* 44:875–884, 2007.
111. Lee AR, Lee MS, Jung IS, et al: Imaging diagnosis—FDG-PET/CT of a canine splenic plasma cell tumor, *Vet Radiol Ultrasound* 51:145–147, 2010.
112. Wright ZM, Rogers KS, Mansell J: Survival data for canine oral extramedullary plasmacytoma: a retrospective analysis (1996–2006), *J Am Anim Hosp Assoc* 44:75–81, 2008.
113. Ware K, Gieger T: Use of strontium-90 plesiotherapy for the treatment of a lingual plasmacytoma in a dog, *J Small Anim Pract* 52:220–223, 2011.
114. Mellor PJ, Polton GA, Brearley M, et al: Solitary plasmacytoma of bone in two successfully treated cats, *J Feline Med Surg* 9:72–77, 2007.
115. Zikes C, Spielman B, Shapiro W, et al: Gastric extramedullary plasmacytoma in a cat, *J Vet Intern Med* 12:381–383, 1998.
116. Frazier KS, Hines ME, Hurvitz AI, et al: Analysis of DNA aneuploidy and c-myc oncoprotein content of canine plasma cell tumors using flow cytometry, *Vet Pathol* 30:505–511, 1993.