

# Tuberculosis of spine: An experience of 30 cases over two years

Amey P. Patankar

Department of Neurosurgery, Baroda Medical College, SSG Hospital, Vadodara, Gujarat, India

## ABSTRACT

**Objective:** Tuberculosis of spine is still a very common condition in India. Here, the results of 30 cases of tuberculosis of spine treated in SSG Hospital, Vadodara, Gujarat, in the last two years, are reviewed.

**Materials and Methods:** A total of 30 patients with tuberculosis of spine were treated in SSG Hospital in the last two years. They were classified into three groups, based on the GATA, GATA = Gulhane Askeri Tip Akademisi (Gulhane Military Medical Academy) classification for spinal tuberculosis, with few modifications. Their neurologic status was evaluated by the Frankel's grading. All the patients were started on four drug anti-tuberculosis medication given every alternate day as per the DOTS and RNTCP program of the Government of India for 6 months. Patients in group 1 were treated by bed rest, analgesics, and antituberculous drugs after confirmation of the diagnosis by CT-guided biopsy. Patients in group 2 were treated by surgical of USG-guided aspiration of abscesses followed by full course of antituberculous drugs. Twenty-one patients in group 3 underwent surgery. A single-stage anterior decompression and anterior fixation was done in all the cases.

**Results:** All the nine patients in group I and 2 responded well to medical management and were cured of the disease. Out of the 21 operated patients, 19 had significant improvement in neurological status and return to their normal activities. The first operated patient died. The neurological status of one patient did not improve till 1 month after surgery and was lost to follow-up. Thus, 100% of group 1 and 2 patients were cured of the disease and 90% of group 3 patients had good neurological recovery.

**Conclusions:** If treated timely and adequately, the outcome for tuberculosis of spine is relatively good. Anterolateral approach to the spine with decompression and fixation gives good result with respect to neurological function.

**Key words:** Anterolateral approach to spine, Gulhane Askeri Tip Akademisi classification for tuberculosis of spine, instrumentation in tuberculosis of spine, post TB kyphosis

## Introduction

Tuberculosis and its various forms are still very rampant in India. Tuberculosis of spine is the most common and the most serious form of skeletal tuberculosis. The thoracic spine is the most common site of affection. Tuberculosis usually affects the intervertebral disc and the adjacent vertebral bodies, the

“paradiscal” area. Involvement of the posterior elements is very uncommon.

Antituberculous drugs from the mainstay of treatment with surgery are reserved for those with neurological symptoms. In India, patients usually present late, after the onset of neurological symptoms.

Here, the results in 30 patients with tuberculosis of spine, treated over the last two years in Neurosurgery unit of SSG Hospital, are reviewed. The neurologic status was graded according to Frankel's classification. Based on the neurologic status and MRI studies, the patients were classified into three categories as per the recommendations of the GATA classification,<sup>[1]</sup> with modifications.

## Materials and Methods

### Presentation

Patients with tuberculous involvement of the spine usually present with back pain or neck pain, which is exaggerated on

Access this article online	
Quick Response Code:	Website: www.asianjns.org
	DOI: 10.4103/1793-5482.145085

### Address for correspondence:

Dr. Amey P. Patankar, 303, Tower 2 B, Natraj Enclave,  
Near Jalaram Mandir, Karelibaug, Vadodara, Gujarat, India.  
E-mail: docapp@rediffmail.com

sitting, standing, and walking. Varying degrees of neurologic symptoms like difficulty in walking, tightness of the lower limbs, incontinence of urine, loss of sensation in the limbs and the trunk may be present depending on the degree of cord compression. On examination, tenderness may be elicited over the involved vertebra. There may be localized gibbus formation. Signs of neurologic compromise like hypertonia, weakness in the lower limbs, extensor plantar, exaggerated lower limb reflexes, and sensory loss may be present to varying degree. The neurologic status of the patients is graded according to Frankel's classification. Of the 30 patients, 20 were males and 10 were females with the ages ranging from 6 to 70 years.

The patients underwent further evaluation by X-rays and MRI of the spine, and were classified into three groups, based of the GATA classification for tuberculosis of spine [Table 1]. An example of each type is shown in Figures 1-3. The co-relation between neurological status according to Frankel's grade, site of involvement, and GATA classification is depicted in Table 2.

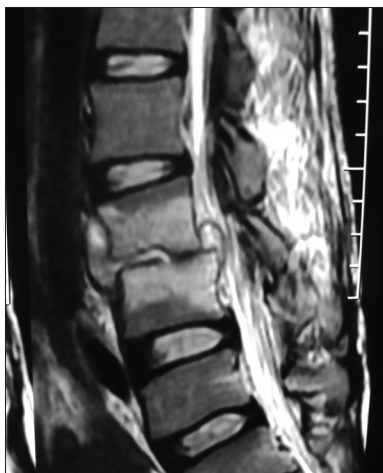### Treatment

All the patients were started four drug regimen (RHEZ) (10-20 mg/kg rifampicin, 5-10 mg/kg isoniazid, 15 mg/kg ethambutol, and pyrazinamide 25-30 mg/kg) antituberculous medication, given every alternate day, as per the DOTS and RNTCP program of the Government of India.

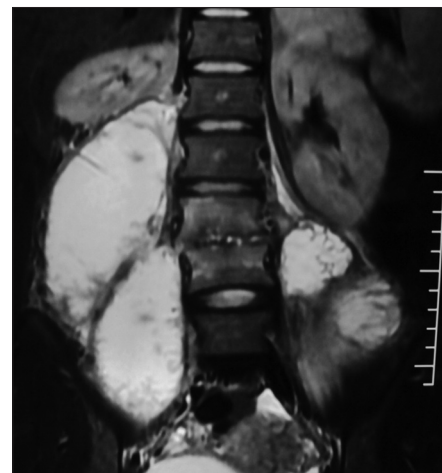
Four patients in group 1 were treated by bed rest, analgesics, and antituberculous drugs after confirmation of the diagnosis by CT-guided biopsy. Of the five patients in group 2, two patients underwent USG-guided aspiration of psoas abscess. One patient had to undergo thoracotomy and surgical drainage of pre and paravertebral and subcutaneous abscesses because of their large size. Two patients with cervical spine disease underwent surgical drainage of prevertebral and epidural abscesses with debridement of infected disc material. These two patients were operated by the anterior Smith-Robinson's approach by a transverse skin crease incision. After drainage of the prevertebral abscess, the infected disc material was curetted out. The posterior longitudinal ligament was opened

**Table 1: Based on the X-ray and MRI findings, patients were classified into three groups**

Group	MRI finding	Neurologic deficit	Treatment	No of patients	Example
1	The lesion located in one vertebra, one level disc degeneration, no collapse, no abscess, no evidence of spinal cord compression and canal compromise	No neurologic deficits	Fine needle biopsy for confirmation of diagnosis and antituberculous drug therapy	4	Figure 1
2	Abscess formation, one or two level disc degeneration, no vertebral body collapse no evidence of spinal cord compression and canal compromise	No neurologic deficits	Abscess drainage (by USG-guided aspiration or surgical drainage), debridement and antituberculous drug therapy	5	Figure 2
3	Vertebral collapse, abscess formation, kyphosis, radio logic evidence of cord compression	Neurologic deficit present	Anterior debridement and decompression  Anterior internal fixation by titanium cage filled with bone graft, and titanium bicortical screws and rods (plate and screws for cervical spine)	21	Figure 3



**Figure 1:** MRI example of group 1 with tuberculous spondylodiscitis of lumbar spine



**Figure 2:** MRI example of group 2, showing bilateral psoas abscess with lumbar tuberculosis

under microscope and the epidural pus was drained out. As there was no significant destruction of the adjacent vertebral bodies, no bone grafting and fixation was done.

In six of the above nine patients of group 2, the CT-guided biopsy was confirmatory of tuberculosis. In three patients, the picture was that of non-specific inflammation. These patients were given full course of antituberculous drugs, as the clinical and radiological picture was highly suggestive of tuberculosis. These patients responded to treatment and showed resolution of symptoms. Of the 21 patients in group 3, [Figures 4 and 5] undergoing surgery, 19 patients had thoracic spine involvement, one had involvement of the lumbar spine, and one had cervical spine involvement. Antero-lateral approach was used in all cases of thoracic and lumbar spine. One patient of group 3 with cervical spine involvement had significant destruction of the fourth cervical vertebra. After drainage of the abscess and discectomy of the infected disc material, corpectomy, bone grafting, and fixation by titanium plate and screws was done by Smith- Robinsons' approach.

Patients with thoracic spine involvement were treated by anterolateral approach by thoracotomy.

In the first seven cases, thoracotomy was done by cardiovascular surgeon. Then onwards, it was done by the neurosurgeon himself. For involvement above the level of 6<sup>th</sup> thoracic vertebra, the right-sided thoracotomy was done, as the arch of aorta interferes with vision on the left side. For lesion below D5, left-sided thoracotomy was done, as the liver on the right side makes access difficult.

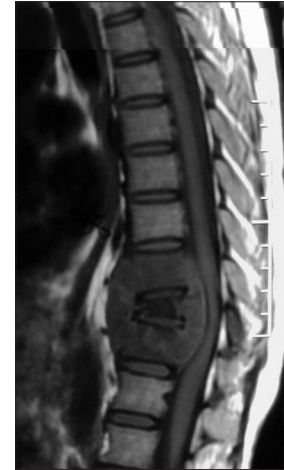Surgery was performed in the lateral position. Thoracotomy was two ribs above the level of the vertebral body involvement to account for the downward sloping of the ribs. For example, for tuberculosis involving the D8 vertebra, thoracotomy was done via 6<sup>th</sup> rib. Intraoperative monitoring of cord function like Somato Sensory Evoked Potential was not used as it is not available in SSG Hospital.

One patient, a six-year-old girl with involvement of the lumbar spine underwent similar procedure through the retroperitoneal anterolateral approach.

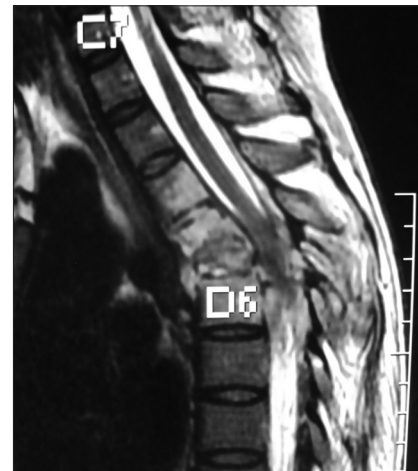**Postoperative treatment**

The patients were observed in an intensive care unit for one

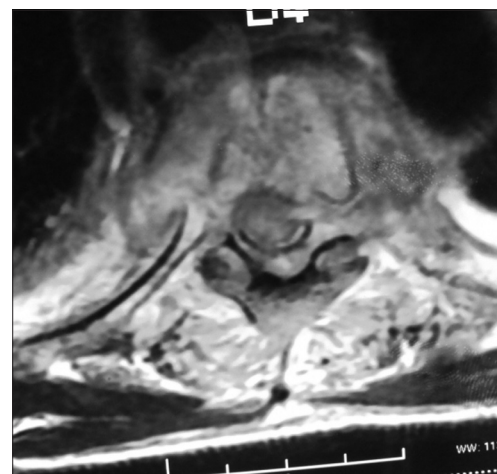
day. Intravenous antibiotics and analgesics, both opioids and non-opioids were used on the day of surgery. Chest and limb physiotherapy and incentive spirometry were started from the first postoperative day. Patients were allowed oral medications and a normal diet from the first postoperative



**Figure 3:** MRI example of group 3 with extensive vertebral destruction and epidural abscess



**Figure 4:** MRI showing D4 to D6 tuberculosis with cord compression



**Figure 5:** MRI axial section of Figure 8, of patient with D4 TB

**Table 2: Site of involvement, classification, and the degree of neurologic deficit according to Frankel's grading**

Site of involvement	No of patients	Group			Frankel's grade				
		1	2	3	A	B	C	D	E
Cervical	3	0	2	1	0	0	0	1	2
Thoracic	20	0	1	19	2	7	9	1	1
Lumbar	7	4	2	1	0	0	1	0	6

day. Oral antibiotics were continued for 7 days. Oral analgesics, both opioids and non-opioids, were used for four drug anti-tuberculous drugs were continued postoperatively according to RNTCP and DOTS program.

Patients were mobilized from the first day and were encouraged to walk with support. External support with a dorsolumbar brace was used for three months.

The intercostal drain was removed on 3<sup>rd</sup> or 4<sup>th</sup> postoperative day after confirming adequate lung expansion clinically and radiologically.

In patients with bladder involvement preoperatively, catheter was removed after power in the lower limb was restored to grade 3.

Stitches were removed on 9<sup>th</sup> postoperative day.

### Complications

The first operated patient developed sudden hypotension at the end of surgery. He had postoperative drain output of 2 l in 4 hours. He was re-explored, but no definite bleeding point could be found. He succumbed on the day of surgery.

All other operated patients did not develop any surgery-related or drug-related complications.

### Follow-up

X-ray and MRI of the spine were done at the end of first week to confirm adequate decompression and the position of the implants [Figure 6].

Histopathological confirmation of tuberculosis was obtained in 18 of the 21 operated cases. Three patients showed histological picture of non-specific inflammation, possibly because they were already taking antituberculous drugs 3-4 months prior to surgery. These patients were given the full course of antituberculous drugs, as the clinical, radiological, and operative picture was undoubtedly that of tuberculosis. Patients are being regularly

followed, first after 10-15 days and then every 3-4 months, with instructions to report any new symptom development.

### Results

All the nine patients of group 1 and 2 responded well to medical management. They gradually became pain-free, started gaining weight, and none of them developed any neurological symptoms in the one-year follow-up. One patient, operated for cervical spine tuberculosis, developed hepatotoxic side effects of INH, 1 month after surgery. After 6 months, she developed back pain. MRI showed inflammatory tuberculous spondylodiscitis of the D8 and D9 vertebrae, without any cord compression or collapse of vertebral body (group 1). She was treated as category two treatment failure cases according to the RNTCP guidelines. She responded to medical treatment and is symptom-free at present. Of the 21 operated patients, 19 had significant improvement in their symptoms, neurological status and return to their normal activities.

The first operated patient developed sudden hypotension at the end of surgery. He had postoperative drain output of 2 l in 4 hours. He was re-explored, but no definite bleeding point could be found. He succumbed on the day of surgery.

One patient with thoracic spine involvement had no improvement in neurologic status one month after surgery, and was lost to follow-up.

The neurologic status of the patients at 2 months of follow-up is shown in the Graph 1.

### Discussion

Tuberculosis of spine, though dreaded, has got relatively good prognosis if treated adequately and in a timely manner. Antituberculous drugs remain the mainstay of treatment, with surgery reserved for those with neurological deficit.

However, in India, patients usually present late, only after significant abscess formation and development of neuro deficits. The reasons for these being:

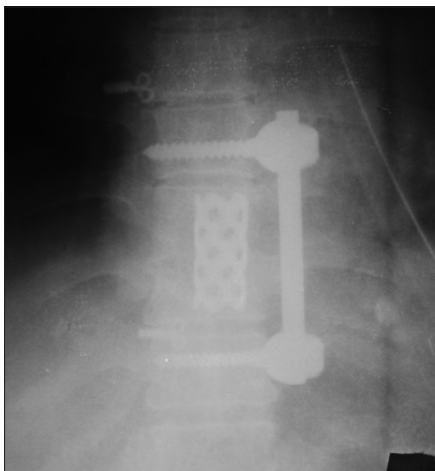
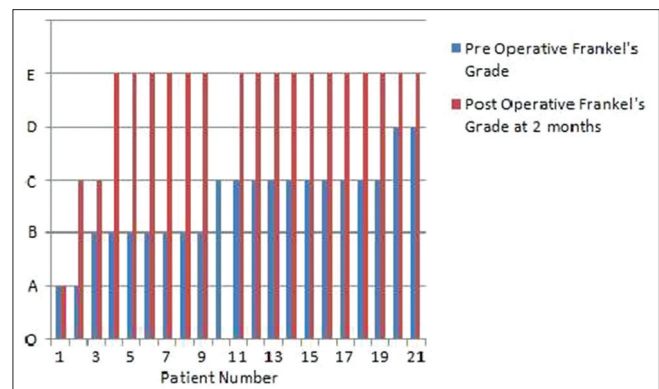


Figure 6: Postoperative X-ray to show position of implants



Graph 1: Neurological recovery at 2 months of follow-up

1. Illiterate patients stopping ATT midway
2. The alternate day treatment with ATT given under DOTS program of RNTCP may not have adequate effect in bone TB, because of relative avascularity of the bone, resulting in treatment failure. This is evidenced by neurological deterioration in 10 patients who were already taking ATT
3. The short-course chemotherapy for 6-8 months may not be sufficient to completely eradicate the disease from the avascular bone. Hence, 12-18 months of ATT would be better. However, this requires proper studies before this claim can be substantiated

The GATA system of classification<sup>[1]</sup> is a useful guide to classify and guide the treatment of the patients with tuberculous involvement of spine. Addition of a fourth group, to include patients with tuberculous involvement of the posterior column, though rare, only would complete the GATA classification.<sup>[2]</sup> Though the incidence of posterior column involvement is claimed to be as high as 10% in the Indian population,<sup>[2]</sup> in this series, there is no patient with involvement of the posterior column.

It is also interesting to note that all patients with involvement of the lumbar spine, except one, were treated conservatively and responded well to treatment.<sup>[3]</sup> These patients present with back pain, radiculopathy, and varying degrees of psoas-abscess formation. USG-guided aspiration of abscess, along with antitubercular drugs give excellent results in these patients.

In those requiring surgery, the anterior approach is preferred for the cervical spine and anterolateral transthoracic approach for the thoracic and thoracolumbar spine. This is because, tuberculosis usually involves the anterior column and this route offers the best route for decompression of the cord resulting in improvement in neurological function. Internal fixation and fusion with cage filled with bone-graft can be done at the same sitting, so as to provide immediate stabilization and mobilization. No significant difficulty was faced intraoperatively when using the transthoracic approach. In one patient, even in presence of adhesions, surgery was completed uneventfully. Adequate chest physiotherapy and mobilization of the patient prevents postoperative complications.

The addition of posterior fixation instrumentation in all patients with tuberculosis of spine, to prevent delayed kyphosis, is debatable. There are various studies which prove that anterior debridement, fusion, and anterior instrumentation provide good long-term results in terms of neurological recovery and kyphosis correction and prevention.<sup>[4-8]</sup> Addition of an anterior titanium cage filled with rib bone-graft would act as a strut to prevent vertebral body collapse.

The two bicortical screws inserted in the normal vertebral bodies above and below would provide a strong anterior support to resist the compressive forces. This would be

further reinforced by the external orthosis. Also, some degree of kyphosis correction is achieved by distraction anteriorly. Thus, addition of screw, rod, and cage fixation would offset the compressive forces and prevent the onset of delayed kyphosis. Hence, addition of posterior fixation in all the cases of tuberculosis of spine may not be required.

There are many advocates for single-stage combined anterior decompression and posterior fixation in tuberculosis of spine,<sup>[9]</sup> to prevent delayed onset kyphosis. However, only 3% of cases of tuberculosis of the spine develop a severe kyphotic deformity.<sup>[10]</sup> The patients at risk are those who developed the disease under the age of 10 years, who had involvement of three or more vertebral bodies and had lesions between C7 to L1.<sup>[10-12]</sup> Prolonged and costly single-staged, combined anterior and posterior fixation can be thus avoided by judicious selection of patients for the second-stage posterior fixation, only if they develop increasing kyphosis.<sup>[10-12]</sup> It not only adds to the operating time and its additional morbidity, but also to the cost of the implants. The patients with this disease usually belong to the poorest sections of the society, and cannot afford the additional cost of implants. This factor was also kept in mind while operating upon these patients, the immediate goal being restoration of neurologic function with early mobilization. In this series, there is only one patient under the age of 10 years, who was operated by the anterolateral retroperitoneal approach. This patient is under regular follow-up to detect increasing kyphosis.

The length of the present study, however, is at present insufficient to settle the debate for the need for posterior instrumentation in all cases of tuberculosis of spine.

There are various other advocated approaches like transpedicular and other modified posterior approaches, which have shown to provide equally good results as that of transthoracic approach.<sup>[12]</sup> The advantage of the transthoracic approach lies in the fact that the paraspinal cold abscesses can be completely drained. Also, the adequate exposure afforded by the transthoracic approach makes decompression of the cord safer as it can be carried out under direct vision without cord manipulation. Though various modified posterior and posterolateral approaches have shown equally good results,<sup>[12]</sup> the view and space available for decompression of the cord and abscess drainage is limited, and hence may lead to cord damage and insufficient decompression of the cord. The fear of morbidity for the transthoracic approach also appears to be exaggerated, as there has been no approach-related morbidity in this series, even with limited resources.

Thus, anterolateral transthoracic approach should be the initial approach of choice in tuberculosis of spine for adequate decompression. The posterior approach is best suited for kyphus correction, and can be used for those cases which go on to develop progressive kyphosis.<sup>[13]</sup>

## Conclusion

1. Antituberculous drugs remain the mainstays of treatment, with surgery reserved for those with neurological deficit and with extensive abscess formation
2. As tuberculosis affects the anterior elements of the spine in the majority of cases, anterior approach to the spine with debridement of the affected vertebra, decompression of the cord, and fixation of the spine should be the procedure of choice and has got excellent outcome
3. Addition of a posterior fixation in all the grade-3 patients may not be required and should be reserved for those patients who develop progressive kyphosis. This is especially true in a developing country like India where cost and human resources are major limiting factors and there is still an ongoing controversy regarding the merits and demerits of anterior vs posterior instrumentation in tuberculosis of spine. However, a longer follow-up is needed to settle this debate
4. The protocol of giving antitubercular drugs every alternate day as per the DOTS regime should be critically reviewed in tuberculosis of spine. Daily dosage for a longer period of 1-2 years will probably lead to a better outcome in tuberculosis of spine. However, this requires further studies.

## References

1. Oguz E, Sehirlioglu A, Altinmakas M, Ozturk C, Komurcu M, Solakoglu C, Vaccaro AR. A new classification and guide for surgical treatment of spinal tuberculosis. *Int Orthop* 2008;32:127-33.
2. Samuel S. Comment on Oguz *et al.*: A new classification and guide for surgical treatment of spinal tuberculosis. *Int Orthop* 2010;34:613.
3. Bhojraj S, Nene A. Lumbar and lumbosacral tuberculous spondylo discitis in adults. Redefining the indications for surgery. *J Bone Joint Surg Br* 2002;84:530-4.
4. Benli IT, Kaya A, Acaroğlu E. Anterior instrumentation in tuberculous spondylitis: Is it effective and safe? *Clin Orthop Relat Res* 2007;460:108-16.
5. Dai LY, Jiang LS, Wang W, Cui YM. Single-stage anterior autogenous bone grafting and instrumentation in the surgical management of spinal tuberculosis. *Spine (Phila Pa 1976)* 2005;30:2342-9.
6. Benli IT, Acaroğlu E, Akalin S, Kiş M, Duman E, Un A. Anterior radical debridement and anterior instrumentation in tuberculosis spondylitis. *Eur Spine J* 2003;12:224-34.
7. Benli IT, Kiş M, Akalin S, Citak M, Kanevetçi S, Duman E. The results of anterior radical debridement and anterior instrumentation in Pott's disease and comparison with other surgical techniques. *Kobe J Med Sci* 2000;46:39-68.
8. Benli IT, Alanay A, Akalin S, Kiş M, Acaroğlu E, Ateş B, *et al.* Comparison of anterior instrumentation systems and the results of minimum 5 years follow-up in the treatment of tuberculosis spondylitis. *Kobe J Med Sci* 2004;50:167-80.
9. El-Sharkawi MM, Said GZ. Instrumented circumferential fusion for tuberculosis of the thoracic-lumbar spine. A single or double stage procedure? *Int Orthop* 2012;36:315-24.
10. Tuli SM. Severe kyphotic deformity in tuberculosis of the spine. *Int Orthop* 1995;19:327-31.
11. Rajasekaran S, Soundarapandian S. Progression of kyphosis in tuberculosis of the spine treated by anterior arthrodesis. *J Bone Joint Surg Am* 1989;71-A: 1314-23.
12. Rajasekaran S. Kyphotic deformity in spinal tuberculosis and its management. *Int Orthop* 2012;36:359-65.
13. Garg B, Kandwal P, Nagaraja UB, Goswami A, Jayaswal A. Anterior versus posterior procedure for surgical treatment of thoracic lumbar tuberculosis: A retrospective analysis. *Indian J Orthop* 2012;46:165-70.

**How to cite this article:** Patankar AP. Tuberculosis of spine: An experience of 30 cases over two years. *Asian J Neurosurg* 2016;11:226-31.

**Source of Support:** Nil, **Conflict of Interest:** None declared.