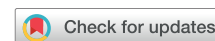



Since January 2020 Elsevier has created a COVID-19 resource centre with free information in English and Mandarin on the novel coronavirus COVID-19. The COVID-19 resource centre is hosted on Elsevier Connect, the company's public news and information website.

Elsevier hereby grants permission to make all its COVID-19-related research that is available on the COVID-19 resource centre - including this research content - immediately available in PubMed Central and other publicly funded repositories, such as the WHO COVID database with rights for unrestricted research re-use and analyses in any form or by any means with acknowledgement of the original source. These permissions are granted for free by Elsevier for as long as the COVID-19 resource centre remains active.

Serial Left and Right Ventricular Strain Analysis in Patients Recovered from COVID-19



Kathleen A. Young, MD, Hema Krishna, MD, Vaibhav Jain, MBBS, Izhan Hamza, MBBS, Christopher G. Scott, MS, Patricia A. Pellikka, MD, and Hector R. Villarraga, MD, Rochester, Minnesota

Background: Strain analysis of transthoracic echocardiography (TTE) is a sensitive tool to detect myocardial dysfunction in those affected by COVID-19. Consideration of preexisting cardiovascular disease is important in detecting changes related to COVID-19. We sought to assess serial TTE changes in patients recovered from COVID-19 compared with baseline, pre-COVID-19 exams, with a focus on left and right ventricular longitudinal strain.

Methods: This retrospective review of serial TTEs in confirmed COVID-19 patients at Mayo Clinic sites included patients who had a TTE within 2 years prior to confirmed COVID-19 diagnosis, and the first available outpatient TTE after diagnosis was used as a comparison. Patients with interval cardiac surgery, procedure, or device placement ($n = 9$) were excluded. Biventricular strain was retrospectively performed on both echocardiograms.

Results: Of 259 individuals, ages 60 ± 16 years, 47% female, and 88% Caucasian, post-COVID-19 TTEs were performed a median of 55 days (interquartile range, 37-92) following diagnosis. No clinically significant TTE changes were noted, although left ventricular ejection fraction was higher (58% vs 57%, $P = .049$) and tricuspid annulus plane systolic excursion was lower (20 vs 21 mm, $P = .046$) following COVID-19. Baseline left ventricular global longitudinal strain (LV GLS) and right ventricular free wall strain (RV FWS) were normal (-19.6% and -25.8% , respectively) and similar following COVID-19 (-19.6% and -25.7% , $P = .07$ and $.77$, respectively). In the 74 inpatients, no significant change from baseline was seen for LV GLS (-19.4% vs -19.1% , $P = .62$), RV FWS (-25.5% vs -25.0% , $P = .69$), or left ventricular ejection fraction (57% vs 57%, $P = .71$). A significant worsening in strain occurred in 27 patients, 16 (6.8%) of the 237 with LV GLS and 14 (6.0%) of the 235 with RV FWS. Ten (20%) patients reporting new symptoms following COVID-19 had worsened strain, compared with 5 (7%) with persistent/progressive symptoms and 11 (9%) with no new symptoms ($P = .04$).

Conclusions: While patients with new symptoms following COVID-19 were more likely to have a worsening in absolute strain values, no clinically significant change in TTE parameters was evident in most patients following COVID-19 regardless of symptom status. (J Am Soc Echocardiogr 2022;35:1055-63.)

Keywords: COVID-19, Post-COVID-19 syndrome, Echocardiography, Strain

Cardiac manifestations reported in COVID-19 patients have included acute coronary syndrome, arrhythmias, myocarditis, pericarditis, stress cardiomyopathy, and right ventricular dilation and dysfunction.¹⁻³ Strain is a sensitive tool for assessment of cardiac dysfunction, and investigations of echocardiographic findings in patients with COVID-19 have found right ventricular strain and left ventricular global longitudinal strain (LV GLS) to be associated with COVID-19-related death.^{4,5} However, among patients with COVID-19 undergoing clinically indicated echocardiography, preexisting heart disease has been common, with two-dimensional echocardiographic abnormalities present in 78% of patients who had undergone echocardiography prior to the diagnosis of COVID-19.⁶ Thus, many of the echocardiographic abnormalities identified on prior studies of patients with COVID-19 may have been preexisting.

Greater understanding of subtle changes in cardiac function attributable to COVID-19 is important because of the potential for chronic cardiopulmonary symptoms in some patients.^{7,8} Multiple studies

From the Department of Cardiovascular Medicine (K.A.Y., H.K., V.J., I.H., P.A.P., H.R.V.) and Division of Biomedical Statistics and Informatics (C.G.S.), Mayo Clinic, Rochester, Minnesota.

This research was supported by a grant from the Department of Cardiovascular Medicine and by Dr. Pellikka's Betty Knight Scripps Professorship, Mayo Clinic.

Conflicts of Interest: None.

R. Parker Ward, MD, FASE, served as guest editor for this report.

Reprint requests: Patricia A Pellikka, MD, Mayo Clinic, 200 First Street SW, Rochester, MN 55905 (E-mail: Pellikka.Patricia@mayo.edu).

Received April 28, 2022, and in revised form June 8, 2022. Accepted for publication June 14, 2022.

0894-7317/\$36.00

Copyright 2022 by the American Society of Echocardiography.

<https://doi.org/10.1016/j.echo.2022.06.007>

Abbreviations**IQR** = Interquartile range**LV GLS** = Left ventricular global longitudinal strain**LVEF** = Left ventricular ejection fraction**RV FWS** = Right ventricular free wall strain**RVSP** = Right ventricular systolic pressure**TAPSE** = Tricuspid annulus plane systolic excursion**TTE** = Transthoracic echocardiography

describing the echocardiographic findings, including biventricular strain analysis, of individuals recovered from COVID-19 have emerged.⁹⁻¹⁵

Most of these studies compare inpatient echocardiogram findings at the time of COVID-19 infection to echocardiograms obtained 1 to 4 months into recovery, with many suggesting residual subclinical cardiac dysfunction based on strain analysis.^{9,12-14}

However, comparison to pre-COVID-19 cardiac status is imperative. Oftentimes, inpatient COVID-19 echocardiograms

A significant worsening in strain was defined as a relative increase of $\geq 15\%$ from the pre-COVID-19 echocardiogram and to a value greater than -18% for LV GLS and greater than -24% for RV FWS.¹⁹⁻²³

Post-COVID-19 Symptoms

Chart review was completed on all patients to evaluate cardiopulmonary symptom status following COVID-19 infection. Charts of outpatient medical record notes at the time of the post-COVID-19 TTE were reviewed for documentation of new or persistent/progressive cardiopulmonary symptoms compared with the patient's pre-COVID-19 baseline. Symptoms evaluated included arrhythmia, cough, lightheadedness, edema, fatigue, chest pain, palpitations, and dyspnea. Patients were sorted into 1 of 3 categories: no symptoms, new symptoms, or persistent/progressive symptoms. Seven patients had indeterminate symptom status at the time of the post-COVID-19 TTE.

Statistical Analysis

Individual characteristics are presented as number (percentage) for categorical variables, mean (SD) for normally distributed continuous variables, and median (interquartile range IQR) for nonnormally distributed variables. Changes between measurements taken on pre- and post-COVID-19 echocardiograms were analyzed using paired *t* test for continuous variables that were approximately normally distributed or Wilcoxon signed-rank test for continuous variables that did not appear to be normally distributed. Categorical variables were compared between time points using McNemar's test. Comparisons of categorical variables between independent groups such as symptom status or significant changes in strain were based on chi-square test or Fisher's exact test. Comparison of continuous variables between independent groups was based on 2-sample *t* test or Wilcoxon rank-sum test. Comparison of changes between groups based on symptoms was based on analysis of variance methods. Subgroup analysis was also performed in those who were managed as inpatients for COVID-19. All analyses were performed using SAS version 9.4. Two-sided tests were used, and $P < .05$ was set as the level of significance.

RESULTS

A total of 259 individuals had both a baseline echocardiogram prior to their COVID-19 diagnosis and an outpatient echocardiogram completed after recovery from COVID-19 infection. The average age of the patients included was 60 years (SD = 16), 47% were female, and 88% were Caucasian (Table 1). Approximately two-thirds (71%) of the patients were managed for COVID-19 in the outpatient setting. There was a high prevalence of comorbidities at baseline, with hypertension (58%), congestive heart failure (31%), and cardiac arrhythmias (31%) occurring most frequently (Table 1).

Of the 74 patients that were hospitalized following COVID-19 diagnosis, 66 (89%) were admitted for symptomatic COVID-19 infection and 8 (11%) had an alternative primary admitting diagnosis. Six patients (8%) required intensive care unit level of care, 3 (4%) required mechanical ventilation, and 51 (69%) required supplemental oxygen.

The pre-COVID-19 echocardiogram was obtained a median of 220 days (IQR, 98-358) prior to laboratory-confirmed COVID-19 diagnosis. The post-COVID-19 echocardiogram occurred a median

grams will follow abbreviated protocols and may not be ideal for strain analysis.¹⁶⁻¹⁸ In addition, hemodynamic alterations related to acute respiratory distress syndrome or use of inotropes and mechanical ventilation could impact the results of studies obtained while patients are acutely ill, particularly right ventricular free wall strain (RV FWS).^{3,5} Therefore, the aim of this study was to evaluate serial echocardiographic changes in patients recovered from COVID-19 compared with their baseline, pre-COVID-19 echocardiogram, with a focus on left and right ventricular longitudinal strain.

METHODS**Study Design**

This is an Institutional Review Board–approved retrospective review of clinically indicated serial transthoracic echocardiography (TTE) in patients with laboratory-confirmed COVID-19 at Mayo Clinic sites. Patients were identified through Mayo Clinic's established registry of confirmed and recovered COVID-19 patients as of January 2021. Identified patients were then cross-referenced with the echocardiography laboratory database. Demographic and clinical information was abstracted from the medical record.

Patient Population

Included patients had a baseline TTE or stress TTE in the 2 years prior to their confirmed COVID-19 diagnosis (since January 1, 2019). The first available outpatient TTE following COVID-19 diagnosis was utilized for comparison. All baseline and follow-up TTEs were completed between January 2019 and February 2021. Medical records were reviewed for interim cardiac events; 3 patients with cardiac surgery were excluded. An additional 6 patients were excluded due to interval cardiac intervention or device placement, which could influence changes in serial strain analysis.

Echocardiography

Left and right ventricular longitudinal strain assessment was retrospectively performed on both echocardiograms to assess for changes that may be attributable to the diagnosis of COVID-19. This was completed by 3 experienced research sonographers who were blinded to the aims of the study. Strain analysis was completed with TomTec software, and the echocardiography core lab protocol was followed.

HIGHLIGHTS

- On average, no clinically significant differences were seen comparing pre- and post-COVID-19 TTEs.
- A new reduction of left or right ventricular strain after COVID-19 infection was uncommon.
- Reduction in strain was more common in patients with new symptoms following COVID-19.

of 55 days (IQR, 37-92) following COVID-19 diagnosis, with a median time of 327 days (IQR, 168-429) between pre- and post-COVID-19 studies. Time to post-COVID-19 echocardiogram following diagnosis was longer for those managed as inpatients versus outpatients, with a median of 68 days (IQR, 44-115) compared to 50 days (IQR, 33-77), respectively ($P < .001$).

Indications for pre- and post-COVID-19 echocardiograms were evaluated based on the referral diagnoses recorded at the time of echocardiography. Compared with the pre-COVID-19 indications, there were a higher number of echocardiograms obtained for the indication of heart failure on the post-COVID-19 studies ($n = 18$ vs $n = 31$, respectively; $P = .007$; [Figure 1](#)). There was no significant difference in the number of studies for the indications of left ventricular function, chest pain, palpitations, dyspnea, arrhythmia, or fatigue on the post-COVID-19 echocardiograms ([Figure 1](#)).

Echocardiography Data

Overall, no clinically significant changes were seen when comparing the baseline pre-COVID-19 echocardiograms to those obtained following recovery from COVID-19 infection ([Graphical Abstract, Table 2](#)). The average left ventricular ejection fraction (LVEF) at baseline was 57% (SD = 11), and it was 58% (SD = 11) following COVID-19 infection ([Table 2, P = .049](#)). When those patients who had been hospitalized for COVID-19 were evaluated separately, no

Table 1 Patient characteristics at the time of pre-COVID-19 echocardiogram

	Total (N = 259)	Significant worsening in LV GLS or RV FWS (n = 27)	No significant change in LV GLS or RV FWS (n = 225)	P value
Age, years, mean (SD)	60 (16)	64 (15)	60 (16)	.26
Gender, female, n (%)	122 (47)	16 (59)	101 (45)	.16
Body mass index, mean (SD)	30 (7)	30 (7)	30 (9)	.62
Race, n (%):				.32
White	227 (88)	22 (81)	200 (89)	
African American	18 (7)	3 (11)	14 (6)	
Native American	4 (2)	0 (0)	3 (1)	
Asian	2 (1)	1 (4)	1 (0.4)	
Other	6 (2)	1 (4)	7 (3)	
Hispanic ethnicity, n (%)	12 (5)	1 (4)	11 (5)	.78
COVID-19 management, n (%):				.07
Inpatient	74 (29)	12 (44)	61 (27)	
Outpatient	185 (71)	15 (56)	164 (73)	
Comorbidities, n (%):				
Hypertension	150 (58)	18 (67)	129 (57)	.36
Cardiac arrhythmias	79 (31)	13 (48)	65 (29)	.04
Congestive heart failure	81 (31)	15 (56)	60 (27)	.002
Coronary artery disease	60 (23)	4 (15)	53 (24)	.30
Cardiac amyloidosis	2 (1)	0 (0)	2 (1)	>.99
Cardiac transplant	16 (6)	2 (7)	13 (6)	.74
Diabetes mellitus	74 (29)	7 (26)	66 (29)	.73
Chronic kidney disease	47 (18)	6 (22)	39 (17)	.55
Dialysis	15 (6)	2 (7)	13 (6)	.74
Other organ transplant	17 (7)	3 (11)	14 (6)	.35
Stroke	20 (8)	4 (15)	16 (7)	.17
Chronic obstructive pulmonary disease or asthma	51 (20)	8 (30)	41 (18)	.16
Pulmonary circulation disorder	12 (5)	1 (4)	11 (5)	>.99
Chronic liver disease	18 (7)	0 (0)	18 (8)	.23
Cancer	75 (29)	10 (37)	63 (28)	.34
Current/former smoker	89 (34)	9 (33)	77 (34)	.94

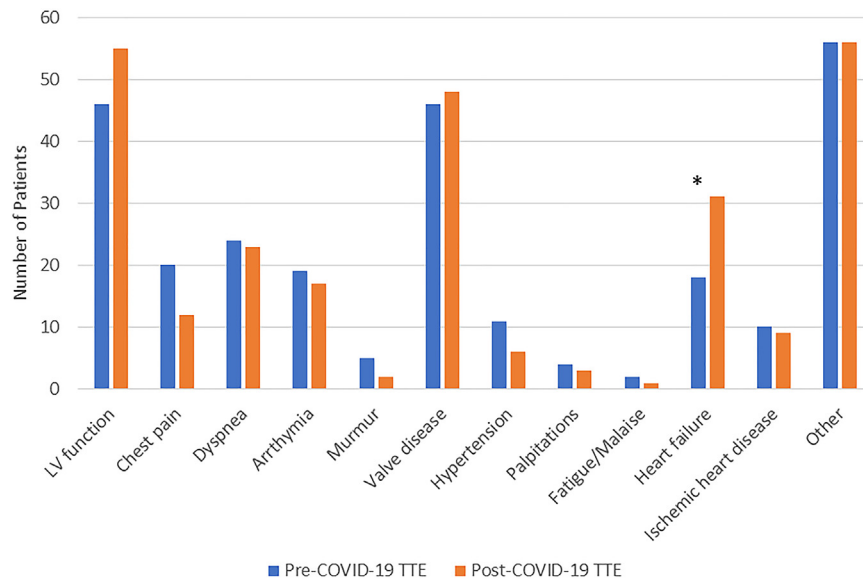


Figure 1 Comparison of TTE study indications for pre- and post-COVID-19 studies. Asterisk (*) denotes category with statistically significant difference between study dates; $P < .05$.

significant change was seen between the 2 studies (57% vs 57%, $P = .71$). There was no significant change in left ventricular size ($P = .26$) or regional wall motion abnormalities ($P = .76$). There was no significant change in diastolic function assessment including overall grade ($P = .53$), medial e' ($P = .50$), E/e' ($P = .52$), or left atrial volume index ($P = .43$). There was no significant change in overall right ventricular size ($P = .99$) or global systolic function ($P = .08$) compared to baseline. Right ventricular systolic pressure (RVSP) was not significantly different between the 2 studies ($P = .81$). As for other markers of RV systolic function, a smaller portion of individuals had tricuspid annulus plane systolic excursion (TAPSE) and RV s' reported on both studies ($n = 50$ and 69 , respectively). There was no significant change in RV s' ($P = .65$); however, TAPSE was higher prior to COVID-19 infection (21 vs 20, $P = .046$; [Table 2](#)).

Serial Left and Right Ventricular Strain Analysis

Left and right ventricular longitudinal strain was retrospectively analyzed in 237 (92%) and 235 (91%) of the included patients, respectively. LV GLS could not be measured in 15 (6%), RV FWS could not be measured in 17 (7%), and neither LV GLS nor RV FWS could be analyzed in 7 (3%) patients. Reasons for the inability to obtain strain analysis included poor image quality, contrast use, or incomplete acquisition of necessary views at the time of study completion. Prior to infection, mean LV GLS was normal at -19.6% (SD = 3.4). After COVID-19 infection, there was no significant change in the mean LV GLS (-19.6% , $P = .07$; [Table 2](#)). COVID-19 patients hospitalized following their diagnosis demonstrated no difference in LV GLS between pre- and post-COVID-19 echocardiograms (LV GLS, -19.4% vs -19.1% , respectively, $P = .62$; [Table 2](#)). Similarly, RV FWS was normal in all patients at the time of the pre-COVID-19 TTE (-25.8%) with no significant change following recovery from COVID-19 infection (-25.7% , $P = .77$; [Table 2](#)). Again, there was no difference comparing pre- and post-COVID-19 RV FWS in those patients who were hospitalized following their diagnosis (-25.5% vs -25.0% , $P = .69$; [Table 2](#)).

However, a clinically significant worsening in strain, defined as a relative increase of $\geq 15\%$ from the pre-COVID-19 echocardiogram and to a value greater than -18% for LV GLS and greater than -24% for RV FWS, was seen in 27 patients including 16 (6.8%) of the 237 patients with LV GLS and 14 (6%) of the 235 patients with RV FWS. Three patients had a significant worsening in both LV GLS and RV FWS. In the 16 patients with worsened LV GLS, pre-COVID-19 mean LV GLS was -19.9% (SD = 1.7), and post-COVID-19 it was -14.5% (SD = 1.9). In the 14 patients with worsened RV FWS, results were -27.1% (SD = 3.1) before and -18.6% (SD = 4.0) after COVID-19. Compared with those with no significant change in LV GLS or RV FWS ($n = 225$), those with a significant worsening in strain ($n = 27$) were more likely to have cardiac arrhythmias ($P = .04$) or heart failure ($P = .002$) at baseline ([Table 1](#)).

Correlation of Post-COVID-19 Symptoms and Echocardiographic Data

Cardiopulmonary symptom status following COVID-19 infection could be determined by chart review in 252 patients. New symptoms from the patient's baseline following COVID-19 infection were present in 49 (19%), and persistent/progressive symptoms were present in 70 (28%) patients. The remaining 133 (53%) patients had no symptoms following COVID-19 infection. By far, the most common symptom was dyspnea, which was present in 78 (66%) of the 119 with new or persistent/progressive symptoms ([Figure 2](#)). Patients with new symptoms more commonly reported fatigue ($P < .001$, [Figure 2](#)).

Changes in echocardiographic parameters for those with new symptoms following COVID-19 ($n = 49$) were compared to those with persistent/progressive symptoms ($n = 70$) or no symptoms ($n = 133$, [Table 3](#)). No statistically significant differences were seen between the groups ([Table 3](#)). Cardiac biomarker levels were recorded when available for hospitalized patients. There was no significant difference in peak cardiac troponin ($P = .84$) or N-terminal pro-brain natriuretic peptide ($P = .56$) values in those with new versus persistent/progressive versus no symptoms.

Table 2 Comparison of Pre-COVID-19 and post-COVID-19 echocardiographic characteristics

	Pre-COVID-19 echocardiogram (N = 259)	Post-COVID-19 echocardiogram (N = 259)	Data available, N	Change mean (SD)	P value
Heart rate, beats/min, mean (SD)	73 (14)	72 (13)	256	-0.2 (14.8)	.92
Atrial fibrillation/flutter, n (%)	22 (9)	20 (8)	240		.37
Systolic blood pressure, mm Hg, mean (SD)	130 (20)	132 (22)	257	1.0 (21.1)	.76
Diastolic blood pressure, mm Hg, mean (SD)	74 (13)	75 (12)	257	0.6 (12.6)	.84
LV GLS, %, mean (SD)	-19.6 (3.4)	-19.6 (3.6)	237	-0.1 (2.5)	.07
Managed as inpatient (n = 74), mean (SD)	-19.4 (3.0)	-19.1 (3.6)	70	0.2 (2.8)	.62
RV FWS, %, mean (SD)	-25.8 (4.5)	-25.7 (4.1)	235	0.01 (4.0)	.77
Managed as inpatient (n = 74), mean (SD)	-25.5 (4.6)	-25.0 (4.6)	65	0.2 (4.7)	.69
LVEF, %, mean (SD)	57 (11)	58 (11)	259	1.0 (7.7)	.049
Managed as inpatient (n = 74), mean (SD)	57 (12)	57 (12)	74	-0.4 (8.2)	.71
LV stroke volume index, mL/m ² , mean (SD)	44 (11)	45 (12)	183	0.5 (9.7)	.46
RWMSI, mean (SD)	1.1 (0.3)	1.1 (0.3)	265	0.01 (0.17)	.49
RWMSI >1, n (%)	35 (14)	36 (14)	259		.76
LV size, n (%):			252		.26
Normal	212 (83)	207 (81)			
Mildly enlarged	21 (9)	26 (10)			
Moderately enlarged	13 (5)	14 (5)			
Severely enlarged	8 (3)	9 (4)			
LV end-diastolic dimension, mm, mean (SD)	50 (7)	50 (7)	239	-0.2 (5.2)	.63
LV end-systolic dimension, mm, mean (SD)	34 (8)	33 (8)	219	-0.3 (4.8)	.36
LV end-diastolic volume, mL, mean (SD)	128 (56)	130 (60)	83	-3.2 (29.0)	.32
LV end-systolic volume, mL, mean (SD)	60 (44)	59 (45)	83	-3.1 (20.8)	.18
Septal wall thickness, mm, mean (SD)	11 (2)	11 (2)	212	0.01 (1.7)	.85
Posterior wall thickness, mm, mean (SD)	10 (2)	10 (2)	212	-0.08 (1.8)	.78
Relative wall thickness, mean (SD)	0.41 (0.09)	0.42 (0.09)	212	-0.001 (0.09)	.83
Diastolic function grade:			91		.53
Normal	46 (30)	32 (27)			
Grade 1	34 (22)	16 (13)			
Grade 2	14 (9)	10 (8)			
Grade 3	1 (1)	2 (2)			
Indeterminate	58 (38)	59 (50)			
Mitral E/A ratio, mean (SD)	1.2 (0.7)	1.3 (0.8)	170	-0.05 (0.69)	.67
Mitral annulus e' medial, m/sec, mean (SD)	0.07 (0.03)	0.07 (0.03)	183	0.0009 (0.02)	.50
Mitral E/e' (medial), mean (SD)	12.4 (6.9)	12.1 (6.2)	179	-0.2 (4.6)	.52
Left atrial volume index, mL/m ² , mean (SD)	35 (13)	35 (12)	129	-0.6 (8.4)	.43
Mitral valve regurgitation, moderate or greater, n (%)	14 (6)	13 (6)	211		.71
Tricuspid valve regurgitation, moderate or greater, n (%)	14 (6)	18 (7)	227		.48
Aortic valve regurgitation, moderate or greater, n (%)	5 (2)	7 (3)	191		.16
RV size, n (%):			241		.99
Normal	202 (82)	209 (83)			
Mildly enlarged	35 (14)	33 (13)			
Moderately enlarged	7 (3)	8 (3)			
Severely enlarged	2 (1)	1 (0.4)			
RV function, n (%):			241		.08
Normal	207 (83)	215 (85)			

(Continued)

Table 2 (Continued)

	Pre-COVID-19 echocardiogram (N = 259)	Post-COVID-19 echocardiogram (N = 259)	Data available, N	Change mean (SD)	P value
Mildly reduced	32 (13)	29 (12)			
Moderately reduced	8 (3)	7 (3)			
Right atrial pressure, mm Hg, mean (SD)	6 (3)	6 (3)	193	-0.2 (3.0)	.39
RVSP, mm Hg, mean (SD)	33 (11)	33 (12)	147	-0.2 (10.0)	.81
TAPSE, mm, mean (SD)	21 (5)	20 (5)	50	-1.3 (4.6)	.046
RV s', m/sec, mean (SD)	0.12 (0.03)	0.12 (0.03)	69	-0.002 (0.03)	.65
Pericardial effusion, n (%)	20 (8)	17 (7)	250		.53

LV, Left ventricular; RV, right ventricular; RWMSI, regional wall motion score index.

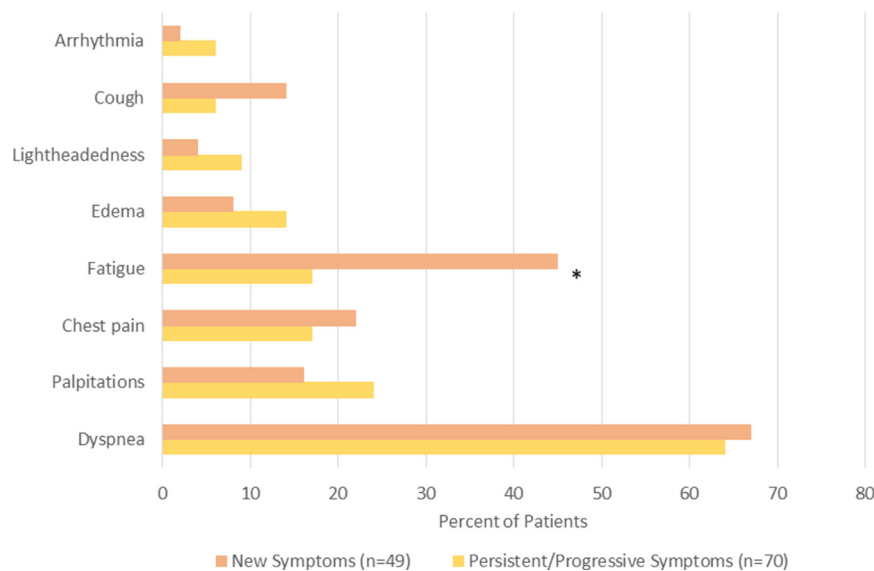


Figure 2 Post-COVID-19 symptom assessment was completed by chart review of clinical documentation at the time of the patient's post-COVID-19 TTE. The figure demonstrates the percentage of patients reporting a corresponding symptom, categorized by those with new symptoms versus patients reporting persistent/progressive symptoms. Asterisk (*) denotes category with statistically significant difference between those with new symptoms and those with persistent/progressive symptoms; $P < .05$.

Excluding the 7 patients with neither LV GLS nor RV FWS measurements available, patients were evaluated according to post-COVID-19 symptom status and change in strain (Graphical Abstract). Of the 49 patients with new symptoms following COVID-19, a significant worsening in LV GLS or RV FWS was present in 10 (20%). Patients with new symptoms following COVID-19 infection were more likely to have a clinically significant worsening in strain (20%) compared with those who had a clinically significant worsening in strain but with persistent/progressive symptoms (7%) or no symptoms (9%, $P = .04$; Graphical Abstract).

DISCUSSION

To our knowledge, this is the first study that evaluates echocardiographic changes related to COVID-19 infection by comparing baseline, pre-COVID-19 echocardiograms to those obtained following COVID-19 infection, thereby accounting for preexisting cardiovascular disease as well as abnormalities that might have been due to

hemodynamic perturbations related to acute COVID illness. In this retrospective study of 259 comorbid individuals managed either as inpatients or outpatients for their COVID-19 infection, no clinically significant differences were identified comparing pre- and post-COVID-19 echocardiograms. There was no difference in overall LV GLS and RV FWS between pre- and post-COVID-19 echocardiograms, even when those who were hospitalized following diagnosis were evaluated separately. However, a significant worsening in LV GLS and/or RV FWS occurred in a small portion of individuals (6.8% and 6.0%, respectively), and those reporting new cardiopulmonary symptoms following COVID-19 infection were more likely to have a clinically significant worsening in LV GLS and/or RV FWS.

As it was recognized that myocardial injury was common in acute COVID-19 infection with many potential cardiac manifestations,¹ TTE was readily poised to be the ideal diagnostic tool to help identify cardiac involvement and risk stratify patients. It was noted early on that both right and left ventricular strain were commonly abnormal in patients hospitalized with acute COVID-19 infection and were associated with increased COVID-19 mortality.^{4,5,24,25} However, in

Table 3 Changes in TTE parameters by post COVID symptom status

	No symptoms (N = 133)	Persistent/progressive symptoms (n = 70)	New symptoms (n = 49)	P value*
Echocardiogram:				
Heart rate, beats/min, mean (SD)	-1.4 (12.2)	-0.6 (17.4)	2.2 (17.2)	.36
Systolic blood pressure, mm Hg, mean (SD)	-0.7 (20.1)	5.4 (22.7)	-2.4 (18.0)	.09
Diastolic blood pressure, mm Hg, mean (SD)	0.9 (13.0)	1.2 (12.5)	-0.8 (11.2)	.66
LV GLS, %, mean (SD)	-0.4 (2.1)	-0.1 (2.4)	0.4 (3.3)	.20
Managed as inpatient (n = 69), mean (SD)	0.1 (3.1)	0.6 (2.0)	0.1 (3.5)	.63
RV FWS (%), mean (SD)	0.01 (3.7)	-0.5 (4.0)	0.7 (4.5)	.24
Managed as inpatient (n = 64), mean (SD)	0.4 (3.7)	-1.0 (4.7)	1.4 (5.8)	.26
LVEF (%), mean (SD)	1.3 (7.6)	1.4 (7.0)	-1.1 (8.8)	.15
Managed as inpatient (n = 73), mean (SD)	-0.2 (8.6)	1.2 (7.1)	-2.6 (8.8)	.30
LV stroke volume index, mL/m ² , mean (SD)	1.8 (9.7)	-1.5 (9.9)	0.2 (9.7)	.13
RWMSI, mean (SD)	-0.002 (0.18)	0.02 (0.20)	0.02 (0.08)	.62
LV end-diastolic dimension, mm, mean (SD)	-0.1 (4.9)	-0.9 (6.1)	0.6 (4.7)	.30
LV end-systolic dimension, mm, mean (SD)	-0.3 (5.0)	-1.1 (3.7)	0.7 (5.6)	.20
LV end-diastolic volume, mL, mean (SD)	-1.6 (34.6)	-1.5 (23.6)	-8.5 (20.2)	.69
LV end-systolic volume, mL, mean (SD)	-5.6 (23.7)	-0.7 (20.1)	0.5 (12.8)	.51
Septal wall thickness, mm, mean (SD)	-0.1 (1.6)	0.5 (2.0)	-0.2 (1.6)	.07
Posterior wall thickness, mm, mean (SD)	-0.07 (1.8)	0.07 (1.9)	-0.15 (1.6)	.82
Relative wall thickness, mean (SD)	-0.001 (0.09)	0.01 (0.11)	-0.01 (0.08)	.60
Mitral E/A ratio, mean (SD)	-0.11 (0.77)	-0.02 (0.67)	0.06 (0.42)	.47
Mitral annulus e' medial, m/sec, mean (SD)	0.002 (0.02)	-0.001 (0.02)	-0.001 (0.02)	.52
Mitral E/e' (medial), mean (SD)	-0.9 (4.8)	0.4 (4.1)	0.9 (4.4)	.07
Left atrial volume index, mL/m ² , mean (SD)	-1.6 (8.3)	1.1 (9.2)	-1.0 (7.1)	.30
Right atrial pressure, mm Hg, mean (SD)	-0.5 (3.0)	-0.4 (3.1)	0.4 (2.6)	.30
RVSP, mm Hg, mean (SD)	-0.9 (8.6)	-1.4 (10.7)	3.8 (12.6)	.11
TAPSE, mm, mean (SD)	-0.9 (5.7)	-1.2 (3.1)	-2.0 (4.5)	.87
RV s', m/sec, mean (SD)	0.004 (0.03)	-0.010 (0.03)	-0.004 (0.02)	.28

LV, Left ventricular; RV, right ventricular; RWMSI, regional wall motion score index.

*Analysis of variance P value reported for comparison across 3 groups.

acutely ill COVID-19 patients who can have advanced pulmonary involvement, abnormalities of cardiac function are often a reflection of the cardiac response to the stress and treatment (i.e., inotropes, mechanical ventilation) of a systemic inflammatory illness.³ Furthermore, we have previously shown that many of the cardiac abnormalities observed in patients with acute COVID-19 infection were preexisting.⁶

As the population of patients recovered from COVID-19 continues to grow, multiple publications have reported on echocardiographic findings following COVID-19 infection.⁹⁻¹⁵ Ozer *et al.*¹⁴ reported ongoing evidence of cardiac dysfunction based on abnormal LV GLS values in 1/3 of patients recovered from COVID-19 infection; however, there was no comparison to baseline or inpatient echocardiographic data. Lassen *et al.*¹² found that right ventricular function measured by right ventricular longitudinal strain and TAPSE improved with recovery from COVID-19; however, LV GLS remained reduced at 3 months post-COVID-19 diagnosis. This study also demonstrated that right and left ventricular strain in those recovered from COVID-19 were lower when compared with COVID-19-free matched controls.¹² Several other studies have compared inpatient echocardiographic findings at the time of COVID-19 infection to subsequent outpatient follow-up ranging from 1 to 4

months.^{9-11,13,15} The World Alliance Societies of Echocardiography COVID follow-up study, which included 153 paired baseline and follow-up echocardiograms, found no significant change in left or right ventricular function during recovery from COVID-19. However, when evaluated separately, those with impaired left or right ventricular function tended to improve.¹⁰ Other studies similarly suggest there is an overall trend toward improvement in biventricular function,^{11,15} with some studies noting concern for residual subclinical ventricular dysfunction based on strain analysis.^{9,13}

The current study is novel as it provides a comparison of outpatient post-COVID-19 echocardiograms to baseline pre-COVID-19 studies, thereby accounting for preexisting cardiovascular disease and avoiding acute and temporary imaging abnormalities and abbreviated examination protocols that are often followed in acute COVID-19 illness.¹⁸ Many echocardiographic parameters were evaluated in this population of patients recovered from COVID-19 infection, and no clinically significant differences were seen. These findings are additive to the current literature that has demonstrated there is improvement in many echocardiographic parameters following acute COVID-19 infection, further suggesting that when baseline cardiac function is taken into consideration, many patients will not experience a significant change in their cardiac structure or function due

to COVID-19 infection, even when assessed by a sensitive parameter such as strain.

However, we were able to identify a small portion of individuals that did experience a significant worsening in LV GLS and/or RV FWS following COVID-19 infection. These individuals were more likely to have cardiovascular comorbidities including cardiac arrhythmias and heart failure at baseline, which may contribute to a substrate for a change in strain with COVID-19 infection as preexisting cardiovascular disease has been associated with increased severity of illness.²⁶

Notably, a large portion of the studied patients did have a milder COVID-19 illness, with many managed as outpatients and with only a few of the inpatients requiring intensive care unit care and/or mechanical ventilation. However, this mirrors what is seen in clinical practice and represents findings from a true sample of recovered COVID-19 patients. Importantly, anyone with a history of COVID-19 may experience persistent cardiopulmonary symptoms following COVID-19 infection despite the severity of their illness, often termed long COVID or post-COVID syndrome.^{7,27,28} In our studied population, there was no increase in post-COVID-19 symptom-related indications for TTE such as chest pain, dyspnea, palpitations, and fatigue. However, further chart review was completed on all patients for cardiopulmonary symptom status following COVID-19 infection, which indeed showed 19% of patients reported new and 28% reported persistent/progressive symptoms from their pre-COVID-19 baseline at the time of their post-COVID-19 TTE.

Given the potential significant clinical impact of a large number of recovered patients with post-COVID syndrome, we sought to find any associations between post-COVID-19 symptom status and echocardiographic parameters. We saw no significant differences in the change of TTE findings between those reporting new symptoms, persistent/progressive symptoms, or no symptoms from baseline following COVID-19 infection. Interestingly, when LV GLS and RV FWS changes were evaluated in the context of post-COVID-19 symptoms, patients reporting new symptoms following COVID-19 were found to be more likely to have a clinically significant worsening in absolute LV GLS and/or RV FWS values compared with those with either persistent/progressive symptoms or no symptoms. Recently published expert consensus pathways recommend a basic cardiac evaluation, including TTE, for those with cardiopulmonary post COVID-19 symptoms,²⁹ particularly if they are new. The current study findings indicate that left and right ventricular strain assessment should be considered as part of a comprehensive TTE in those with post-COVID syndrome, as new strain abnormalities may indicate a need for further cardiac evaluation and/or follow-up.

Limitations

This study has limitations that should be acknowledged in the interpretation of the data. The goal of this study was to evaluate for echocardiographic changes pre- and post-COVID-19 infection. However, we did not track medication use or medication changes for this study, which may have influenced echocardiographic findings. In addition, the large portion of mild COVID-19 cases may limit our ability to see differences in studied parameters. Given the retrospective nature of the study, chart review and abstraction were completed for all patients, and we excluded those known to have interval cardiac surgery or invasive cardiac procedures, but it remains possible that some patients could have had interim events performed elsewhere that were not recognized. The generalizability of the findings is limited by the fact that only surviving patients were eligible for inclusion in this

retrospective review and that the population studied was largely Caucasian. Lastly, patients categorized as having persistent/progressive symptoms could indeed have delayed symptoms related to COVID-19 infection contributing to their post-COVID-19 symptom status; however, this is difficult to discern by chart review, so they are categorized separately from those with new symptoms from baseline for the purposes of this manuscript.

CONCLUSION

In this retrospective review of patients with both pre- and post-COVID-19 echocardiographic evaluation, no clinically significant change in TTE parameters was evident in most patients following COVID-19, even as detected by sensitive parameters such as strain analysis. However, patients reporting new symptoms following COVID-19 infection were more likely to have a clinically significant worsening in absolute values of LV GLS and/or RV FWS and warrant cardiac evaluation.

ACKNOWLEDGMENTS

We are grateful for the assistance of Mayo Clinic cardiovascular sonographers Zachary Barrett-O'Keefe, RDCS, Jessica A. Narum, RDCS, and James M. Welper, RDCS, who performed the retrospective strain analysis for this study.

REFERENCES

- Giustino G, Pinney SP, Lala A, Reddy VY, Johnston-Cox HA, Mechanick JL, et al. Coronavirus and cardiovascular disease, myocardial injury, and arrhythmia: JACC Focus Seminar. *J Am Coll Cardiol* 2020;76:2011-23.
- Kim J, Volodarskiy A, Sultana R, Pollie MP, Yum B, Nambiar L, et al. Prognostic utility of right ventricular remodeling over conventional risk stratification in patients with COVID-19. *J Am Coll Cardiol* 2020;76:1965-77.
- Pellikka PA, Naqvi TZ. The right ventricle: a target in COVID-19 cardiac insult. *J Am Coll Cardiol* 2020;76:1978-81.
- Lassen MCH, Skaarup KG, Lind JN, Alhakak AS, Sengelov M, Nielsen AB, et al. Echocardiographic abnormalities and predictors of mortality in hospitalized COVID-19 patients: the ECHOVID-19 study. *ESC Heart Fail* 2020;7:4189-97.
- Li Y, Li H, Zhu S, Xie Y, Wang B, He L, et al. Prognostic value of right ventricular longitudinal strain in patients with COVID-19. *JACC Cardiovasc Imaging* 2020;13:2287-99.
- Krishna H, Ryu AJ, Scott CG, Mandale DR, Naqvi TZ, Pellikka PA. Cardiac abnormalities in COVID-19 and relationship to outcome. *Mayo Clin Proc* 2021;96:932-42.
- Nalbandian A, Sehgal K, Gupta A, Madhavan MV, McGroder C, Stevens JS, et al. Post-acute COVID-19 syndrome. *Nat Med* 2021;27:601-15.
- Vehar S, Boushra M, Ntiamoah P, Biehler M. Post-acute sequelae of SARS-CoV-2 infection: caring for the "long-haulers." *Cleve Clin J Med* 2021;88:267-72.
- Baruch G, Rothschild E, Sadon S, Szekely Y, Lichter Y, Kaplan A, et al. Evolution of right and left ventricle routine and speckle-tracking echocardiography in patients recovering from coronavirus disease 2019: a longitudinal study. *Eur Heart J Cardiovasc Imaging* 2021. <https://doi.org/10.1093/ehjci/jeab190>.
- Karagodin I, Singulane CC, Descamps T, Woodward GM, Xie M, Tucay ES, et al. Ventricular changes in patients with acute COVID-19

- infection: follow-up of the World Alliance Societies of Echocardiography (WASE-COVID) Study. *J Am Soc Echocardiogr* 2022;35:295-304.
11. Bieber S, Kraechan A, Hellmuth JC, Muenchhoff M, Scherer C, Schroeder J, et al. Left and right ventricular dysfunction in patients with COVID-19-associated myocardial injury. *Infection* 2021;49:491-500.
 12. Lassen MCH, Skaarup KG, Lind JN, Alhakak AS, Sengelov M, Nielsen AB, et al. Recovery of cardiac function following COVID-19–ECHOVID-19: a prospective longitudinal cohort study. *Eur J Heart Fail* 2021;23:1903-12.
 13. Mahajan S, Kunal S, Shah B, Garg S, Palleda GM, Bansal A, et al. Left ventricular global longitudinal strain in COVID-19 recovered patients. *Echocardiography* 2021;38:1722-30.
 14. Ozer S, Candan L, Ozyildiz AG, Turan OE. Evaluation of left ventricular global functions with speckle tracking echocardiography in patients recovered from COVID-19. *Int J Cardiovasc Imaging* 2021;37:2227-33.
 15. van den Heuvel FMA, Vos JL, van Bakel B, Duijnhouwer AL, van Dijk APJ, Dimitriu-Leen AC, et al. Comparison between myocardial function assessed by echocardiography during hospitalization for COVID-19 and at 4 months follow-up. *Int J Cardiovasc Imaging* 2021;37:3459-67.
 16. Kaminski A, Payne A, Roemer S, Ignatowski D, Khandheria BK. Answering to the call of critically ill patients: limiting sonographer exposure to COVID-19 with focused protocols. *J Am Soc Echocardiogr* 2020;33:902-3.
 17. Kirkpatrick JN, Mitchell C, Taub C, Kort S, Hung J, Swaminathan M. ASE statement on protection of patients and echocardiography service providers during the 2019 novel coronavirus outbreak: endorsed by the American College of Cardiology. *J Am Soc Echocardiogr* 2020;33:648-53.
 18. Anand V, Thaden JJ, Pellikka PA, Kane GC. Safe operation of an echocardiography practice during the COVID-19 pandemic: single-center experience. *Mayo Clin Proc* 2021;96:531-6.
 19. Celutkiene J, Pudil R, Lopez-Fernandez T, Grapsa J, Nihoyannopoulos P, Bergler-Klein J, et al. Role of cardiovascular imaging in cancer patients receiving cardiotoxic therapies: a position statement on behalf of the Heart Failure Association (HFA), the European Association of Cardiovascular Imaging (EACVI) and the Cardio-Oncology Council of the European Society of Cardiology (ESC). *Eur J Heart Fail* 2020;22:1504-24.
 20. Lang RM, Badano LP, Mor-Avi V, Afilalo J, Armstrong A, Ernande L, et al. Recommendations for cardiac chamber quantification by echocardiography in adults: an update from the American Society of Echocardiography and the European Association of Cardiovascular Imaging. *J Am Soc Echocardiogr* 2015;28:1-39.e14.
 21. Voigt JU, Pedrizzetti G, Lysyansky P, Marwick TH, Houle H, Baumann R, et al. Definitions for a common standard for 2D speckle tracking echocardiography: consensus document of the EACVI/ASE/Industry Task Force to standardize deformation imaging. *J Am Soc Echocardiogr* 2015;28:183-93.
 22. Thavendiranathan P, Poulin F, Lim KD, Plana JC, Woo A, Marwick TH. Use of myocardial strain imaging by echocardiography for the early detection of cardiotoxicity in patients during and after cancer chemotherapy: a systematic review. *J Am Coll Cardiol* 2014;63:2751-68.
 23. Plana JC, Galderisi M, Barac A, Ewer MS, Ky B, Scherrer-Crosbie M, et al. Expert consensus for multimodality imaging evaluation of adult patients during and after cancer therapy: a report from the American Society of Echocardiography and the European Association of Cardiovascular Imaging. *J Am Soc Echocardiogr* 2014;27:911-39.
 24. Karagodin I, Carvalho Singulane C, Woodward GM, Xie M, Tucay ES, Tude Rodrigues AC, et al. Echocardiographic correlates of in-hospital death in patients with acute COVID-19 infection: the World Alliance Societies of Echocardiography (WASE-COVID) Study. *J Am Soc Echocardiogr* 2021;34:819-30.
 25. Rothschild E, Baruch G, Szekely Y, Lichter Y, Kaplan A, Taieb P, et al. The predictive role of left and right ventricular speckle-tracking echocardiography in COVID-19. *JACC Cardiovasc Imaging* 2020;13:2471-4.
 26. Yang J, Zheng Y, Gou X, Pu K, Chen Z, Guo Q, et al. Prevalence of comorbidities and its effects in patients infected with SARS-CoV-2: a systematic review and meta-analysis. *Int J Infect Dis* 2020;94:91-5.
 27. Raman B, Bluemke DA, Luscher TF, Neubauer S. Long COVID: post-acute sequelae of COVID-19 with a cardiovascular focus. *Eur Heart J* 2022;43:1157-72.
 28. Carfi A, Bernabei R, Landi F. For the Gemelli against COVID-19 Post-Acute Care Study group. Persistent symptoms in patients after acute COVID-19. *JAMA* 2020;324:603-5.
 29. Writing C, Gluckman TJ, Bhavne NM, Allen LA, Chung EH, Spatz ES, et al. 2022 ACC expert consensus decision pathway on cardiovascular sequelae of COVID-19 in adults: myocarditis and other myocardial involvement, post-acute sequelae of SARS-CoV-2 infection, and return to play: a report of the American College of Cardiology Solution Set Oversight Committee. *J Am Coll Cardiol* 2022;79:1717-56.