

Perioperative Evaluation of Cerebral Blood Flow Using ^{123}I -labeled *N*-isopropyl-*p*-iodoamphetamine Single-Photon Emission Computed Tomography without Blood Sampling in Patients Who Underwent Carotid Artery Stenting

Naoki Matsumoto, Rei Enatsu, Yasuzumi Matsui, Hiroyuki Ikeda, Norikazu Yamana, Masashi Oda, Masaaki Saiki, Osamu Narumi

Department of Neurosurgery, National Hospital Organization Himeji Medical Center, Himeji 670-8520, Hyogo, Japan

Key words: Carotid Artery Stenosis; Carotid Artery Stenting; *N*-isopropyl-*p*-iodoamphetamine-Rest and True Acetazolamide Images Estimated Method Using Dynamic Acquisition; Single-Photon Emission Computed Tomography

INTRODUCTION

The evaluation of regional cerebral vascular reserve (rCVR) with single-photon emission computed tomography (SPECT) is useful for predicting cerebral hyperperfusion following carotid artery stenting (CAS) and carotid endarterectomy (CEA).^[1] Quantitative SPECT dual table autoradiography (DTARG) is commonly used to evaluate regional cerebral blood flow (rCBF) and rCVR. However, this method requires arterial blood sampling, which is invasive and stressful for the patients.

The *N*-isopropyl-*p*-iodoamphetamine-rest and true acetazolamide images estimated method using dynamic acquisition (IMP-RAMDA) method is a noninvasive method with ^{123}I -labeled IMP which has the advantage of an excellent linearity of rCBF.^[2] It measures rCBF at rest and after an acetazolamide (ACZ) challenge, thereby enabling rCVR to be evaluated without any blood sampling. The IMP-RAMDA method is used at many institutions in Japan. However, the perioperative usefulness has fewly been reported. The purpose of our retrospective study was to investigate the perioperative usefulness of the IMP-RAMDA method.

CASE REPORT

Nine patients underwent CAS and one patient underwent CEA at our institution between August 2011 and March 2013. To conduct this study under similar conditions,

we enrolled nine consecutive patients with carotid artery stenosis who underwent CAS. Pre- and post-operative rCBF and preoperative rCVR were evaluated in all patients using the IMP-RAMDA method. We performed CAS under local anesthesia at least 1 month after an ischemic event. Postoperative SPECT was performed on the 1st postoperative day. The mean age was 76.4 years (range: 72–84 years), and six patients were male. Six patients were symptomatic whereas three were asymptomatic. The average degree of stenosis was $83.2 \pm 6.3\%$ (mean \pm standard deviation [SD], range: 70–90%), according to the North American Symptomatic Carotid Endarterectomy Trial criteria. We estimated resting rCBF and rCVR in the middle cerebral artery (MCA) areas. Cerebral hyperperfusion after CAS was defined as a CBF increase of $\geq 100\%$.^[3] Reduced rCVR was defined as $\text{CVR} < 12\%$.^[3] The following parameters were calculated:

- rCVR to ACZ: $([\text{rCBF after ACZ challenge} - \text{rCBF at rest}] / \text{rCBF at rest}) \times 100\%$
- Asymmetry index: $(\text{rCBF at rest on the CAS side} / \text{rCBF at rest on the contralateral side}) \times 100\%$.

Address for correspondence: Dr. Rei Enatsu,
Department of Neurosurgery, National Hospital Organization Himeji
Medical Center, 68 Motomachi, Himeji 670-8520, Hyogo, Japan
E-Mail: enatsur@gmail.com

This is an open access article distributed under the terms of the Creative Commons Attribution-NonCommercial-ShareAlike 3.0 License, which allows others to remix, tweak, and build upon the work non-commercially, as long as the author is credited and the new creations are licensed under the identical terms.

For reprints contact: reprints@medknow.com

© 2016 Chinese Medical Journal | Produced by Wolters Kluwer - Medknow

Received: 16-03-2016 **Edited by:** Peng Lyu

How to cite this article: Matsumoto N, Enatsu R, Matsui Y, Ikeda H, Yamana N, Oda M, Saiki M, Narumi O. Perioperative Evaluation of Cerebral Blood Flow Using ^{123}I -labeled *N*-isopropyl-*p*-iodoamphetamine Single-Photon Emission Computed Tomography without Blood Sampling in Patients Who Underwent Carotid Artery Stenting. Chin Med J 2016;129:1616-8.

Access this article online

Quick Response Code:



Website:
www.cmj.org

DOI:
10.4103/0366-6999.184473

Protocol of the *N*-isopropyl-*p*-iodoamphetamine-rest and true acetazolamide images estimated method using dynamic acquisition method and data analysis

The IMP-RAMDA method is a combination of Kawamura's method^[4] and the graph plot method [Figure 1a].^[5] SPECT study was performed using a two-head rotating gamma camera (E.cam, Toshiba Medical Systems Corporation, Tokyo, Japan) with a low-medium energy general purpose collimator. Data were obtained by continuous rotation in a 64 × 64 matrix. A dynamic scan was performed with the graph plot method^[5] for 2 min after the first

administration of IMP (111 MBq) in a 1 min intravenous infusion. Sequential 5 min SPECT scans were initiated 5 min after the administration of IMP and were performed four times. ACZ (17 mg/kg) was administered 15 min after the first administration of IMP. IMP (111 MBq) was then administered 25 min after its first administration as a 1 min intravenous infusion. Sequential 5 min SPECT scans were started 5 min later and performed four times. Regions-of-interest (ROI) were selected on the spatial resolution-equalized and nonequalized CBF images both at rest and after an ACZ challenge, using an automatic ROI definition tool, Neuro Flexer (Nihon Medi-Physics, Tokyo, Japan). Anterior cerebral artery areas were susceptible to the effect of cross flow from the opposite side. Therefore, we selected MCA areas as the target region.

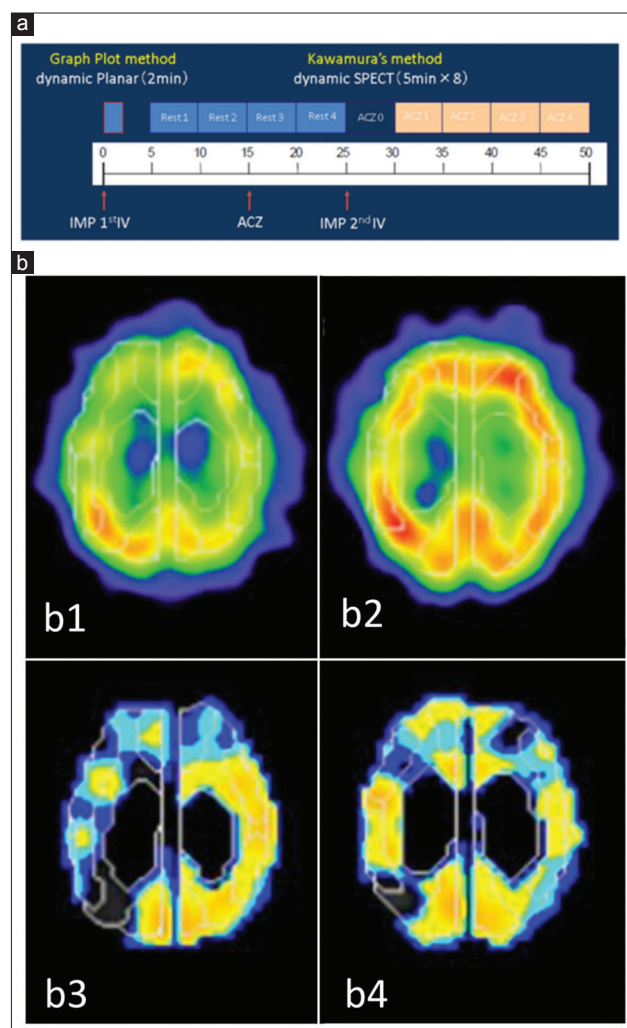


Figure 1: (a) Protocol of the IMP-RAMDA method. (b) SPECT images in a 77-year-old man with stenosis of the right carotid artery. Preoperative cerebral blood flow in the resting state determined by SPECT (b1) and postoperative cerebral blood flow in the resting state determined by SPECT (b2). Preoperative image of cerebrovascular reactivity determined with IMP-RAMDA method (b3) and postoperative image of cerebrovascular reactivity determined with IMP-RAMDA method (b4). Preoperative SPECT showing low cerebrovascular reactivity in the right hemisphere and the value was 11.83 (b3). Postoperative SPECT revealed increased cerebrovascular reactivity on the side of carotid artery stenting and the value was 26.44 (b4). IMP: *N*-isopropyl-*p*-iodoamphetamine; RAMDA: Rest and true acetazolamide images estimated method using dynamic acquisition; SPECT: Single-photon emission computed tomography; ACZ: Acetazolamide.

DISCUSSION

SPECT images (resting rCBF and rCVR) are shown in Figure 1b. CAS was successfully performed with no complications in all patients. The results of preoperative resting rCBF and rCVR are shown in Table 1, and the value of rCVR on the side of carotid artery stenosis was estimated to be $36.0 \pm 14.7\%$ (mean \pm SD, range: 11.8–58.1%). On the other hand, the rCVR value on the contralateral side was $54.0 \pm 14.4\%$ (mean \pm SD, range: 32.7–70.6%). These values are almost consistent with the previous ARG study.^[6] The pretreatment asymmetry index was estimated at $94.3 \pm 2.5\%$ (mean \pm SD, range: 90.2–97.9%) and was >75% in all patients. The ratio of postoperative resting rCBF to preoperative rCBF on the affected side was $104.2 \pm 10.7\%$ (mean \pm SD, range: 79.0–112.0%). Furthermore, the ratio of postoperative resting rCBF on the affected side compared to that of the contralateral side was $98.8 \pm 6.7\%$ (mean \pm SD, range: 90.6–112.6%). No patient developed cerebral hyperperfusion from the aspects of rCBF and clinical symptoms (e.g., headaches, seizures, and neurological deficits), and showed the significant laterality of postoperative rCBF.

The DTARG method quantitatively measures resting rCBF and rCVR within 1 h using arterial blood sampling. Arterial blood sampling is a painful procedure for patients and troublesome for hospital staff. We applied the IMP-RAMDA method to the perioperative evaluation of CAS for two purposes; (1) the postoperative detection and (2) the preoperative prediction of cerebral hyperperfusion.

The risk factors for postoperative cerebral hyperperfusion include (1) reduced CVR and (2) a pretreatment asymmetry index.^[1] Kaku *et al.*^[1] suggested that a pretreatment asymmetry index under 75% was a risk factor for cerebral hyperperfusion. In our study, no patient showed a reduction in CVR under 12%, except for one patient with a mild CVR reduction, and the pretreatment asymmetry index was over 75% in all patients. Therefore, all patients were considered to be of low risk for postoperative cerebral hyperperfusion. In our study, no patient showed cerebral hyperperfusion. These results indicate that the rCBF study with the IMP-RAMDA method correlated

Table 1: Results of perioperative rCBF and CVR with IMP-RAMDA method

Patients No.	Side of CAS			Contralateral side				
	rCBF (ml·100 g ⁻¹ ·min ⁻¹)		P	rCVR (%)	rCBF (ml·100 g ⁻¹ ·min ⁻¹)			rCVR (%)
	Before CAS	After CAS		Before CAS	Before CAS	After CAS	P	Before CAS
1	38.1	43.2	0.236	53.4	39.5	38.4	0.859	66.1
2	34.2	39.6		44.6	37.9	43.7		45.4
3	38.1	39.2		25.1	40.8	38.8		66.8
4	35.0	36.6		43.5	37.1	37.3		68.5
5	43.6	44.8		39.5	44.8	45.1		47.8
6	47.8	37.8		11.8	48.9	39.0		32.7
7	34.9	38.5		19.9	37.7	37.9		70.6
8	38.2	42.8		58.1	41.8	47.7		50.1
9	47.1	45.5		28.0	49.5	45.6		37.2

P values are derived from Wilcoxon signed rank test (IBM SPSS statistics version 22 procedure [IBM Corp., Armonk, NY, USA]). rCBF: Regional cerebral blood flow; CVR: Cerebral vascular reserve; IMP: *N*-isopropyl-p-iodoamphetamine; RAMDA: Rest and true acetazolamide images estimated method using dynamic acquisition; CAS: Carotid artery stenting.

well with the clinical manifestations and can be used to evaluate hemodynamic changes after CAS. To evaluate the detectability of cerebral hyperperfusion, we need to accumulate the data of patients who underwent perioperative evaluations with the IMP-RAMDA method.

Limitations

Our study is limited by its small sample size. Furthermore, no patient developed cerebral hyperperfusion; hence, the study is limited by inferring the predictability of CVR reductions with the IMP-RAMDA method for cerebral hyperperfusion. Our present study was also a retrospective study. Postoperative CVR was measured in only one patient [Figure 1] and perioperative hemodynamic changes were not evaluated in detail. Therefore, we need to accumulate data from more cases to establish the usefulness of the IMP-RAMDA method in predicting cerebral hyperperfusion and evaluating CVR changes.

Financial support and sponsorship

Nil.

Conflicts of interest

There are no conflicts of interest.

REFERENCES

1. Kaku Y, Yoshimura S, Kokuzawa J. Factors predictive of cerebral hyperperfusion after carotid angioplasty and stent placement. *AJNR Am J Neuroradiol* 2004;25:1403-8.
2. Iida H, Akutsu T, Endo K, Fukuda H, Inoue T, Ito H, *et al.* A multicenter validation of regional cerebral blood flow quantitation using [¹²³I] iodoamphetamine and single photon emission computed tomography. *J Cereb Blood Flow Metab* 1996;16:781-93. doi: 10.1097/00004647-199609000-00003.
3. Hosoda K, Kawaguchi T, Shibata Y, Kamei M, Kidoguchi K, Koyama J, *et al.* Cerebral vasoreactivity and internal carotid artery flow help to identify patients at risk for hyperperfusion after carotid endarterectomy. *Stroke* 2001;32:1567-73. doi: 10.1161/01.STR.32.7.1567.
4. Kawamura Y, Ashizaki M, Saida S, Sugimoto H. Usefulness of rate of increase in SPECT counts in one-day method of *N*-isopropyl-4-iodoamphetamine [¹²³I] SPECT studies at rest and after acetazolamide challenge using a method for estimating time-dependent distribution at rest. *Ann Nucl Med* 2008;22:457-63. doi: 10.1007/s12149-008-0134-3.
5. Okamoto K, Ushijima Y, Okuyama C, Nakamura T, Nishimura T. Measurement of cerebral blood flow using graph plot analysis and I-123 iodoamphetamine. *Clin Nucl Med* 2002;27:191-6. doi: 10.1097/00003072-200203000-00009.
6. Nakagawara J. Clinical neuroimaging of cerebral ischemia (In Japanese). *No To Shinkei (Brain Nerve)* 1999;51:502-13.