

Cholesterol granuloma of the anterior mediastinum with osseous metaplasia

Tarek Frederick Ezzat, Salem Alowami
McMaster University, Canada

Abstract

Cholesterol granuloma is a well-characterized entity comprised of a foreign-body giant cell-reaction that forms in response to the presence of cholesterol crystals. It is usually found in the middle-ear or mastoid process in patients with diseases associated with chronic inflammation such as cholesteatoma and otitis media. They are rarely seen in the mediastinum. Osseous metaplasia is an exceedingly rare feature of cholesterol granulomas only reported twice in the literature. We report a case of a cholesterol granuloma of the anterior mediastinum with osseous metaplasia in a 75 year-old man that was found incidentally during urgent coronary artery bypass graft surgery.

Case Report

A 75 year-old male with a history of angina, hypertension, peripheral vascular disease, smoking addiction, chronic obstructive pulmonary disease, dyslipidemia, and a remote motor vehicle collision had undergone urgent coronary artery bypass graft for acute non-ST-elevation myocardial infarction. Pre-operative chest radiography showed a questionable density in the anterior mediastinum that was attributed to a shadowing effect of the first rib (Figure 1). During surgery, a pair of firm, well-circumscribed masses was found in the anterior mediastinum and thymic remnant; these were excised. The dimensions of each nodule were 3.0×3.0×2.0 cm, and their cut surfaces were granular. One of the nodules was diffusely hemorrhagic and focally calcified, while the other was yellow and fatty. The nodules were entirely submitted. The microscopic images revealed relatively large needle-shaped crystals surrounded by multinucleate giant cells and histiocytes, some of which had phagocytosed hemosiderin granules, consistent with a cholesterol granuloma (Figure 2). Osseous metaplasia was also noted in the calcified nodule (Figures 3 and 4). The patient recovered without incident and was discharged from hospital.

Discussion

Cholesterol granulomas are frequently described occurring in the temporal bone as a result of inflammatory ear disease.¹ However, they are not exclusive to this location. An intraventricular cholesterol granuloma near the septum pellucidum thought to be secondary to remote head trauma from a motor vehicle collision was previously reported.² Orbitofrontal cholesterol granulomas have been associated with trauma as miniscule as a bee sting,³ and have been shown to recur after incomplete excision.³⁻⁵ Some of these have been reported to exhibit evidence of dysplasia of the adjacent bone, suggesting a pre-existing bony or vascular anomaly as a possible etiology.⁶ Renal cholesterol granulomas were thought to be associated in separate cases with hypercholesterolemia or atheromatous cholesterol emboli and epithelioid angiomyolipoma.^{7,8} In the breast, the inciting event was postulated to be duct ectasia or periductal inflammation.⁹ Previously reported anterior mediastinal cholesterol granulomas have been associated with prior trauma and multilocular thymic cyst.^{2,10,11} Pancreatic cholesterol granuloma with peritoneal dissemination has been observed and may have been due to prior episodes of acute pancreatitis.¹² There has been a case of multiple cholesterol granulomas associated with multiple endocrine neoplasia type-1, thought to be caused by systemic distribution of pancreatic enzymes.¹³

Regarding the general theory of the pathogenesis of these lesions, the prevailing wisdom believes that a traumatic or inflammatory event incites tissue hemorrhage. Subsequent erythrocyte degeneration, coupled with a local milieu of inflammatory cytokines, attracts immune cells to the region. Cholesterol from the destroyed cell membranes forms crystalline complexes which provoke a foreign-body giant-cell reaction.¹⁴ This process can result in a slow-growing mass which has the potential to be locally aggressive.² Hyperlipidemia, cholesterol emboli, and impaired lymphatic drainage may also play a role in the formation of these lesions.^{7,10}

Osseous metaplasia is an extremely rare and pathogenically mysterious feature of cholesterol granulomas that has been reported only twice before in the literature: in the breast and fallopian tube.^{9,15} It is theorized to be the result of pluripotent cell, mesenchymal cell, and fibroblastic differentiation into osteoblasts due to stimulation by pro-inflammatory cytokines such as interleukins and transforming-growth-factor-beta, and bone morphogenetic proteins.¹⁶⁻¹⁸

In the case of our patient, the remote motor vehicle collision that he had experienced in

Correspondence: Tarek Frederick Ezzat,
McMaster University, Canada.
E-mail: tezzat@dal.ca

Key words: metaplasia, mediastinum, tumor, granuloma, benign.

Conflict of interests: the authors report no potential conflict of interests.

Received for publication: 5 November 2011.

Revision received: 13 July 2012.

Accepted for publication: 13 July 2012.

This work is licensed under a Creative Commons Attribution NonCommercial 3.0 License (CC BY-NC 3.0).

©Copyright T.F. Ezzat and S. Alowami, 2012
Licensee PAGEPress, Italy
Rare Tumors 2012; 4:e47
doi:10.4081/rt.2012.e47

decades prior likely caused hemorrhage of anterior mediastinal soft tissues. The subsequent inflammatory response and erythrocyte breakdown stimulated a foreign-body giant-cell reaction to the cholesterol crystals formed from the plasma membranes of the degenerated cells. Though not entirely explainable, the environment within the area of the cholesterol granuloma encouraged the development of mature osteoid. Another less likely possibility is that small fragments of bone became lodged in the anterior mediastinum after the patient's major traumatic incident.

The differential diagnosis for anterior mediastinal masses as in this case include germ cell tumors, thyroid goiters or neoplasms, hemangiomas, and thymic lesions including cysts, thymoma, and thymic seminoma.¹⁹ Microscopically there were no ectodermal or endodermal elements present, nor were there any areas consistent with germ cell tumor morphology. The lesion did not have the vascular network expected in a hemangioma. Thymic or thyroidal tissue was not observed, but given the patients advanced age and expected thymic involution, a pre-existing thymic lesion could not be ruled out.

The imaging findings of these masses are not specific to cholesterol granuloma and may simulate different entities, both baleful and benign. Such mimics include dermoid cyst,⁶ pancreatic cystic neoplasm,¹² craniopharyngioma,² renal cell carcinoma,⁸ breast cancer,^{9,20} and invasive thymic neoplasm.¹⁴ The unfortunate consequence of this is that unnecessary, potentially harmful interventions could be performed for this ultimately benign entity.¹⁴ In the cases of cholesterol granulomas that are causing clinical symptoms, surgical excision is the treatment of choice.

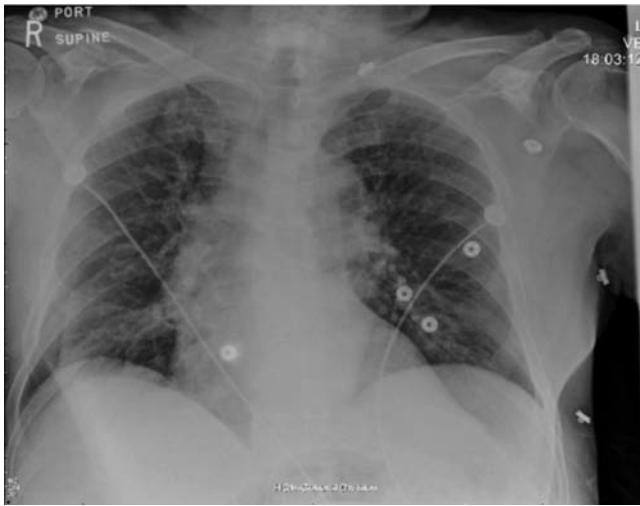

Figure 1. Posteroanterior chest radiograph.

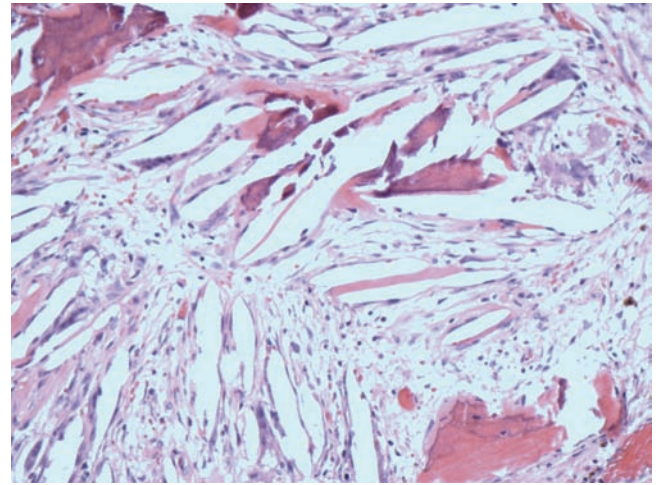


Figure 3. Cholesterol granuloma with osseous metaplasia, 100x magnification.

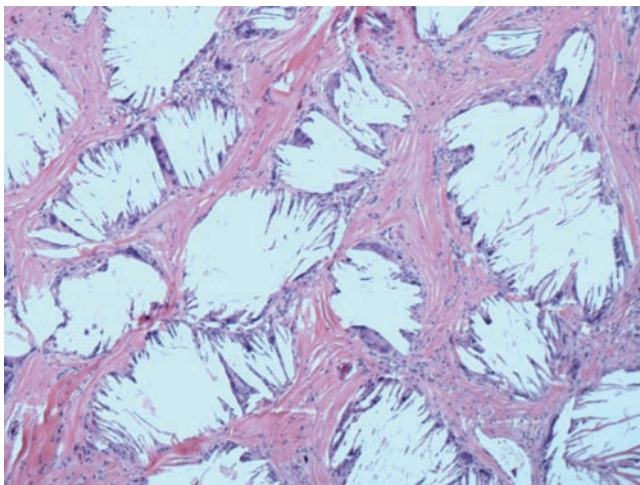


Figure 2. Cholesterol granuloma, 40x magnification.

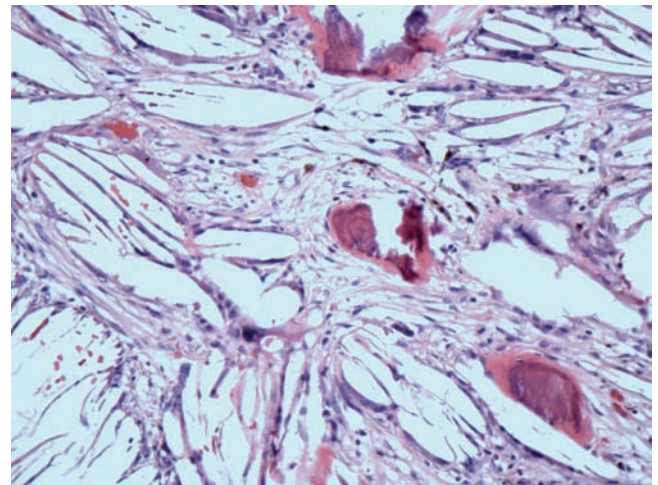


Figure 4. Cholesterol granuloma with osseous metaplasia, 100x magnification.

Conclusions

To our knowledge, this is the third reported case of an isolated anterior mediastinal cholesterol granuloma, and the first exhibiting osseous metaplasia. The tumor in our patient may have been precipitated by hyperlipidemia, a thymic lesion - though no thymic or cystic tissue was present on microscopic analysis - or from the motor vehicle trauma he had sustained years ago.

References

1. Eisenberg MB, Haddad G, Al-Mefty O. Petrous apex cholesterol granulomas: evolution and management. *J Neurosurg* 1997;86:822-9.
2. Grossi PM, Ellis MJ, Cummings TJ, et al. Cholesterol granuloma of the lateral ventricle. Case report. *J Neurosurg* 2008;108:357-60.
3. Khalatbari MR, Moharamzad Y. Recurrent orbitofrontal cholesterol granuloma in pediatric patient: case report and review of the literature. *Child Nerv Syst* 2012;28:291-6.
4. Loeffler KU, Kommerell G. Cholesterol granuloma of the orbit-pathogenesis and surgical management. *Int Ophthalmol* 1997;21:93-8.
5. Ong LY, McNab AA. Recurrent orbital cholesterol granuloma. *Orbit* 2008;27:119-21.
6. Selva D, Phipps SE, O'Connell JX, et al. Pathogenesis of orbital cholesterol granu-

- loma. *Clin Experiment Ophthalmol* 2003; 31:78-82.
7. Thevendran G, Al-Akraa M, Powis S, Davies N. Cholesterol granuloma of the kidney mimicking a tumour. *Nephrol Dial Transplant* 2003;18:2449-50.
 8. Cheng KL, Chang H, Tsai CM, et al. Sonographic appearance of a cholesterol granuloma within a renal epithelioid angiomyolipoma. *J Clin Ultrasound* 2011; 39:95-8.
 9. Garofalo SG, Casolino C, Accurso A, Falletti J. Cholesterol Granuloma of the breast with unusual ossification features (osseous metaplasia). *Pathol Res Pract* 2008;204:353-6.
 10. Luckraz H, Coulston J, Azzu A. Cholesterol granuloma of the superior mediastinum. *Ann Thorac Surg* 2006;81:1509-10.
 11. Suster S, Rosai J. Multilocular thymic cyst: an acquired reactive process. Study of 18 cases. *Am J Surg Pathol* 1991;15:388-98.
 12. Imai H, Osada S, Sasaki Y, et al. Cholesterol granuloma in the pancreas accompanied by peritoneal disseminated lesions. *Pancreas* 2011;40:795-6.
 13. Kimura N, Komuro K, Uchino S, et al. Multiple endocrine neoplasia type 1-associated cystic pancreatic endocrine neoplasia and multifocal cholesterol granulomas. *Pathol Int* 2010;60:321-5.
 14. Fujimoto K, Takamori S, Yano H, et al. Focal cholesterol granuloma in the anterior mediastinum: [18F]-fluoro-2-deoxy-D-glucose-positron emission tomography and magnetic resonance imaging findings. *J Thorac Oncol* 2007;2:1054-6.
 15. Perino A, Petronio M. Granulomatous cholesterol salpingitis with ceriod accumulation and osseous metaplasia. *Acta Eur Fert* 1974;5:259-74.
 16. Jacono AA, Sclafani AP, Van De Water T, et al. Metaplastic bone formation in nasal polyps with histologic presence of transforming growth factor beta-1 (TGFbeta-1) and bone morphogenetic proteins (BMPs). *Otolaryngol Head Neck Surg* 2001;125:96-7.
 17. Teot LA, O'Keefe RJ, Rosier RN, et al. Extrasosseous primary and recurrent giant cell tumors: transforming growth factor-beta1 and -beta2 expression may explain metaplastic bone formation. *Hum Pathol* 1996;27:625-32.
 18. Toyran S, Lin AY, Edward DP. Expression of growth differentiation factor-5 and bone morphogenic protein-7 in intraocular osseous metaplasia. *Br J Ophthalmol* 2005; 89:885-90.
 19. Kurosaki Y, Tanaka YO, Itai Y. Thymic seminoma with prominent cystic changes. *Am J Roentgenol* 1996;167:1345-6.
 20. Ishizaki M, Ohsumi S, Takashima S, Mandai K. Two cases of cholesterol granuloma of the breast. *Breast Cancer*. 2001; 8:158-61.