

A Spontaneous Lower Motor Neuron Disease Apparently Caused by Indigenous Type-C RNA Virus in Wild Mice^{1,2}

Murray B. Gardner,³ Brian E. Henderson,³ J. Earle Officer,³ Robert W. Rongey,³ John C. Parker,⁴ Cynthia Oliver,⁴ John D. Estes,⁵ and Robert J. Huebner^{5,6}

SUMMARY—A high incidence of spontaneous lower-limb paralysis occurred in a population of wild mice (*Mus musculus*) which had a high incidence of naturally occurring lymphoma and elevated indigenous type-C virus activity. Experimental transmission evidence indicated that both the neurologic and lymphomatous disorders almost certainly were caused by the indigenous type-C virus. The virus appeared to have a direct neurotropic effect on anterior horn neurons in the lower spinal cord.—*J Natl Cancer Inst* 51: 1243-1254, 1973.

WE RECENTLY DESCRIBED (1) a population of wild mice that had a high prevalence of indigenous type-C virus associated with a high incidence of naturally occurring lymphomas during laboratory observation of up to 12 months. We concurrently observed a progressive lower-limb paresis in many mice from this same population, both with and without lymphoma. We now describe the principal epidemiologic, clinicopathologic, and virologic findings that characterize this neurologic disease. The data presented here and in (2) strongly support an etiologic role for the indigenous type-C virus in both the neurologic and lymphomatous disorders of these mice.

MATERIALS AND METHODS

Collection and processing of mice.—To study the natural history of type-C and type-B RNA tumor viruses indigenous to wild mice, we have trapped wild mice in different geographic areas in and around Los Angeles County for several years (3-5). The mice discussed here were trapped at a squab farm in an isolated rural canyon (LC) about 5 miles from the Pacific Ocean in Ventura County, California. The captured mice were weighed, bled by retro-orbital puncture, and individually housed in facilities separate from the other groups of wild mice under study. Sera were tested for antibodies in either the hemagglutination-inhibition or the complement-fixation (CF) test against 16 murine virus antigens.⁷ Additional serum specimens were collected when sick mice were killed.

A complete necropsy with microscopic study, including study of the central nervous system, was done on each mouse found ill or moribund. Selected tissues were minced and diluted tenfold with Hanks' balanced salt solution (HBSS), then stored at -70° C until they were inoculated by various routes into newborn NIH Swiss and wild mice. Several naturally paralyzed LC wild mice were also sent to another laboratory (Microbiological Associates, Inc.) where independent transmission studies were done. Sonicated aqueous extracts (20%) of various fresh tissues (spleen, liver, spinal cord, muscle, and brain) from the necropsied

mice were tested for murine group-specific (gs) antigen by CF; the antiserum was a 1:20 dilution of serum pools from Fischer rats bearing Moloney sarcoma virus (MSV)-induced tumor transplants. Sections of particular tissues, including parts of the central nervous system, were also prepared for light and electron microscopy (EM) (6).

RESULTS

Epidemiologic Observations

The large-scale trapping of mice from this squab farm began during October 1971. By February of the next year, 2071 LC mice were under laboratory surveillance and a few had hind leg paralysis. At the end of 14 months of observation, 1141 (55.1%) of the original 2071 mice in the colony had died or had been killed because of illnesses such as paralysis or lymphoma (1). During this 14-month period, 183 (16.1%) of the killed or dead mice had exhibited paralysis; 184 (16.1%) of them showed lymphoma. Twenty-six (1.3%) had both paralysis and lymphoma.

The association between paralysis and lymphoma was so striking that the relative risk of lymphoma in a paralyzed wild mouse was approximately twelvefold greater than in a nonparalyzed mouse from the same colony. Despite this close association, the epidemiologic picture of the paralytic disease was somewhat different from that of the lymphomas. The rate of paralysis was similar in both sexes, whereas lymphomas occurred twice as frequently in female as in male mice. The rate of paralysis was fairly constant at about 1% per month of the surviving colony until about 12 months; since then about 2% of the colony has become paralyzed each month (text-fig. 1). By contrast, the rate of lymphomas was low during the first 6 months of observation and then increased. Mice heavier (>20.0 g) when trapped developed

¹ Received April 3, 1973; accepted June 4, 1973.

² Study conducted under Public Health Service contract PH 43-NCI-68-1030 within the Special Virus-Cancer Program of the National Cancer Institute.

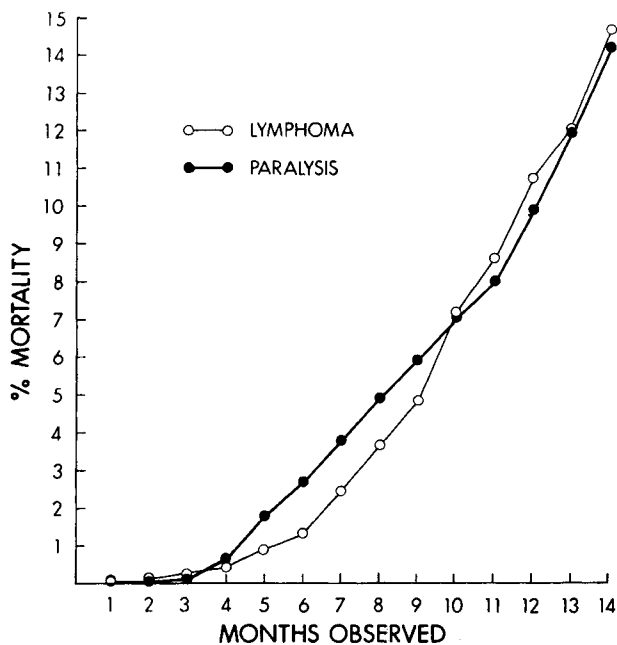
³ Department of Pathology, University of Southern California School of Medicine, Los Angeles, Calif. 90033.

⁴ Microbiological Associates, Inc., Bethesda, Md. 20014.

⁵ Viral Carcinogenesis Branch, National Cancer Institute, National Institutes of Health, Public Health Service, U.S. Department of Health, Education, and Welfare, Bethesda, Md. 20014.

⁶ We thank John Farnum and Rene Germaine for technical assistance, Herman Menck and Michael Hejjas for computerization of data, Paul Hill for supervision of the complement-fixation tests, and Ann Dawson and Sherril Nixon for preparation of the manuscript.

⁷ Lymphocytic choriomeningitis, mouse encephalomyelitis virus, polyoma, mouse hepatitis virus, reovirus-3, K virus, Kilham rat virus, H-1, SV5, Sendai virus, mouse adenovirus, minute virus of mice (MVM), pneumonia virus of mice, ectromelia, mouse salivary gland virus, and rat coronavirus.



TEXT-FIGURE 1.—Cumulative monthly percentage of paralysis and lymphoma in LC wild mice held in the laboratory for 14 months.

paralysis and lymphoma faster than did mice weighing less (<12.0 g) and thus presumably younger.

Clinical and Laboratory Findings

The most outstanding feature of this disease was a progressive hind-leg paralysis. The earliest sign was a slight-to-moderate tremor of 1 or both hind limbs. The tremor spread to the trunk and head, but rarely involved the upper limbs. The involved hind limbs subsequently became weak and, eventually, paralyzed; associated with this were atrophy of the lower limbs and pelvic girdle (fig. 1), weight loss, dehydration, ruffling of the hair and, terminally, bowel and bladder incontinence. The illness lasted 10 days to 2 months before causing death.

Electromyographs (by Dr. Walter Goodman and Dr. Joseph Van Der Meulen) showed fibrillation potentials along with high voltage long-duration complexes (fasciculation) and sparsity of motor unit potentials typical of lower motor neuron disease or neuropathy affecting the hind limb and paraspinal musculature.

The principal histopathologic findings in the naturally paralyzed wild mice were seen in the anterior horn areas of the lower spinal cord. Non-specific vacuolar neuronal degeneration (fig. 2) was accompanied by an unequivocal proliferation of astroglial cells (fig. 3). Inflammatory infiltrates and primary demyelination were absent. The brain, brain stem, upper spinal cord, and sciatic nerves were generally normal in gross and microscopic appearance. The skeletal musculature from the paralyzed hind limbs showed neurogenic atrophy (fig. 4). Apart from lymphoma, histopathologic findings in the visceral tissues of both paralyzed and nonparalyzed LC wild mice were no different than the incidental

histopathologic features in wild mice from the other trapping areas (5).

EM examination of naturally paralyzed wild mice revealed type-C virus particles in 8 of 11 lower spinal cord biopsy specimens and 3 of 3 from skeletal musculature of the paralyzed hind leg. Type-C virus particles were not seen in 12 specimens of brain or 3 of sciatic nerve from naturally paralyzed mice. In the lower spinal cord, numerous type-C virus particles were noted in the extracellular spaces and, less frequently, budding singly from the plasma membrane of neurons (fig. 5) and oligodendroglial cells. More commonly, neurons in the anterior horns of the lower spinal cord contained within their cytoplasm virus-like particles believed to be type-C virus (see below). These particles budded into intracellular vacuoles and cisterns of the rough endoplasmic reticulum (RER) (figs. 6–8). The vacuoles were lined with smooth membranes from which many virions were budding. Inside the vacuoles, some particles had bizarre shapes; membranous debris was also present. Within neurons, virus particles also budded in cylindrical configuration from the membranes of the RER. Both budding and free particles were in the cisterns of the RER, which were thereby moderately dilated. In cross section, the free intracisternal particles measured 80–90 nm in diameter and showed a trilamellar structure with smooth outer membrane and an electron-lucent core. Incompletely formed particles, possibly nucleocapsid precursor material, were also seen occasionally within the RER. Smooth-walled vacuoles without virus particles were noted within neurons with or without virus particles elsewhere in their cytoplasm. This vacuolar change was more severe in those neurons which did not show virus particles. Occasionally, an increase in the extracellular space was apparent. Other neurons were free of both virus particles and vacuoles and appeared normal in fine structure. Only neurons apparently contained the extensively intracellular replicating particles. A few intracisternal type-A particles were sometimes seen in neurons in the brain and spinal cord which did not contain the particles just described. Intracellular replicating virus particles were usually not in the skeletal musculature, although many type-C virus particles were in the interstitium close to the sarcolemma.

Mouse antibody production (MAP) tests⁸ (7) on samples of brain and spinal cord extracts from 17 naturally paralyzed LC wild mice were negative. Brain suspensions prepared from the same mice were trypsin treated and tested for hemagglutination of human O red blood cells with negative results. Numerous tissue extracts of brain, spinal cord, and viscera from naturally paralyzed wild mice were inoculated into thioglycolate broth and onto blood agar plates. There was no evidence of bacterial growth. Attempts to isolate mycoplasma in mycoplasma broth inoculated with dilutions of minced lung, liver, and spleen, as well as middle ear and nasal washings, were negative.

⁸The MAP test detects induced antibodies against the same 16 murine virus antigens as listed in footnote 6.

Brain, spinal cord, and visceral tissue suspensions from the same 17 naturally paralyzed wild mice were passaged 4–6 times in NIH Swiss mouse kidney tissue cultures, Swiss mouse embryo cultures, and C3H mouse liver clone NCPC-1469. Cytopathic effects were apparent only in 1 cell culture. Mouse cytomegalovirus (CMV) was isolated in mouse embryo tissue culture from 1 visceral organ specimen.

Serum from every recently trapped LC wild mouse was negative for antibodies to the standard battery of 16 murine viral antigens. Sera from 26 naturally paralyzed wild mice, collected at necropsy, were also negative against these antigens except for 4, which were positive for antibody to MVM.

Type-C Virus Activity and Experimental Transmission

Twenty percent extracts of spleen, brain, and spinal cord tissue from age- and sex-matched, naturally paralyzed and nonparalyzed LC mice with and without concurrent lymphomas were assayed for type-C virus gs antigen by CF and type-C particles by EM. The gs antigen was detected in 99% of the spleen extracts regardless of whether the mice died of lymphoma, paralysis, or other causes (table 1). The geometric mean titer of gs antigen in spleens from lymphomatous mice (32.0) was higher than the antigen titer in spleens from nontumorous mice, paralyzed (12.7) or nonparalyzed (10.3). LC mice with lymphomas show a higher incidence of type-C virus gs antigen detectable by CF than do wild mice with spontaneous lymphoma from other trapping areas (1, 5). Tissue extracts of brain and spinal cord from these lymphomatous but nonparalyzed LC wild mice have gs antigen detectable by CF in 30–47% tested (table 1).

Brain and spinal cord tissue extracts from nontumorous and nonparalyzed LC mice were, with 1 exception, without detectable CF gs antigen (table 1). A few LC mice without tumors but with early paralysis, i.e., clinical disease of <3 weeks duration, were also lacking gs antigen in extracts of brain and spinal cord, whereas 58% of the nontumorous LC mice with advanced paralytic disease (3–12 wk duration) had detectable gs antigen in the spinal cord. A smaller number of these mice (17%) also showed gs antigen in the brain extracts. Detection of type-C virus by EM in spinal cord biopsy specimens of LC mice

with advanced paralysis correlated well with gs antigen results.

Twenty percent tissue extracts of brain, spinal cord, and liver-spleen from 3 naturally paralyzed LC mice were separately pooled and passaged by the intracerebral (ic) route into several litters of newborn NIH Swiss and newborn wild mice (table 2). Of 33 NIH Swiss mice inoculated, 13 (39%) developed a progressive hind-leg paralysis and 9 (27%) developed lymphoma after 4–8 months of observation. Five had both paralysis and lymphoma. Except for edema, slight perivascular lymphoid cuffing, and gliosis occasionally noted in the brain stem and upper spinal cord, the clinical features and the intensity and distribution of the neuropathologic lesions of this induced disease in NIH Swiss mice were like those in the naturally paralyzed LC wild mice. The lymphomas were of a diffuse, poorly differentiated lymphocytic type similar in organ distribution and histologic pattern to the naturally occurring lymphomas of the LC mice (1). Only 1 of the 46 inoculated wild mice developed paralytic disease after 6 months; another developed lymphoma after 9 months.

A second passage was made from filtered (440 nm) and unfiltered extracts of various tissues taken from 1 of the NIH Swiss mice (XM-292) which had developed hind-leg paralysis and lymphoma 4 months after inoculation with pooled spinal cord extracts from the naturally paralyzed LC wild mice. These extracts were inoculated ic into newborn NIH Swiss and wild mice (table 3). Portions of the same extracts were positive for type-C virus *in vitro* by the XC plaque (8) assay and the CF test for murine leukemia virus gs antigen (COMUL) (9) on NIH Swiss embryo cells. Hind-leg paralysis was induced within 2–7 months in 90 of 125 (72%) inoculated NIH Swiss mice. Extracts, filtered or unfiltered, from every tissue tested could induce the paralysis. The shortest latent period (1–2 months) and highest incidence of paralysis (97%) followed inoculation of the liver-spleen extracts. Lymphoma occurred after 4–6 months in 5 (4%) of the 125 NIH Swiss mice, 2 of which also were paralyzed. These lymphomatous mice had been inoculated with extracts of spinal cord, muscle, or lymph node. Paralysis occurred after 3 months in 2 of 5 wild mice that had been inoculated with filtered liver-spleen extracts.

TABLE 1.—Type-C virus gs antigen expression in tissues of naturally paralyzed and nonparalyzed LC mice

	Nonparalyzed		Paralyzed		
	Nontumorous	Lymphomas	Nontumorous		Lymphoma
			Early disease	Late disease	
GS antigen (CF):					
Spleen.....	31/31 (100%)	30/30 (100%)	9/10 (90%)	24/24 (100%)	3/3 (100%)
Brain.....	1/31 (3%)	14/30 (47%)	1/10 (10%)	4/24 (17%)	2/3 (67%)
Spinal cord.....	1/30 (3%)	9/30 (30%)	0/10 (0%)	14/24 (58%)	3/3 (100%)

TABLE 2.—Primary transmission *in vivo* of lower limb paralysis from naturally paralyzed wild mice to newborn wild and NIH Swiss mice by *ic* inoculation

Inoculum*	Host	Number inoculated†	Number of lymphomas	LP‡	Number with paralysis	LP	Number with paralysis + lymphoma§
Brain.....	NIH Swiss.....	9	4	5-7	3	5	2
	Wild mice 	4	0		0		0
Spinal cord.....	NIH Swiss.....	12¶	3	4-6	7	4-8	2
	Wild mice.....	22	1	9	1	6	0
Liver and spleen.....	NIH Swiss.....	12	2	7-8	3	7-8	1
	Wild mice.....	20	0		0		0
Total.....	NIH Swiss.....	33	9		13		5
Total.....	Wild mice.....	46	1		1		0

*The inocula were 0.03 ml of an unfiltered 10% extract in HBSS of brain, spinal cord, or liver and spleen from a pool of 3 naturally paralyzed LC wild mice. Each mouse was inoculated 1X *ic* within 24 hours of birth.

†Includes mice surviving minimum of 4 months.

‡LP=latent period in months.

§Included in the preceding columns.

||From laboratory colonies of 3 trapping areas other than LC. Wild mice in these 3 laboratory colonies have shown no spontaneous lymphomas until at least 22 months under observation and no spontaneous paralysis for 3 years of observation (5).

¶One mouse in this group had a mast cell tumor of the spleen without lymphoma.

In a separate laboratory (Microbiological Associates, Inc.), 48 Swiss Webster mice were inoculated *ic* as newborns with brain extracts from naturally paralyzed LC wild mice (table 4). Seven days after inoculation, the brains of 4 or 5 mice from each inoculated group were harvested and pooled, and extracts were blind-passaged into another litter of newborn mice (P_2); the remainder of the litter was held and observed for disease (P_1). After 4-7 months, 6 mice in P_1 and 5 mice in P_2 became paralyzed; in addition, 1 mouse in P_1 had lymphoma after 6 months. The only virus detected by MAP, tissue culture, and serologic methods (data not shown) in the inocula or tissues of the mice with induced paralytic disease was type C.

DISCUSSION

The progressive lower motor neuron type of paralysis we observed in a natural situation in this group of wild mice has not been previously described. However, in 1962-65, Stansly (10) probably saw the same type of hind-leg paralysis while passaging reticulum cell sarcomas in BALB/c mice. His studies also suggested that the paralytogenic and lymphomagenic agents were the same. We have apparently rediscovered this phenomenon as a spontaneous occurrence in a natural population of wild mice. In addition, we reported (2) the experimental induction of the identical paralytic disease together with an occasional lymphoma in newborn wild and NIH Swiss mice by inoculation of purified type-C virus derived from cultured cells of a wild mouse embryo from another trapping area. These combined studies establish with virtual certainty that the type-C RNA virus is the etiologic agent of both the paralysis and lymphoma.

A combination of morphologic, serologic, and virologic tests has failed to indicate infection with other murine viruses capable of producing disease of the central nervous system in mice (7, 11). In addition to type-C virus, detected in all naturally and experi-

mentally paralyzed mice examined, the only other murine viruses that could be detected were mouse CMV, isolated from the visceral tissues of 1 naturally paralyzed LC mouse, and MVM antibody, present in a low percentage of paralyzed LC mice. However, both CMV and MVM have commonly been found in feral mice (7, 12) and are not known to produce neurologic disease.

Certain neuromuscular disorders of inbred mice generally show distinctly different clinical and pathologic findings from those observed in the LC wild mice (13-16). The "wobbler" disease described by Duchon et al. (16) is closest in clinical presentation to our observations. However, the wobbler mouse is characterized by weakness and ataxia of the forelimbs and neuronal degeneration mainly in the brain stem and cervical cord. In addition, wobbler disease occurs in young mice and lasts up to and beyond 12 months. No evidence of any virus has been detected by EM or experimental transmission (17).

The clinical and pathologic features of this paralytic disease, although not pathognomonic, are similar to those described for the progressive motor unit atrophy type of amyotrophic lateral sclerosis (ALS) in humans (18) and the subacute spongiform encephalopathies (19). The restriction of pathologic changes predominantly to the lower spinal cord distinguishes this paralytic disease from the spongiform encephalopathies. Another important difference, of course, is the absence of reported type-C particles in EM studies of the spongiform encephalopathies and human ALS material. In the natural and experimentally transmitted paralysis in mice, many typical type-C virus particles are seen by EM in the extracellular spaces of the spinal cord and, less frequently, budding from the plasma membrane of neurons and oligodendroglia. This correlates well with the detection of gs antigen by CF and recovery of infectious type-C virus *in vitro* from the spinal cord extracts of paralyzed mice (tables 1, 3, 4).

TABLE 3.—*Second passage in vivo of lower limb paralysis from an experimentally paralyzed and lymphomatous NIH Swiss mouse (XM-292) to newborn wild and NIH Swiss mice by ic inoculation*

Inoculum*	In vitro virus recovery from inoculum		Host	Number inoculated†	Number with lymphomas	LP‡	Number with paralysis	LP	Number with paralysis and lymphoma.§
	XC	COMUL							
Brain									
Unfiltered	+	+	NIH Swiss-----	12	0		9	2-6	0
Filtered ¶	+	+	NIH Swiss-----	10	0		2	5-6	0
Spinal cord			Wild mice**-----	9	0		0		0
Unfiltered	+	+	NIH Swiss-----	9	0		5	4-7	0
Filtered	ND††	+	NIH Swiss-----	7	1	6	1	7	0
Liver and spleen									
Unfiltered	+	+	NIH Swiss-----	17	0		17	1-2	0
Filtered	ND	+	Wild mice-----	15	0		0		0
			NIH Swiss-----	15	0		14	2-6	0
			Wild mice-----	5	0		2	3	0
Muscle									
Unfiltered	+	+	NIH Swiss-----	15	0		14	2-6	0
Filtered	ND	-	NIH Swiss-----	15	1	4	10	3-7	0
Lymph node									
Unfiltered	+	+	NIH Swiss-----	9	3	5	8	2-7	2
			Wild mice-----	9	0		0		0
	+	+	NIH Swiss-----	16	0		10	3-5	0
Filtered			NIH Swiss-----	125	5		90		2
Total			Wild mice-----	38	0		2		0

*The inocula were 0.03 ml of a 10% extract in HBSS of brain, spinal cord, liver and spleen, skeletal muscle, and lymphomatous lymph node from 1 experimentally paralyzed and lymphomatous NIH Swiss mouse (XM-292). Each experimental mouse was inoculated 1 X ic within 24 hours of birth.
 †Includes mice surviving minimum of 1 month.
 ‡LP = latent period in months.
 §Included in the preceding columns.
 || Assayed for MuLV gs antigen induction by CF on NIH Swiss embryo cell cultures. Results given as (+) if CF gs antigen detectable in cell pack 13 days after inoculation, (+) if CF gs antigen not detected until 21 days or more after inoculation, and (-) if cell pack still negative by CF 28 days after inoculation.
 ¶Filtered through 440 nm.
 **From same wild mouse colonies described in table 2, || footnote.
 ††Not done.

TABLE 4.—Transmission *in vivo* of lower-limb paralysis from naturally paralyzed wild mice to newborn Swiss-Webster mice by *ic* inoculation

Inoculum *	Host	Number paralyzed				Type-C virus assay in brains and spinal cords of experimentally paralyzed Swiss Webster mice		
		No. inoculated				EM ‡	XC §	CF gs antigen §
		Passage 1	LP †	Passage 2	LP			
Brain-----	Swiss Webster---	1/4	7	0/5	7	+	5.5	ND
Brain-----	Swiss Webster---	1/4	7	4/7	4-7	+	5.2	+
Brain-----	Swiss Webster---	2/5 ¶	7	1/9	6-7	+	5.1	+
Brain-----	Swiss Webster---	2/5	5-7	0/9	7	+	4.8	+

* The inocula were 0.03 ml of a 10% extract in HBSS of brain from 4 naturally paralyzed LC wild mice. Each was inoculated 1× *ic* within 24 hours of birth. MAP tests on each inoculum were negative (studies done at Microbiological Associates).

† LP = Latent period in months.

‡ Performed by Doctor Vernon, Microbiological Associates.

§ Performed on 1-4 paralytic mice from each inoculated group.

|| Not done.

¶ One of these mice developed lymphoma without paralysis after 6 months.

Somewhat unusual, however, are the many particles seen within the cytoplasm of anterior horn neurons of the lower spinal cord. Type-C particles typically replicate by budding from the plasma membrane of infected cells into the extracellular space without showing a cylindrical configuration. However, intracellular type-C virus identical to the intraneuronal particles with cylindrical budding into cisterns of the endoplasmic reticulum has been described in several different murine cell types [megakaryocytes (20, 21), alveolar (22) and epididymal epithelial cells (23), and myelomonocytic cells (24)] infected *in vivo* with laboratory strains of mouse leukemia virus. Moreover, intracytoplasmic vacuoles, like those seen in the mouse neurons, which contain membranous debris and shed from their lining numerous type-C particles, some with aberrant shape and size, have been described in murine (25, 26) and human (27) cells infected with mouse leukemia and sarcoma viruses. Therefore, we believe that the particles seen by EM within the cytoplasm of anterior horn neurons also represent type-C virus. The possibility that these intracellular particles are not virions or are some other unidentified species of virus seems remote but cannot be absolutely excluded. More detailed neuropathologic fine-structural studies on these mice will be reported elsewhere (28, 29).

The pathogenesis of the paralytogenic disease needs further clarification. The type-C virus appeared to have a distinct neurotropic action, with multiplication within and damage to anterior horn neurons. In the original colony of LC wild mice, many embryos were infected with type-C virus. In addition, further exposure to type-C virus occurs via milk (6) during nursing. Thus we assume that early in life almost all these mice were infected and made relatively tolerant to their type-C virus. The incubation period before development of the neuropathologic disease probably relates to degree of virus exposure in the central nervous system, to genetic factors, and, perhaps, to immunologic response. However, the lack of leukocytic infiltrates suggests the absence of a

significant immune response. Genetically mutant strains or unique envelope properties of "wild" type-C virus may account for distinct subpopulations of virus with specific neurotropic or oncogenic activity. Additional factors such as sex and age must be operating to account for the occurrence of lymphoma, which showed a somewhat different epidemiologic pattern. New cases of paralysis occurred at a similar incidence rate in both sexes during the 14 months of observation, but lymphomas predominated in female mice and increased in incidence over time. An understanding of the pathogenic mechanisms responsible for the lower motor neuron disease of these mice may have important implications in understanding human neurologic diseases such as ALS.

REFERENCES

- (1) GARDNER MB, HENDERSON BE, ESTES JD, et al: An unusually high incidence of spontaneous lymphoma in a population of wild house mice. *J Natl Cancer Inst* 50:1571-1579, 1973
- (2) OFFICER JE, TEGSON N, FONTANILLA E, et al: Isolation of a neurotropic type C virus. *Science*. In press
- (3) GARDNER MB, OFFICER JE, RONGEY RW, et al: C-type RNA tumour virus genome expression in wild house mice. *Nature [New Biol]* 232:617-620, 1971
- (4) GARDNER MB, OFFICER JE, RONGEY RW, et al: C-type RNA tumor virus in wild house mice (*Mus musculus*). *Bibl Haematol*. In press
- (5) GARDNER MB, HENDERSON BE, RONGEY RW, et al: Spontaneous tumors of aging wild house mice. *J Natl Cancer Inst* 50:719-734, 1973
- (6) RONGEY RW, HLAVACKOVA A, LARA S, et al: Types B and C RNA virus in breast tissue and milk of wild mice. *J Natl Cancer Inst* 50:1581-1589, 1973
- (7) ROWE WP, HARTLEY JW, HUEBNER RJ: Polyoma and other indigenous viruses. In *The Problems of Laboratory Animal Disease* (Harris RJ, ed.). New York, Academic Press Inc. 1962, pp 131-142
- (8) ROWE WP, PUGH WE, HARTLEY JW: Plaque assay techniques for murine leukemia viruses. *Virology* 42:1136-1139, 1970
- (9) HARTLEY JW, ROWE WP, CAPPS WI, et al: Isolation of naturally occurring viruses of the murine leukemia virus group in tissue culture. *J Virol* 3:126-132, 1969
- (10) STANSLY PG: Non-oncogenic infectious agents associated with experimental tumors. *Prog Exp Tumor Res* 7:224-258, 1965

- (11) TUFFERY AA, INNES JR: Diseases of laboratory mice and rats. In *Animals for Research* (Lane-Petter W, ed.). London, Academic Press Inc., 1963, chapt 3, pp 47-108
- (12) PARKER JC, COLLINS MJ JR, CROSS SS, et al: Minute virus of mice. II. Prevalence, epidemiology, and occurrence as contaminant of transplanted tumors. *J Natl Cancer Inst* 45:305-310, 1970
- (13) D'AMATA CJ, HICKS SP: Neuropathologic alterations in the ataxia (paralytic) mouse. *Arch Pathol* 80:604-612, 1965
- (14) SIDMAN RL, DICKIE MM, APPEL SH: Mutant mice (quaking and jumping) with deficient myelination in the central nervous system. *Science* 144:309-311, 1964
- (15) MICHELSON AM, RUSSELL ES, HARMAN PJ: Dystrophia muscularis: A hereditary primary myopathy in the house mouse. *Proc Natl Acad Sci USA* 41:1079-1084, 1955
- (16) DUCHEN LW, FALCONER DS, STRICH SJ: Hereditary progressive neurogenic muscular dystrophy in the mouse. *J Physiol (Lond)* 183:53-55, 1966
- (17) ANDREWS J: Personal communication
- (18) HIRANO A, MALAMUD N, KURLAND LT, et al: A review of the pathological findings in amyotrophic lateral sclerosis. In *Motor Neuron Diseases: Research on Amyotrophic Lateral Sclerosis and Related Disorders* (Norris FH, Kurland LT, eds.), vol 2. New York, Grune & Stratton, 1969, pp 51-59
- (19) LAMPERT PW, GAJDUSEK DC, GIBBS CJ: Subacute spongiform virus encephalopathies. Scrapie, Kuru and Creutzfeldt-Jakob disease: A review. *Am J Pathol* 68:626-656, 1972
- (20) DALTON AJ, LAW LJ, MOLONEY JB, et al: An electron microscopic study of a series of murine lymphoid neoplasms. *J Natl Cancer Inst* 27:747-791, 1961
- (21) DMOGHOWSKI L, GROSS L, PADGETT F: Electron microscopic studies of rat leukemia induced with mouse leukemia virus. *Proc Soc Exp Biol Med* 110:504-508, 1962
- (22) BUCCIARELLI E, RIBACCHI R: C-type particles in primary and transplanted lung tumors induced in BALB/c mice by hydrazine sulfate: Electron microscopic and immunodiffusion studies. *J Natl Cancer Inst* 49:673-684, 1972
- (23) FELDMAN DG, GROSS L: Electron microscopic study of the distribution of the mouse leukemia virus (Gross) in genital organs of virus-infected C3H mice and AKR mice. *Cancer Res* 27:1513-1527, 1967
- (24) SANEL FT: Studies of neoplastic myelomonocytic cells in BALB/c mice producing infectious type C virus. *Cancer Res* 33:671-678, 1973
- (25) DELLATORRE G, DELLE PORTE G: Type C virus in the pancreas of normal C57BL mice. *Cancer Res* 32:1595-1597, 1972
- (26) HACKETT AJ, SYLVESTER SS: Cell line derived from BALB/3T3 that is transformed by murine leukemia virus. A focus assay for leukemia virus. *Nature [New Biol]* 239:164-166, 1972
- (27) McALLISTER RM, NICOLSON M, GARDNER MB, et al: RD-114 virus compared with feline and murine type C viruses released from RD cells. *Nature (Lond)* 242:75-78, 1973
- (28) DAVIS R, GARDNER MB: Myelopathy associated with C-type virus in mice. Presented at Am Assoc Neuro-path, Freeport, Grand Bahamas, June 1973
- (29) ANDREWS JM, GARDNER MB: Studies on the wobbler (wt) mouse: Current status and comparison with a virus induced motor neuron disease in wild mice. Presented at Am Assoc Neuro-path, Freeport, Grand Bahamas, June 1973

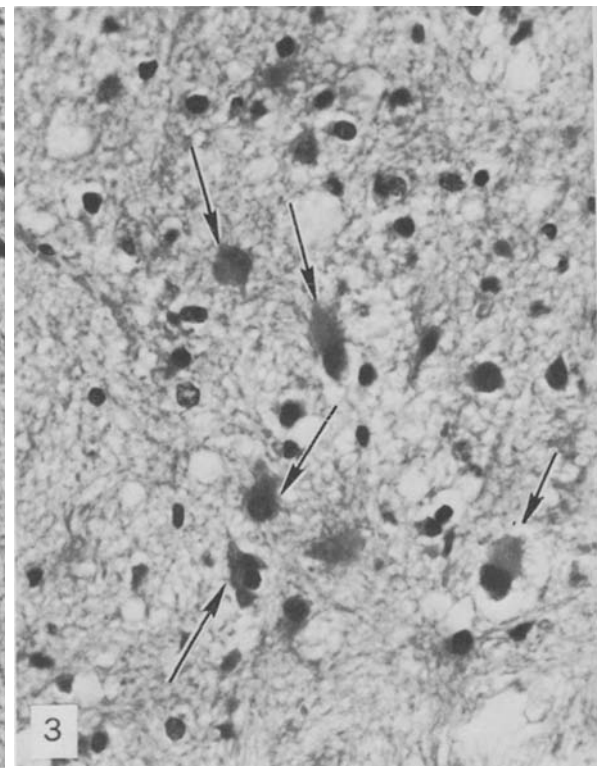
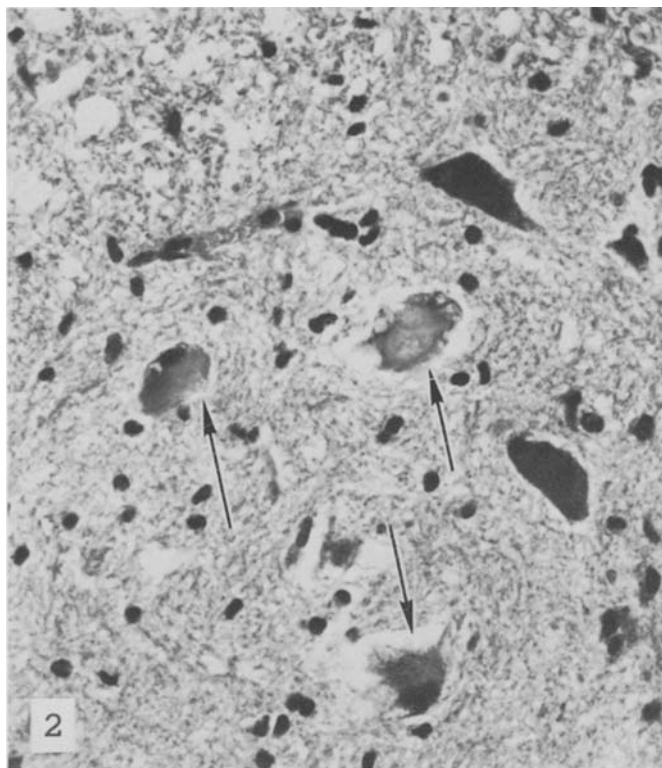
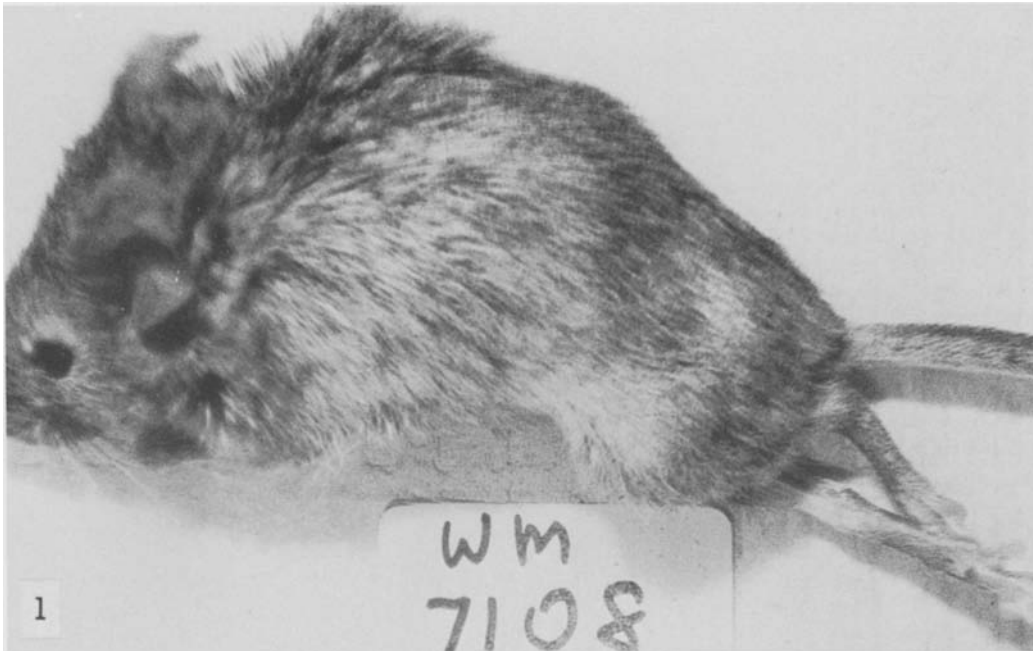


FIGURE 1.—Spontaneously paralyzed LC wild mouse with advanced atrophy of the lower-limb girdle and extremities.

FIGURE 2.—Degeneration of anterior horn neurons from lower spinal cord. Central condensation of eosinophilic staining cytoplasm is surrounded by tiny vacuoles (*arrows*). No inflammatory cells. Clear space around neurons is a shrinkage artifact. Hematoxylin and eosin (H & E). $\times 500$

FIGURE 3.—Gliosis in the anterior horn area of lower spinal cord. *Arrows* indicate proliferating astroglial cells. H & E. $\times 500$

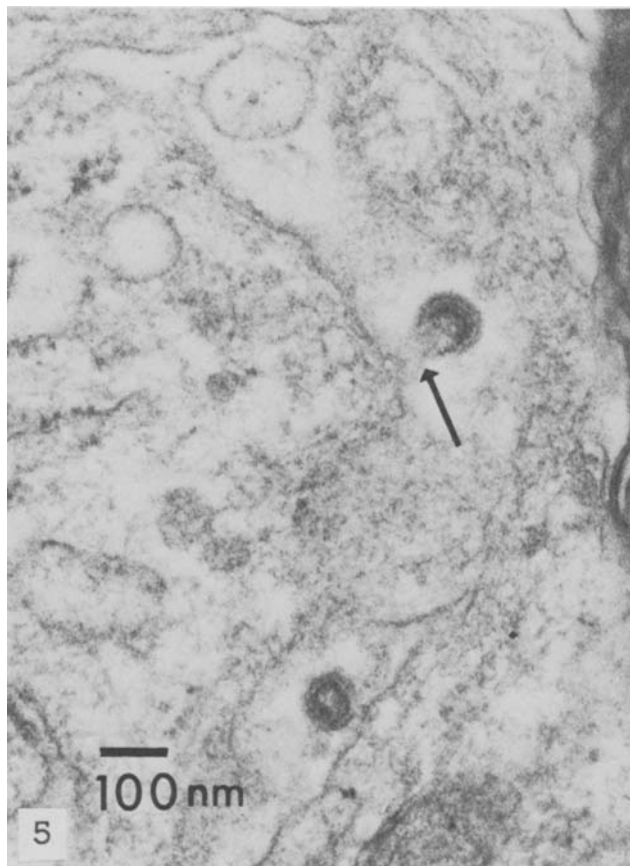
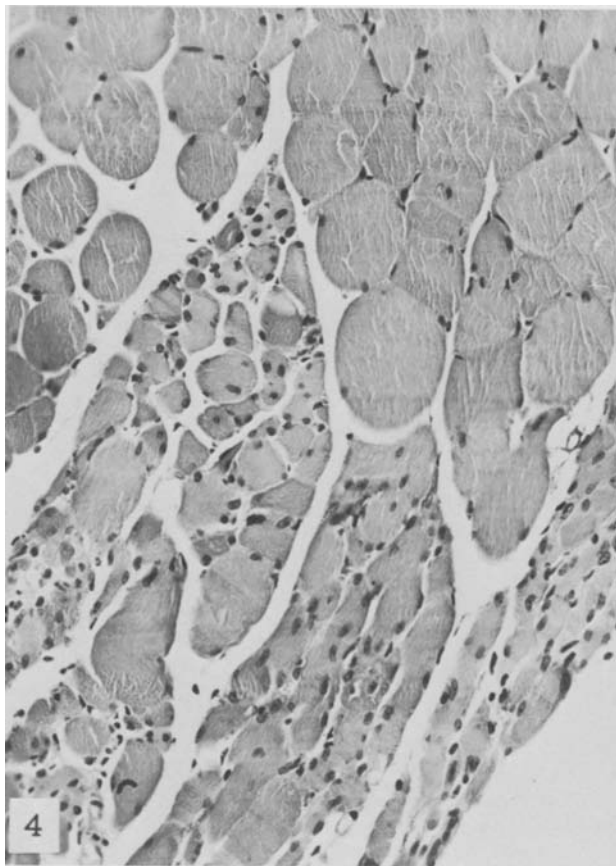


FIGURE 4.—Neurogenic atrophy of skeletal musculature from paralyzed hind limb. Fascicles of atrophic muscle fibers are clearly distinguished from larger normal sized fibers. H & E. $\times 250$

FIGURE 5.—Type-C virus budding from plasma membrane of neuron in lower spinal cord (*arrow*). Another type-C particle lies within extracellular space. Uranyl acetate & lead citrate. $\times 78,000$

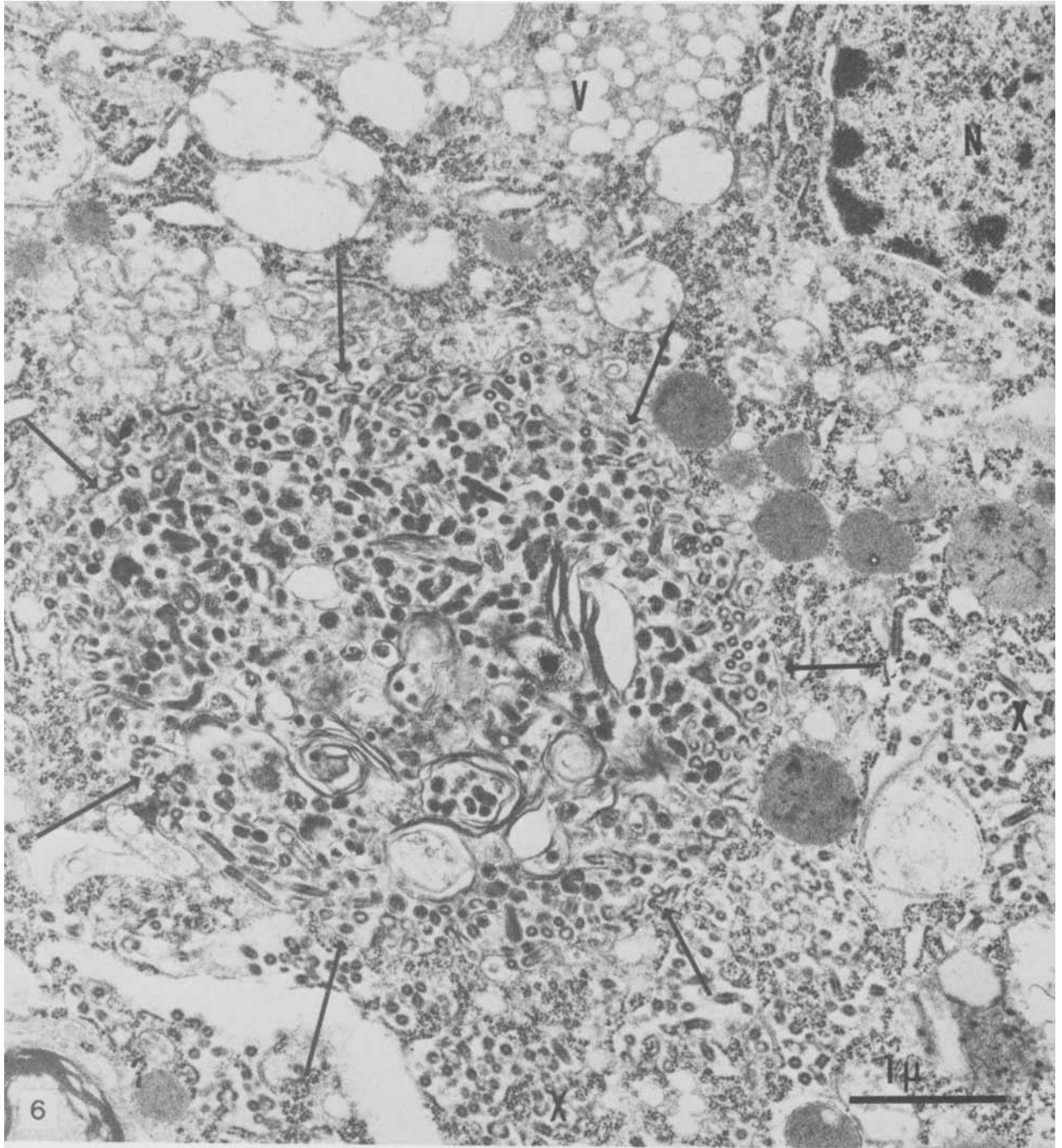


FIGURE 6.—Numerous virus particles bud into a smooth walled vacuole (outlined by arrows) in cytoplasm of neuron. Many such particles show aberrant configuration. Membranous profiles and membrane-bound dense material of questionable viral nature are also within vacuole. Numerous cylindrical budding particles and precursor nucleocapsid-like material are in cisterns of RER (X). Vacuoles (V) without virus particles are elsewhere in cytoplasm of same neuron (N). Uranyl acetate & lead citrate. $\times 24,300$

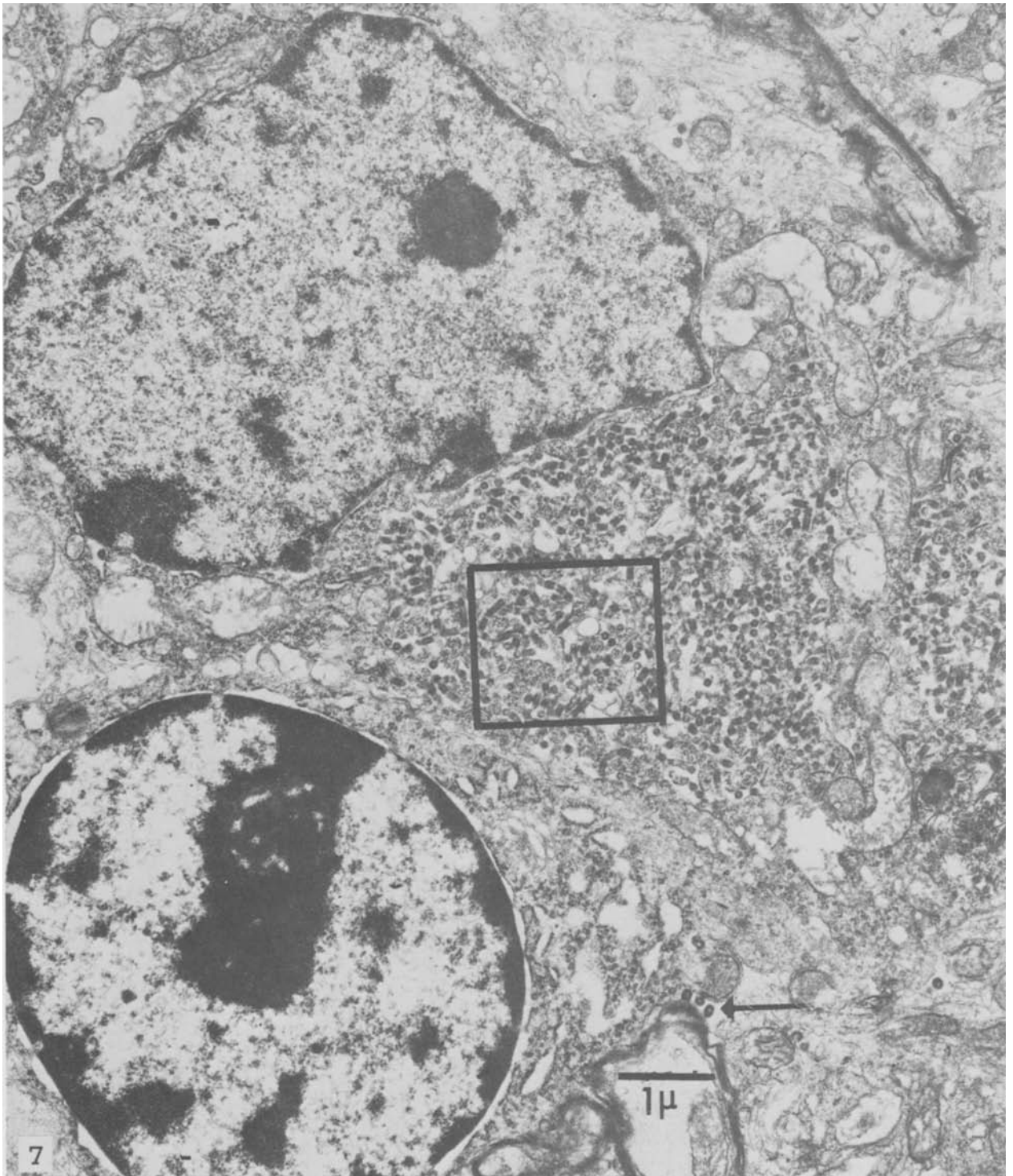


FIGURE 7.—Type-C virus particles replicating within cytoplasm of spinal cord neuron. Numerous cylindrical budding virions project into the RER. Type-C virus particles also in the extracellular space (*arrow*). Adjacent oligodendroglial cell is free of virus. Uranyl acetate & lead citrate. $\times 16,800$

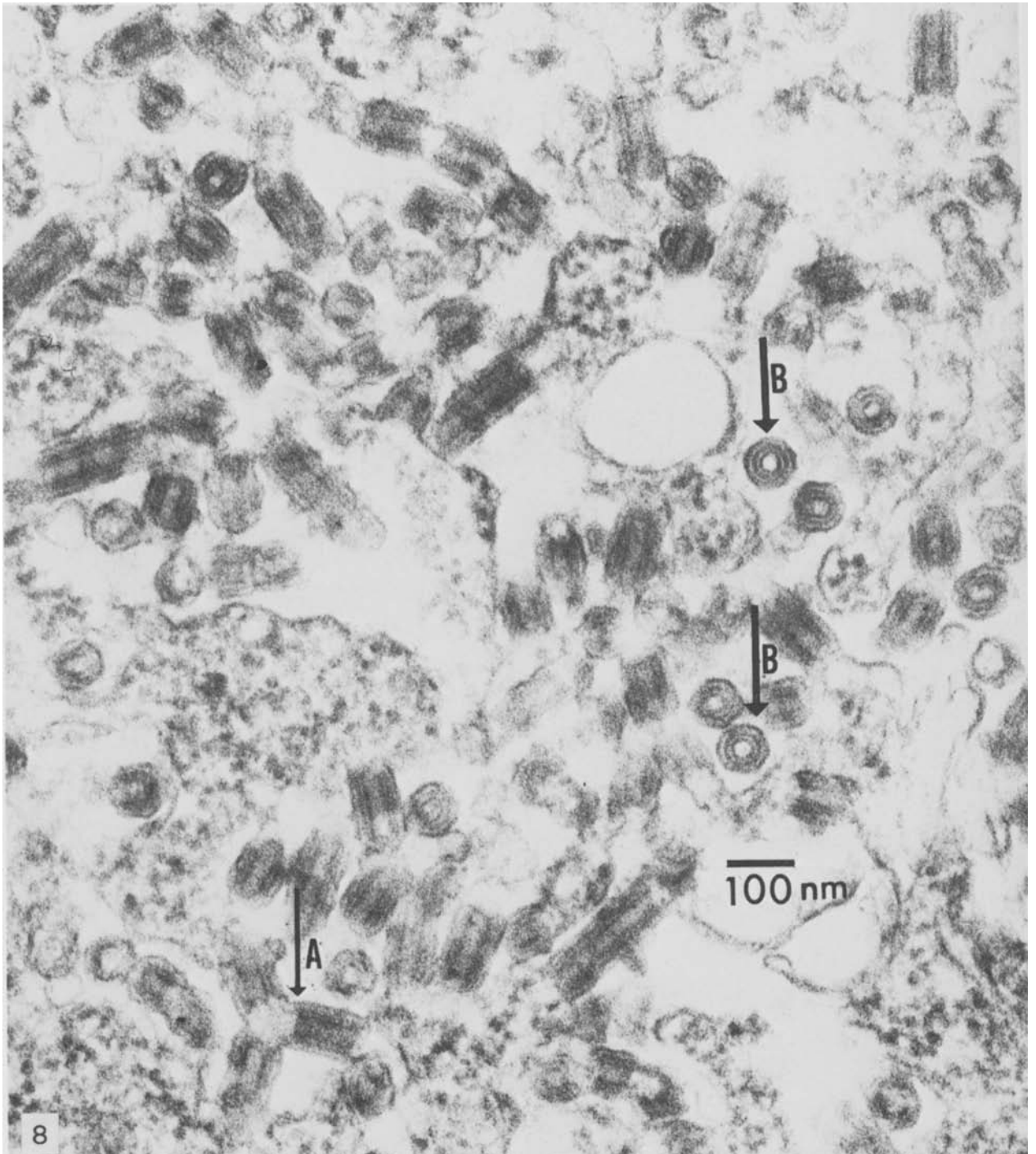


FIGURE 8.—Enclosed area of figure 7—numerous type-C virions with aberrant cylindrical budding configuration (arrow A) within cisterns of RER. Where cut in cross section (arrows B), particles show trilamellar structure characteristic of immature type-C virus particles. Uranyl acetate & lead citrate. $\times 108,000$