

Lipoma in the femoral triangle

Elroy Patrick Weledji and Felix Adolfe Elong

Department of Surgery, Obstetrics and Gynaecology, Faculty of Health Sciences, University of Buea, Limbe, PO Box 63, Buea, Cameroon

Corresponding author: Elroy P. Weledji. Email: elroypat@yahoo.co.uk

Lesson

The differential diagnosis of a lipoma in the femoral region will include a femoral hernia and vice-versa or both may coexist.

Keywords

femoral hernia, lipoma, imaging, exploration

Case report

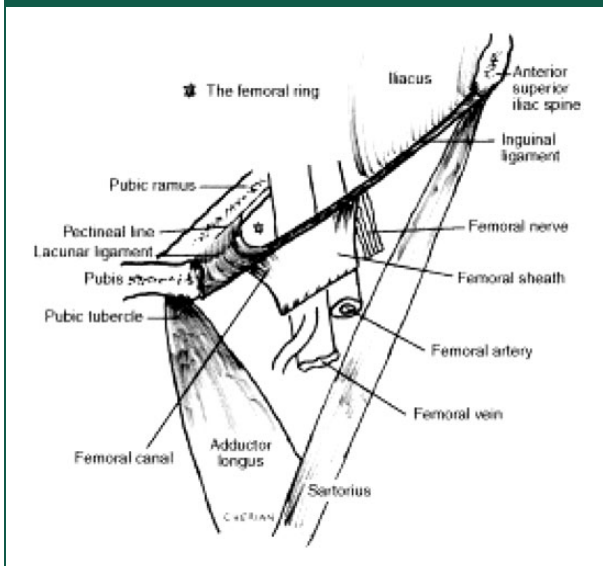
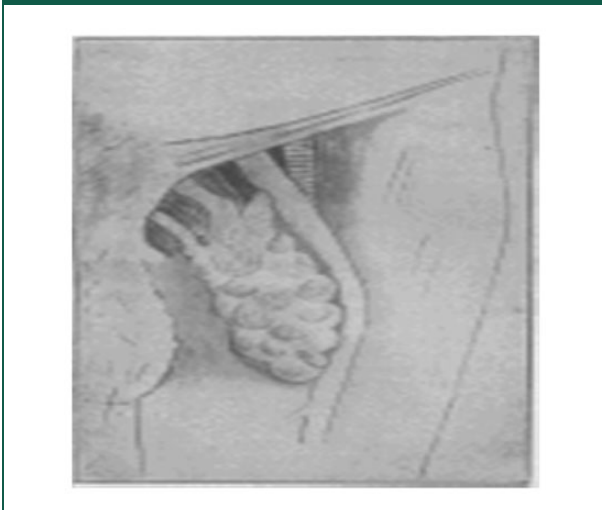
A 23-year-old woman presented with a long history of a progressive swelling in the right upper inner thigh. This was associated with some discomfort, and the poor aesthesis and shame of exposure to her partner during sexual intercourse. She was otherwise well with no past medical history. Physical examination revealed a disfiguring, non-tender, large fluctuant, prolapsing swelling measuring 10 cm × 8 cm in the upper adductor region of the thigh. The edges were smooth and palpable but for the upper edge. It was not attached to underlying muscle or overlying skin. The swelling was not warm and had no pulsation, nor cough impulse. The corresponding region of the other (L) thigh showed similar consistency but smaller in size. A presumptive diagnosis of a lipoma was made, and ultrasonographic examination reported a large lipoma with nodularity on the right thigh and a smaller lipoma on the left thigh. Following consent for the excision of the lipoma on the right thigh, a difficult and elaborate dissection in the femoral triangle revealed an irregular shaped lipoma. It had a broad base anteriorly and a narrow neck which extended deeply into a (peritoneal) hernia sac in the femoral canal (Figure 2). The sac was opened, explored and excised along with the largely associated pre(extra)-peritoneal fat. The remnant sac was suture-ligated, reduced and the femoral canal closed with nylon by approximating the inguinal ligament to the pectineal ligament. Caution was taken against injuring the femoral vein. Apart from a haematoma in the redundant cavity that was evacuated on the third postoperative day, she made good post-operative recovery and was discharged thereafter. Due to

lack of resources, a histological examination of the specimen was not done.

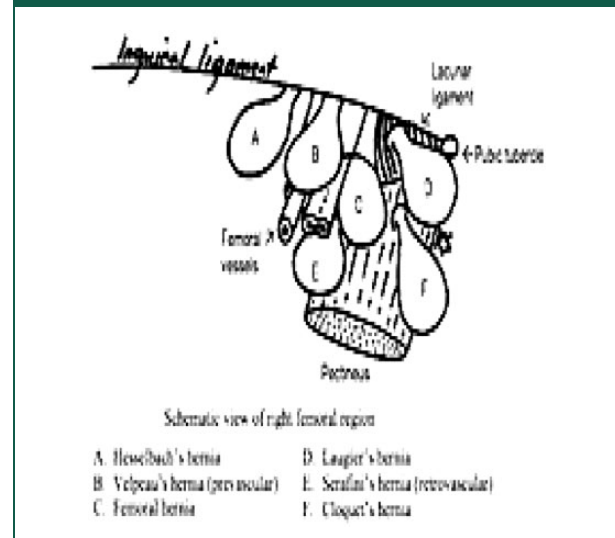
Discussion

Femoral hernias account for 5%–10% of groin hernias in adults and most occur in elderly women.¹ The incidence in the paediatric population is 0.5% and mostly misdiagnosed as an inguinal hernia.² The femoral canal (ring) is a defect in the anterior abdominal wall bounded anteriorly by the inguinal ligament, posteriorly by the pectineal ligament (Gimbernats), medially by the lacunar ligament and laterally by the femoral vein (Figure 1). The canal contains the deep inguinal node of Cloquet that drains lymph from the clitoris and penis and fatty connective tissue. The disposition of the anatomy of the female pelvis and the later loss of the fatty tissue in the femoral canal is a predisposing factor in elderly women. The (peritoneal) hernia sac may contain pre-peritoneal fat, omentum, small bowel or other visceral structure. The urgency of repair is due to the increased risk of ischaemia as the three sides of the canal are rigid structures which do not allow any expansion. The differential diagnosis of a femoral hernia include lipoma of the skin and subcutaneous tissue, inguinal hernia, enlargement of the deep inguinal node of Cloquet, saphena varix or varicosities of the saphenous vein and a psoas abscess.³ Unlike the high incidence of round ligament lipoma,⁴ preperitoneal lipoma extending through the femoral canal is relatively rare.^{5,6}

This case demonstrates the fact that a lipoma in the femoral region may actually be pre(extra)-peritoneal fat associated with a femoral hernia. Another important differential diagnosis is a hypertrophic condition of the nearby septum crurale of the sapheno-femoral junction which is mainly composed of extra-peritoneal fatty tissue. In both, the long saphenous vein is usually pushed aside (Figure 2).⁵ Lipomas are associated more frequently with large hernias.⁷ A sliding lipoma, referring to a sliding herniation of preperitoneal fat into the inguinal canal,

Figure 1. Schematic diagram of the femoral triangle.**Figure 2.** Schematic diagram of femoral hernia masquerading as a lipoma.⁵

forming a reducible indirect inguinal hernia in the absence of a peritoneal sac, has been reported.⁸ This may also occur in some femoral hernias as in this case but with a peritoneal sac. It is suggested that hypertrophic, inguinal fatty tissue should be considered as hernias only when accompanied by a peritoneal sac. The presence of the peritoneal hernia sac would determine the nature of the pathology. In a resourced area, the histological examination of the excised specimen would be routine as it would also importantly exclude a primary or metastatic deposit.⁹ Amongst the various presentations of femoral hernia, the ‘femoral’

Figure 3. Various presentations of femoral hernias.³

type (98.5%) as in this case is most common and easiest to repair.⁷ The prevascular (Velpeau's hernia) and retrovascular types (Scrafeu's hernia) occur infrequently and are extremely difficult to repair (Figure 3).^{1,7}

Primary benign tumours of the groin may arise from connective tissue, muscle, fat, blood vessels and lymphoid tissue.^{3,9} As many femoral herniae do not have the two signs diagnostic of hernia – reducibility and cough impulse – the diagnosis depends upon the site of the lump. This makes the differential diagnosis very difficult and hence the importance of clearly defining its relations to surrounding structures.³ Imaging techniques may diagnose hernias but not with a 100% specificity or sensitivity.¹⁰ Occasionally, as in this case, the diagnosis can only be finally determined during the operation.

Conclusions

Both lipoma and femoral hernia may coexist as a sliding pre-peritoneal lipoma. Imaging techniques may be misleading, thus, the need for surgical exploration.

Declarations

Competing Interests: None declared.

Funding: None declared.

Ethical approval: Written informed consent from the patient was granted to write and publish the paper.

Guarantor: MNN

Contributorship: EPW is main author, FAE contributed with literature search.

Acknowledgements: The authors acknowledge the final year medical student, Sylvie Njong, who assisted with the perioperative care of the patient.

Provenance: Not commissioned; peer-reviewed by Shaun Appleton.

References

1. Rutkow IM. Epidemiologic, economic and sociologic aspects of hernia surgery in the United States in 1990s. *Surg Clin North Am* 1998; 78: 941–951.
2. Lee SL and DuBois JJ. Laparoscopic diagnosis and repair of pediatric femoral hernia. Initial experience of four cases. *Surg Endosc* 2000; 14: 1110–1113.
3. Browse N. Hernia. In: Browse N (ed.) *An Introduction to the symptoms and signs of Surgical disease*. London: Edward Arnold, 1990.
4. Lilly MC and Arregui ME. Lipomas of the cord and round ligament. *Ann Surg* 2002; 235: 586–590.
5. Patten CJ. Lipoma in the site of a femoral hernia. *Br Med J* 1909; 1: 1059.
6. Osemek P, Pasnik K and Trojanowski P. Huge, irreducible femoral hernia interpreted as a preperitoneal lipoma in radiological findings. *Videosurgery Other Minimally Invasive Tech* 2010; 5: 35–37.
7. Kingsnorth A and Majid A. *Fundamentals of surgical practice*, 2nd ed. Cambridge: Cambridge University Press, 2006, p.279.
8. Lau H. Sliding lipoma: an indirect inguinal hernia without a peritoneal sac. *J Laparoendosc Adv Surg Tech A* 2004; 14: 57–59.
9. Wang T and Vaiperyl R. Hernia sacs: is a histological examination necessary? *J Clin Pathol* 2015; 66: 104–106.
10. Shadbolt C, Heinze S and Dietrich R. Imaging of groin masses: inguinal anatomy and pathologic conditions revisited. *Radiographics* 2001; 21: 261–271.