

Hemophagocytic Lymphohistiocytosis Secondary to Human Immunodeficiency Virus-Associated Histoplasmosis

Anthony A. Castelli,¹ David G. Rosenthal,² Rachel Bender Ignacio,^{3,4} and Helen Y. Chu³

¹University of Washington School of Medicine, ²Department of Medicine, ³Division of Allergy and Infectious Diseases, Department of Medicine, University of Washington, and ⁴Global Oncology, Vaccine and Infectious Disease Division, Fred Hutchinson Cancer Research Center, Seattle, Washington

Hemophagocytic lymphohistiocytosis (HLH) in immunocompromised hosts is a fulminant syndrome of immune activation with high rates of mortality that may be triggered by infections or immunodeficiency. Rapid diagnosis and treatment of the underlying disorder is necessary to prevent progression to multiorgan failure and death. We report a case of HLH in a patient with human immunodeficiency virus, disseminated histoplasmosis, *Mycobacterium avium* complex, and *Escherichia coli* bacteremia. We discuss management of acutely ill patients with HLH and treatment of the underlying infection versus initiation of HLH-specific chemotherapy.

Keywords. histoplasmosis; HIV; HLH.

Hemophagocytic lymphohistiocytosis (HLH) is a syndrome of unregulated macrophage activation resulting in overproduction of inflammatory cytokines and hemophagocytosis [1]. Secondary HLH is due to another underlying disease process such as infection, autoimmune disease, or malignancy. Hemophagocytic lymphohistiocytosis can occur due to human immunodeficiency virus (HIV) or associated opportunistic infections [2]. We present the case of a severely immunocompromised patient with HLH and discuss issues related to diagnosis and management of acutely ill patients with multiple potential etiologies for HLH.

Received 8 July 2015; accepted 16 September 2015.

Correspondence: Helen Y. Chu, MD, MPH, 1616 Eastlake Ave E. Suite 320, MS 356423, Seattle, WA 98102 (helenchu@uw.edu).

Open Forum Infectious Diseases

© The Author 2015. Published by Oxford University Press on behalf of the Infectious Diseases Society of America. This is an Open Access article distributed under the terms of the Creative Commons Attribution-NonCommercial-NoDerivs licence (<http://creativecommons.org/licenses/by-nc-nd/4.0/>), which permits non-commercial reproduction and distribution of the work, in any medium, provided the original work is not altered or transformed in any way, and that the work is properly cited. For commercial re-use, please contact journals.permissions@oup.com.

DOI: 10.1093/ofid/ofv140

CASE REPORT

A 32-year-old Mexican man presented to a community clinic with 2 months of low-grade fevers, night sweats, odynophagia, and 30 pound weight loss. He was diagnosed with HIV with a CD4⁺ count of 3 cells/mm³ and HIV viral load of 354 800 copies/mL. On presentation to the HIV clinic, his family reported that he had become confused during the interval time. The patient had a temperature of 38.4°C and a heart rate of 115 beats per minute, with examination remarkable for oropharyngeal plaques, cachexia, and delirium without focal neurologic deficits. Laboratory test results were notable for aspartate aminotransferase 162 µ/L, alanine aminotransferase 56 µ/L, alkaline phosphatase 112 µ/L, total bilirubin 1.6 mg/dL, white blood cell count of 3.83 × 10³/mL, hemoglobin 10.4 g/dL, platelet count 145 × 10³/µL, and a lactate dehydrogenase of 1679 µ/L. A computed tomography scan of the chest, abdomen, and pelvis was remarkable for enlarged mediastinal lymph nodes up to 21 mm × 12 mm with borderline splenomegaly and no major abdominal or retroperitoneal lymphadenopathy, a nonspecific finding commonly seen in infection, malignancy, granulomatous diseases, and a number of other diseases (Figure 1). The mediastinal lymphadenopathy in the setting of HIV prompted concern for Hodgkin's lymphoma, disseminated fungal infections, pulmonary tuberculosis, and multicentric Castleman's disease. The patient was directly admitted to the hospital and started on fluconazole for oropharyngeal candidiasis and cefepime for fever and hypotension. Blood cultures grew *Escherichia coli*, susceptible to cefepime; however, daily fevers persisted. Epstein-Barr virus (EBV) studies showed a positive EBV immunoglobulin (Ig)G and nuclear antibody, negative IgM, and an EBV viral load of 830 IU/mL. Sepsis physiology persisted, with worsening of liver function tests and pancytopenia. A bone marrow biopsy was performed that demonstrated hemophagocytosis (Figure 2), and the oncology consult service recommended initiation of dexamethasone and etoposide following the HLH-2004 protocol. This was deferred due to concern for underlying infection [3]. Further results included a serum ferritin of 64 410 ng/mL (reference range, 20–230 ng/mL), serum fibrinogen of serum triglyceride level of 234 mg/dL (reference range, 0–150 mg/dL), soluble CD25 of 2823 units/mL (reference range, 0 to ≤1033 pg/mL), and natural killer (NK) cell functional assay FC/LU30 = 7 (reference range, 7–125 LU30). With fever, pancytopenia, hemophagocytosis on bone marrow, elevated CD25, low NK cell activity, elevated triglycerides, and elevated ferritin, the patient met criteria for HLH. Wright-Giemsa stain from a blood culture showed small

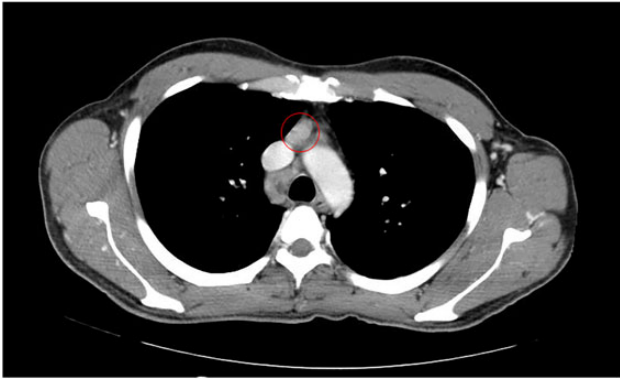


Figure 1. Chest computed tomography scan with contrast, showing mediastinal lymphadenopathy. Highlighted is one 12 × 21 mm enlarged lymph node in the right mediastinum.

clusters of yeast-like organisms (Figure 1B) concerning for underlying histoplasmosis, and liposomal amphotericin B was initiated. Patient's fever, hypotension, and hyperferritinemia resolved within the next 1–2 days. On hospital day (HD) 7, cultures from blood, bone marrow, and bronchoalveolar lavage all grew yeast, confirmed to be *Histoplasma capsulatum*; urine *Histoplasma* antigen was >19 ng/mL. Acid-fast bacilli cultures from blood and sputum grew *Mycobacterium avium complex* (MAC), and clarithromycin and ethambutol were started on HD-12. All subsequent blood and urine cultures were negative for *Histoplasma*, MAC, and *E coli*. After 2 weeks of clinical improvement on the liposomal amphotericin B, he was transitioned to oral itraconazole 200 mg twice daily, with plans to maintain treatment until CD4 >150 and a minimum of 12 months of therapy. We initiated antiretroviral therapy (ART) 3 weeks after starting *Histoplasma* treatment, balancing the evidence favoring immediate ART initiation during opportunistic infections with the risk of immune reconstitution inflammatory syndrome provoking recurrent HLH, which can be life-threatening [4]. Tenofovir/emtricitabine and

raltegravir were chosen to avoid CYP3A4 interactions with itraconazole and MAC therapy; rifamycins for MAC were also avoided for the same reasons. The patient continues to do well 15 months later at the follow-up visit.

DISCUSSION

Hemophagocytic lymphohistiocytosis is a life-threatening syndrome of hyperinflammation leading to multiorgan injury. Patients often present with a sepsis-like syndrome, and high rates of mortality are observed with untreated disease. Hemophagocytic lymphohistiocytosis is diagnosed by identifying known genetic mutations or fulfilling a minimum of 5 of 8 of the following criteria: fever, splenomegaly, cytopenia in 2 cell lines, hypertriglyceridemia or hypofibrinogenemia, hemophagocytosis in bone marrow, spleen or lymph nodes, low or absent NK cell activity, ferritin >500 µg/L, and soluble CD25 >2400 U/mL [3]. The pathogenesis of HLH includes defective cytotoxic regulatory function of macrophages, and NK cells leads to unregulated cytokine release and cell damage. Natural killer cells are a subset of lymphocytes responsible for elimination of activated macrophages, and low levels of NK cell activity are part of the diagnostic criteria for HLH. As a result of this dysregulated activation, excessive cytokine release occurs with elevated levels of interferon-γ, tumor necrosis factor-α, interleukin (IL)-6, IL-10, and IL-12, and soluble interleukin-2 receptor (CD25). High levels of soluble CD25 are part of the diagnostic criteria for HLH [5]. Secondary HLH is postulated to be due to activation of the immune system in response to a trigger such as malignancy, infection, or autoimmune disease [1, 3]. The HLH-2004 guidelines recommend that primary HLH be treated with an induction phase of steroids, cyclosporine A, and etoposide for 8 weeks [3]. For secondary HLH, it is controversial when immunosuppressive therapy is indicated versus treatment of the underlying infection alone [3]. In contrast, EBV-associated HLH is successfully treated with immunosuppressive agents alone [3]. Management of HLH

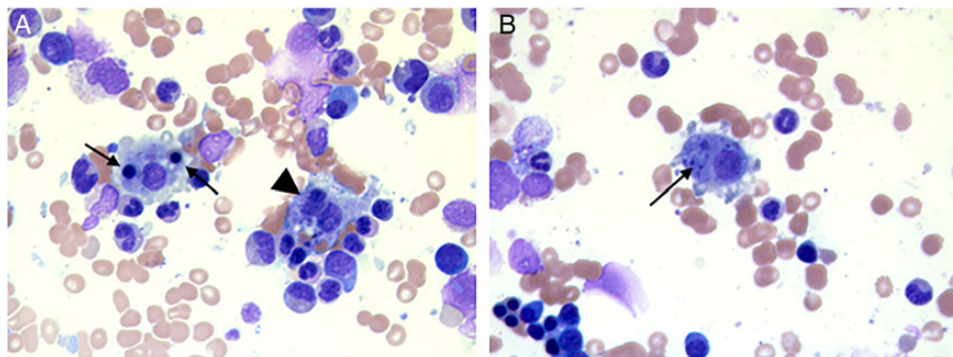


Figure 2. Wright-Giemsa stains (A) illustrating 2 macrophages with red blood cells (arrows) and a lymphocyte (arrowhead) in the cytoplasm, consistent with hemophagocytosis. (B) Wright-Giemsa stains illustrate a macrophage with phagocytosed yeast forms surrounded by the clear zone characteristic of *Histoplasma capsulatum*.

Table 1. Cases of Histoplasmosis-Associated HLH, Treatment, and Outcomes

Source	Underlying Disease	Treatment	Outcome
Reiner and Spivak [8]	Renal transplant, CMV, HSV	Amphotericin B	Survived
Keller and Kurtzberg [9]	Chronic mucocutaneous candidiasis	Amphotericin B	Survived
Koduri et al [10]	HIV/AIDS	Amphotericin B with IVIG	Deceased
	HIV/AIDS	Amphotericin B with IVIG	Deceased
	HIV/AIDS	Amphotericin B with IVIG	Deceased
	HIV/AIDS	Amphotericin B with IVIG	Survived
	HIV/AIDS	Amphotericin B	Survived
	HIV/AIDS	Amphotericin B	Survived
Kumar et al [11]	None reported	Patient expired before initiation of therapy	Deceased
	HIV	Patient expired before initiation of therapy	Deceased
Rao et al [12]	CLL	Amphotericin B	Survived
Masri et al [13]	Heart transplant	Amphotericin B	Survived
Saluja et al [14]	Immunocompetent	Itraconazole	Survived
Gil-Brusola et al [15]	HIV/AIDS	Patient expired before initiation of therapy	Deceased
Guiot et al [16]	HIV/AIDS	Amphotericin B	Survived
Sanchez et al [17]	HIV/AIDS, TB	Amphotericin B and antituberculosis therapy	Survived
Wang et al [18]	Hepatitis C virus, cryoglobulinemia	Patient expired before initiation of therapy	Deceased
Phillips et al [7]	Sarcoidosis	Amphotericin B, symptoms relapsed and treated with CCE	Survived
De Lavaissiere et al [19]	HIV, IRIS within 3 weeks of ART	Amphotericin B with IVIG	Survived
Lo et al [20]	Renal transplant	Amphotericin B	Survived
	Renal transplant	Amphotericin B	Survived
van Koeveringe et al [6]	CLL	CCE, symptoms relapsed and resolved with amphotericin B	Survived

Abbreviations: AIDS, acquired immune deficiency syndrome; ART, antiretroviral therapy; CCE, corticosteroids, cyclosporine and etoposide; CLL, chronic lymphocytic leukemia; CMV, cytomegalovirus; HIV, human immunodeficiency virus; HLH, hemophagocytic lymphohistiocytosis; HSV, herpes simplex virus; IRIS, immune reconstitution inflammatory syndrome; IVIG, intravenous immunoglobulin; TB, tuberculosis.

in the setting of disseminated histoplasmosis is less well defined (Table 1). Of 16 patients who received amphotericin B, 13 survived and had resolution of both disseminated histoplasmosis and HLH. In 1 case, initial treatment with immunotherapy resulted in symptom relapse and initiation of amphotericin B [6]. In another case, a patient responded to immunotherapy after worsening on amphotericin B treatment alone [7]. In our patient, treatment with amphotericin B was associated with marked clinical improvement without use of immunosuppressive therapy.

CONCLUSIONS

In conclusion, a thorough investigation should be done in an immunosuppressed patient with persistent fevers and suspicion for HLH, because prompt initiation of treatment for the specific trigger may improve outcomes and limit use of cytotoxic chemotherapy.

Acknowledgments

We thank all of the clinicians involved in the care of this patient. We also acknowledge Dr. Daniel Sabath for providing the images.

Financial support. This work was supported by the National Institutes of Health (Grants T32-CA-080416 [to R. B. I.] and K23-A1103105 [to H. Y. C.]).

Potential conflicts of interest. H. Y. C. reports grants from GlaxoSmithKline, grants from PATH, grants and nonfinancial support from the Bill and Melinda Gates Foundation, and grants from the Thrasher Foundation, outside the submitted work.

All authors have submitted the ICMJE Form for Disclosure of Potential Conflicts of Interest. Conflicts that the editors consider relevant to the content of the manuscript have been disclosed.

References

1. Mehta RS, Smith RE. Hemophagocytic lymphohistiocytosis (HLH): a review of literature. *Med Oncol* 2013; 30:740.
2. Roupheal NG, Talati NJ, Vaughan C, et al. Infections associated with haemophagocytic syndrome. *Lancet Infect Dis* 2007; 7:814–22.
3. Henter JI, Horne A, Arico M, et al. HLH-2004: diagnostic and therapeutic guidelines for hemophagocytic lymphohistiocytosis. *Pediatr Blood Cancer* 2007; 48:124–31.
4. Cuttelod M, Pascual A, Baur Chaubert AS, et al. Hemophagocytic syndrome after highly active antiretroviral therapy initiation: a life-threatening event related to immune restoration inflammatory syndrome? *AIDS* 2008; 22:549–51.
5. Janka GE, Lehmbert K. Hemophagocytic lymphohistiocytosis: pathogenesis and treatment. *Hematology Am Soc Hematol Educ Program* 2013; 2013:605–11.
6. van Koeveringe MP, Brouwer RE. *Histoplasma capsulatum* reactivation with haemophagocytic syndrome in a patient with chronic lymphocytic leukaemia. *Neth J Med* 2010; 68:418–21.
7. Phillips J, Staszewski H, Garrison M. Successful treatment of secondary hemophagocytic lymphohistiocytosis in a patient with disseminated histoplasmosis. *Hematology* 2008; 13:282–5.

8. Reiner AP, Spivak JL. Hematophagic histiocytosis. A report of 23 new patients and a review of the literature. *Medicine (Baltimore)* **1988**; 67:369–88.
9. Keller FG, Kurtzberg J. Disseminated histoplasmosis: a cause of infection-associated hemophagocytic syndrome. *Am J Pediatr Hematol Oncol* **1994**; 16:368–71.
10. Koduri PR, Chundi V, DeMarais P, et al. Reactive hemophagocytic syndrome: a new presentation of disseminated histoplasmosis in patients with AIDS. *Clin Infect Dis* **1995**; 21:1463–5.
11. Kumar N, Jain S, Singh ZN. Disseminated histoplasmosis with reactive hemophagocytosis: aspiration cytology findings in two cases. *Diagn Cytopathol* **2000**; 23:422–4.
12. Rao RD, Morice WG, Phylily RL. Hemophagocytosis in a patient with chronic lymphocytic leukemia and histoplasmosis. *Mayo Clin Proc* **2002**; 77:287–90.
13. Masri K, Mahon N, Rosario A, et al. Reactive hemophagocytic syndrome associated with disseminated histoplasmosis in a heart transplant recipient. *J Heart Lung Transplant* **2003**; 22:487–91.
14. Saluja S, Sunita , Bhasin S, et al. Disseminated histoplasmosis with reactive haemophagocytosis presenting as PUO in an immunocompetent host. *J Assoc Physicians India* **2005**; 53:906–7.
15. Gil-Brusola A, Peman J, Santos M, et al. Disseminated histoplasmosis with hemophagocytic syndrome in a patient with AIDS: description of one case and review of the Spanish literature. *Rev Iberoam Micol* **2007**; 24:312–6.
16. Guiot HM, Bertran-Pasarell J, Tormos LM, et al. Ileal perforation and reactive hemophagocytic syndrome in a patient with disseminated histoplasmosis: the role of the real-time polymerase chain reaction in the diagnosis and successful treatment with amphotericin B lipid complex. *Diagn Microbiol Infect Dis* **2007**; 57:429–33.
17. Sanchez A, Celaya AK, Victorio A. Histoplasmosis-associated hemophagocytic syndrome: a case report. *AIDS Read* **2007**; 17:496–9.
18. Wang Z, Duarte AG, Schnadig VJ. Fatal reactive hemophagocytosis related to disseminated histoplasmosis with endocarditis: an unusual case diagnosed at autopsy. *South Med J* **2007**; 100:208–11.
19. De Lavaissiere M, Manceron V, Bouree P, et al. Reconstitution inflammatory syndrome related to histoplasmosis, with a hemophagocytic syndrome in HIV infection. *J Infect* **2009**; 58:245–7.
20. Lo MM, Mo JQ, Dixon BP, et al. Disseminated histoplasmosis associated with hemophagocytic lymphohistiocytosis in kidney transplant recipients. *Am J Transplant* **2010**; 10:687–91.