

Trauma and reconstruction

Subcapsular hematoma of the kidney after extracorporeal shock wave lithotripsy: A rare complication

Ahmed Jdaini^{*,**}, Mohammed Aynaou, Mohamed Irzi, Tarik Mhanna, Hammou El farhaoui, Ali Barki

Department of Urology, Mohammed IV University Medical Center, Mohammed the First University Oujda, Morocco

ARTICLE INFO

Key words:

Extracorporeal shock wave lithotripsy
Subcapsular renal hematoma
Surgery

ABSTRACT

extracorporeal shock wave (ESLW) is a common and relatively safe procedure, with a high success rate and low side effects.

its complications are limited to the kidneys and always disappear spontaneously. Acute pain is the only manifestation of kidney hematoma and should be explored. Conservative treatment is generally the treatment of choice.

We reported the case of a 60-year-old man who underwent extracorporeal lithotripsy, 4 h after the procedure, he was presented to the emergency with severe abdominal pain, and a CT scan showed a hematoma of the left kidney. Conservative treatment was performed, and the patient was discharged at home in 48h.

Introduction:

The introduction of shock wave fragmentation in the field of urolithiasis is one of the major therapeutic contributions in the history of urology.¹ It is the method of choice for the treatment of most stones of renal and ureteral localizations, because it is a minimally invasive method and with less complications.

Otherwise, its application is not completely free from undesirable effects. In fact, it causes trauma or others significant injuries in the organs crossed by shock waves, including the kidney, of which the renal hematoma is one of these injuries.

By the report of this case we hope to increase the clinical suspicion of renal hematomas when the patients with kidney surgery history present an acute pain of the flanks after extracorporeal lithotripsy.

Case presentation:

A 60-year-old man with a history of left pyelolithotomy, spleno-pancreatectomy for adenocarcinoma in the tail of the pancreas, no other medical history of hemostasis disorder, and he was not on blood thinners. The patient is followed in our department for left renal lithiasis of 7 mm in lower caliceal and pyelic stones of 15 mm for which he has not undergone any procedure. Based on the patient's history, we decide

to treat this lithiasis by extracorporeal lithotripsy. The lithotripsy session was lasting 50 min and without any anesthesia. Besides the patient has received 3000 shocks without incident during this session. Four hours after SWL, the patient was presented to the emergency room with slight pain on the left flank without hematuria and without any other signs.

The clinical examination showed that the patient was afebrile and appeared healthy. There were no abnormal pulmonary. Blood tests were without particularity.

Computed tomography showed a 38mm subcapsular renal hematoma without extravasation of the contrast medium, 7mm and 15 mm stones in left renal (fig1).

The conservative attitude has been adopted the patient was hospitalized in a surgery unit with strict bed rest for six days. Put on analgesic medical treatment, a daily biological control did not objectify any anomaly. A control scanner was performed 48 hours after hospitalization, which objectified the reduction in size of the hematoma (fig2).

Discussion

Since its first presentation in the beginning 1980s, extracorporeal shock wave lithotripsy (ESWL) has revolutionized the treatment of urolithiasis. The shock waves generated are responsible for the destruction of stones. However they can also cause serious

* Corresponding author.

E-mail addresses: dr.jdainiahmed@gmail.com (A. Jdaini), aynmed89@gmail.com (M. Aynaou), irziirzi1992@gmail.com (M. Irzi), tarik.mhanna@hotmail.com (T. Mhanna), h.elfarhaoui@gmail.com (H. El farhaoui), alibarki@hotmail.com (A. Barki).

<https://doi.org/10.1016/j.eucr.2020.101194>

Received 29 February 2020; Received in revised form 2 April 2020; Accepted 2 April 2020

Available online 3 April 2020

2214-4420/© 2020 The Authors.

Published by Elsevier Inc.

This is an open access article under the CC BY-NC-ND license

(<http://creativecommons.org/licenses/by-nc-nd/4.0/>).

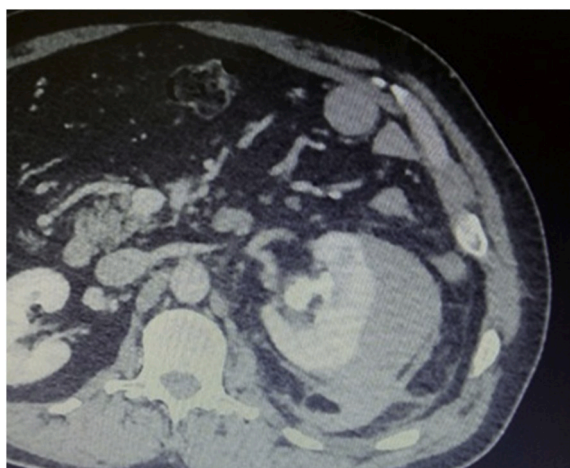


Fig. 1. 38mm left subcapsular renal hematoma.

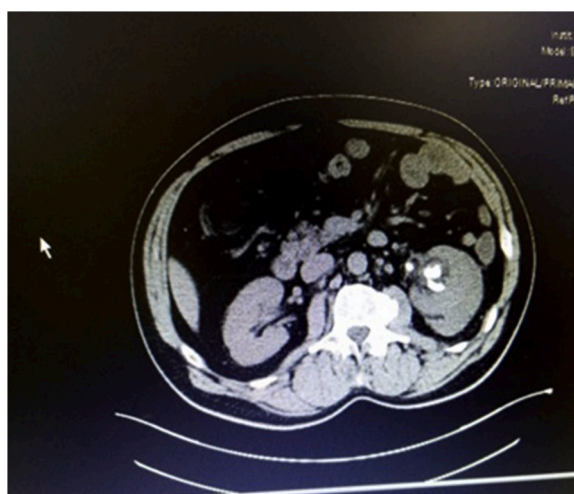


Fig. 2. Control scanner showed a reduction in the size of the hematoma.

complications.

Renal hematomas are rare and occur in <1% of patients who undergo ESWL.² however, performing imaging after lithotripsy increases the frequency of hematomas by 20–25%.

ESWL causes renal parenchyma lesions as well as renal vascular lesions which consists of dilation of the veins, endothelial lesions and the formation of thrombus which will obviously cause intra parenchymal hemorrhage and therefore the formation of a renal hematoma.³

Other serious complications have been reported such as acute pancreatitis, splenic rupture, intestinal damage, myocardial infarction and rupture of aortic aneurysms.³

Several risk factors have been linked to the formation of a renal hematoma after lithotripsy, particularly the pre-existence of uncontrolled or poorly controlled hypertension, as well as diabetes mellitus, generalized atherosclerosis, coronary artery disease and obesity are associated with increased rates of hematoma formation, in addition to risk factors such as underlying coagulopathy, or thrombocytopenia, moreover the number of shocks and the frequency of shock delivery were found to be a predisposing factor for hematoma formation.

However, no study has incriminated the surgical history as a risk factor for renal hematomas after extracorporeal lithotripsy.

Indeed, most common symptoms were lower back, flank pain and gross hematuria.

In our case, the patient had a history of renal surgery and developed flank pain, a relatively common symptom after ESWL, and was hemodynamically stable. After all, the severity of the pain with the non-response to analgesia raised the suspicion of a more severe pathology, thus warranting a more thorough investigation by computed tomography.

It is not common to do CT scans for each patient presenting for flank pain after ESWL, as most of these patients will respond to analgesia and the pain is usually classic flank pain.

Conclusion:

Subcapsular renal hematoma should be suspected in patients with pain in the lower back or acute flank after ESWL, especially in patients who do not respond to analgesic treatments.

Supportive care and observation are a treatment of choice, in our case the patient's surgical history seems to have a role in the onset of renal hematoma after extracorporeal lithotripsy.

Declaration of competing interest

The authors declare they have no relevant interest(s) to disclose.

References

1. Chaussy C, Schmiedt E, Jocham D, Brendel W, Forssmann B, Walther V. First clinical experience with extracorporeally induced destruction of kidney stones by shock waves. *J Urol.* 1982;127(3):417–420.
2. Skolarikos A, Alivizatos G, de la Rosette J, Liatsikos EN. Extracorporeal shock wave lithotripsy 25 years later: complications and their prevention. *Eur Urol.* 2006;50(5): 981–990.
3. Silberstein Jonathan, Lakin Charles M, Parsons J Kellogg. Division of urology, university of California-san diego (UCSD) medical center, san diego, CA; †department of veterans affairs medical center, san diego, CA; ‡moore's UCSD cancer center, La jolla, CA. *Rev Urol.* 2008;10(3):236–241.