



Original Article

The reverse question mark and L.G. Kempe incisions for decompressive craniectomy: A case series and narrative review of the literature

Edgar G. Ordóñez-Rubiano¹, Luisa F. Figueredo², Carlos A. Gamboa-Oñate¹, Ivo Kehayov³, Jorge A. Rengifo-Hipus⁴, Ingrid J. Romero-Castillo⁴, Angie P. Rodríguez-Medina⁴, Javier G. Patiño-Gomez¹, Oscar Zorro¹

¹Department of Neurosurgery, Hospital de San José - Fundación Universitaria de Ciencias de la Salud, Bogota, Colombia, ²Department of Neurosurgery, Mayo Clinic, Jacksonville, Florida, USA, ³Department of Neurosurgery, Faculty of Medicine, Medical University of Plovdiv, Plovdiv, Bulgaria, ⁴Department of Neurosurgery, School of Medicine, Hospital de San José - Fundación Universitaria de Ciencias de la Salud, Bogota, Colombia.

E-mail: *Edgar G. Ordóñez-Rubiano - egordonez@fucsosalud.edu.co; Luisa F Figueredo - lf.figueredo1341@gmail.com; Carlos A. Gamboa-Oñate - gamboaoate.carlos@gmail.com; Ivo Kehayov - dr.kehayov@gmail.com; Jorge A. Rengifo-Hipus - jarengifo@fucsosalud.edu.co; Ingrid J. Romero-Castillo - ijromero@fucsosalud.edu.co; Angie P. Rodríguez-Medina - aprodriguez2@fucsosalud.edu.co; Javier G. Patiño-Gomez - javierpati@gmail.com; Oscar Zorro - oscarzorro19@yahoo.com



***Corresponding author:**

Edgar G. Ordóñez-Rubiano
Department of Neurosurgery,
Hospital de San José - Fundación
Universitaria de Ciencias de la
Salud (FUCS), Bogota, Colombia.
egordonez@fucsosalud.edu.co

Received : 15 January 2022

Accepted : 22 June 2022

Published : 08 July 2022

DOI

10.25259/SNI_59_2022

Quick Response Code:



ABSTRACT

Background: Decompressive craniectomy (DC) is a lifesaving procedure, relieving intracranial hypertension. Conventionally, DCs are performed by a reverse question mark (RQM) incision. However, the use of the L. G. Kempé's (LGK) incision has increased in the last decade. We aim to describe the surgical nuances of the LGK and the standard RQM incisions to treat patients with severe traumatic brain injury (TBI), intracranial hemorrhage (ICH), empyema, and malignant ischemic stroke. Furthermore, to describe, surgical limitations, wound healing, and neurological outcomes related to each technique.

Methods: To describe a prospective acquired, case series including patients who underwent a DC using either an RQM or an LGK incision in our institution between 2019 and 2020.

Results: A total of 27 patients underwent DC. Of those, ten patients were enrolled. The mean age was 42.1 years (26–71), and 60% were male. Five patients underwent DC using a large RQM incision; three had severe TBI, one ICH, and one ischemic stroke. The other five patients underwent DC using an LGK incision (one ICH, one subdural empyema, and one ischemic stroke). About 50% of patients presented severe headaches associated with vomiting, and six presented altered mental status (drowsy or stuporous). Motor deficits were present in four cases. In patients with ischemic or hemorrhagic stroke, symptoms were directly related to the stroke location. Hospital stays varied between 13 and 22 days. No readmissions were recorded, and no fatal outcome was documented during the follow-up.

Conclusion: The utility of the LGK incision is comparable with the classic RQM incision to treat acute brain injuries, where an urgent decompression must be performed. Some of these cases include malignant ischemic strokes, ICH, and empyema. No differences were observed between both techniques in terms of prevention of scalp necrosis and general cosmetic outcomes.

Keywords: Decompressive craniectomy, Intracranial hemorrhage, Kempe, Traumatic brain injury

This is an open-access article distributed under the terms of the Creative Commons Attribution-Non Commercial-Share Alike 4.0 License, which allows others to remix, transform, and build upon the work non-commercially, as long as the author is credited and the new creations are licensed under the identical terms.

©2022 Published by Scientific Scholar on behalf of Surgical Neurology International

INTRODUCTION

Brain edema results from a multifactorial combination of pathological mechanisms that vary depending on the etiology of the brain injury.^[23] The edema produces an elevated intracranial pressure (ICP) with further displacement of brain tissue that can lead to herniation, resulting in permanent neurologic sequelae or death.^[6] Decompressive craniectomy (DC) is a neurosurgical procedure defined as the surgical removal of a portion of the skull. It has been performed to relieve elevated ICP in patients with traumatic brain injury (TBI).^[3,7] In a severe TBI setting, a large frontotemporoparietal DC (at least 12 × 15 × 15 diameter) is indicated for patients with refractory intracranial hypertension and diffuse parenchymal injury to reduce mortality and improve neurological outcomes.^[4] To achieve an adequate exposure for a large DC, the skin incision planning is mandatory. The hemispherectomy incision of Ludwig G. Kempe, *a.k.a* L.G. Kempe's (LGK) incision^[9] described as a midline sagittal incision with a "T-bar" extension, and the standard large frontotemporoparietal reverse question mark (RQM) incision remains the most used incisions for this purpose.^[17]

In wartime, neurosurgeons have noted a breakdown of the RQM incision along the posterior curve. The posterior portion of the scalp flap is subject to dependent swelling and more surface contact.^[17] In addition, when the RQM incision is used in patients with complex scalp wounds, it can result in islands of devascularized scalp, prone to necrosis, and further infection.^[17] This allowed the resurgence in the use of the LGK incision, which offers the advantage of limiting the dependent portion of the wound and provides a better blood supply to the scalp. This incision also preserves the occipital and posterior auricular arterial supply to the scalp flap, making the posterior portion less dependent on the arterial supply vessels.^[9,17] In wartimes, the Kempe's incision demonstrated less posterior wound breakdown and less temporalis muscle atrophy.^[17]

The DC was first reported by Kocher and Cushing^[5,20] and has been used for different clinical scenarios, primarily for patients with severe TBI, but also stroke,^[15] subdural empyemas,^[12,22] and other multiple etiologies.^[17] In this study, we describe the surgical nuances of both LGK and RQM incisions. We review the surgical and clinical aspects of both surgical techniques and present our early results of a case series in using these incisions to perform a large frontotemporoparietal DC in patients with severe TBI, subdural empyema, and intracranial hemorrhage (ICH), comparing surgical features, technical limitations, wound healing, and neurological outcomes.

MATERIALS AND METHODS

Clinical data and study design

This is a retrospective case series study. Patients who underwent a DC using either an LGK incision or a large RQM incision were enrolled. Patients were admitted to the emergency department in our institution between January 2019 and January 2020. Inclusion criteria included patients over 18 year old, with severe TBI, ICH, or subdural empyema with radiological signs of brain edema and evident clinical findings of intracranial hypertension. Radiological findings, including midline shift and subtle or noticeable signs of mass effect, including effacement of the ipsilateral lateral ventricle or effacement of the basal cisterns, were used to enroll patients into the study. Exclusion criteria included patients who underwent large craniotomies for brain tumor surgery and those with a severe TBI that underwent DC, where information was not complete for adequate characterization, or when the technical surgical features were not achieved, including a wide exposure in cases of trauma, where the first goal was the surgical draining of a subdural hematoma or where the primary goal of surgery was not treating mainly intracranial hypertension due to brain edema (e.g., epidural hematoma). Authorization was requested to our Institutional Ethics Board to include the information of the subjects in this study, preserving their identity both in the analysis of the information and in all images presented. This research was performed following the Declaration of Helsinki. This is a retrospectively analyzed study with approval by our Institutional Review Board.

Surgical procedure

All patients underwent a nonenhanced head CT scan, and those with ICH or subdural empyema underwent an enhanced CT scan whenever possible. A contralateral external ventricular drain (EVD) was placed in the same procedure, except for patients with subdural empyema. The patients were positioned supine, lateral-sided opposite to DC, with the head rotated 45° for adequate hemispheric exposure. For the Kempe's incision, the scalp was incised overlying the sagittal suture from the widow's peak to theinion with a "T-bar" extension. The incision was started 1–2 cm anterior to the tragus at the temporal root of the zygoma and extending superiorly to meet the midline sagittal incision approximately 1 cm behind the coronal suture [Figure 1]. Some variations in the "T-bar" meeting point depended on the location of the primary lesion (e.g., a parietal or posterior temporal ICH). Closure involved placing a stay "U" stitch at the apex of the wound with vicryl 2–0, followed by galea sutures with vicryl 2–0 and 3–0, and a skin suture avoiding crossing points at the "T" with prolene 3–0.

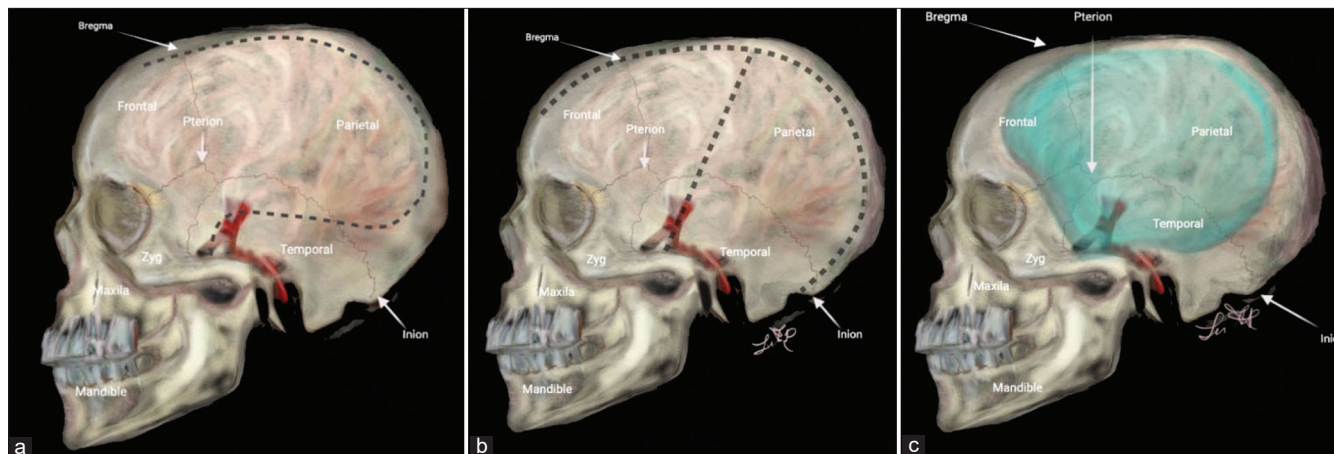


Figure 1: Illustration of L.G. Kempe's incision for a decompressive craniectomy. Dot lines demonstrate the (a) reverse question mark and (b) L.G. Kempe's incisions for adequate exposure of the bone landmarks. (c) The area for bone resection is demonstrated in aquamarine color.

On the other hand, the RQM scalp incision started 1 cm anterior to the tragus at the root of the zygoma, curving posteriorly above and behind the ear toward the asterion. The incision is gently curved around the parietal bone to the midline and directed to the widow's peak.^[7] The scalp is incised and reflected anteriorly as a myocutaneous flap of the scalp and temporalis muscle. We used four to five burr-holes, usually one frontal located anterior to the coronal suture, another in the pterional "key-hole," a posterior parietal, and a basal temporal. In addition, the craniotomy had an additional removal of the temporal bone until getting into the middle fossa floor to achieve a successful basal decompression. According to intraoperative findings, the decision to perform a DC or a hinge craniotomy was based on the surgeon's preference. If the bone flap was in good condition, it was sent for preservation in a special freezer under -30°C for further cranioplasty in TBI cases. Patients were transferred to the ICU afterward for complementary medical treatment.

RESULTS

A total of 27 patients underwent DC. Of those, ten patients met inclusion criteria and were enrolled, accordingly. The mean age was 42.1 years (26–71), and 50% were male. Five patients underwent DC using a large RQM incision; three had severe TBI, one ICH, and one ischemic stroke. The other five patients underwent DC using an LGK incision (two with severe TBI, one ICH, one subdural empyema, and one ischemic stroke) [Table 1]. About 50% of patients presented severe headaches associated with vomiting; six presented altered mental status (drowsy or stuporous). Motor deficits were present in four cases [Table 2]. Of the LGK group, only two patients underwent a hinge craniotomy. All patients in

the RQM group underwent a DC. All patients underwent an EVD, except from one patient with empyema in the LGK group. In patients who presented ischemic or hemorrhagic stroke, their symptoms were directly related to the stroke location. There were no intraoperative complications related to the procedure. No wound infections or dehiscence were registered in the postoperative follow-up. Hospital stays varied between 13 and 22 days. No readmissions were recorded, and no fatal outcome was documented during the follow-up.

ILLUSTRATIVE CASES

Case 1 – Intracranial hemorrhage

A 60-year-old male presented to the ED with a sudden loss of consciousness while drinking alcohol with his wife. The patient had a history of moderate alcohol consumption and nontreated hypertension. On his physical examination, he presented with a Glasgow Coma Scale (GCS) score of 13/15. He was drowsy, disoriented, and with left hemiparesis. The nonenhanced CT scan demonstrated a right temporoparietal ICH with significant mass effect and midline shift to the left [Figure 2]. The CT angiography showed no vascular malformations associated with the hemorrhage. The patient underwent a left 10×10 cm hinge craniotomy using a modified LGK incision to drain the hematoma. The patient had to be managed with deep sedation for 7 days after surgery due to a refractory status epilepticus due to persistent brain edema after the hematoma drainage. The patient recovered progressively until he was able to develop most of his daily activities. On the 1-year follow-up, the patient presented with a left hemianopsia, but the rest of his neurological examination was unremarkable.

Table 1: Clinical and demographic features.

Patient	Age	Gender	Diagnosis	Surgical Procedure	Scalp Incision
1	60	Male	Right temporoparietal ICH	Hinge craniotomy, ICH drainage, EVD	LGK
2	26	Male	Recurrent frontoparietal right subdural empyema	Hinge Craniotomy, subdural empyema drainage	LGK
3	39	Female	Right MCA ischemic stroke	Right DC, left EVD	LGK
4	43	Male	Severe TBI, acute SDH	DC, acute SDG drainage, left EVD	RQM
5	27	Male	Right temporal ICH	DC, ICH drainage, left EVD	RQM
6	71	Male	Severe TBI left acute frontal SDH	DC, acute SDH drainage, right EVD	RQM
7	42	Female	Severe TBI, left temporal contusion	DC, acute SDH drainage, right EVD	RQM
8	32	Male	Severe TBI, acute SDH	DC, acute SDH drainage, right EVD	LGK
9	34	Female	Severe TBI, acute SDH	DC, right EVD	LGK
10	47	Female	Right MCA ischemic stroke	DC, right EVD	RQM

DC: Decompressive craniectomy, EVD: External ventricular drain, ICH: Intracerebral hemorrhage, LGK: L.G. Kempe, MCA: Middle cerebral artery, RQM: Reverse question mark, SDH: Subdural hematoma

Case 2 – Subdural empyema

A 26-year-old male presented with an acute onset headache, confusion, and left hemiparesis after a suicidal attempt with coumarin (rat poison) consumption. The patient underwent drainage for a right subdural empyema through a right frontal burr hole. On postoperative day 3, the patient presented consciousness impairment with acute decline to a GCS score 7/15. A recurrent right 8.4 mm frontoparietal subdural empyema with a 4 mm midline shift to the left was detected in the postoperative nonenhanced CT scan [Figure 3]. Due to the extension of the empyema, the patient underwent a second procedure consisting of a large right hinge craniotomy through an LGK incision for the empyema drainage. In his 2-year follow-up on his physical examination, the patient remained only with a left 4+/5 hemiparesis, otherwise unremarkable.

Case 8 – Traumatic brain injury

A 32-year-old man presented to the emergency department after a car accident. No relevant clinical antecedents were present. The patient presented under sedation and on his physical examination presented a GCS score of 8/15, with a Richmond Agitation Sedation Scale of -3. Brainstem reflexes were present, and the left pupil was 5 mm and fixed. The CT scan revealed a left acute subdural hematoma with a midline shift to the right and effacement of the basal cisterns [Figure 4]. The patient underwent a left 12 × 15 cm DC using a Kempe’s incision and drainage of the subdural hematoma and the placement of a right EVD. The patient was discharged on postoperative day 10 and recovered uneventfully 3 months after the procedure. The 6-month follow-up was unremarkable. After 9-months after surgery, an autologous cranioplasty was performed uneventfully.

Case 10 – Ischemic stroke

A 39-year-old woman presented with acute onset of dysarthria, ataxia, emesis, and headaches. She developed a status epilepticus after hospital admission. The CT scan showed a large left middle cerebral artery ischemic stroke [Figure 5]. Consequently, the patient underwent a left DC through an LGK incision and a right-sided EVD placement. The patient remained with altered consciousness and was transferred to a chronic care unit after a 2-month hospital-stay period.

DISCUSSION

Our study describes additional applications for the LGK incision. Some of the pathologies include empyema, intracranial hemorrhage, and ischemic strokes, considering the common pathophysiologic background of all of them: an increased ICP. Both techniques, RQM and LGK incisions, could be performed similarly to treat different entities. It is essential to consider that neurological prognosis depends directly on the severity and location of the injury. The direct decrease in ICP may improve overall survival for all pathologies in the same way that it has been described for TBI previously.^[4] However, the decision-making to perform a DC must consider the risk of moderate-to-severe neurological sequelae, including persistent disorders of consciousness (DOC) depending on the extension of the primary injury. Information regarding DC indications and recommendations as well as incision’s discussions is presented in Table 3. To analyze and resume data for each pathology treated in our series, all different etiologies are discussed below.

CD has been previously used for ischemic strokes.^[13] In a review performed by Hossain-Ibrahim *et al.*, the findings were inconclusive of the use of craniectomy for middle cerebral artery strokes. However, they suggest an improvement in

Table 2: Clinical presentation and radiological findings.

Patient	Clinical presentation	Preoperative neurological examination	Scans performed preoperatively	Intracranial Imaging Findings	Glasgow Outcome Scale Extended
1	Headache, vomiting, drowsiness	GCS score 13/15, drowsy, disoriented, left hemiparesis	Non-enhanced CT	Right temporoparietal ICH with a volume of 67 cc, 11 mm midline shift, effacement of basal cisterns.	7
2	Headache, disorientation, left hemiparesis	GCS score 14/15, disoriented, left hemiparesis, fever	Non-enhanced CT	Right 9 cc frontoparietal subdural empyema with a diameter of 8.4 mm. Effacement of subarachnoid space with 4 mm midline shift.	6
3	Dysarthria, astasis, vomiting, headache	GCS score 9/15, developing an epileptic status	Non-enhanced CT	Left MCA ischemic stroke with volume 195 cc and no initial midline shift. Progressive midline shift 6 due to malignant edema.	3
4	Headache, vomiting, seizures, altered mental status	Initial GCS score 15/15. Progressive decline to 13/15, drowsy, and developing an epileptic status.	Non-enhanced CT	L8 aminar acute frontal right SDH, right EDH 14 mm, 9 mm right contusion, diffuse brain edema, and a 7.14 mm midline shift, with basal cisterns effacement.	6
5	Headache, vomiting, seizures, left hemiparesis, altered mental status	GCS score 11/15, generalized seizure, drowsy, incoherent language, CN III paresis, left hemiparesis, left central facial paresis.	Nonenhanced CT, CTA	Right parietal ICH with a volume of 52 cc, midbrain compression, 3 mm midline shift, effacement of basal cisterns, and diffuse hemispheric brain edema. CTA without spot signs and negative for vascular malformations but an increase in the hematoma volume.	8
6	Headache, vomiting, disorientation, transitory altered mental status	No deficit observed	Nonenhanced CT	Right frontal laminar acute SDH, 5 mm midline shift, right frontal contusion, left temporal contusion, traumatic SAH Greene I.	6
7	Under sedation	Initial GCS score 13/15, deterioration to 10/15.	Non-enhanced CT	Left temporal contusion 4 cc, left SDH with a 6.5 mm diameter, hemispheric brain edema with basal cisterns effacement. 1 mm midline shift.	6
8	Under sedation	GCS score 10/15, somnolent, unintelligible speech, localizing pain, symmetric extremities movement	Non-enhanced CT	Left acute subdural hematoma 9 mm thick, 7 mm midline shift, subfalcine herniation, and 5 frontal edema	4
9	Stupor after mechanical thromboembolctomy	GCS 8/15, stupor, right hemiparesis, withdrawal from pain, inappropriate words.	Non-enhanced CT	Hypodense image within M1 with no opacification ahead in CECT, associated with a frontotemporoparietal cytotoxic edema and hemorrhagic transformation with a 15 mm midline shift.	5
510	Under sedation	GCS 3/15 under sedation RASS 15, isochoric.	Nonenhanced CT	Right no displaced occipital fracture, 12 mm thick hemispheric subdural hematoma, 10 mm midline shift, frontotemporal left contusions, traumatic SAH	2

CT: Computed tomography, CTA: Computed tomography angiography, GCS: Glasgow coma scale, ICH: Intracranial hemorrhage, SAH: Subarachnoid hemorrhage, RASS: Richmond Agitation Sedation Scale

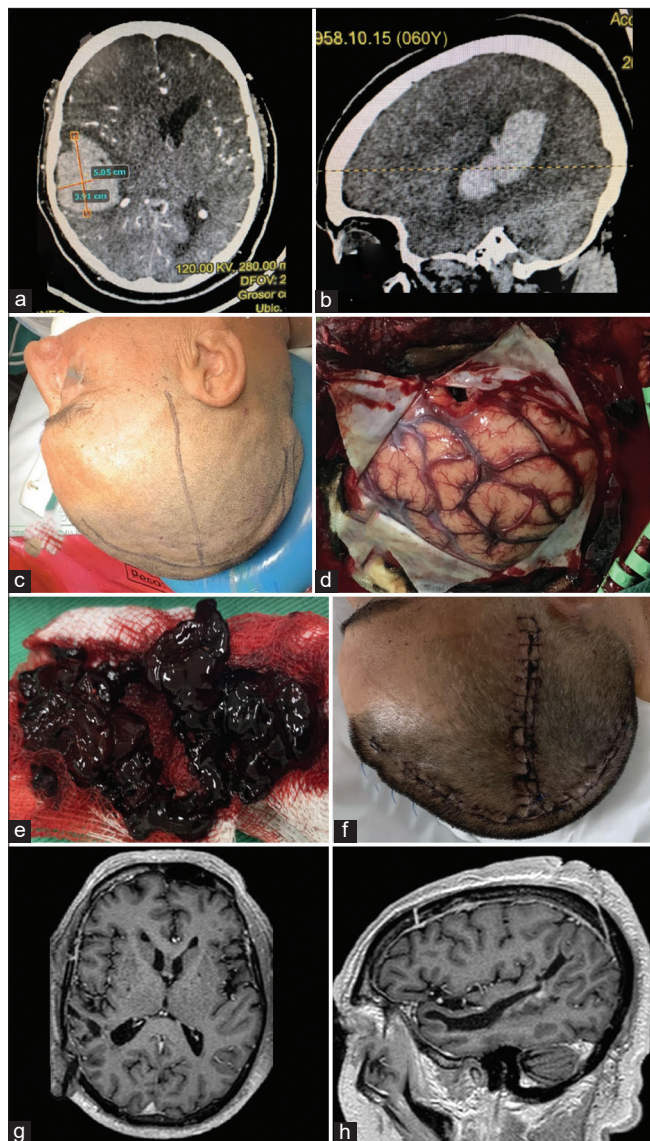


Figure 2: Intracranial Hemorrhage. (a and b) Preoperative enhanced CT scan of the head demonstrating a large intraparenchymal hemorrhage with significant mass effect and secondary midline shift to the left. No extravasation after contrast administration was noticed. (c) Preoperative scalp marking (d) brain exposure. A small corticectomy in the most basal aspect of the brain exposure is demonstrated. (e) The drained clot counted for approximately 5 cm³ volume is observed. (f) Postoperative picture of the inverted T-bar incision without evidence of dehiscence. (g and h) 1-year follow-up postoperative post contrast axial and sagittal T1 images.

malignant strokes, particularly in young patients.^[8] Moscote-Salazar *et al.* exemplify the use of an extensive craniectomy for refractory intracranial hypertension. In their study, they recommend the use of the RQM or LGK incisions equally.^[13] In this study, one case was performed using the RQM and the other with an LGK incision. No differences were noted between the interventions. In terms of prognosis, intrinsic pathologies of the patient can contribute to a worse

outcome. In our series, a good example was the hemorrhagic transformation of the ischemic stroke presented in Case 10, which could be associated with the poor medium-term prognosis of the patient, who remained with a persistent DOC.

A different indication for decompression is the subdural empyema. Subdural empyema is a collection of purulent material between the dura and the arachnoid. It is a life-threatening entity that is generally associated with paranasal sinusitis, otitis media, or mastoiditis.^[1] The treatment includes immediate surgical evacuation through a burr-hole or craniotomy. Nathoo *et al.* provided a database from 1982 to 1997 that suggests craniotomy as the surgical procedure of choice as treatment in this pathology. The main argument was that performing a craniotomy allows a complete evacuation of the pus, and more importantly, decompresses the underlying cerebral hemisphere.^[14] More case reports have been conducted showing the benefits of continuous irrigation and antibiotic therapy.^[12] Most interventions have been performed with an RQM incision, without much more information comparing the RQM with LGK. In our case, we performed that an LGK incision successfully performed for the craniotomy, without infection of the bone, comparable with the same procedure made by an RQM incision. No dehiscence was evident, and the resolution of the empyema was complete. Given the prior drainage through a burr hole, this case corroborates the preference of performing a wide craniotomy at first.

In the setting of epilepsy, the requirement for extensive hemispherectomies makes mandatory the use of a wide craniotomy. An example of this is an old work published in 1995 by Peacock *et al.* In that work, all cases were performed using an LGK incision, having successful results; however, they did not compare the incision with other techniques. They reported that only three patients had a mild neuro infection, which was easily controlled with antibiotics.^[16] In our study, there were no cases with acute edema related to aggressive primary epilepsy. These scenarios are infrequent but would be amenable for treatment with DC as a rescue option.

Conventionally, DC has been widely used for patients with intracranial hypertension after severe DTI and most published series have performed RQM for this purpose. L.G. Kempe made the first description of a “T-shaped” incision.^[10,11] In 2010, Ragel *et al.* published the most remarkable work regarding the LGK incision for trauma. This work compared the experience of 90 craniotomies during October 2007–September 2009 in the Afghanistan and Iraq conflicts.^[17] During this time, they performed DC to safely transfer neurologically ill patients to tertiary military hospitals, which could be located 8–18 h from the war zone. Compared with the RQM, which is subject to

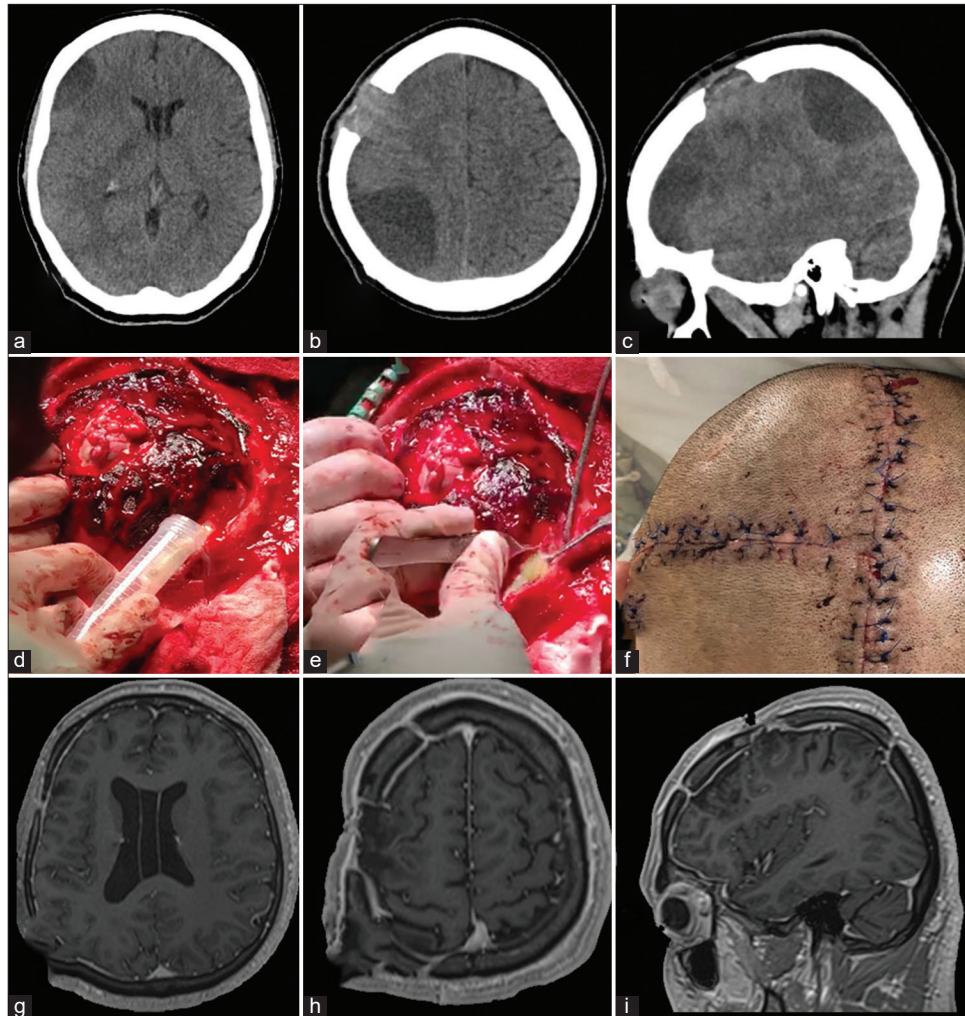


Figure 3: Subdural empyema. (a-c) Non-enhanced CT scan demonstrates a recurrent subdural empyema with separate extension to the right frontal and parietal lobes. (d-e) Intraoperative images show the purulent collection drainage, remarkable brain edema, and epidural bleeding. (f) A postoperative picture of the T-bar incision is demonstrated. (g-i) One-year follow-up enhanced MRI of the head shows no recurrent empyema. (g-h) One-year postoperative MRI with gadolinium administration showed encephalomalacia with the recovery of the normal position of the frontal and temporal lobes.

dependent swelling and followed by necrosis, LGK incision was favored in their study. Long-term experience showed less posterior wound breakdown with LGK incision as well as less temporalis muscle atrophy as well as an easier exposure for further cranioplasty. In addition, in cases, where there is a need to perform a second contralateral DC, this incision is ideal for its exposure.^[17] In 2019, a multicenter experience-based study demonstrated treatment for damage control in neurotrauma with low-resources and austere environments. The study showed the advantage of LGK incision in terms of reducing the risk of flap necrosis. In addition, this incision suggested the benefit when long-distance transportation is required in low-income areas, and there is an increased risk of a bilateral injury. For these cases, a modified LGK incision (C-shaped) was recommended.^[18]

In 2019, Rubiano *et al.* published a narrative review about the evolution of the damage control concept in neurotrauma in low- to middle-income countries or areas with limited resources. This review focused on the utility of different incision techniques. The authors highlighted the use of the LGK technique to achieve greater access for a wider craniectomy that could be advanced to a bilateral procedure, particularly in the scenario of a blast traumatic injury. In addition, they concluded that, in cases, where long-distance travel is anticipated, the T-shaped incision has the advantage in terms of preserving the superficial temporal and occipital arteries, reducing the flap necrosis, and improving the wound healing.^[18] Indeed, these two advantages are well to consider in many Latin-American countries, where transportation to a specialized trauma center could take several hours.^[2] In our

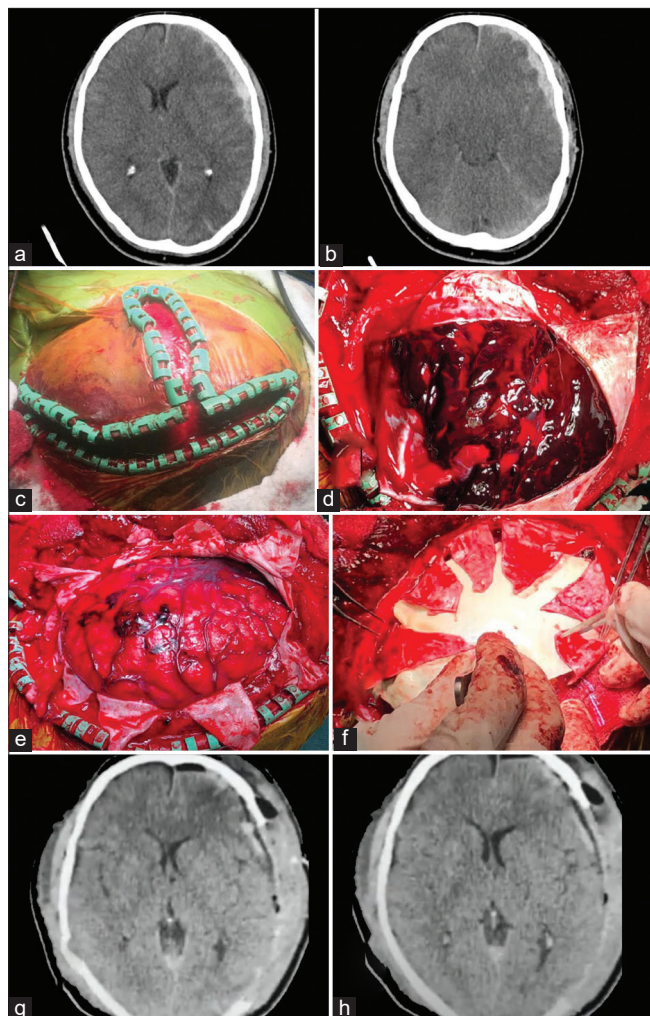


Figure 4: L.G. Kempe's incision for trauma. (a and b) A preoperative CT scan demonstrates a left acute subdural hematoma with mass effect and a midline shift to the right with effacement of the basal cisterns. (c-f) An inverted "T-bar" incision is demonstrated, with consequent drainage of the hematoma and duroplasty. (g-h) Postoperative CT scan shows complete drainage of the hematoma, recovery of the midline, and the cranial defect in the left parietotemporal cranial vault.

series, we have demonstrated satisfactory results using both techniques for trauma. No changes were detected in those cases and implementation of each technique remains on the neurosurgeon's preference.

In regard to cosmetic outcomes, in 2020, Safari *et al.* evaluated the differences between both incision techniques for large craniotomies. In this study, 23 patients were followed for 6 months postoperatively. Their evaluation included aesthetic aspects assessed by the Stony Brook Scar Evaluation Scale (SBSES), which describes a qualitative subjective perspective from the patients about their scars. Based on the postoperative hair follicle density changes, either group showed any difference ($P = 0.657$), and the difference

between the SBSES significantly favored the T-shaped incision ($P = 0.005$).^[19] This variable needs to be further studied in patients after complete defect reconstruction. This aspect was not evaluated in our patients. However, no objective differences were noted for muscle atrophy or other features like changes in hair follicle density in the middle-term follow-up.

The literature is variable in regard of surgical complications. An old problem with the Kempe's incision is the necrosis in the intersections of the T-section.^[21] In this study, we describe two cases, in which the LGK incision was used and partial suffering of the borders of the wound was noted but had no further dehiscence or infection associated to the compromised areas. Middle-term follow-up demonstrated no complications associated to this matter. The suffering of the skin could be associated to the tension forces related to the incision's shape. No complications were noted to the posterior aspect of the RQM incision either. The authors recommend avoiding prolonged periods, where the intersection of the T-Section will be exposed to elevated pressures due to the head's position, even after complete wound healing. In addition, we evidenced no other complications in the RQM group. Despite most of DC in our institution were traditionally performed using a RQM incision, in the last decade, the need to improve the times for decompression has allowed a transition to the LKG technique and, therefore, has also transformed our practice. The rapid surgical learning curve has significantly changed the preference of the attending surgeons, given the safety, and rapid approach of this technique. The early satisfactory results have demonstrated the utility to perform adequately DC in different scenarios, without increasing complications associated to the procedure.

Limitations

The availability of information related to the LGK incision for other pathologies rather than TBI increases the bias at the time of objective evaluation. However, in the different settings reported, including bilateral lesions, empyema, malignant strokes, intracranial hemorrhages, and even in cosmetic outcomes, the T-shaped incision exceeded the expectations over the classic RQM. This study did not evaluate the times needed to complete the craniectomy neither for closure. However, it seems that LGK incision could be faster to complete the decompression but longer for skin closure. Certainly, further studies are required to scrutinize potential uses and differences between both techniques.

CONCLUSION

The utility of LGK T-shaped incision seems to be comparable with the traditional RQM incision to treat traumatic injuries

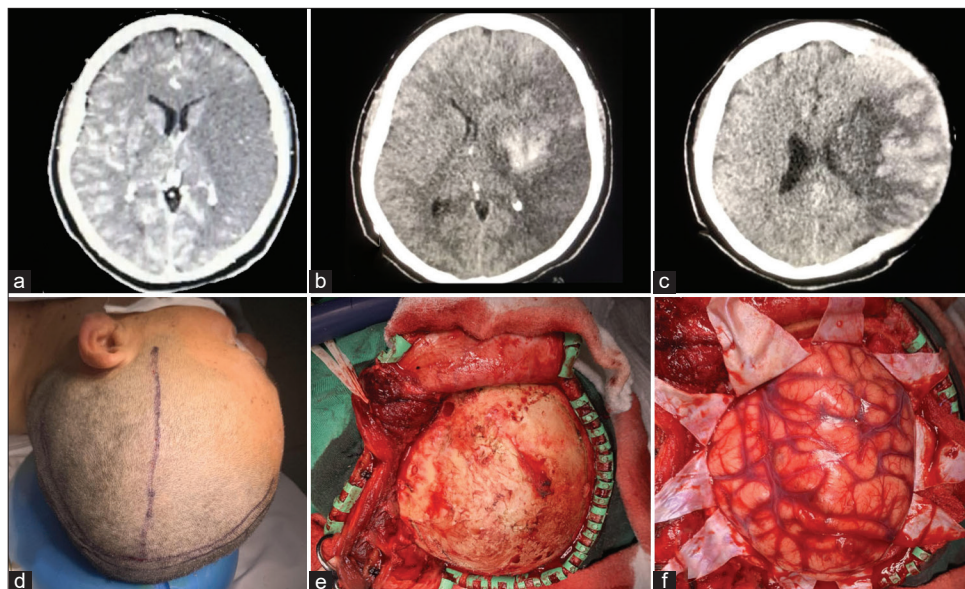


Figure 5: Decompressive craniectomy for ischemic stroke. (a) Admission-enhanced CT scan of the head demonstrates a large left middle cerebral artery infarction. (b) Two-hour admission nonenhanced CT scan shows hemorrhagic transformation of the stroke with significant edema and midline shift to the right. (c) Postoperative CT scan demonstrates recovery of the midline and transcranial herniation of the infarcted parenchyma. (d) Skin marking with a T-shaped Kemp's mark. (e) Bone exposure. In this picture, the inferior displacement of the temporal muscle allows adequate exposure of the cranium. (f) After opening the dura mater, significant edema was evident.

Table 3: Case series of decompressive craniectomy results according to etiology.

Case Series	Etiology	Results/Conclusions
Hossain-Ibrahim <i>et al.</i> ^[8]	Stroke	Suggest an improvement in malignant strokes. No comments were made comparing incisions
Moscote-Salazar <i>et al.</i> ^[13]	Stroke and intracranial hemorrhage	Recommend the use of the RQM or LGK incisions equally. No differences were noted between the interventions
Nathoo <i>et al.</i> ^[14]	Empyema	Suggests craniotomy as the surgical procedure of choice as treatment in this pathology. No comments were made about incision
Lee <i>et al.</i> ^[12]	Empyema	Benefits of continuous irrigation and antibiotic therapy. No comments were made comparing incisions
Peacock <i>et al.</i> ^[16]	Epilepsy	LGK incision with successful results; not comparison the incision with other technique
Ragel <i>et al.</i> ^[17]	Trauma	War wounds – less posterior wound breakdown with LGK incision and less temporalis muscle atrophy, as well as an easier exposure for further cranioplasty compared to RQM
Rubiano <i>et al.</i> ^[18]	Trauma	Benefit LGK incision in terms of reducing the risk of flap necrosis
Rubiano <i>et al.</i> ^[18]	Damage control in areas with limited resources	LGK technique to achieve greater access for a wider craniectomy – preserving the superficial temporal and occipital arteries, reducing the flap necrosis and improving the wound healing.
Safari <i>et al.</i> ^[19]	Cosmetic outcomes	Advantage in transportation to a specialized trauma center Stony Brook Scar Evaluation Scale significantly favored the LGK incision
Veldeman <i>et al.</i> ^[21]	Stroke, hemorrhage, and trauma	The LGK incision was abandoned before the study due to frequent wound healing problems at the intersection of both linear incisions.

LGK: L. G. Kemp's, RQM: reverse question mark

and other pathologies, where an urgent decompression should be performed, including malignant ischemic strokes, ICH, and empyema. In terms of prevention of scalp necrosis and general cosmetic outcomes, no differences were found. Finally, the decision whether to use either technique should be performed based on a case-by-case manner as well as on the neurosurgeon's preference and experience to provide the best option for each patient.

Declaration of patient consent

Institutional Review Board (IRB) permission obtained for the study.

Financial support and sponsorship

Nil.

Conflicts of interest

There are no conflicts of interest.

REFERENCES

1. Agrawal A, Timothy J, Pandit L, Shetty L, Shetty J. A review of subdural empyema and its management. *Infect Dis Clin Pract* 2007;15:149-53.
2. Becerra JM, Reis RS, Frank LD, Ramirez-Marrero FA, Welle B, Arriaga Cordero E, *et al.* Transport and health: A look at three Latin American cities. *Cad Saude Publica* 2013;29:654-66.
3. Bor-Seng-Shu E, Figueiredo EG, Amorim RL, Teixeira MJ, Valbuza JS, de Oliveira MM, *et al.* Decompressive craniectomy: A meta-analysis of influences on intracranial pressure and cerebral perfusion pressure in the treatment of traumatic brain injury. *J Neurosurg* 2012;117:589-96.
4. Carney N, Totten AM, O'Reilly C, Ullman JS, Hawryluk GW, Bell MJ, *et al.* Guidelines for the management of severe traumatic brain injury, fourth edition. *Neurosurgery* 2017;80:6-15.
5. Cushing H. I. Subtemporal decompressive operations for the intracranial complications associated with bursting fractures of the skull. *Ann Surg* 1908;47:641-644.1.
6. Dunn LT. Raised intracranial pressure. *J Neurol Neurosurg Psychiatry* 2002;73 Suppl 1:i23-7.
7. Eberle BM, Schnüriger B, Inaba K, Gruen JP, Demetriades D, Belzberg H. Decompressive craniectomy: Surgical control of traumatic intracranial hypertension may improve outcome. *Injury* 2010;41:894-8.
8. Hossain-Ibrahim M, Tarnaris A, Wasserberg J. Decompressive craniectomy friend or foe? *Trauma* 2012;14:16-38.
9. Kempe LG. Hemispherectomy. *Oper Neurosurg* 1968;1:179-89.
10. Kobrine AI, Kempe LG. Studies in head injury. I. An experimental model of closed head injury. *Surg Neurol* 1973;1:34-7.
11. Kobrine AI, Kempe LG. Studies in head injury. II. Effect of dexamethasone on traumatic brain swelling. *Surg Neurol* 1973;1:38-42.
12. Lee OE, Patiño-Ladino S. Decompressive craniectomy for empyema by *Aggregatibacter aphrophilus*: Literature review and case report. *Univ Med* 2019;60:86-95.
13. Moscote-Salazar LR, Alvis-Miranda HRL, Ramos-Villegas Y, Quintana-Pajaro L, Rubiano AM, Alcalá-Cerra G, *et al.* Refractory traumatic intracranial hypertension: The role of decompressive craniectomy. *Cir Cir* 2019;87:358-64.
14. Nathoo N, Nadvi SS, Gouws E, van Dellen JR. Craniotomy improves outcomes for cranial subdural empyemas: Computed tomography-era experience with 699 patients. *Neurosurgery* 2001;49:872-7.
15. Pallesen LP, Barlinn K, Puetz V. Role of decompressive craniectomy in ischemic stroke. *Front Neurol* 2018;9:1119.
16. Peacock WJ, Wehby-Grant MC, Shields WD, Shewmon DA, Chugani HT, Sankar R, *et al.* Hemispherectomy for intractable seizures in children: A report of 58 cases. *Childs Nerv Syst* 1996;12:376-84.
17. Ragel BT, Klimo P Jr., Martin JE, Teff RJ, Bakken HE, Armonda RA. Wartime decompressive craniectomy: Technique and lessons learned. *Neurosurg Focus* 2010;28:E2.
18. Rubiano AM, Maldonado M, Montenegro J, Restrepo CM, Khan AA, Monteiro R, *et al.* The evolving concept of damage control in neurotrauma: Application of military protocols in civilian settings with limited resources. *World Neurosurg* 2019;125:e82-93.
19. Safari H, Bagher S, Halili BA. Cosmetic outcomes of scalp in standard reverse question mark incision and L.G. Kempe incision in large craniotomies. *Iran J Neurosurg* 2020;6:203-10.
20. Schirmer CM, Ackil AA Jr., Malek AM. Decompressive craniectomy. *Neurocrit Care* 2008;8:456-70.
21. Veldeman M, Daleiden L, Hamou H, Höllig A, Clusmann H. An altered posterior question-mark incision is associated with a reduced infection rate of cranioplasty after decompressive hemicraniectomy. *J Neurosurg* 2020;134:1262-70.
22. Wada Y, Kubo T, Asano T, Senda N, Isono M, Kobayashi H. Fulminant subdural empyema treated with a wide decompressive craniectomy and continuous irrigation case report. *Neurol Med Chir (Tokyo)* 2002;42:414-6.
23. Xi G, Keep RF, Hoff JT. Pathophysiology of brain edema formation. *Neurosurg Clin N Am* 2002;13:371-83.

How to cite this article: Ordóñez-Rubiano EG, Figueredo LF, Gamboa-Oñate CA, Kehayov I, Rengifo-Hipus JA, Romero-Castillo IJ, *et al.* The reverse question mark and L.G. Kempe incisions for decompressive craniectomy: A case series and narrative review of the literature. *Surg Neurol Int* 2022;13:295.