

# A Primer for Pediatric Emergency Front-of-the-Neck Access

Joana Berger-Estilita, MD, MMed, Vivian Wenzel, MD, Markus M. Luedi, MD, MBA, and Thomas Riva, MD

“Cannot intubate, cannot oxygenate” situations in healthy children are uncommon but are often associated with poor outcomes. Clinical assessment, anticipatory planning, and the use of algorithms can lessen the likelihood of untoward outcomes, but the common final pathway of many algorithms for a difficult pediatric airway involves obtaining emergency tracheal access. The airway practitioner must have the know-how and training needed to invasively secure the airway when confronted with this rare but potentially devastating emergency. We provide practitioners with an overview of pediatric emergency front-of-the-neck access strategies and a structure for their management. (A&A Practice. 2021;15:e01444.)

## GLOSSARY

**CICO** = cannot intubate, cannot oxygenate; **ECMO** = extracorporeal membrane oxygenation; **FONA** = front-of-the-neck access; **IV** = intravenous

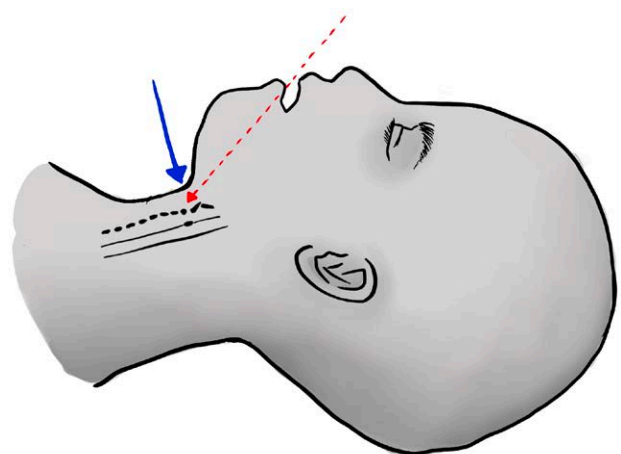
The incidence of difficult pediatric airway is 0.28%,<sup>1</sup> and 2% of these children require a surgical airway.<sup>2</sup> Although rare in healthy children, “cannot intubate, cannot oxygenate” (CICO) situations are closely associated with poor outcomes.<sup>3</sup> Algorithms emphasize the early recognition and treatment of functional and anatomical airway obstructions and the use of apneic oxygenation<sup>4</sup> during airway instrumentation. Furthermore, they recommend limiting the number of laryngoscopies and encourage early progression to advanced intubation techniques.<sup>2</sup> These approaches may eliminate the need for an invasive airway. However, in CICO scenarios, unplanned front-of-the-neck access (FONA) may present as the only life-saving option.

Nevertheless, specific instructions for performing FONA techniques are not usually included in algorithms. Because FONA indications are extremely rare and several FONA approaches are described in the literature, justifiable safety concerns can be raised. Currently, there is no evidence favoring a particular technique, and the existing studies are based on low case numbers. In this educational tool, we offer pediatric airway practitioners a structure for the management of this rare emergency.

## AIRWAY ANATOMY IN CHILDREN AND CURRENT GUIDELINES

Pediatric airways are characterized by elasticity and compressibility, making them challenging to access in an invasive approach, particularly in very young children (Figure 1). In very young children, the relationship between the mandible and the trachea—even with maximal extension of the head and neck—permits successful puncture of the cricothyroid membrane only at a very steep angle (Figure 1). A percutaneous technique can result in tracheal compression and posterior wall perforation, while surgical cricothyroidotomy is discouraged due to the risk of fracturing the laryngeal cartilage.<sup>5</sup> In neonates, the outer diameter of the smallest available tracheal tube exceeds the longitudinal dimensions of the cricothyroid membrane.

In a CICO situation for children aged 1–8 years, guidelines<sup>6</sup> recommend either a surgical tracheotomy if a trained otolaryngologist is available or a percutaneous



**Figure 1.** Model of the percutaneous approach in young children. The red dotted arrow shows the ideal angle for puncturing the cricothyroid membrane with a percutaneous cannula. The blue arrow illustrates that, despite neck extension, the angle for safe percutaneous cricothyroidotomy is not optimal in young children.

From the Department of Anaesthesiology and Pain Medicine, Inselspital, Bern University Hospital, University of Bern, Bern, Switzerland.

Accepted for publication February 19, 2021.

Funding: None.

The authors declare no conflicts of interest.

Supplemental digital content is available for this article. Direct URL citations are provided in the HTML and PDF versions of this article on the journal's website ([www.cases-anesthesia-analgesia.org](http://www.cases-anesthesia-analgesia.org)).

Address correspondence to Joana Berger-Estilita, MD, MMed, Department of Anaesthesiology and Pain Medicine, Inselspital, Bern University Hospital, University of Bern, Freiburgstrasse, 3010 Bern, Switzerland. Address e-mail to [joana.berger-estilita@insel.ch](mailto:joana.berger-estilita@insel.ch).

Copyright © 2021 The Author(s). Published by Wolters Kluwer Health, Inc. on behalf of the International Anesthesia Research Society. This is an open-access article distributed under the terms of the Creative Commons Attribution-Non Commercial-No Derivatives License 4.0 (CCBY-NC-ND), where it is permissible to download and share the work provided it is properly cited. The work cannot be changed in any way or used commercially without permission from the journal.

DOI: 10.1213/XAA.0000000000001444

cricothyroidotomy. However, the vast majority of airway emergencies leading to a CICO crisis occur in children <1 year,<sup>7</sup> limiting the usefulness of this guideline. For these infants, there is no evidence for the best approach to perform FONA and no consensus regarding the preferred transtracheal route.<sup>6</sup>

In a pediatric CICO crisis, the options to rescue the airway are limited to rigid bronchoscopy or FONA. When FONA is required, options include surgical or cannula cricothyroidotomy and surgical tracheotomy (Table). In special cases, the preemptive use of extracorporeal membrane

oxygenation (ECMO) may represent an effective alternative in an anticipated difficult airway.<sup>7</sup>

### TIME TO TRACHEAL ACCESS AND SUCCESS RATE OF DIFFERENT FONA APPROACHES IN ANIMAL MODELS

Five different techniques are available to access the trachea (Table). Metterlein et al<sup>8</sup> analyzed the catheter-over-needle technique and reported an overall success rate of <50%, with a mean time to tracheal access of 44 seconds. Prunty et al<sup>9</sup> reported a 100% success rate with a wire-guided

**Table. Descriptions of the Different Techniques and Equipment That Can Be Used in a CICO Crisis, Along With Their Advantages (+), Disadvantages (-), and Potential Complications**

FONA Technique	Advantages (+)/disadvantages (-)	Complications
<b>Percutaneous techniques</b>		
Catheter-over-needle: insertion of a plastic cannula over a metal needle for direct access to the trachea <sup>a</sup>	No excessive force is needed because of the small, sharp needle (+) Limited trauma to the tissue <sup>8</sup> (+)  The set is ready to use (+) Quick access to the trachea with 1 hand movement (+) The “stopper” in Quicktrach baby I <sup>b</sup> prevents posterior tracheal wall perforation (+) Not usable in children under 8 y (-) Easy if trained in the Seldinger technique (+) The Melker Emergency Cricothyroidotomy Catheter Set <sup>d</sup> contains an uncuffed airway catheter in different sizes (+) Puncture with needle followed by insertion of a guidewire (-) Not usable in children under 8 y (-) Experience with the Seldinger technique is needed (-) The wire is not kink-resistant, and the dilator is not fixed to the cannula (-)	Bleeding  Lateral and posterior laryngeal and tracheal wall injuries Fracture of the laryngeal cartilage Risk of pre- or retrotracheal placement <sup>8-11</sup>
Wire-guided cricothyroidotomy (Seldinger): wire insertion through a metal needle or a plastic cannula, and placement of a tracheotomy tube with a dilator over the wire <sup>c</sup>	Easy if trained in the Seldinger technique (+) The Melker Emergency Cricothyroidotomy Catheter Set <sup>d</sup> contains an uncuffed airway catheter in different sizes (+) Puncture with needle followed by insertion of a guidewire (-) Not usable in children under 8 y (-) Experience with the Seldinger technique is needed (-) The wire is not kink-resistant, and the dilator is not fixed to the cannula (-)	
Transtracheal cannula: tracheal puncture distal to the cricoid cartilage at an angle of 45° caudally, with cannula insertion over the needle. A jet ventilation catheter for children or an IV catheter (14, 16, or 18 gauge) is suitable <sup>10,11</sup>	No complex equipment is required (+) Easy kinking of a thin cannula <sup>10</sup> (-) Temporary measure for oxygenation with modified jet ventilation (using the Venturi effect) <sup>10</sup> (-)	Jet ventilation poses risks of pneumothorax, subcutaneous emphysema, air embolism, or damage to the esophagus, <sup>10</sup> in case of cannula misplacement
<b>Surgical techniques</b>		
Emergency tracheotomy: vertical midline skin incision with a curved scalpel blade, muscle separation with 2 Backhaus towel clamps, exposure of the cricoids, and the trachea by tracheal anterior luxation with a third clamp. Then, a vertical tracheal incision between the cricoid cartilage and the first tracheal ring with sharp-pointed scissors is performed, along with an incision of the first 2 tracheal rings, and the endotracheal placement of a tracheal tube. The technique is performed with a self-assembled clinical tracheotomy set	No complex equipment is required for children under 8 y (+)  Lower risk of severe complications in comparison with percutaneous techniques (+) Risk of incision of more than 2 tracheal rings (-)	Risk of bleeding due to larger skin and subcutaneous tissue incisions in comparison with percutaneous techniques Injuries of the thyroid gland or the trachea Risk of tracheal injury (immediate) and tracheal stenosis (late) if more than 2 tracheal rings are incised.
Cricothyroidotomy with a scalpel bougie: palpation of the cricothyroid membrane, transverse skin, and cricothyroid membrane incision with the scalpel, 90° rotation of the scalpel, insertion of the bougie into the airway using the scalpel blade as a guide, and insertion of a tracheal tube via the bougie <sup>e</sup>	Fast access to the trachea due to fewer steps (+) Lower risk of severe complications in comparison with percutaneous techniques (+) Not usable in children under 8 y (-)	

Abbreviations: CICO, cannot intubate, cannot oxygenate; IV, intravenous.

<sup>a</sup>Commercially available device: Quicktrach baby I (VMB Medizintechnik GmbH, Sulz, Germany) (ID 1.2).

<sup>b</sup>VMB Medizintechnik GmbH.

<sup>c</sup>Commercially available device: Melker emergency cricothyroidotomy catheter set (Cook Medical, IN) (ID 3.5, 4.0, and 6.0).

<sup>d</sup>Cook Medical.

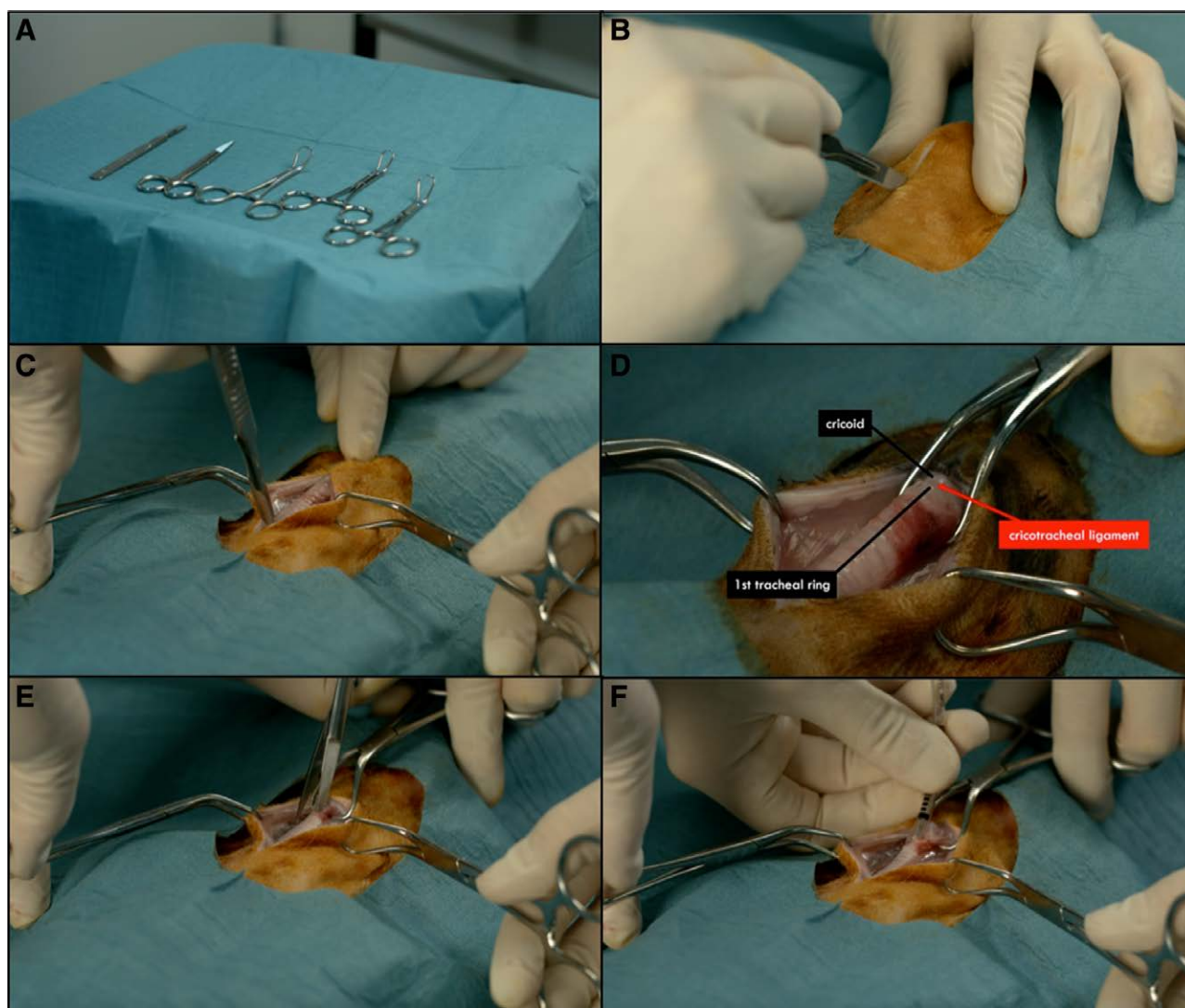
<sup>e</sup>Frova intubating introducer (Cook Medical, Bloomington, IN) or a commercially available device, ie, North American Rescue Tracheotomy Kit with Bougie-Introducer (North American Rescue LLC, Greer, SC) (ID 6).

cricothyroidotomy. However, the complications of this technique include fractures of the laryngeal cartilage (20%) and posterior tracheal wall injuries (13%), and no report has described the time to tracheal access. The success rate using a transtracheal cannula was reported to be between 65.6% and 68.8%.<sup>10</sup> The scalpel bougie technique showed an overall success rate of 75%,<sup>9</sup> while emergency tracheotomy was deemed successful in 94% of the cases.<sup>10</sup> Both techniques were performed in under 1 minute.

Obtaining emergency access to the pediatric airway poses considerable risks of complications. The lowest rate of complications was reported by Ulmer et al,<sup>13</sup> who noted a 17% rate of failure or severe injuries. Other pediatric FONA techniques showed higher complication rates, including the wire-guided technique (69%),<sup>9</sup> the cannula technique (36%),<sup>11,14</sup> the catheter-over-needle technique (33%),<sup>8</sup> and the scalpel technique (38%).<sup>9,11</sup>

The current literature provides equivocal guidance on performing FONA as a life-saving measure for children 8 years or younger.<sup>6</sup> In this patient population, a surgical tracheotomy is preferred. In children older than 8 years, the size of the cricothyroid membrane permits a cricothyroidotomy. Although evidence from animal models<sup>9</sup> appears to show a 100% success rate with percutaneous cricothyroidotomy, data from CICO situations in adults<sup>15</sup> and existing pediatric case reports favor surgical access, which is commonly adopted after unsuccessful percutaneous cricothyroidotomies.

However, it is unclear whether the results obtained from studies with animal models can be applied to guidelines addressing pediatric CICO situations. The low incidence and the heterogeneity of health care practitioner experiences in this regard limit the comparison of success rates. Moreover, the realization of much-needed studies is



**Figure 2.** The 5 key steps for performing emergency tracheotomy using a self-assembled clinical tracheotomy set with a 10-curved scalpel blade, 3 Backhaus towel clamps, and sharp-pointed scissors (A). The picture(s) and the video show the ventral shaved part of a rabbit cadaver obtained as waste product from the food industry (high-volume butchery). No live animals were used for that manuscript and no animals were killed for performing the tracheostomies. Orientation by palpating the neck, vertical midline incision (B), separation of the muscles using 2 Backhaus towel clamps and exposure of the trachea and cricoid by tracheal anterior luxation with a third clamp (C, D), tracheal incision, with the scissor placed perpendicularly, between the cricoid cartilage and the first tracheal ring with sharp-pointed scissors, avoiding the incision of more than 2 tracheal rings (E), and placement of an appropriately sized endotracheal tube (F).

impeded by ethical concerns pertaining to children. Based on current knowledge, no single technique can be deemed superior to the others. However, data in pediatric and adult patients seem to show that surgical techniques offer a higher rate of success in combination with a lower risk of severe complications.

Percutaneous access is sometimes recommended in pediatric CICO crisis algorithms due to anesthesiologists' reluctance to initiate a surgical procedure. Despite the more difficult procedural execution of percutaneous techniques in children (due to tracheal flexibility and elasticity), anesthesiologists have historically been trained more frequently (and, therefore, feel more comfortable) using percutaneous techniques.

Given the paucity of evidence, we recommend emergency tracheotomy for FONA in children 8 years or younger. For children older than 8 years, we recommend a scalpel technique or a percutaneous technique. In an ideal scenario, a trained otolaryngologist should provide a surgical airway.<sup>13</sup> However, recent studies suggest no difference in performance times between surgeons and anesthesiologists with proper training.<sup>13</sup> We recommend that anesthesiologists—particularly those dedicated to pediatric anesthesia—should receive training and develop their skills in surgical FONA techniques for all pediatric age groups by completing training sessions using animal models. Familiarity and expertise in using a particular technique—in this case, a surgical technique—will enhance patient safety.

### BERN INSTITUTIONAL PROTOCOL

In a CICO crisis, we perform an emergency tracheotomy in children  $\leq 8$  years and a scalpel cricothyroidotomy technique in children older than 8 years. Our reasons for choosing the surgical approach in both groups are the higher rate of success and lower risk of severe complications in comparison with percutaneous techniques and the impracticality of cricothyroidotomy in newborns and infants. Alternatively, in children older than 8 years, percutaneous cricothyroidotomy using an uncuffed tracheal cannula with an internal diameter of 4.0mm can also be attempted. The 5 key steps of emergency tracheotomy are described in Figure 2.

It is important to remember to access the trachea using a vertical incision and to avoid incision of more than 2 tracheal rings, since this drastically reduces the risk of severe and irreparable complications. The risk of complete transection of the trachea can be reduced by avoiding a horizontal cut.

A video depicting the 5 steps of our emergency tracheotomy has been provided as Supplemental Digital Content 1, (Video, <http://links.lww.com/AACR/A427>).

### CONCLUSIONS

The need for FONA in neonates and infants is one of the most critical situations a clinician can encounter. Airway practitioners require training as well as equipment to successfully perform a FONA when warranted. We favor the surgical technique as the first choice in all children, with the option of attempting the percutaneous technique in children older than 8 years. ■■

### ACKNOWLEDGMENTS

The authors thank Jeannie Wurz, medical writer/editor (native English speaker), Department of Anesthesiology and Pain Medicine, Bern University Hospital, University of Bern, for editing the manuscript. They also wish to thank Stella Wenzel, from Dust Design Studio, for transforming our ideas into a digital image. They thank Dr Francis Ulmer (native English speaker and pediatric airway specialist) for the thorough revision of this manuscript. Finally, the authors would like to thank Editage ([www.editage.com](http://www.editage.com)) for final English language editing.

### DISCLOSURES

**Name:** Joana Berger-Estilita, MD, MMed.

**Contribution:** This author helped in the conception and design of the manuscript and perform a critical review for important intellectual content.

**Name:** Vivian Wenzel, MD.

**Contribution:** This author helped draft the manuscript and perform a critical review of important intellectual content.

**Name:** Markus M. Luedi, MD, MBA.

**Contribution:** This author helped draft the manuscript and perform a critical review of important intellectual content.

**Name:** Thomas Riva, MD.

**Contribution:** This author helped in the conception and design of the manuscript and perform a critical review of important intellectual content.

**This manuscript was handled by:** BobbieJean Sweitzer, MD, FACP.

### REFERENCES

1. Engelhardt T, Virag K, Veyckemans F, Habre W; APRICOT Group of the European Society of Anaesthesiology Clinical Trial Network. Airway management in paediatric anaesthesia in Europe—insights from APRICOT (Anaesthesia Practice In Children Observational Trial): a prospective multicentre observational study in 261 hospitals in Europe. *Br J Anaesth.* 2018;121:66–75.
2. Fiadjoe JE, Nishisaki A, Jagannathan N, et al. Airway management complications in children with difficult tracheal intubation from the Pediatric Difficult Intubation (PeDI) registry: a prospective cohort analysis. *Lancet Respir Med.* 2016;4:37–48.
3. Morray JP, Geiduschek JM, Caplan RA, Posner KL, Gild WM, Cheney FW. A comparison of pediatric and adult anesthesia closed malpractice claims. *Anesthesiology.* 1993;78:461–467.
4. Riva T, Theiler L, Jaquet Y, Giger R, Nisa L. Early experience with high-flow nasal oxygen therapy (HFNOT) in pediatric endoscopic airway surgery. *Int J Pediatr Otorhinolaryngol.* 2018;108:151–154.
5. Navsa N, Tossel G, Boon JM. Dimensions of the neonatal cricothyroid membrane—how feasible is a surgical cricothyroidotomy? *Paediatr Anaesth.* 2005;15:402–406.
6. Black AE, Flynn PE, Smith HL, Thomas ML, Wilkinson KA; Association of Pediatric Anaesthetists of Great Britain and Ireland. Development of a guideline for the management of the unanticipated difficult airway in pediatric practice. *Paediatr Anaesth.* 2015;25:346–362.
7. Habre W, Disma N, Virag K, et al; APRICOT Group of the European Society of Anaesthesiology Clinical Trial Network. Incidence of severe critical events in paediatric anaesthesia (APRICOT): a prospective multicentre observational study in 261 hospitals in Europe. *Lancet Respir Med.* 2017;5:412–425.
8. Metterlein T, Frommer M, Kwok P, Lyer S, Graf BM, Sinner B. Emergency cricothyrotomy in infants—evaluation of a novel device in an animal model. *Paediatr Anaesth.* 2011;21:104–109.
9. Prunty SL, Aranda-Palacios A, Heard AM, et al. The 'can't intubate can't oxygenate' scenario in pediatric anaesthesia: a comparison of the Melker cricothyroidotomy kit with a scalpel bougie technique. *Paediatr Anaesth.* 2015;25:400–404.

10. Johansen K, Holm-Knudsen RJ, Charabi B, Kristensen MS, Rasmussen LS. Cannot ventilate-cannot intubate an infant: surgical tracheotomy or transtracheal cannula? *Paediatr Anaesth*. 2010;20:987–993.
11. Holm-Knudsen RJ, Rasmussen LS, Charabi B, Böttger M, Kristensen MS. Emergency airway access in children—transtracheal cannulas and tracheotomy assessed in a porcine model. *Paediatr Anaesth*. 2012;22:1159–1165.
12. Sheridan RL, Ryan DP, Fuzaylov G, Nimkin K, Martyn JA. Case records of the Massachusetts General Hospital. Case 5-2008. An 18-month-old girl with an advanced neck contracture after a burn. *N Engl J Med*. 2008;358:729–735.
13. Ulmer F, Lennertz J, Greif R, Bütikofer L, Theiler L, Riva T. Emergency front of neck access in children: a new learning approach in a rabbit model. *Br J Anaesth*. 2020;125:e61–e68.
14. Stacey J, Heard AM, Chapman G, et al. The ‘Can’t Intubate Can’t Oxygenate’ scenario in Pediatric Anesthesia: a comparison of different devices for needle cricothyroidotomy. *Paediatr Anaesth*. 2012;22:1155–1158.
15. Cook TM, Woodall N, Frerk C; Fourth National Audit Project. Major complications of airway management in the UK: results of the Fourth National Audit Project of the Royal College of Anaesthetists and the Difficult Airway Society. Part 1: anaesthesia. *Br J Anaesth*. 2011;106:617–631.