

Contents lists available at [ScienceDirect](https://www.sciencedirect.com)

American Journal of Ophthalmology Case Reports

journal homepage: www.ajocasereports.com/

Brief Report

Synthetic rubber sheet to manage exposure keratopathy

Ayano Yoshimura^{a,b}, Kaoru Araki-Sasaki^{b,c,*}, Noriko Toyokawa^d, Ryo Fujiwara^{b,c},
Kanji Takahashi^c, Fumi Gomi^a

^a Department of Ophthalmology, Hyogo College of Medicine, 1-1, Mukogawacho, Nishinomiya, Hyogo, 663-8501, Japan

^b Department of Ophthalmology, JCHO Hoshigaoka Medical Center, 4-8-1, Hoshigaoka, Hirakata, 573-8511, Japan

^c Department of Ophthalmology, Kansai Medical University, 2-5-1, Shinmachi, Hirakata, Osaka, 573-1010, Japan

^d Nagata Eye Clinic, 1147 Horai-cho, Nara, Japan



ARTICLE INFO

Keywords:

Lagophthalmos
Corneal ulcer
Exposure keratopathy
Dry eye
Facial paralysis
Ocular surface

ABSTRACT

Purpose: Exposure keratopathy often progresses even with conventional various treatments and needs plastic surgery. However, plastic surgery of eye lid is often difficult in cases with poor general condition by cerebrovascular disorders. We will propose a novel method using synthetic rubber sheet to manage the exposure keratopathy under poor general conditions.

Observations: We treated with synthetic rubber sheet on 9 eyes of 9 patients who suffered from refractory exposure keratopathy due to cerebrovascular disorders. Sheets cut from sterile surgical gloves made of synthetic rubber (SR sheets) were placed directly onto the ocular surface with antibiotic ointment and fixed with gauze and tape. Severity of the exposure keratopathy was scored before and after the application of SR sheet. Covered ocular surface with SR sheet could keep an adequate moist environment and exposure keratopathy was improved in all the cases with no adverse effects during an average observation period of 166.2 days.

Conclusions and importance: Sterile synthetic rubber sheet cut from surgical gloves is an effective, safe, easy, and economical material to maintain better condition of ocular surface and especially useful for refractory exposure keratopathy under poor general condition.

1. Introduction

Exposure keratopathy due to lagophthalmos is mainly caused by central or peripheral facial cranial nerve paralysis. A peripheral paralysis called Bell's palsy is usually transient and will resolve with time. In contrast, central facial nerve paralysis caused by cerebrovascular disorders is permanent, resulting in severe exposure keratopathy. Once exposure keratopathy becomes refractory, it will lead to corneal ulceration which will progress to perforation.¹ There are many patients suffering from exposure keratopathy caused by central paralysis in intensive care units (ICU), coronary care units (CCU), and nursing facilities. Lagophthalmos was present in 17–25% of the patients admitted to ICUs.^{2,3} In cases with paralysis by cerebral infarction, exposure keratopathy will remain for the patients' entire life. However, plastic surgery is often difficult in various reasons under poor general conditions or it sometimes fails in vain. Various treatments keeping the ocular surface moist have been reported, e.g., GeliPerm dressing, eye patches, hypoallergenic tapes, saline-soaked gauzes, and suturing the eyelids

(tarsorrhaphy) combined with eye drops and/or ointments.⁴ Nevertheless, the corneal erosion often persists and progresses to corneal perforation. Thus, another method to manage exposure keratopathy easily is necessary to improve corneal condition of the patients under poor general condition. Purpose of this study is to show that covering the ocular surface with a rectangular piece of synthetic rubber sheets cut from a sterile surgical glove (SR sheets) is a simple and effective method to improve the corneal condition in exposure keratopathy.

2. Subjects and methods

We studied 9 eyes of 9 patients who had persistent corneal ulcers due to lagophthalmos at JCHO Hoshigaoka Medical Center and Nagata Eye Clinic. Their average age was 59.6 years with a range of 47–88 years. All the patients had cerebrovascular disorders, e.g., brainstem hemorrhage and/or cerebral infarction, and all of them used wheelchairs due to physical disabilities. Their referring doctors had applied artificial tears, ophthalmic ointments, and gauze eye patches and some plastic surgery

* Corresponding author. Department of Ophthalmology, Kansai Medical University, 2-5-1, Shin-machi, Hirakata, Osaka, 573-1010, Japan.

E-mail address: sasakis@hirakata.kmu.ac.jp (K. Araki-Sasaki).

<https://doi.org/10.1016/j.ajoc.2021.101185>

Received 7 November 2020; Received in revised form 18 April 2021; Accepted 25 July 2021

Available online 29 July 2021

2451-9936/© 2021 Published by Elsevier Inc. This is an open access article under the CC BY-NC-ND license (<http://creativecommons.org/licenses/by-nc-nd/4.0/>).

for the lagophthalmos. However, because the exposure keratopathy had not improved, the patients were referred to our hospitals.

Protocol for this study was approved by the Ethics Committee of the JCHO Hoshigaoka Medical Center and Nagata Eye Clinic, Kansai Medical University and the procedures conformed to the tenets of the Declaration of Helsinki. After obtaining a signed written informed consent from the patients, we started the treatment with SR sheet. The sheet was cut into 20 × 30 mm square from a sterile surgical gloves (Sensi-Touch Pro Sensoprene® Soft Toray Medical) and kept into the sterile container (Fig. 1a and b). The SR sheet was placed onto the ocular surface with antibiotic ointment, covered with surgical gauze and attached with surgical tape (Fig. 2). The SR sheet and gauze were changed three times/day at beginning of application.

Status of the cornea was graded by the severity of four signs, viz., conjunctival injection and vascular invasion, corneal thinning, corneal opacity, and corneal erosion (Table 1). The severity of each was scored from 0 to 3, and the total score was calculated at each time point. The quality of the ocular surface was scored by two doctors from photographs of the ocular surface without being informed on the clinical course of the patient, i.e., in a masked manner.

3. Results

3.1. Representative cases (Case1&7)

Case 1 was a 54-year-old woman who had bone dysplasia accompanied by cerebral hemorrhage and infarction. During the period of pain due to lagophthalmos (approximately 36 months), she was treated with taping and a gauze patch with antibiotic ointment. The condition of the ocular surface fluctuated during this conventional procedure, and the conjunctiva of her right eye gradually became more severely hyperemic and the condition progressively deteriorated. She was referred to our department and was initially treated with topical hyaluronic acid adding to antibiotic ointment and gauze patch. However, the corneal thinning progressed (Fig. 3a). The total score of her right eye was 12 points at this time (vessel invasion 3, corneal thinning 3, corneal opacity 3, corneal erosion 3). Because of the progression of severeness, we decided to apply a SR sheet with antibiotic ointment to keep the moisture of the ocular surface. The sheet was covered with a gauze patch and held in place with surgical tape. SR sheet with the antibiotic ointment was changed several times a day, and hyaluronic acid eye drops were also applied three times a day. After one month, the epithelial defect was completely healed, the corneal opacity was improved, and the inflammation gradually subsided and total score improved to 3 points (vessel invasion 1, corneal thinning

1, corneal opacity 1, corneal erosion 0) (Fig. 3b). A SR sheet was applied continuously with shorter wearing times until she was transferred to another hospital.

Case 7 was a 54-year-old man with a brainstem hemorrhage who suffered from lagophthalmos. Although he had been treated with tarsorrhaphy and extension of the upper eyelid by plastic surgery and also with an eye patch, the keratitis had progressed gradually during the 6 years of these treatments. The conjunctiva of his right eye was severely hyperemic and the corneal ulcer became deeper (Fig. 4a). We applied a SR sheet with antibiotic ointment to keep the moisture of the ocular surface in the same way as Case 1. The total score of his lagophthalmic cornea was 11 points at the beginning of the SR sheet application (vessel invasion 3, corneal thinning 2, corneal opacity 3, corneal erosion 3). Within one month, the epithelial defect was completely healed, the corneal opacity was reduced, and the inflammation subsided. The total score improved to 7 points (vessel invasion 1, corneal thinning 3, corneal opacity 3, corneal erosion 0; Fig. 4b). Because of the recurrence of keratitis after a discontinuance of the SR sheet, the SR sheet was continuously applied with shorter wearing time, e.g. during sleep.

A summary and treatment times course of all cases are presented in Table 2 and Fig. 5. All cases suffered from lagophthalmos for more than 24 months. Every case had undergone a gauze patch and ointment treatment, and four cases had undergone plastic surgery. Because all of the ocular surface lesions did not heal with these conventional treatments, and the patients developed severe keratitis, the SR sheet was applied. The average duration of sheet application was 166.2 days with a range of 35–254 days. The SR sheets significantly improved the corneal score in all cases ($P = 0.004$; Wilcoxon signed-rank test). The conjunctival injection was resolved, corneal erosion was healed, and the density of the opacity was reduced. There were no adverse effects in any of the eyes. Case 7 and 9 had higher scores even after the use of the rubber sheets because of the corneal scar which remained as the corneal opacity. However, the corneal ulcer and inflammation were resolved in both cases. Finally, 3 cases (Cases 1, 2, 6) were transferred to other hospitals or nursing facilities for elderly people. Case 4 died because of muscular dystrophy. In Case 9 with facial nerve paralysis, SR sheets were applied after two plastic surgeries, and they worked well and resulted in the healing of the keratitis in a short period without severe recurrences. In the remaining four cases, (Cases 3, 5, 7, 8), the corneal erosion recurred after the cessation of the SR sheet as in the representative case. Therefore, the SR sheet treatment was continuously applied during sleeping supplemented with eye drops during the day (Fig. 5).

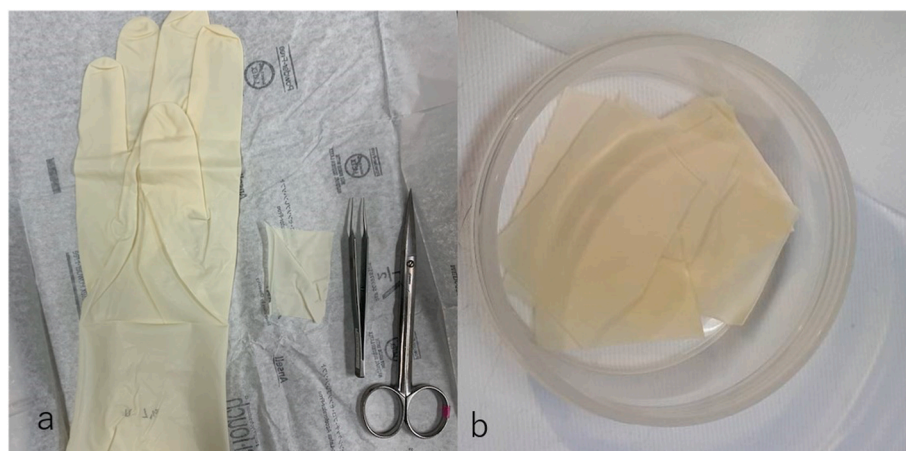

Fig. 1. Preparations of the rubber sheets to cover an eye with exposure kerathopathy.
 a. Conventional surgical hand glove (Sensi-Touch Pro Sensoprene® Soft Toray Medical) was cut into 20 mm × 30 mm pieces under sterile conditions.
 b. The rubber sheets are stored in a sterile container.

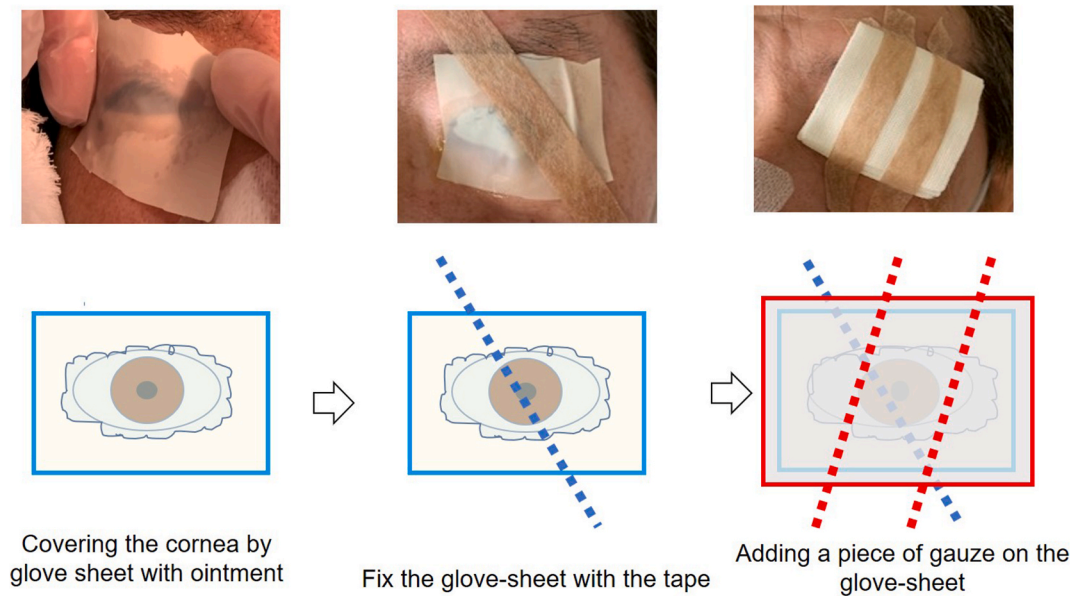


Fig. 2. The method of application of rubber sheets. The ocular surface was covered by the rubber sheet with ointment and fix with gauzes and tapes.

Table 1
Grading of severity in exposure keratopathy.

manifestation	Grade			
	0	1	2	3
hyperemia, vascular invasion	none	slight	moderate	remarkable
corneal thinning		<1/2 of the corneal stromal thickness	≥1/2 of the corneal stromal thickness	descemetocele
corneal opacity		slight	<1/4 of the entire corneal surface	≥1/4 of the entire corneal surface
erosion		slight	<1/4 of the entire corneal surface	≥1/4 of the entire corneal surface

4. Discussion

Our results showed that a rectangular piece of synthetic rubber sheet cut from sterile surgical glove was effective in resolving the exposure

keratopathy. We selected this material because it is powder-free and latex-free, clear, sterile, soft, inexpensive, and can be applicable to mucosal membranes. The risk of type IV allergies caused by chemical substances can be reduced by a manufacturing method that does not use vulcanization accelerators. In this regard, the rubber surgical gloves (Senti-Touch® Pro Sensoprene® Soft Toray Medical) do not use any “vulcanization accelerator”. In addition, the synthetic rubber gloves do not contain natural rubber latex which is the causative agent of immediate allergies. Furthermore, the SR sheets have moderate rigidity but are still flexible enough to conform to protrusions or irregularities of the ocular surface. Taken together, we consider that the SR sheets are safe and do not cause any allergic reactions. We conclude that they are suitable to apply onto the ocular surface.

There are several conventional methods for the treatment of lagophthalmos, but these have been reported to be not effective in many cases. A patch by gauze with ointment often does not work because of the space between the ocular surface and gauze. Direct taping of the eyelids often fails to keep the eyelids closed because of the movements in concordance with that of the opposed eye. The continuous eyelid suture or tarsorrhaphy are hard to be accepted cosmetically and the continuous eyelid closure will increase the risk of ocular infections.⁵⁻⁷ Lagophthalmos from cerebral disorder will not be resolved spontaneously.

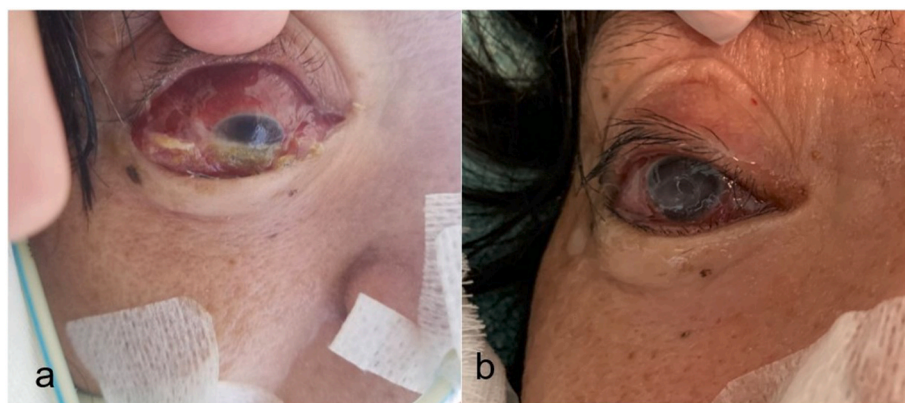

Fig. 3. Photographs of anterior segment of the affected eyes before (a) and after (b) the application of SR sheet in case 1. Note the severe hyperemic conjunctiva and inflammatory deposition on the corneal ulcer (a). The epithelial defect was completely healed, the corneal opacity was improved, and the inflammation was gradually relieved (b). Total score improved from 12 (vessel invasion 3, corneal thinning 3, corneal opacity 3, corneal erosion 3) to 3 (1/1/1/0).

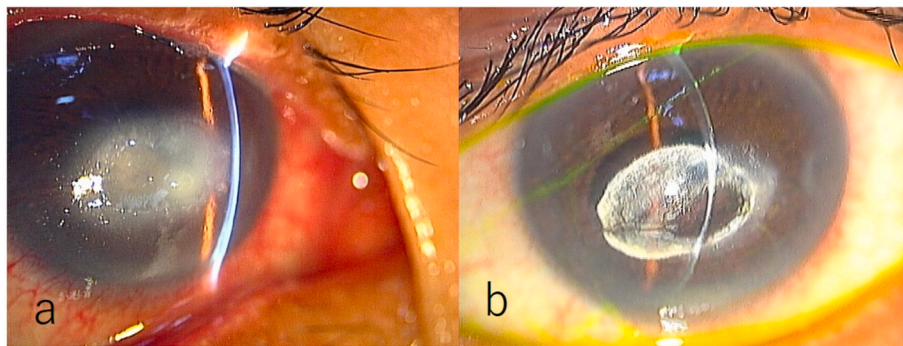


Fig. 4. Photographs of anterior segment of the affected eyes before (a) and after (b) the application of SR sheet in case 7.

Note the corneal ulcer by lagophthalmos with sever hyperemic conjunctiva (a).

Although the corneal opacity was still present, the epithelial defect was healed, with no inflammation (b). Total score improved from 11 (vessel invasion 3, corneal thinning 2, corneal opacity 3, corneal erosion 3) to 7 (1/3/3/0) points. The keratitis recurred after the cessation of SR sheet, and the coverage was continuously applied during sleeping.

Table 2
Summary of all cases of exposure keratopathy.

age	sex	Cause of lagophthalmos	Period suffering lagophthalmic keratitis (months)	Sheet application period (days) and condition afterwards	Score (before) (injection/thinning/opacity/erosion)	Score (after) (injection/thinning/opacity/erosion)	
Case1	54	F	Cerebral hemorrhage	36 M	128 Transfer to another hospital	12 (3/3/3/3)	3 (1/1/1/0)
Case2	58	M	Cerebral hemorrhage	31 M	199 Transfer to another hospital	7 (3/1/1/2)	2 (0/0/2/0)
Case3	51	M	Cerebral hemorrhage	56 M Plastic surgery twice	254 Continuously usage during sleeping time	4 (2/0/2/1)	1 (0/0/1/0)
Case4	53	M	Muscular dystrophy	41 M Plastic surgery	229 Passed away	10 (2/3/3/2)	4 (1/2/2/0)
Case5	67	F	Facial paralysis	67 M	176 Continuously usage during sleeping time	7 (3/0/2/2)	2 (1/0/1/0)
Case6	64	M	Brain-stem hemorrhage	23 M	142 Transfer to another hospital	7 (2/1/2/2)	3 (1/0/1/1)
Case7	54	M	Brain-stem hemorrhage	58 M Tarsorrhaphy plastic surgery	243 Continuously usage during sleeping time	11 (3/2/3/3)	7 (1/3/3/0)
Case8	47	M	Cerebral hemorrhage	48 M	90 Continuously usage during sleeping time	10 (2/2/3/3)	4 (0/1/2/1)
Case9	84	F	Facial paralysis	36 M Plastic surgery twice	35 Settled with SR sheet and switched to taping	8 (1/3/2/2)	5 (1/2/2/0)

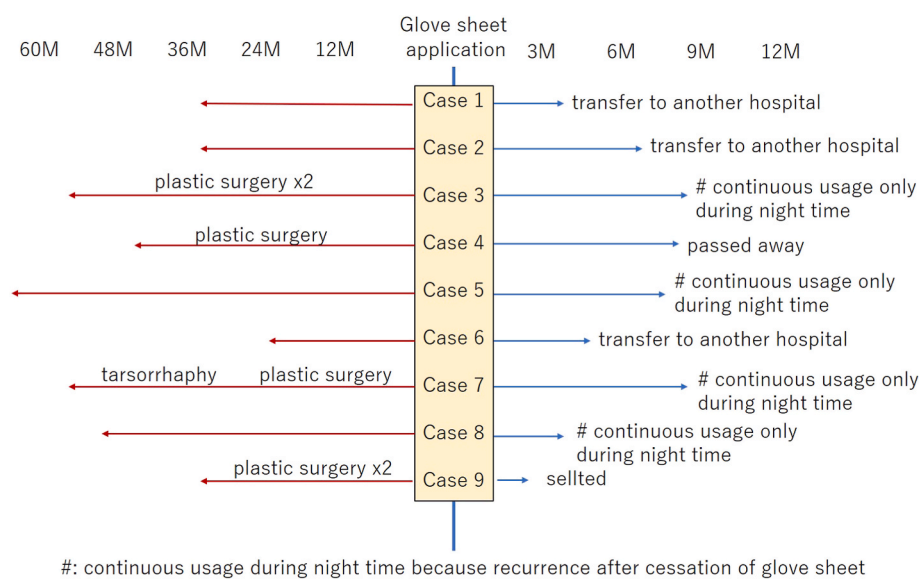


Fig. 5. Clinical course during periods of lagophthalmos and application of synthetic rubber sheets. All cases suffered from lagophthalmos for over 24 months even with conventional treatments. The average duration of the sheet application was 166.2 days with a range of 35–254 days. All cases were in better condition following the use of SR sheets. Three patients were transferred to other medical facilities, one patient deceased, and one patients completed the SR sheet treatment, and the remaining four patients were continuously treated to prevent the recurrence of keratitis.

Although the tarsorrhaphy often works well just after the closure of the eye, the keratitis will soon recur after opening of the eye. In addition, it is very difficult to perform tarsorrhaphy repeatedly.

The rationale for the treatment with SR sheets is to maintain the ocular surface moist even with the eyelid open. Some previous studies have shown the efficacy of polyethylene covers which has a similar concept as our SR sheets.^{1,8–10} However, no significant effect of polyethylene cover has been reported by So et al.¹¹ The polyethylene cover is too soft and can be easily pulled away from the eye by eye and eyelid movements. This then results in an incomplete covering. We suggest that the SR sheets cut from surgical gloves are better than polyethylene covers which are restricted for food and cooking use. The merits of the SR sheets are that they were designed for medical use and can be applied to cover the ocular surface easily at various time periods depending on the condition of the eye.

According to the appended paper of surgical gloves, we should pay attention to the deterioration due to oils and fats. However, the materials of the Sensi-Touch® Pro Sensoprene® soft Toray Medical is approved to be used to handle the mucous membranes of the intestine, oral cavity, and vagina during long operation times even though these membranes contain oils and fats. In this regard, the ocular surface does not contain excess oils and fats in comparison with other mucous membranes. We generally change the SR sheets at least once a day and we have not experienced any deterioration of the sheets. Therefore, we can conclude that they are safe for use on the ocular surface.

The synthetic rubber sheets cut from a sterile surgical glove is an effective material to maintain the ocular surface moist and to prevent the progression of corneal ulcer in exposure keratopathy. There are many patients of exposure keratopathy in poor general conditions in ICU, CCU, and nursing facilities. We propose that the material of surgical glove is suitable to protect the dryness of lagophthalmos, and we expect that a similar kind of sheet would be commercially available for the refractory exposure keratopathy.

Patient consent

Written consent to publish this case has not been obtained. This report does not contain any personal identifying information.

Written informed consent was obtained from all the patients before the entry into this study.

Funding

No funding or grant support.

Authorship

All authors attest that they meet the current ICMJE criteria for Authorship.

Declaration of competing interest

The following authors have no financial disclosures: KT, FG, AY, KS, NT, RF.

Acknowledgements and Disclosures

The authors thank Dr. Yohei Takada of the Department of Otorhinology of JCHO Hoshigaoka Medical Center, and Dr. Yoshikazu Kanemori of Kanemori Clinic of Ophthalmology and Plastic Surgery for their useful suggestions and discussions.

The authors also thank Professor Emeritus Duco Hamasaki of the Bascom Palmer Eye Institute for his critical discussion and editing the final manuscript.

References

1. Kocaçal Güler E, Eşer I, Eğrilmez S. Effectiveness of polyethylene covers versus carbomer drops (Viscotears) to prevent dry eye syndrome in the critically ill. *J Clin Nurs*. 2011;20:1916–1922.
2. Cunningham C, Gould D. Eyecare for the sedated patient undergoing mechanical ventilation: the use of evidence-based care. *Int J Nurs Stud*. 1998;35:32–40.
3. Dawson D. Development of a new eye care guideline for critically ill patients. *Intensive Crit Care Nurs*. 2005;21:119–122.
4. Gixti A, Sadri M, Edgar J, Datta AV. Common ocular surface disorders in patients in intensive care units. *Ocul Surf*. 2012;10:26–42.
5. Norn MS. Tear-film and cornea wetting time [proceedings]. *Acta Ophthalmol Suppl*. 1975;42–43.
6. Lenart SB, Garrity JA. Eye care for patients receiving neuromuscular blocking agents or propofol during mechanical ventilation. *Am J Crit Care*. 2000;9:188–191.
7. Baum JL. The Castroviejo Lecture. Prolonged eyelid closure is a risk to the cornea. *Cornea*. 1997;16:602–611.
8. Ahmadinejad M, Karbasi E, Jahani Y, Ahmadipour M, Soltaninejad M, Karzari Z. Efficacy of simple eye ointment, polyethylene cover, and eyelid taping in prevention of ocular surface disorders in critically ill patients: a randomized clinical trial. *Crit Care Res Pract* 2020. 2020:6267432.
9. Shan H, Min D. Prevention of exposure keratopathy in intensive care unit. *Int J Ophthalmol*. 2010;3:346–348.
10. Koroloff N, Boots R, Lipman J, Thomas P, Rickard C, Coyer F. A randomised controlled study of the efficacy of hypromellose and Lacri-Lube combination versus polyethylene/Cling wrap to prevent corneal epithelial breakdown in the semiconscious intensive care patient. *Intensive Care Med*. 2004;30:1122–1126.
11. So HM, Lee CC, Leung AK, Lim JM, Chan CS, Yan WW. Comparing the effectiveness of polyethylene covers (Gladwrap) with lanolin (Duratears) eye ointment to prevent corneal abrasions in critically ill patients: a randomized controlled study. *Int J Nurs Stud*. 2008;45:1565–1571.