

# Topical Decorin Reduces Corneal Inflammation and Imparts Neuroprotection in a Mouse Model of Benzalkonium Chloride-induced Corneal Neuropathy

Mengliang Wu,<sup>1</sup> Laura E. Downie,<sup>1</sup> Lisa J. Hill,<sup>2</sup> and Holly R. Chinnery<sup>1</sup>

<sup>1</sup>Department of Optometry and Vision Sciences, The University of Melbourne, Parkville, Victoria, Australia

<sup>2</sup>School of Biomedical Sciences, Institute of Clinical Sciences, University of Birmingham, Birmingham, United Kingdom

Correspondence: Holly R. Chinnery, Department of Optometry and Vision Sciences, The University of Melbourne, 200 Berkeley Street, Carlton, Victoria 3053, Australia; [holly.chinnery@unimelb.edu.au](mailto:holly.chinnery@unimelb.edu.au).

Received: September 11, 2022

Accepted: January 11, 2023

Published: February 21, 2023

Citation: Wu M, Downie LE, Hill LJ, Chinnery HR. Topical decorin reduces corneal inflammation and imparts neuroprotection in a mouse model of benzalkonium chloride-induced corneal neuropathy. *Invest Ophthalmol Vis Sci.* 2023;64(2):20. <https://doi.org/10.1167/iovs.64.2.20>

**PURPOSE.** We evaluated the neuroprotective and immunomodulatory effects of topical decorin in a murine model of benzalkonium chloride (BAK)-induced corneal neuropathy.

**METHODS.** Topical BAK (0.1%) was administered daily to both eyes of female C57BL/6J mice ( $n = 14$ ) for 7 days. One group of mice received topical decorin (1.07 mg/mL) eye drops to one eye and saline (0.9%) to the contralateral eye; the other group received saline eye drops to both eyes. All eye drops were given three times daily over the experimental period. A control group ( $n = 8$ ) received daily topical saline only, instead of BAK. Optical coherence tomography imaging was performed before (at day 0) and after (day 7) treatment to evaluate the central corneal thickness. Whole-mount immunofluorescence staining was performed to evaluate the density of corneal intraepithelial nerves and immune cells.

**RESULTS.** BAK-exposed eyes showed corneal epithelial thinning, infiltration of inflammatory macrophages and neutrophils, and a lower density of intraepithelial nerves. No change to the corneal stromal thickness or dendritic cell density was observed. After BAK exposure, decorin-treated eyes had a lower density of macrophages and less neutrophil infiltration and a higher nerve density than the saline-treated group. Contralateral eyes from the decorin-treated animals showed fewer macrophages and neutrophils relative to saline-treated animals. A negative correlation was found between corneal nerve density and macrophage or neutrophil density.

**CONCLUSIONS.** Topical decorin provides neuroprotective and anti-inflammatory effects in a chemical model of BAK-induced corneal neuropathy. The attenuation of corneal inflammation by decorin may contribute to decreasing corneal nerve degeneration induced by BAK.

Keywords: benzalkonium chloride, decorin, macrophages, neutrophils, corneal nerve regeneration

The cornea is densely innervated by branches of the ophthalmic division of the trigeminal nerve. In the epithelium, corneal sensory nerves stratify to form the sub-basal nerve plexus (SBNP), also termed the intraepithelial corneal basal nerves.<sup>1</sup> Axons from the SBNP course between the basal epithelial cells; nerve branches arising from the SBNP penetrate vertically through the epithelium and terminate as superficial nerve terminals (SNT) within the apical layers of the epithelium. Various ocular and systemic conditions can cause corneal nerve damage, including dry eye disease, infectious keratitis, and diabetes mellitus.<sup>2-4</sup>

Drug-induced neurotoxicity in the cornea has also been reported in patients with long-term use of preservative-containing eye drops.<sup>5</sup> Despite providing antimicrobial effects,<sup>6</sup> preservatives such as benzalkonium chloride (BAK) can cause dose-dependent ocular surface toxicity, leading to impaired corneal epithelial and endothelial barrier integrity, inflammatory cell infiltration, and corneal neuropathy.<sup>7-9</sup>

In patients with glaucoma, preservative-containing prostaglandins induce corneal SBNP changes, including altered nerve branching and nerve beading after 12 months; these effects were not observed in patients treated with nonpreserved prostaglandin eye drops.<sup>10</sup> Animal studies have also demonstrated the neurotoxic effect of BAK on the ocular surface. Decreased corneal intraepithelial nerve density was observed in mice treated with BAK (0.01% or 0.10%) eye drops for 1 week,<sup>9</sup> and in rabbits exposed to topical BAK (0.005%–0.020%) for 6 days.<sup>11</sup>

Despite the clinical importance of treatments to promote corneal reinnervation and restore corneal sensitivity, there are relatively few therapeutic approaches. Recently, several randomized, double-masked, vehicle-controlled trials have demonstrated promising efficacy of recombinant human nerve growth factor for treating neurotrophic keratopathy.<sup>12,13</sup> Topical application of recombinant human nerve growth factor in these clinical trials primarily aims to promote corneal epithelial healing; however, recent

evidence supporting a direct neurogenerative effect of recombinant human nerve growth factor has been reported in a prospective, observational clinical study, although control group data were not available.<sup>14</sup>

Decorin is an endogenous, leucine-rich proteoglycan that has demonstrated potent anti-inflammatory and antiscarring activity in the central nervous system. There is evidence that decorin modulates various cellular activities, including collagen fibrillogenesis, wound healing, inflammation, and nerve axon growth.<sup>15</sup> Our previous work has shown that decorin can modify immune cell activity and promote corneal nerve regeneration in a mouse model of sterile corneal abrasion.<sup>16</sup> To the best of our knowledge, there are few reports on strategies to promote corneal nerve regeneration or to mitigate nerve loss in BAK-induced corneal neuropathy. In this study, we sought to evaluate the corneal neuroprotective effect of topical decorin, and its capacity to modulate corneal inflammation in a mouse model of BAK-induced nerve degeneration.

## METHODS

### Animals and BAK Application

All animal procedures were performed in accordance with the ARVO Statement for the Use of Animals in Ophthalmic and Vision Research and approved by the Animal Ethics Committee at the Florey Institute of Neuroscience and Mental Health (18-094-UM). Female C57BL/6J mice ( $n = 22$ , 8 weeks old) were purchased from the Animal Resources Centre, Murdoch, Western Australia and housed in a specific pathogen-free environment at the Florey Institute of Neuroscience and Mental Health. The mice were randomly assigned to one of three groups with respect to intervention, namely, the BAK + decorin group ( $n = 7$ ), BAK + saline group ( $n = 7$ ), or saline control group ( $n = 8$ ). All mice were anesthetized with an intraperitoneal injection of ketamine (80 mg/kg) and xylazine (10 mg/kg), diluted in saline. The BAK + decorin group and BAK + saline group each received topical application of 5  $\mu$ L 0.1% BAK (Sigma, St Louis, MO, USA) to both eyes, and the saline control group received 5  $\mu$ L of saline to both eyes (day 0). On the following days (day 1 to day 6), mice were gently restrained for a single daily application of BAK or saline eye drops, and then held for 30 seconds to allow the eye drops to distribute across the ocular surface. At day 7, the mice were anaesthetized, imaged, and euthanized, and the corneas of both eyes were collected for further analysis.

### Treatment With Topical Decorin

Recombinant human decorin core protein (Galacorin, Catalent, Somerset, NJ, USA) was used in this study. Topical decorin (1.07 mg/mL) or vehicle (0.9% saline) eye drops were applied 1 hour after administration of BAK/saline, three times per day at 4-hourly intervals over the 7 days. Decorin treatment was assigned randomly to the left or right eyes in the BAK + decorin group, with the remaining eye receiving PBS to control for any contralateral effects of decorin. Mice in the BAK + saline group and saline control group received saline in both eyes. A summary of the study design is provided in Figure 1.

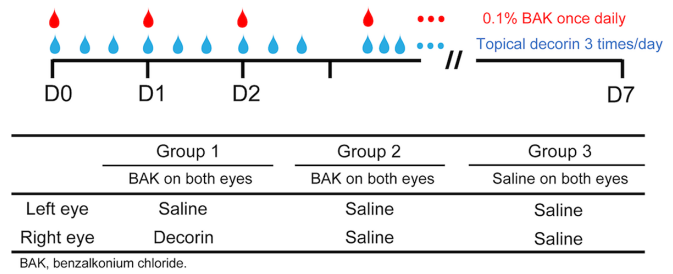


FIGURE 1. Schematic diagram of the study timepoints and different treatments for the animals.

### SD Optical Coherence Tomography (OCT)

In vivo SD-OCT imaging was performed to assess corneal integrity and measure the central corneal thickness at day 0 and day 7. Anesthetized mice were placed on the animal imaging mount and rodent alignment stage attached to the SD-OCT imaging device (Biotigen Envisu R2200 VHR; Biotigen, Inc., Durham, NC, USA). Volumetric  $3 \times 3$  mm rectangular scans of the central cornea (1000 A-scans/200 B-scans) were captured using an 18-mm telecentric lens. A z-stack OCT image was created by generating a projection of three adjacent central corneal frames, after registration to decrease the noise and increase the contrast of the image. The central corneal thickness was taken as the mean measure from three projected images, for each cornea, using ImageJ software (<http://imagej.nih.gov/ij/>; provided in the public domain by the National Institutes of Health, Bethesda, MD, USA).

### Corneal Wholemount Immunofluorescence

Mice were euthanized at day 7 and enucleated eyes were fixed in Zamboni's fixative for 2 hours at room temperature and then washed in PBS. Dissected corneas were incubated with primary antibody rabbit anti- $\beta$  tubulin 488 (identify nerves; 1:500; AB15708A4, Millipore, Billerica, MA, USA), rat anti-CD45 (identify all nucleated hematopoietic cells; 1:500; #550539, BD Biosciences, Franklin Lakes, NJ, USA), rabbit anti-IBA1 (identify macrophages; 1:500; #019-19741, Fujifilm Wako Chemicals, Osaka, Japan), and rat anti-NIMP (identify neutrophils; 1:100; NIMP-R14, Abcam, Cambridge, MA, USA) in a PBS solution with 5% goat serum and 0.5% Triton X-100 overnight at room temperature. Afterward, tissue flat-mounts were washed with PBS three times before incubation with the secondary antibodies, goat anti-rabbit Alexa Fluor 647 (1:500; #A21244, Thermo Fisher Scientific, Carlsbad, CA, USA), goat anti-rat Alexa Cy3 (1:500; #A10522, Thermo Fisher Scientific) and Hoechst (1:1000; Sigma) for 2 hours at room temperature. Immunostained samples were then washed and mounted onto glass slides with aqueous mounting medium and coverslipped for imaging.

### Corneal Wholemount Imaging and Analysis

Corneal wholemounts were imaged using a confocal microscope (Confocal Laser Scanning Microscopy SP8; Leica Microsystems, Buffalo Grove, IL, USA). Three nonoverlapping z-series were captured from the central (within the 0.75-mm diameter of the central corneal region) and peripheral cornea (between 1.0 mm and 1.5 mm peripheral corneal zone), respectively. For corneal nerve

quantification, separate z-stacks of the SNT and SBNP were created by generating z-projections of the superficial and basal epithelial layers.<sup>17</sup> To compare the immune cell changes between groups, z-stack images of the anterior corneal stroma (5 μm directly below the basal epithelium) were created for analyzing neutrophils (NIMP<sup>+</sup> with a distinct polymorphonuclear appearance) and macrophages (CD45<sup>+</sup> Iba1<sup>+</sup>). For the analysis of mature dendritic cells (DCs) (CD45<sup>+</sup> with typical dendriform shape), epifluorescence images (two central and two peripheral) were collected using an Olympus BX51 microscope (450 μm × 300 μm area). All images were analyzed by a masked observer. Corneal nerve density was quantified indirectly as the percent image area with positive beta-tubulin staining using manual thresholding in ImageJ software.<sup>17</sup> The density of corneal macrophages, neutrophils and DCs was derived from manual cell counts using ImageJ.

**Statistical Analyses**

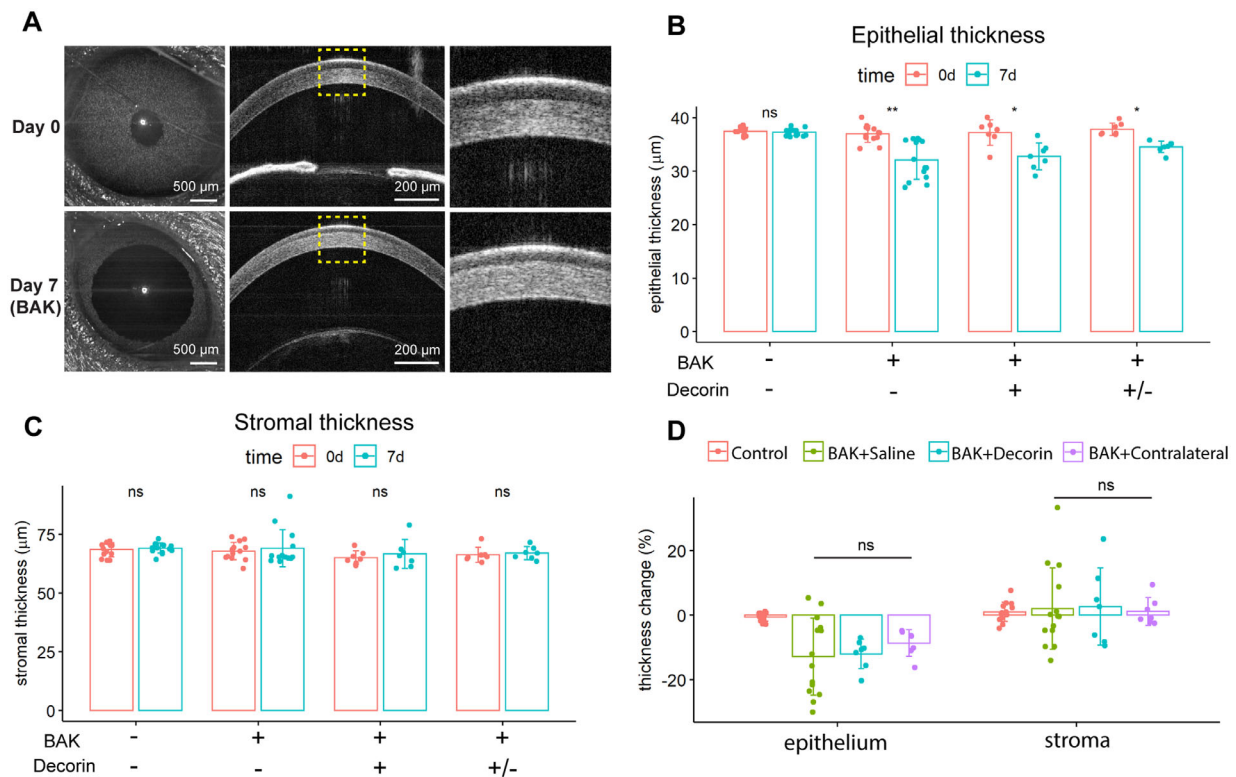
To analyze the potential contralateral eye effect of the decorin treatment, eyes receiving different interventions were combined into four analytical groups, namely, BAK + decorin, BAK + contralateral (the contralateral eye of the decorin-treated eye), BAK + saline, and a saline control. Comparison of corneal thickness before and after intervention, in each group, was performed using a paired *t*-test, or Wilcoxon signed-rank test when the data were not distributed normally. For comparisons between eyes that received different interventions, the data analysis was

performed by fitting a mixed effects model taking account the intraclass correlation for using data from both eyes. After fitting the model, post hoc tests were performed to examine the three main effects, including BAK exposure, decorin treatment, and any potential contralateral eye effects from the decorin treatment. Relationships between corneal nerve and immune cell densities were analyzed using Spearman correlation. Statistical analyses were performed, and figures were constructed, in R software (version 4.1.2; R Development Core Team, <https://www.r-project.org/>). A *P* value of less than 0.05 was considered statistically significant. All summary data are shown as mean ± standard deviation.

**RESULTS**

**Topical BAK Exposure Decreased the Central Corneal Thickness**

During the daily eye drop application, we did not observe any frank ocular surface damage. In the en face OCT images after 7 days of topical BAK exposure, no obvious inflammation in the anterior segment was observed in the OCT scanning (Fig. 2A). Central corneal epithelial thickness was decreased in all eyes after BAK exposure, relative to baseline measurements taken at day 0 (Figs. 2A, B). There was no significant difference in corneal stromal thickness after topical BAK exposure (Fig. 2C). In the saline control group, the corneal epithelial and stromal thicknesses were unchanged after daily topical saline applications for 1 week. Regarding the effect of topical decorin



**FIGURE 2.** Central corneal thickness changes after topical application of BAK and decorin. (A) Representative OCT images showing reduced corneal epithelial thickness after topical BAK exposure in all intervention groups. Corneal (B) epithelial and (C) stromal thickness in the saline control, BAK + saline, BAK + decorin, and BAK + contralateral (yellow) eye of the decorin-treated eye. (D) Comparison of epithelial or stromal thickness change (day 0 vs. day 7) between each condition. ns, not significant; \* *P* < 0.05; \*\* *P* < 0.01.



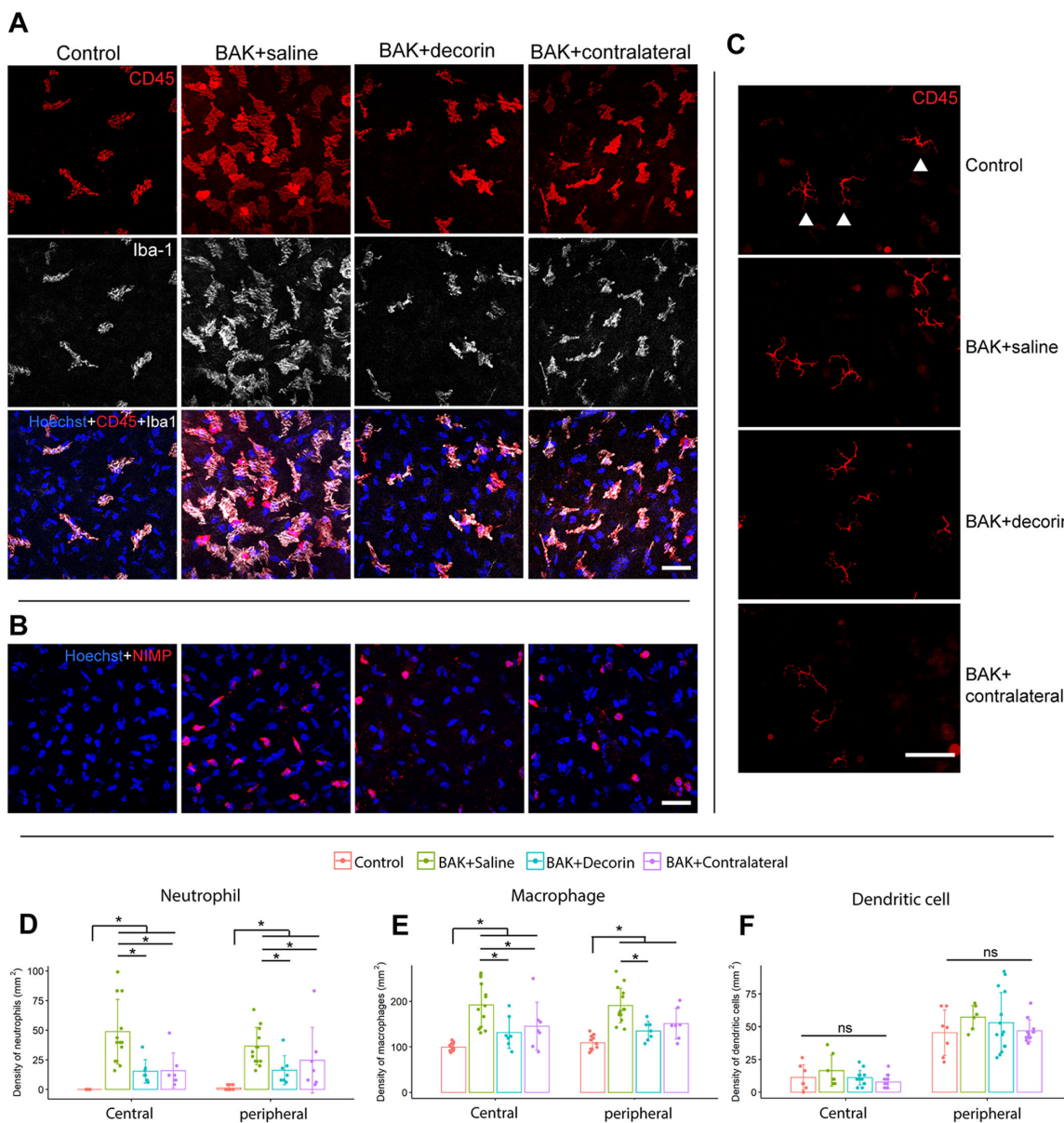
treatment, the decrease in the corneal epithelial thickness in the BAK + decorin group and their contralateral eyes was similar to that observed in the BAK + saline group (Figs. 2B and 2D) (BAK + saline,  $32.1 \pm 3.6 \mu\text{m}$  at day 7 vs.  $37.0 \pm 1.6 \mu\text{m}$  at day 0 [ $P = 0.003$ ]; BAK + decorin,  $32.7 \pm 2.5 \mu\text{m}$  vs.  $37.3 \pm 2.4 \mu\text{m}$  [ $P = 0.016$ ]; BAK + contralateral,  $34.6 \pm 1.1 \mu\text{m}$  vs.  $37.9 \pm 1.2 \mu\text{m}$  [ $P = 0.016$ ]), indicating that decorin did not show any direct or contralateral effects on BAK-induced corneal epithelial thickness changes.

### Topical Decorin Treatment Decreased Corneal Neutrophil and Macrophage Densities

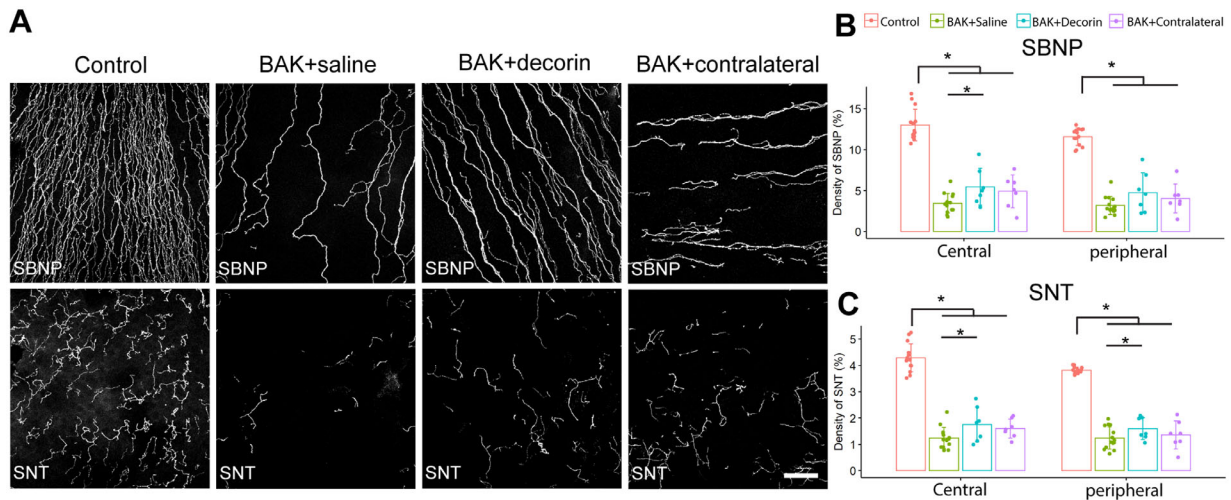
Daily topical application of BAK induced corneal inflammatory cell changes compared with saline controls in both the

central and peripheral regions, including a higher density of macrophages (BAK + saline vs. saline control, central cornea,  $192 \pm 48 \text{ cells/mm}^2$  vs.  $99 \pm 8 \text{ cells/mm}^2$  [ $P < 0.001$ ]; peripheral cornea,  $191 \pm 38 \text{ cells/mm}^2$  vs.  $109 \pm 15 \text{ cells/mm}^2$  [ $P < 0.001$ ]) and neutrophils (BAK + saline vs. saline control, central cornea,  $49 \pm 27 \text{ cells/mm}^2$  vs.  $0 \text{ cells/mm}^2$  [ $P < 0.001$ ]; peripheral cornea,  $37 \pm 16 \text{ cells/mm}^2$  vs.  $1 \pm 2 \text{ cells/mm}^2$  [ $P < 0.001$ ]) (Figs. 3A–E).

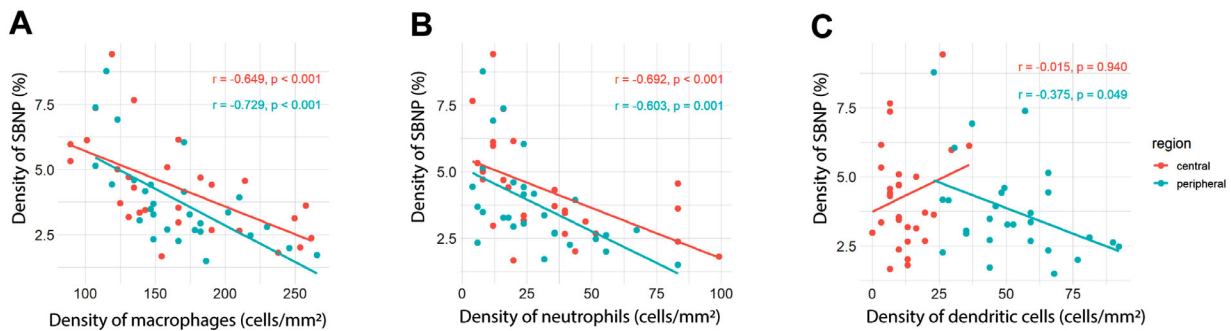
There were no intergroup differences in the density of mature DCs in the cornea (Fig. 3F). Eyes treated with topical decorin during the 1-week BAK exposure period showed lower densities of neutrophils (BAK + decorin vs. BAK + saline, central cornea,  $15 \pm 10 \text{ cells/mm}^2$  vs.  $49 \pm 27 \text{ cells/mm}^2$  [ $P < 0.001$ ]; peripheral cornea,  $16 \pm 12 \text{ cells/mm}^2$  vs.  $37 \pm 16 \text{ cells/mm}^2$  [ $P = 0.007$ ]) (Fig. 3E) and macrophages (BAK + decorin vs. BAK + saline, central cornea,



**FIGURE 3.** Corneal immune cell changes after topical application of BAK and decorin at day 7. (A) Representative confocal microscopic images of central anterior stromal CD45<sup>+</sup> Iba1<sup>+</sup> macrophages. Scale bar, 50  $\mu\text{m}$ . (B) Representative confocal microscopic images of central anterior stromal NIMP<sup>+</sup> neutrophils. Scale bar, 50  $\mu\text{m}$ . (C) Representative immunofluorescence images of the central cornea showing intraepithelial mature DCs characterized by distinct dendritic shape (arrowheads). Scale bar, 100  $\mu\text{m}$ . (D–F) Comparison of corneal neutrophil (D), macrophage (E), and DC (F) density between each group at day 7. ns, not significant; \*  $P < 0.05$ .



**FIGURE 4.** Corneal nerve changes after topical application of BAK and decorin. **(A)** Representative confocal microscopic images of corneal intraepithelial nerves stained using  $\beta$ -III-tubulin antibody, comprising the SBNP and SNT. Scale bar, 50  $\mu$ m. **(B, C)** Comparison of SBNP **(B)** and SNT **(C)** density, quantified as the percentage (%) of the image area occupied by corneal nerves, between each group. \*  $P < 0.05$ .



**FIGURE 5.** Correlations between the corneal SBNP density (% area) and the density of immune cells, comprising macrophages **(A)**, neutrophils **(B)**, and DCs **(C)** in the central (red) and peripheral (aqua) corneal regions. Data are from BAK + saline, BAK + decorin, and BAK + contralateral groups.

131  $\pm$  35 cells/mm<sup>2</sup> vs. 192  $\pm$  48 cells/mm<sup>2</sup> [ $P = 0.002$ ]; peripheral cornea, 135  $\pm$  21 cells/mm<sup>2</sup> vs. 191  $\pm$  38 cells/mm<sup>2</sup> [ $P = 0.001$ ] (**Fig. 3D**) in both the central and peripheral cornea, relative to those treated with BAK only. Notably, the contralateral eyes to decorin-treated eyes demonstrated similar results of fewer macrophages in the central cornea (146  $\pm$  53 cells/mm<sup>2</sup> vs. 192  $\pm$  48 cells/mm<sup>2</sup> [ $P = 0.013$ ]) and peripheral cornea (151  $\pm$  34 vs. 191  $\pm$  38 cells/mm<sup>2</sup> [ $P = 0.013$ ]), and fewer neutrophils in the central cornea (16  $\pm$  15 cells/mm<sup>2</sup> vs. 49  $\pm$  27 cells/mm<sup>2</sup> [ $P = 0.001$ ]). No difference in the density of mature DCs was observed after topical decorin treatment. Representative images of immune cells in the peripheral cornea were provided in Supplementary File 1.

**Decorin Decreased the Extent of Corneal Sensory Nerve Degeneration**

We have reported previously that topical application of decorin to the injured mouse corneal epithelium promotes nerve recovery and inhibits macrophage recruitment.<sup>16,18</sup> We examined whether decorin could impart similar neuroprotective effects in a model of repeated corneal neurotoxicity, induced by topical BAK. Overall, nerve density in the SBNP, in both the central and peripheral cornea, was approx-

imately 70% lower after 7 days of daily topical application of BAK relative to saline control eyes (BAK + saline vs. saline control, central cornea, 3.46  $\pm$  1.18% vs. 12.98  $\pm$  1.92% [ $P < 0.001$ ]; peripheral cornea, 3.19  $\pm$  1.10% vs. 11.57  $\pm$  1.05% [ $P < 0.001$ ]) (**Fig. 4**). The daily BAK exposure induced a similar extent of corneal nerve degeneration in the apically located SNT as the SBNP (BAK + saline vs. saline control, central cornea, 1.24  $\pm$  0.40% vs. 4.29  $\pm$  0.53% [ $P < 0.001$ ]; peripheral cornea, 1.24  $\pm$  0.42% vs. 3.82  $\pm$  0.12% [ $P < 0.001$ ]). In the central cornea, topical treatment with decorin preserved more of the SBNP and SNT compared with eyes treated with BAK + saline (BAK + decorin vs. BAK + saline, SBNP, 5.46  $\pm$  2.23% vs. 3.46  $\pm$  1.18% [ $P = 0.023$ ]; SNT, 1.76  $\pm$  0.66% vs. 1.24  $\pm$  0.40% [ $P = 0.030$ ]) (**Figs. 4B, C**). Similarly, decorin-treated eyes demonstrated a higher density of SNT in the peripheral cornea (BAK + decorin vs. BAK + saline, 1.60  $\pm$  0.42% vs. 1.24  $\pm$  0.42% [ $P = 0.047$ ]).

**Correlations Between Corneal Sensory Nerve and Immune Cell Features**

Given the close links between corneal nerves and immune cells, we examined the relationships between nerve preservation and the densities of key immune cell classes that participate in corneal wound healing. Corneal SBNP

density was negatively correlated with an increased density of macrophages (central cornea,  $\rho = -0.649$ ,  $P = 0.001$ ; peripheral cornea,  $\rho = -0.729$ ,  $P < 0.001$ ) (Fig. 5A). Similarly, there was a significant negative correlation between corneal SBNP density and the density of neutrophils in both the central cornea ( $\rho = -0.692$ ,  $P = 0.003$ ) and peripheral cornea ( $\rho = -0.603$ ,  $P = 0.003$ ) (Fig. 5B). The density of mature DCs in the peripheral cornea was also negatively correlated with SBNP density ( $\rho = -0.375$ ,  $P = 0.049$ ) (Fig. 5C). There was no relationship between the density of the corneal SBNP and mature DCs in the central cornea (Fig. 5C).

## DISCUSSION

Corneal nerves play vital roles in the maintenance of ocular surface health by influencing the blink reflex, regulating tear production, and releasing numerous neurotropic substances that support corneal nerve structure and sensitivity.<sup>19</sup> Corneal nerves also promote corneal wound healing and can influence the regulation of inflammation after injury.<sup>20–22</sup> However, the corneal sensory nerves are vulnerable to various insults, including trauma, infection, chemical burns, and iatrogenic injury. Many studies have provided evidence of topical preservative (e.g., BAK)-induced corneal neurotoxicity.<sup>8,11,23</sup> We have reported previously that topical decorin treatment can promote nerve regeneration after an initial traumatic injury.<sup>16</sup> In the current study, we sought to test the neuroprotective and immunomodulatory capacities of topical decorin in a model where the insult, topical BAK, was repeated daily over the course of 1 week. We observed that eyes treated with topical decorin retained more corneal sensory nerves compared with those that did not receive this treatment, and this effect was accompanied by fewer corneal inflammatory cells, including neutrophils and macrophages. These data provide evidence that topical decorin has neuroprotective effects in the cornea when challenged by a repeated pathological stimulus, making it an attractive candidate agent to be considered as part of a therapeutic regime for corneal neurotoxicity.

In vitro and in vivo rodent and human studies have demonstrated the time- and dose-dependent toxicity of topical BAK on the ocular surface.<sup>7,24</sup> In mice, treatment with 0.2% topical BAK twice daily for 1 week induced epithelial thinning, apoptosis in the basal epithelium, the infiltration of corneal immune cells, and an increased expression of proinflammatory cytokines, including TNF- $\alpha$ , IL-1 $\beta$ , and IL-6.<sup>25,26</sup> In a randomized double-masked clinical trial involving healthy volunteers topically treated with 0.01% BAK for 6 weeks, a significant increase in the density of corneal Langerhans cells was described based on in vivo confocal microscopy image analysis.<sup>9</sup> These findings provide evidence for a proinflammatory effect of BAK on the ocular surface. In the present study, we observed a significant decrease in corneal epithelial thickness and an increase in the stromal immune cell density, including neutrophils and macrophages after 1 week of daily topical application of 0.1% BAK. This inflammatory response was able to be mitigated by three times daily treatment with topical decorin, suggesting that decorin has a corneal immunomodulatory effect in BAK-induced local inflammation.

Consistent with results from the current study, BAK-induced corneal sensory nerve damage has been reported in recent experimental and clinical studies. Using the *thy1*-YFP transgenic mouse, to visualize the corneal nerves in

vivo, Sarkar et al.<sup>8</sup> observed decreased corneal stromal nerve fiber density after applying 0.1% BAK daily for 1 week. Lower corneal SBNP and SNT densities have also been reported in rabbits after daily topical 0.005% to 0.020% BAK exposure for 6 to 9 days.<sup>11</sup> A recent clinical study identified that patients receiving multiple therapies for glaucoma showed poorer corneal nerve fiber parameters compared with those on nonpreserved monotherapy treatment regimens.<sup>23</sup> Decreased corneal nerve fiber length was also observed in patients using preserved glaucoma monotherapy compared with a healthy control group.<sup>23</sup> Thus, even at clinical doses (0.004%–0.025%) that are much lower than those included in our preclinical study, repeated exposure to topical BAK can induce long-term corneal nerve damage.

BAK-induced neurotoxicity in the cornea might occur by two main pathways. First, BAK can induce nerve degeneration directly by compromising the lipid barrier of the nerve cell membrane.<sup>27</sup> There is also evidence that BAK-induced immune responses are involved.<sup>9,26</sup> Sarkar et al.<sup>8</sup> observed two different forms of BAK-induced neurotoxicity in mouse corneas. In their *thy1*-YFP mouse model, after ceasing topical BAK exposure, some of the damaged corneal stromal nerves regenerated in a pattern consistent with their baseline configuration, whereas others regenerated in different patterns and locations. The authors speculated that the reversible neurotoxicity of BAK might be associated with the resolution of inflammation after the discontinuation of BAK exposure.<sup>8</sup> Many studies have demonstrated that exaggerated inflammatory responses can damage corneal sensory nerves.<sup>28,29</sup> Our data provide supportive evidence for this theory. Topical decorin treatment attenuated BAK-induced corneal inflammatory responses, characterized by a lower density of macrophages and neutrophils, which was associated with the retention of more corneal sensory nerves. The observed negative correlation between the density of corneal intraepithelial nerves and macrophages or neutrophils suggests that the anti-inflammatory effect of decorin may contribute to its neuroprotective properties. Therefore, a therapeutic strategy focused on regulating inflammatory responses may be a relevant consideration for the treatment of BAK-induced corneal neuropathy.

There is increasing evidence for reciprocal spatiotemporal and biochemical communication between corneal immune cells and sensory nerves. Many studies have described negative correlations between these corneal features, in both ocular and systemic diseases, including dry eye disease,<sup>30</sup> infectious keratitis,<sup>31</sup> and diabetes.<sup>32</sup> Liu et al.<sup>33</sup> reported that the depletion of natural killer cells in mice delayed corneal nerve regeneration and increased neutrophil infiltration after corneal epithelial abrasion. Exaggerated inflammatory responses subsequent to cytokine secretion may contribute to the sensory nerve damage or inhibit their regeneration. In a mouse model of dry eye disease, corneal inflammatory cell infiltration and a higher expression of IL-17 and IFN- $\gamma$  mRNA was associated with corneal nerve degeneration.<sup>28</sup> In herpes simplex virus-infected corneas, Tian et al.<sup>29</sup> demonstrated a neuroprotective effect with topical application of pigment epithelium-derived factor, which was associated with the attenuation of neutrophil infiltration and reduced expression of IL-6, IL-1 $\beta$ , and TNF- $\alpha$ . Similarly, our previous work has shown that in mice with sterile injured corneas, treatment with topical decorin led to fewer infiltrating neutrophils, a lower density of macrophages and decreased expression of TGF- $\beta$  mRNA; these



changes were accompanied by enhanced corneal nerve regeneration.<sup>18</sup>

The immunomodulatory role of decorin has been reported in many tissues.<sup>34,35</sup> Decorin is an antagonist of TGF- $\beta$ , binding to all three TGF- $\beta$  isoforms and neutralizing their biological activities.<sup>15</sup> In an in vitro study of macrophages from bone marrow, decorin showed antiproliferative effects on macrophages by blocking endogenously produced TGF- $\beta$ .<sup>36</sup> In addition, another inflammatory cytokine, TNF- $\alpha$ , can be sequestered away from its receptor by decorin, to attenuate inflammatory responses.<sup>37</sup> However, decorin may induce a proinflammatory environment via binding to Toll-like receptor 2/4.<sup>38</sup> One explanation is that the function of decorin in inflammation seems to depend on the pattern of inflammation, that is, whether it is caused by a sterile injury or microbial pathogenesis. Decorin has been shown to share an antitumorogenic property by inducing proinflammatory responses and a release of cytokines, including pro-IL-1 $\beta$  and IL-10.<sup>39</sup> In our previous work, attenuation of inflammatory response, as characterized by lower neutrophil infiltration and a lower density of macrophages, was observed after topical decorin application in a corneal epithelial abrasion model.<sup>18</sup> In the current study, we confirmed the anti-inflammatory effect of decorin in a BAK-induced model of corneal inflammation, which might partially contribute to its neuroprotective properties.

Consistent with previous findings,<sup>18</sup> in the current study of BAK-induced corneal neurotoxicity, we observed a contralateral eye effect with topical decorin, involving a decrease in the density of macrophages and neutrophils in fellow eyes. Launay et al.<sup>26</sup> applied topical BAK in one eye of mice and observed that the unilateral BAK-induced corneal nerve degeneration elicited inflammation and neuron activation in both the ipsilateral and contralateral sensory trigeminal complex in the brainstem, characterized by activated microglia and a release of proinflammatory cytokines. The unilateral corneal nerve damage can induce the activation of transient receptor potential vanilloid 1 in the injured eye and substance P release in the opposite eye, leading to contralateral reactions of ocular pain and inflammation.<sup>40</sup> Lee et al.<sup>41</sup> demonstrated that a unilateral trephine-induced corneal injury model resulted in corneal DC infiltration in the contralateral eye, and an increased number of mature DCs and effector lymphocytes in the draining lymph nodes. Therefore, it is possible that the higher density of preserved corneal nerves in decorin-treated eye contributes to the relative attenuation of contralateral eye inflammation. These contralateral effects support the existence of functional neuroimmune crosstalk in the cornea that would be expected to involve downstream lymph nodes, the trigeminal ganglion, and brainstem.

This study was unable to reveal whether decorin is neuroprotective (i.e., preserves the nerves that are there) or neuroregenerative (i.e., encourages the growth of new nerves), or possibly both. Our previous work supports a regenerative effect of decorin in the corneal epithelial abrasion model,<sup>16</sup> whereas the BAK-induced neuropathy is different because it involves both ongoing nerve degeneration and regeneration. It would be interesting to differentiate between the relative contributions of these two related but distinct mechanisms in future studies. In addition, ocular surface epithelial damage was not directly measured as part of the study.

In conclusion, this study demonstrates that topical decorin treatment is beneficial to corneal nerves and has

anti-inflammatory effects in BAK-induced corneal neuropathy. The relative preservation of corneal nerves with decorin treatment was associated with a coincident attenuation of the corneal inflammatory response, providing the rationale for future studies to explore the detailed pathways of corneal neuroimmune interactions in the cornea. Given that bilateral effects on regulating inflammatory responses can be triggered by unilateral decorin treatment, the mechanism of immunomodulatory effect of decorin that may involve retrograde signals through trigeminal nuclei warrants further investigation. These findings also provide evidence of the therapeutic potential of decorin in corneal neuropathy with inflammation.

### Acknowledgments

The authors acknowledge the Florey Advanced Microscopy Facility at the Florey Institute of Neuroscience & Mental Health Facility for provision of instrumentation, training, and general support.

Funding support is provided by the National Health and Medical Research Council (HRC, APP1126540) and the Australian Government Research Training Program (MW).

Disclosure: **M. Wu**, None; **L.E. Downie**, None; **L.J. Hill**, None; **H.R. Chinnery**, None

### References

1. Stepp MA, Pal-Ghosh S, Downie LE, et al. Corneal Epithelial "neuromas": A case of mistaken identity? *Cornea*. 2020;39:930–934.
2. Benitez del Castillo JM, Wasfy MA, Fernandez C, Garcia-Sanchez J. An in vivo confocal masked study on corneal epithelium and subbasal nerves in patients with dry eye. *Invest Ophthalmol Vis Sci*. 2004;45:3030–3035.
3. Hamrah P, Cruzat A, Dastjerdi MH, et al. Corneal sensation and subbasal nerve alterations in patients with herpes simplex keratitis: An in vivo confocal microscopy study. *Ophthalmology*. 2010;117:1930–1936.
4. Hossain P, Sachdev A, Malik RA. Early detection of diabetic peripheral neuropathy with corneal confocal microscopy. *Lancet*. 2005;366:1340–1343.
5. Baudouin C, Labbe A, Liang H, Pauly A, Brignole-Baudouin F. Preservatives in eyedrops: The good, the bad and the ugly. *Prog Retin Eye Res*. 2010;29:312–334.
6. Charnock C. Are multidose over-the-counter artificial tears adequately preserved? *Cornea*. 2006;25:432–437.
7. Chen W, Li Z, Hu J, et al. Corneal alternations induced by topical application of benzalkonium chloride in rabbit. *PLoS One*. 2011;6:e26103.
8. Sarkar J, Chaudhary S, Namavari A, et al. Corneal neurotoxicity due to topical benzalkonium chloride. *Invest Ophthalmol Vis Sci*. 2012;53:1792–1802.
9. Zhivov A, Kraak R, Bergter H, Kundt G, Beck R, Guthoff RF. Influence of benzalkonium chloride on Langerhans cells in corneal epithelium and development of dry eye in healthy volunteers. *Curr Eye Res*. 2010;35:762–769.
10. Fogagnolo P, Dipinto A, Vanzulli E, et al. A 1-year randomized study of the clinical and confocal effects of tafluprost and latanoprost in newly diagnosed glaucoma patients. *Adv Ther*. 2015;32:356–369.
11. Chen W, Zhang Z, Hu J, et al. Changes in rabbit corneal innervation induced by the topical application of benzalkonium chloride. *Cornea*. 2013;32:1599–1606.

12. Bonini S, Lambiase A, Rama P, et al. Phase II randomized, double-masked, vehicle-controlled trial of recombinant human nerve growth factor for neurotrophic keratitis. *Ophthalmology*. 2018;125:1332–1343.
13. Pflugfelder SC, Massaro-Giordano M, Perez VL, et al. Topical recombinant human nerve growth factor (cenegermin) for neurotrophic keratopathy: A multicenter randomized vehicle-controlled pivotal trial. *Ophthalmology*. 2020;127:14–26.
14. Pedrotti E, Bonacci E, Chierigo C, et al. Eight months follow-up of corneal nerves and sensitivity after treatment with cenegermin for neurotrophic keratopathy. *Orphanet J Rare Dis*. 2022;17:63.
15. Gubbiotti MA, Vallet SD, Ricard-Blum S, Iozzo RV. Decorin interacting network: A comprehensive analysis of decorin-binding partners and their versatile functions. *Matrix Biol*. 2016;55:7–21.
16. Wu M, Downie LE, Grover LM, et al. The neuroregenerative effects of topical decorin on the injured mouse cornea. *J Neuroinflammation*. 2020;17:142.
17. Downie LE, Naranjo Golborne C, Chen M, et al. Recovery of the sub-basal nerve plexus and superficial nerve terminals after corneal epithelial injury in mice. *Exp Eye Res*. 2018;171:92–100.
18. Wu M, Downie LE, Hill LJ, Chinnery HR. The effect of topical decorin on temporal changes to corneal immune cells after epithelial abrasion. *J Neuroinflammation*. 2022;19:90.
19. Marco B, Alessandro R, Philippe F, Fabio B, Paolo R, Giulio F. The effect of aging on nerve morphology and substance P expression in mouse and human corneas. *Invest Ophthalmol Vis Sci*. 2018;59:5329–5335.
20. Nishida T. Neurotrophic mediators and corneal wound healing. *Ocul Surf*. 2005;3:194–202.
21. Yuan K, Zheng J, Shen X, et al. Sensory nerves promote corneal inflammation resolution via CGRP mediated transformation of macrophages to the M2 phenotype through the PI3K/AKT signaling pathway. *Int Immunopharmacol*. 2022;102:108426.
22. Zhang Y, Gao N, Wu L, et al. Role of VIP and Sonic Hedgehog signaling pathways in mediating epithelial wound healing, sensory nerve regeneration, and their defects in diabetic corneas. *Diabetes*. 2020;69:1549–1561.
23. Agnifili L, Brescia L, Villani E, et al. In vivo confocal microscopy of the corneal sub-basal nerve plexus in medically controlled glaucoma. *Microsc Microanal*. 2022;7:1–8.
24. Pauly A, Meloni M, Brignole-Baudouin F, Warnet JM, Baudouin C. Multiple endpoint analysis of the 3D-reconstituted corneal epithelium after treatment with benzalkonium chloride: Early detection of toxic damage. *Invest Ophthalmol Vis Sci*. 2009;50:1644–1652.
25. Lin Z, Liu X, Zhou T, et al. A mouse dry eye model induced by topical administration of benzalkonium chloride. *Mol Vis*. 2011;17:257–264.
26. Launay PS, Reboussin E, Liang H, et al. Ocular inflammation induces trigeminal pain, peripheral and central neuroinflammatory mechanisms. *Neurobiol Dis*. 2016;88:16–28.
27. Hanani M, Ledder O, Yutkin V, et al. Regeneration of myenteric plexus in the mouse colon after experimental denervation with benzalkonium chloride. *J Comp Neurol*. 2003;462:315–327.
28. Choi EY, Kang HG, Lee CH, et al. Langerhans cells prevent subbasal nerve damage and upregulate neurotrophic factors in dry eye disease. *PLoS One*. 2017;12:e0176153.
29. Tian X, Wang T, Zhang S, et al. PEDF reduces the severity of herpetic simplex keratitis in mice. *Invest Ophthalmol Vis Sci*. 2018;59:2923–2931.
30. Tepelus TC, Chiu GB, Huang J, et al. Correlation between corneal innervation and inflammation evaluated with confocal microscopy and symptomatology in patients with dry eye syndromes: A preliminary study. *Graefes Arch Clin Exp Ophthalmol*. 2017;255:1771–1778.
31. Cavalcanti BM, Cruzat A, Sahin A, Pavan-Langston D, Samayoa E, Hamrah P. In vivo confocal microscopy detects bilateral changes of corneal immune cells and nerves in unilateral herpes zoster ophthalmicus. *Ocul Surf*. 2018;16:101–111.
32. D'Onofrio L, Kalteniece A, Ferdousi M, et al. Small nerve fiber damage and Langerhans cells in type 1 and type 2 diabetes and LADA measured by corneal confocal microscopy. *Invest Ophthalmol Vis Sci*. 2021;62:5.
33. Liu Q, Smith CW, Zhang W, Burns AR, Li Z. NK cells modulate the inflammatory response to corneal epithelial abrasion and thereby support wound healing. *Am J Pathol*. 2012;181:452–462.
34. Bocian C, Urbanowitz AK, Owens RT, Iozzo RV, Gotte M, Seidler DG. Decorin potentiates interferon-gamma activity in a model of allergic inflammation. *J Biol Chem*. 2013;288:12699–12711.
35. Borges MC, Narayanan V, Iozzo RV, Ludwig MS. Deficiency of decorin induces expression of Foxp3 in CD4(+)CD25(+) T cells in a murine model of allergic asthma. *Respirology*. 2015;20:904–911.
36. Comalada M, Cardo M, Xaus J, et al. Decorin reverses the repressive effect of autocrine-produced TGF-beta on mouse macrophage activation. *J Immunol*. 2003;170:4450–4456.
37. Tufvesson E, Westergren-Thorsson G. Tumour necrosis factor-alpha interacts with biglycan and decorin. *FEBS Lett*. 2002;530:124–128.
38. Merline R, Moreth K, Beckmann J, et al. Signaling by the matrix proteoglycan decorin controls inflammation and cancer through PDCD4 and microRNA-21. *Sci Signal*. 2011;4:ra75.
39. Schaefer L, Iozzo RV. Small leucine-rich proteoglycans, at the crossroad of cancer growth and inflammation. *Curr Opin Genet Dev*. 2012;22:56–57.
40. Guzman M, Miglio MS, Zgajnar NR, et al. The mucosal surfaces of both eyes are immunologically linked by a neurogenic inflammatory reflex involving TRPV1 and substance P. *Mucosal Immunol*. 2018;11:1441–1453.
41. Lee HK, Kim KW, Ryu JS, Jeong HJ, Lee SM, Kim MK. Bilateral effect of the unilateral corneal nerve cut on both ocular surface and lacrimal gland. *Invest Ophthalmol Vis Sci*. 2019;60:430–441.