

[REVIEW ARTICLE]

Clinical and Serological Features and Pregnancy Outcomes in Women with Polymyositis/Dermatomyositis: A Case-based Review

Yuhei Ito, Yoshiki Yamamoto, Yasuo Suzuki, Kentaro Noda and Ayako Nakajima

Abstract:

We encountered a 30-year-old woman who developed dermatomyositis during pregnancy and was positive for anti-Mi-2 antibodies. She was successfully treated with prednisolone and tacrolimus and delivered a healthy child. We reviewed the cases of idiopathic inflammatory myositis (IIM) that developed during pregnancy that were published after the year 2000 to elucidate the profile of myositis-specific antibodies (MSAs) in them and to evaluate their obstetric outcomes. In cases with IIM that developed during pregnancy, anti-Mi-2, anti-TIF1-g, anti-Jo-1, and anti-EJ antibodies was detected in one case each. The obstetric outcomes of the IIM-complicated pregnancies were poor, especially when complicated with active maternal myositis. Further studies focusing on the possible causal relationships between MSAs and cases with IIM that developed during pregnancy are needed. For better obstetric outcomes, appropriate suppression of the maternal disease activity using immunosuppressants and vigilance regarding the patient's requirement of Caesarean section is important.

Key words: anti-Mi-2 antibody, anti-transcriptional intermediary factor 1-g antibody, myositis, myositis-specific antibody, obstetric outcomes

(Intern Med 61: 143-149, 2022)

(DOI: 10.2169/internalmedicine.7924-21)

Introduction

Polymyositis (PM) and dermatomyositis (DM) are the most common forms of idiopathic inflammatory myositis (IIM) (1). Incidence peaks have been reported in the 2 age groups of 10-15 years old (children) and 40-60 years old (older adults) (1). Since only 14% of patients with IIM belong to the childbearing age group, pregnancy complicated by PM/DM is uncommon; furthermore, the effect of myositis on pregnancy has not yet been revealed (1).

Some studies have suggested that PM/DM might be triggered by pregnancy (1); however, reports on pregnancy-associated PM/DM are scarce. Myositis-specific autoantibodies (MSAs), including anti-aminoacyl-tRNA synthetases (ARS), anti-melanoma differentiation-associated gene 5 (MDA5), anti-Mi-2, anti-transcriptional intermediary factor (TIF) 1- γ , and anti-signal recognition particle antibodies,

have been described in patients with IIM since the 1970s. The development of commercially available examination kits allows us to determine the presence of these antibodies in daily practice year after year. Many reports have shown that patients with PM/DM have characteristic clinical features according to each antibody present (2). The status of these MSAs informs us which extramuscular involvement should be considered (i.e., lung involvement, malignancy, etc.), the prognosis, expected treatment response, and optimal treatment options in the PM/DM patients (3). The obstetric outcomes complicated by IIM, especially in active maternal myositis, have been reported to be poor (1). Therefore, it is important to determine ways to achieve good control of the disease during pregnancy, preferably according to the specific antibody present.

We encountered a patient who developed DM during pregnancy and was positive for anti-Mi-2 antibodies. She was treated with prednisolone and tacrolimus. After deliver-

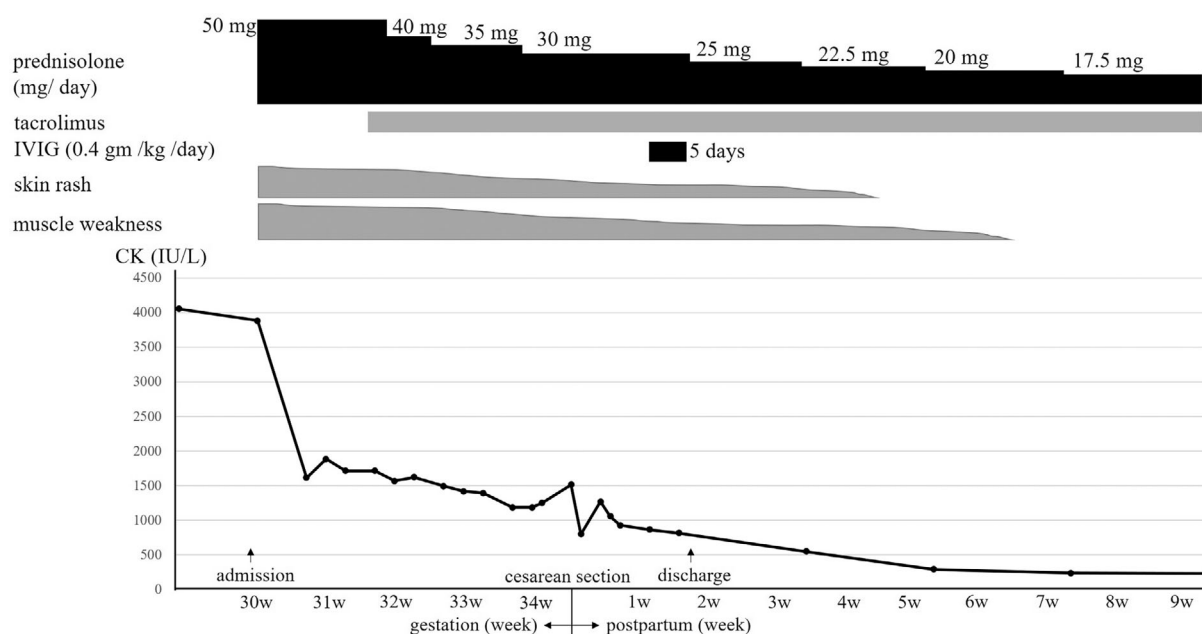


Figure. Clinical course of the patient. IVIG: intravenous immunoglobulin therapy, CK: creatine kinase

ing a healthy boy, she was successfully treated with additional intravenous immunoglobulin therapy (IVIG). We also reviewed cases of IIM that developed during pregnancy to elucidate the clinical features, MSA status, and obstetric outcomes.

Case

A 30-year-old woman presented with a skin rash, proximal muscle weakness (especially in the upper limbs), arthralgia, a low-grade fever, and fatigue at around 6 weeks of gestation during her second pregnancy. Gradually, she found it difficult to hang clothes using her upper limbs. During her first pregnancy, she delivered a healthy baby without any maternal or fetal complications. She had not taken any medications before the appearance of the skin rash. She had no family history of neuromuscular disorders.

Given her unfavorable symptoms, she was admitted to the gynecological unit at 30 weeks of gestation and quickly referred to our rheumatology department for possible DM. The physical examination revealed the following vitals: height, 151 cm; weight, 50 kg; body mass index, 21.9 kg/m²; blood pressure, 122/62 mmHg; body temperature, 36.8°C; heart rate, 92 beats/minute; and percutaneous oxygen saturation, 99% on room air. Chest auscultation revealed normal breath sounds. Periungual erythema, nail fold bleeding, Gottron's papules overlying the dorsal interphalangeal joints, and erythema rash on both arms and her face were detected. She had difficulty lifting her head from the pillow and standing up from the bed. There was muscle weakness in the neck and in the proximal upper and lower extremities bilaterally.

Her laboratory findings were as follows: albumin, 3.4

g/dL; alanine aminotransferase, 80 IU/L; aspartate aminotransferase, 184 IU/L; lactate dehydrogenase, 824 IU/L; creatine kinase (CK), 4,053 IU/L; ferritin, 80.4 ng/mL; myoglobin, 1,068.3 ng/mL; aldolase, 41.6 IU/L; erythrocyte sedimentation rate, 38 mm/hour; immunoglobulin G, 1,654 mg/dL; and C-reactive protein, 0.58 mg/dL. The complete blood count, electrolyte levels, and renal function values were within normal limits. The antinuclear antibody titer was 1:2,560 (speckled pattern). The anti-Mi-2 antibody was positive at 138 index (upper limit normal 53), anti-TIF1- γ antibody was positive at 33 index (upper limit normal 32) (enzyme immunoassay method; BML, Tokyo, Japan). Anti-SS-A antibody was positive at 154.6 U/mL (upper limit normal 7.0) (fluorescence enzyme immunoassay method; BML, Tokyo, Japan). The anti-MDA5, anti-ARS, anti-Jo-1, anti-U1-RNP, and anti-SS-B antibodies were negative.

There were no findings of interstitial lung disease or malignancy on computed tomography. Whole-body magnetic resonance imaging short-tau inversion recovery showed a high signal intensity of multiple muscle groups bilaterally, prominently in the proximal muscles. A skin biopsy of the left dorsal metacarpophalangeal joint area showing erythema rash revealed vacuolar degeneration of the basal cell layer and dermal lymphocytic infiltrate, which was consistent with the characteristics of the skin lesions in DM. The patient was thus diagnosed with DM based on these clinical and laboratory findings using the Bohan and Peter criteria (4, 5). Prednisolone was initiated at a dose of 50 mg/day. The clinical course after admission is shown in Figure.

After 2 weeks (31 weeks of gestation), she had erythema and muscle weakness, the CK level remained high at 1,713 IU/L, and the aldolase level was 29 IU/L. Tacrolimus (3 mg, once daily) was initiated. Although her skin lesion gradually

improved, the elevated CK level and muscle weakness did not improve. Given the risk of her becoming unable to complete labor, which could lead to emergent Caesarean section (C/S) due to muscle fatigue during vaginal delivery, C/S was planned. At 34 weeks of gestation, fetal cardiotocography showed a non-reassuring fetal heart rate with mild prolonged deceleration followed by severe late deceleration, and emergent C/S was performed. The patient delivered a healthy male baby whose neck had become wrapped up in the umbilical cord, which explained the deceleration. The baby's birth weight was 2,272 g, which was appropriate for the delivery date, the Apgar score was 8/10, and no obvious adverse effects were noted. Since the mother's CK level remained high (1,247 IU/L) even 8 days after the delivery, IVIG (0.4 gm/kg/day for 5 days) was started. Her muscle weakness gradually improved along with the decrease in muscle enzyme values, and the prednisolone dose was gradually tapered. She was discharged on the 13th day after delivery, and her baby was discharged on the 19th day. Sixty-five days after delivery, when she was treated with prednisolone (17.5 mg/day) and tacrolimus, her muscle strength had almost completely recovered, and the CK level decreased to 231 IU/L.

Review of Pregnancy-associated IIM Cases and Their Obstetric Outcomes

To elucidate the obstetric outcomes in patients with IIM in terms of autoantibodies and the time point of development of IIM and pregnancy, we reviewed the literature published after the year 2000.

Method

We searched for cases of IIM that developed during pregnancy using the terms "polymyositis," "dermatomyositis" or "inflammatory myositis," and "pregnancy" in PubMed articles published after 2000 to reveal the clinical features and MSA status. We searched various case series or pregnancy cohorts using the terms "pregnancy," "outcome," "polymyositis," "dermatomyositis," and "inflammatory myositis" in the PubMed articles published after 2000 to elucidate the obstetric outcomes of pregnancies complicated with IIM.

Clinical features and MSA status of IIM that developed during pregnancy

We reviewed the English literature to elucidate the clinical features and MSA status in cases with IIM that developed during pregnancy. We identified 14 cases with IIM that developed during pregnancy from 13 reports (6-18); we have summarized them along with our case in Table 1. In addition, six cases of IIM that developed during pregnancy reported by Vánca et al. (19), Nagy et al. (20), and Zhong et al. (21) were also found and have been listed in Table 2, as these cases lacked a detailed description of the status of the antibodies.

The median age of the onset of IIM that developed during

pregnancy was 31 [interquartile range (IQR) 27-32] years old. Among the 15 cases of IIM that developed during pregnancy, 4 (26.7%) had PM, 9 (60%) had DM, and 2 (13.3%) had clinically amyopathic DM. The data regarding the onset of IIM according to the gestation period were available in 13 cases: 1st trimester (from 0 to 15 weeks), 8 cases (62%); 2nd trimester (from 16 to 27 weeks), 4 cases (31%); and 3rd trimester (after 28 weeks), 1 case (8%). Regarding the status of the antibodies, anti-TIF1- γ antibody, anti-Mi-2 antibody, anti-Jo-1 antibody, and anti-EJ antibody were detected in one case each. The median peak CK level was 2,138 (IQR 1,029-3,875) IU/L. With respect to the treatment, oral corticosteroids or pulse methylprednisolone were administered in 13 (86.7%), other immunosuppressants were administered in 5 (33.3%), and IVIG was administered in 6 (40%). Regarding the obstetric outcomes, live births were observed in 13 cases (86.7%), preterm birth (PB) in 8 (53.3%), and small for gestational age (SGA) in 3 (20%); C/S was performed in 9 cases (60%). Notably, with respect to maternal complications, severe respiratory failure requiring invasive mechanical ventilation due to respiratory muscle weakness was seen in 2 (13.3%).

Obstetric outcomes of pregnancies complicated with IIM

A study by Nagy et al. retrospectively collected and analyzed the data of pregnancies complicated with IIM (IIM that developed before or during pregnancy) (20). The studies by Vánca et al., Fernandez et al., Zhong et al., and Gupta et al. collected and analyzed the data of all pregnancies seen in patients with IIM (19, 21-23). The aforementioned five studies describing the characteristics and obstetric outcomes of pregnancies complicated with IIM are summarized in Table 2. In two large population-based cohort studies by Kollstad et al. and Chen et al., detailed information on the temporal relationships between pregnancies and the onset of IIM was not available (24, 25). The study by Silva et al. (1) collected and reviewed the data of cases published before the year 2000. Thus, we excluded these three studies from our review (Table 2). The studies by Vánca et al. (19), Fernandez et al. (22), Zhong et al. (21), and Gupta et al. (23) were retrospective single-center studies conducted in Hungary, Spain, China, and India, respectively, whereas Nagy et al.'s study (20) was an international multicenter retrospective study involving four European countries.

Among the pregnancy studies, the incidence of pregnancies complicated with IIM developed either before pregnancy or during pregnancy ranged from 7.5% to 16.7%, and the maternal IIM during pregnancy was active in almost half the cases. The development of IIM during pregnancy was extremely rare (range, 0-1.4%; Table 2). Regarding the outcomes of pregnancies complicated with IIM, live birth was reported in 25.0-78.6% cases, while fetal loss was reported in 21.4-75.0% (Table 2). Among the live births, PB was reported in 4.2-16.7% cases. Fetal loss was more frequently observed in cases of active IIM during pregnancies (range,

Table 1. Clinical Features and MSA Status in Cases with Idiopathic Inflammatory Myositis That Developed during Pregnancy.

No.	Reference	Age at IIM onset, (y)	Disease	Onset of IIM*	MSA	ANA (pattern)	Peak CK (IU/L)	Treatment	Obstetric outcomes				
									LB	PB	SGA	C/S	Reasons for C/S, complications
1	(6)	26	PM	3rd trimester			8,000	mPSL, PSL	yes	NA	NA	no	
2	(6)	31	PM	24 w			1,000-2,000	PSN	yes	NA	NA	NA	
3	(7)	22	DM	12 w		1/80	245	PSL, IVIG	no [‡]				
4	(8)	34	CADM	4 w		1/40 (Nu)	NA	topical steroid	yes	no	no	no	
5	(9)	27	DM	23 w			394*	DEX, HCQ	yes	yes	NA	yes	scar tenderness
6	(10)	32	DM	5 w		1/160 (diff spe)	3,650	mPSL, IVIG	yes	yes	NA	yes	PROM
7	(11)	31	DM	18 w		1/160 (sp)	1,029	PSL, IVIG	yes	yes	yes	yes	intubation [§]
8	(12)	42	DM	15 w		1/320 (sp)	2,000	mPSL, IVIG	yes	no	NA	yes	planned C/S
9	(13)	40	DM	24 w		1/100	2,138	mPSL	yes	yes	NA	yes	PH
10	(14)	28	DM	4 w		1/160	NA	topical steroids, HCQ, CS	yes	no	no	no	
11	(15)	31	PM	12 w			2,338	mPSL, PSL, IVIG, AZA	yes	yes	yes	yes	fetal distress, intubation [§]
12	(16)	31	CADM	10 w	anti-EJ		509	PSL	yes	yes	NA	yes	PROM
13	(17)	27	PM	NA	anti-Jo-1		3,875	CyA, PSL	yes	yes	yes	yes	PH, fetal distress
14	(18)	32	DM	NA	anti-TIF1- γ		NA	NA	NA	NA	NA	NA	
15	our case	30	DM	6 w	anti-Mi-2	1/2,560 (sp)	4,053	PSL, tacrolimus, IVIG	yes	yes	no	yes	planned C/S

*Described as gestational age at PM/DM onset.

[‡]Due to medical termination.

*Described as CK-MM.

[§]Severe respiratory failure requiring invasive mechanical ventilation due to respiratory muscle weakness.

CADM: clinically amyopathic dermatomyositis, ANA: antinuclear antibody, anti-TIF1- γ antibody: anti-transcriptional intermediary factor 1- γ , anti-SRP antibody: anti-signal recognition particle antibody, AZA: azathioprine, CK: creatinine kinase, CS: corticosteroids, C/S: caesarean section, CyA: cyclosporine A, d: day(s), diff spe: diffuse speckled pattern, DEX: dexamethasone, DM: dermatomyositis, HCQ: hydroxychloroquine, IIM: idiopathic inflammatory myositis, IVIG: Intravenous Immunoglobulin, LB: live birth, mPSL: methylprednisolone, MSA: myositis specific antibody, MTX: methotrexate, m: month(s), NA: not assessed, Nu: nucleolar pattern, PB: preterm birth, PH: pregnancy hypertension, PM: polymyositis, PROM: premature rupture of membranes, PSL: prednisolone, PSN: prednisone, SGA: small for gestational age, sp: speckled pattern, y: years, w: week(s).

42.1-57.1%) than in those with inactive IIM (range, 14.3-28.6%). Notably, two cases of fetal loss were reported in inactive IIM pregnancies by Váncsa et al., both of which were abortions at the patient's request (19). Fetal loss was observed in 50 cases, most cases of which were due to spontaneous abortions (n=32). Other reasons for fetal loss were medical termination (n=10), termination by patient's request (n=6), ectopic pregnancy (n=1), and still birth (n=1). Fetal outcomes were reported to be worse in pregnancies complicated with IIM than in those not complicated with IIM (21, 23). Zhong et al. showed that women with IIM that developed before pregnancy were at a significantly higher risk of either PB or spontaneous abortion than those with IIM that developed during or after pregnancy period (adjusted odds ratio 9.36; p=0.041) (21). Gupta et al. also showed that the obstetric complications (relative risk 7.6; p<0.001) and fetal complications (relative risk 2.7; p=0.002) occurred more frequently in patients with IIM that developed before pregnancy than those with IIM that developed

after pregnancy period (23). In contrast, Fernandez et al. reported no marked difference in the maternal and fetal outcomes between 14 pregnancies complicated with IIM and the 88 not complicated with IIM (22). Furthermore, Nagy et al. reported that active IIM during pregnancy might be associated with intra-uterine growth retardation; the mean weight of newborns of active IIM patients was 2,193 g, whereas that of newborns of inactive IIM patients was 3,167 g (20).

Discussion

In this review, we summarized cases of IIM that developed during pregnancy published after the year 2000. Since then, several autoantibodies associated with IIM have become able to be measured in specific laboratories as well as commercially. The basic characteristics of patients with IIM that developed during pregnancy after 2000, which we have summarized in this review, were not significantly different from those published before 2000, as reported by Silva et

Table 2. Characteristics and Obstetric Outcomes of Pregnancies Complicated with Idiopathic Inflammatory Myositis in English Literature since 2000.

Reference	Pregnancies, n		Subtype		Obstetric outcomes among pregnancies complicated with IIM					
	All*, n	Complicated with IIM [†] , n (%) (active/inactive*)	IIM that developed before pregnancy, n (%)	IIM that developed during pregnancy, n (%)	Live birth		Fetal loss			
					Total, n (%)	PB [‡] , n (%)	Total, n (%) active/inactive	EP, n	Abortion [§] SP/ Pt req/MT, n	SB [§] , n
(19)	186	14 (7.5%) [§] (7/7)	13 (7.0%)	1 (0.5%)	8 (57.1%)	2 (14.3%)	6 (42.8%) 4 (57.1%)/ 2 (28.6%)**	0	4/2/0	0
(22)	102	14 (13.7%) ^{¶¶} NA	14 (13.7%)	0 (0%)	11 (78.6%)	NA	3 (21.4%) NA	0	1/0/2	0
(20)	NA	33 (NA)** (19/14)	30	3	23 (69.7%)	4 (12.1%)	10 (30.3%) 8 (42.1%)/ 2 (14.3%)	1	6/0/2	1
(21)	144	24 (16.7%) ^{¶¶¶} NA	22 (15.3%)	2 (1.4%)	11 (45.8%)	4 (16.7%)	13 (54.2%) NA	0	5/4/4	0
(23)	229	24 (10.4%) ^{§§} NA	24 (10.4%)	0 (0%)	6 (25.0%)	1 (4.2%)	18 (75.0%) NA	0	16/0/2	0

*These include pregnancies complicated with IIM and pregnancies not complicated with IIM.

[†]These include pregnancies with IIM that developed before pregnancy, and IIM that developed during pregnancy.

[‡]Disease status of maternal IIM.

[§]Preterm birth was defined when the pregnancy ended after 20 and before 37 weeks.

[¶]Abortion was defined as the interruption of pregnancy before 20 weeks.

^{§§}Still birth was defined as intrauterine fetal death after 20 weeks.

^{§§}Seen in 8 patients (PM 3, DM 5).

**Both were abortions at patient's request.

^{¶¶}Seen in 9 patients (PM 4, DM 4).

^{¶¶¶}Seen in 23 patients (PM 9, DM 9, JDM 2, PM+SSc 1, DM+RA 1, DM+SLE 1).

^{¶¶¶}Seen in 19 patients (PM 6, DM 13).

^{§§}Seen in 7 patients (DM 2, PM 2, antisynthetase syndrome 2, myositis+SSc 1).

DM: dermatomyositis, EP: ectopic pregnancy, IIM: idiopathic inflammatory myositis, JDM: juvenile dermatomyositis, MT: medical termination, NA: not assessed, PB: preterm birth, PM: polymyositis, Pt req: at patients' request, RA: rheumatoid arthritis, SB: still birth, SLE: systemic lupus erythematosus, SP: spontaneous abortion, SSc: systemic sclerosis.

al. (1). In previous reports, active IIM during pregnancy was also associated with worse pregnancy outcomes other than fetal loss, which could not be included in Table 2. Zhong et al. reported that among 144 pregnancies, those with active IIM had significantly higher risks for either PB or spontaneous abortion than those with inactive IIM (adjusted odds ratio 435.35; $p=0.007$) (21). Other studies have also reported that the obstetric outcomes in patients with IIM that developed during pregnancy before 2000, especially those in the first trimester, included an increased risk of fetal loss (1, 26). Even if fetal loss was avoided, other fetal complications, such as PB or growth retardation, especially in active IIM cases, were concerning (Table 2) (19-23). By investigating each patient's case report precisely (Table 1), among 14 babies (including our case and excluding a case in which the outcome was unknown), 92.9% were live births. These data may highlight the difficulties in treating IIM that develops in pregnant women, even post-2000.

Other studies using a large claim database have also shown that the obstetric outcomes of pregnancies complicated with IIM were poor. This data could not be included in Table 2, as information was insufficient. In a study by

Chen et al. that used the medical records from Australia, 17 pregnancies complicated with PM/DM were compared with 991,292 normal pregnancies. The incidences of PB, SGA, admission to a neonatal intensive-care unit, and severe neonatal morbidity were 35%, 12%, 35%, and 18%, respectively, in the PM/DM cases, which was higher than that of normal pregnancies (25). In a nationwide data set analysis by Kolstad et al. of 853 pregnancies complicated with PM/DM compared with 101,123 normal pregnancies, the incidences of preterm rupture of membranes, intrauterine growth retardation, and C/S were 5.0%, 3.1%, and 25%, respectively, in the PM/DM cases, which was higher than that of normal pregnancies (24). These previous reports together with our review highlighted that controlling the maternal IIM disease activity during pregnancy is essential to reduce the risks of severe obstetric complications.

The patient in our study was interpreted as positive for anti-Mi-2 and falsely positive for anti-TIF1- γ antibodies. Fujimoto et al. reported that anti-Mi-2 β antibody has weak reactivity to the TIF1- γ protein, which may result in elevation of the TIF1- γ antibody titer in cases with anti-Mi-2 antibody positivity (27). Oya et al. reported 13 women with MSA-

positive DM (anti-TIF1- γ in 7, anti-ARS in 4, and anti-MDA5 in 2) in the childbearing age group, suggesting a possible relationship between the presence of anti-TIF1- γ antibody and pregnancy-associated DM (18). Among these 13 MSA-positive DM cases, 3 were pregnancy-associated, and 1 was cancer-associated. Furthermore, all three pregnancy-associated DM cases were positive for anti-TIF1- γ antibodies. In their study, among the three pregnancy-associated DM cases, two had IIM that developed postpartum, and one had IIM that developed during pregnancy. They speculated that overexposure to fetal TIF1- γ autoantigens, which are reportedly expressed strongly in mammalian embryos, might have contributed to the onset of PM/DM (28-30). We also found another three cases of DM that developed in the postpartum period and were MSA-positive (31-33). Among them, anti-Jo-I, anti-SRP, and anti-Mi-2 antibody were detected in one case each. Although no previous study has reported the possible relationship between anti-Mi-2 antibody and pregnancy-associated IIM, several findings on Mi-2 protein could explain this possibility. The Mi-2 β protein has been reported to be expressed in many progenitor cell types, as seen with TIF1- γ , including embryonic stem cells, hematopoietic cells, and neuronal, epithelial, and heart muscle precursors (34-40). The similarities between TIF1- γ and Mi-2 β are that both are associated with transcriptional regulatory processes, and patients with these autoantibodies are at an increased risk of malignancy (41, 42). The accumulation of further data on such cases is needed to elucidate the association between MSAs and pregnancy-associated IIM.

This is the first report of the successful treatment of PM/DM that developed during pregnancy with tacrolimus, wherein a healthy baby was delivered with planned C/S. With respect to the route of delivery in PM/DM patients, Mosca et al. suggests that planned C/S is the optimal method, given the risk of rhabdomyolysis and myoglobinuria due to the skeletal muscle damage during vaginal delivery and difficulties in completing vaginal delivery that could lead to emergent C/S due to muscle weakness (10, 43, 44). In our case, C/S was planned while considering these risks; however, fetal distress due to the umbilical cord being wrapped around the baby's neck prompted emergent C/S with the successful delivery of a healthy baby.

Conclusions

Cases of pregnancy complicated with IIM are uncommon, especially those with a new onset of IIM during pregnancy. Although the pathogenesis of pregnancy-associated IIM remains unclear, anti-Mi-2 and anti-TIF1- γ antibodies have been frequently detected in these cases. However, the number of cases that are positive for MSAs was not sufficient to investigate the associated obstetric characteristics. Since pregnancies complicated with active IIM are associated with poor fetal outcomes, clinicians should appropriately control the disease activity during pregnancy and prepare for possi-

ble C/S.

The authors state that they have no Conflict of Interest (COI).

References

- Silva CA, Sultan SM, Isenberg DA. Pregnancy outcome in adult-onset idiopathic inflammatory myopathy. *Rheumatology (Oxford)* **42**: 1168-1172, 2003.
- Fiorentino DF, Kuo K, Chung L, Zaba L, Li S, Casciola-Rosen L. Distinctive cutaneous and systemic features associated with anti-transcriptional intermediary factor-1 γ antibodies in adults with dermatomyositis. *J Am Acad Dermatol* **72**: 449-455, 2015.
- Benveniste O, Stenzel W, Allenbach Y. Advances in serological diagnostics of inflammatory myopathies. *Curr Opin Neurol* **29**: 662-673, 2016.
- Bohan A, Peter JB. Polymyositis and dermatomyositis (first of two parts). *N Engl J Med* **292**: 344-347, 1975.
- Bohan A, Peter JB. Polymyositis and dermatomyositis (second of two parts). *N Engl J Med* **292**: 403-407, 1975.
- Messina S, Fagiolari G, Lamperti C, et al. Women with pregnancy-related polymyositis and high serum CK levels in the newborn. *Neurology* **58**: 482-484, 2002.
- Park IW, Suh YJ, Han JH, et al. Dermatomyositis developing in the first trimester of pregnancy. *Korean J Intern Med* **18**: 196-198, 2003.
- Morihara K, Katoh N, Hirano S, Kishimoto S. Amyopathic dermatomyositis presenting during pregnancy. *J Am Acad Dermatol* **51**: 838-840, 2004.
- Pasrija S, Rana R, Sardana K, Trivedi SS. A case of autoimmune myopathy in pregnancy. *Indian J Med Sci* **59**: 109-112, 2005.
- Mosca M, Strigini F, Carmignani A, D'Ascanio A, Genazzani AR, Bombardieri S. Pregnant patient with dermatomyositis successfully treated with intravenous immunoglobulin therapy. *Arthritis Rheum* **53**: 119-121, 2005.
- Nozaki Y, Ikoma S, Funouchi M, Kinoshita K. Respiratory muscle weakness with dermatomyositis during pregnancy: successful treatment with intravenous immunoglobulin therapy. *J Rheumatol* **35**: 2289, 2008.
- Linardaki G, Cherouvim E, Goni G, Boki KA. Intravenous immunoglobulin treatment for pregnancy-associated dermatomyositis. *Rheumatol Int* **31**: 113-115, 2011.
- Akalin T, Akkaya H, Büke B, Koçak İ. A case of new-onset dermatomyositis in the second trimester of pregnancy: a case report and review of the literature. *Case Rep Obstet Gynecol* **2016**: 6430156, 2016.
- Awatef K, Salim G, Zahra MF. A rare case of dermatomyositis revealed during pregnancy with good outcome. *Pan Afr Med J* **23**: 117, 2016.
- Ali HS, Hassan IF, George S, Fadlelmula AE. Hypercapnic respiratory failure during pregnancy due to polymyositis-related respiratory muscle weakness: a case report. *J Med Case Rep* **11**: 203, 2017.
- Ochiai M, Sato E, Tanaka E, et al. Successful delivery in a patient with clinically amyopathic dermatomyositis during pregnancy despite first-trimester acute exacerbation of interstitial lung disease. *Mod Rheumatol* **27**: 364-368, 2017.
- Saito M, Isojima S, Miura Y, et al. Polymyositis-dermatomyositis and interstitial lung disease in pregnant woman successfully treated with cyclosporine and tapered steroid therapy. *Case Rep Rheumatol* **2019**: 4914631, 2019.
- Oya K, Inoue S, Saito A, et al. Pregnancy triggers the onset of anti-transcriptional intermediary factor 1 γ antibody-positive dermatomyositis: a case series. *Rheumatology (Oxford)* **59**: 1450-1451, 2020.

19. Vánca A, Panyi A, Constantin T, Zeher M, Dankó K. Pregnancy outcome in idiopathic inflammatory myopathy. *Rheumatol Int* **27**: 435-439, 2007.
20. Nagy-Vincze M, Vencovsky J, Lundberg IE, Dankó K. Pregnancy outcome in idiopathic inflammatory myopathy patients in a multi-center study. *J Rheumatol* **41**: 2492-2494, 2014.
21. Zhong Z, Lin F, Yang J, Zhang F, Zeng X, You X. Pregnancy in polymyositis or dermatomyositis: retrospective results from a tertiary centre in China. *Rheumatology (Oxford)* **56**: 1272-1275, 2017.
22. Pinal-Fernandez I, Selva-O'Callaghan A, Fernandez-Codina A, et al. Pregnancy in adult-onset idiopathic inflammatory myopathy: report from a cohort of myositis patients from a single center. *Semin Arthritis Rheum* **44**: 234-240, 2014.
23. Gupta L, Zanwar A, Ahmed S, Aggarwal A. Outcomes of pregnancy in women with inflammatory myositis: a retrospective cohort from India. *J Clin Rheumatol* **26**: 165-168, 2020.
24. Kolstad KD, Fiorentino D, Li S, Chakravarty EF, Chung L. Pregnancy outcomes in adult patients with dermatomyositis and polymyositis. *Semin Arthritis Rheum* **47**: 865-869, 2018.
25. Chen JS, Roberts CL, Simpson JM, March LM. Pregnancy outcomes in women with rare autoimmune diseases. *Arthritis Rheumatol* **67**: 3314-3323, 2015.
26. Kanoh H, Izumi T, Seishima M, Nojiri M, Ichiki Y, Kitajima Y. A case of dermatomyositis that developed after delivery: the involvement of pregnancy in the induction of dermatomyositis. *Br J Dermatol* **141**: 897-900, 1999.
27. Fujimoto M, Murakami A, Kurei S, et al. Enzyme-linked immunosorbent assays for detection of anti-transcriptional intermediary factor-1 gamma and anti-Mi-2 autoantibodies in dermatomyositis. *J Dermatol Sci* **84**: 272-281, 2016.
28. Yan KP, Dollé P, Mark M, et al. Molecular cloning, genomic structure, and expression analysis of the mouse transcriptional intermediary factor 1 gamma gene. *Gene* **334**: 3-13, 2004.
29. Klonisch T, Drouin R. Fetal-maternal exchange of multipotent stem/progenitor cells: microchimerism in diagnosis and disease. *Trends Mol Med* **15**: 510-518, 2009.
30. Hesling C, Lopez J, Fattet L, et al. Tif1 γ is essential for the terminal differentiation of mammary alveolar epithelial cells and for lactation through SMAD4 inhibition. *Development* **140**: 167-175, 2013.
31. Hung NA, Jackson C, Nicholson M, Highton J. Pregnancy-related polymyositis and massive perivillous fibrin deposition in the placenta: are they pathogenetically related? *Arthritis Rheum* **55**: 154-156, 2006.
32. Mateus S, Malheiro M, Santos MP, Costa R. Dermatomyositis onset in the puerperium period. *BMJ Case Rep* **2015**: bcr2015211025, 2015.
33. Ousmane C, Makhtar BE, Fatoumata B, et al. Polymyositis anti-SRP antibodies and pregnancy about 2 cases. *Pan Afr Med J* **24**: 192, 2016.
34. Yoshida T, Hazan I, Zhang J, et al. The role of the chromatin remodeler Mi-2 β in hematopoietic stem cell self-renewal and multilineage differentiation. *Genes Dev* **22**: 1174-1189, 2008.
35. Zhang J, Jackson AF, Naito T, et al. Harnessing of the nucleosome-remodeling-deacetylase complex controls lymphocyte development and prevents leukemogenesis. *Nat Immunol* **13**: 86-94, 2011.
36. Gómez-Del Arco P, Perdiguero E, Yunes-Leites PS, et al. The chromatin remodeling complex Chd4/NuRD controls striated muscle identity and metabolic homeostasis. *Cell Metab* **23**: 881-892, 2016.
37. Yoshida T, Hu Y, Zhang Z, et al. Chromatin restriction by the nucleosome remodeler Mi-2 β and functional interplay with lineage-specific transcription regulators control B-cell differentiation. *Genes Dev* **33**: 763-781, 2019.
38. Yamada T, Yang Y, Hemberg M, et al. Promoter decommissioning by the NuRD chromatin remodeling complex triggers synaptic connectivity in the mammalian brain. *Neuron* **83**: 122-134, 2014.
39. Reynolds N, Latos P, Hynes-Allen A, et al. NuRD suppresses pluripotency gene expression to promote transcriptional heterogeneity and lineage commitment. *Cell Stem Cell* **10**: 583-594, 2012.
40. Kim J, Sif S, Jones B, et al. Ikaros DNA-binding proteins direct formation of chromatin remodeling complexes in lymphocytes. *Immunity* **10**: 345-355, 1999.
41. Monseau G, Landon-Cardinal O, Stenzel W, et al. Systematic retrospective study on 64 patients anti-Mi2 dermatomyositis: a classic skin rash with a necrotizing myositis and high risk of malignancy. *J Am Acad Dermatol* **83**: 1759-1763, 2020.
42. Trallero-Araguás E, Rodrigo-Pendás J, Selva-O'Callaghan A, et al. Usefulness of anti-p155 autoantibody for diagnosing cancer-associated dermatomyositis: a systematic review and meta-analysis. *Arthritis Rheum* **64**: 523-532, 2012.
43. Abramov Y, Abramov D, Abrahamov A, Durst R, Schenker J. Elevation of serum creatine phosphokinase and its MB isoenzyme during normal labor and early puerperium. *Acta Obstet Gynecol Scand* **75**: 255-260, 1996.
44. Ditzian-Kadanoff R, Reinhard JD, Thomas C, Segal AS. Polymyositis with myoglobinuria in pregnancy: a report and review of the literature. *J Rheumatol* **15**: 513-514, 1988.

The Internal Medicine is an Open Access journal distributed under the Creative Commons Attribution-NonCommercial-NoDerivatives 4.0 International License. To view the details of this license, please visit (<https://creativecommons.org/licenses/by-nc-nd/4.0/>).