

# The impact of macroscopic on-site evaluation using filter paper in EUS-guided fine-needle biopsy

Dongwook Oh, Dong-Wan Seo, Seung-Mo Hong<sup>1</sup>, Tae Jun Song, Do Hyun Park, Sang Soo Lee, Sung Koo Lee, Myung-Hwan Kim

Departments of Gastroenterology and <sup>1</sup>Pathology, Asan Medical Center, University of Ulsan College of Medicine, Seoul, South Korea

## ABSTRACT

**Background and Objectives:** EUS-guided tissue acquisition with rapid on-site cytologic evaluation (ROSE) has been used to increase the diagnostic yield. However, ROSE is not available in many centers. To date, only a few studies have assessed the adequacy of histologic cores in macroscopic on-site evaluation (MOSE) during EUS-guided fine-needle biopsy (EUS-FNB). Blood contamination of histologic core specimens lowers the sample quality and the diagnostic yield. Therefore, we evaluated the efficacy of MOSE using filter paper to increase the adequacy of histologic core specimens while minimizing blood contamination. **Materials and Methods:** Seventy-nine consecutive patients with an intraabdominal mass underwent EUS-FNB between March 2017 and October 2018. Histologic specimens obtained using EUS-FNB were expelled onto filter paper, and the histologic procurement rate on MOSE was evaluated. **Results:** EUS-FNB using a 20-gauge Procore needle or a 22-gauge Acquire needle was successful in all patients. The mean number of needle passes was 2.8 ± 0.8. Visible histologic cores were observed in 94.9% (75/79) of the patients. Blood-contaminated specimens with scanty histologic cores were obtained in 5.1% (4/79) of the patients. On microscopic examination, 92.4% (73/79) of the histologic samples were graded as optimal. The diagnostic accuracy, sensitivity, and specificity were 94.5%, 94.3%, and 100%, respectively. Mild postprocedural adverse events occurred in 2 patients (2.5%:  $n = 1$ , transient fever;  $n = 1$ , acute pancreatitis). **Conclusions:** MOSE using filter paper provided adequate histologic samples while minimizing blood contamination. MOSE can also increase the diagnostic accuracy when ROSE is not available.

**Key words:** EUS-guided fine-needle biopsy, macroscopic on-site evaluation, rapid on-site cytologic evaluation

## INTRODUCTION

EUS-FNA has been widely used as an effective and safe method for tissue acquisition for diagnosing of gastrointestinal tumors. Histologic evaluation is prerequisite for diagnostic confirmation and for guiding

treatment. Although it has been accepted as the standard modality for sampling, the diagnostic accuracy ranges from 78% to 95%.<sup>[1]</sup> The main limitation of FNA cytology is that it does not provide information

This is an open access journal, and articles are distributed under the terms of the Creative Commons Attribution-NonCommercial-ShareAlike 4.0 License, which allows others to remix, tweak, and build upon the work non-commercially, as long as appropriate credit is given and the new creations are licensed under the identical terms.

**For reprints contact:** reprints@medknow.com

**How to cite this article:** Oh D, Seo DW, Hong SM, Song TJ, Park DH, Lee SS, *et al.* The impact of macroscopic on-site evaluation using filter paper in EUS-guided fine-needle biopsy. *Endosc Ultrasound* 2019;8:342-7.

### Access this article online

Quick Response Code:



Website:

www.eusjournal.com

DOI:

10.4103/eus.eus\_34\_19

### Address for correspondence

Dr. Dong-Wan Seo, Department of Gastroenterology, Asan Medical Center, University of Ulsan College of Medicine, 88-Olympic-Ro 43-Gil, Songpa-Gu, Seoul 05505, South Korea. E-mail: dwseoamc@amc.seoul.kr

**Received:** 2019-02-20; **Accepted:** 2019-03-15; **Published online:** 2019-07-01

on tissue architecture to allow a histopathologic diagnosis.<sup>[2]</sup>

To overcome the limitation of EUS-FNA, EUS-guided fine-needle biopsy (EUS-FNB) has been used. EUS-FNB has the advantage of providing well-preserved histologic core tissue samples, thus enabling a histologic diagnosis.<sup>[3]</sup> As obtaining adequate specimens for pathologic diagnosis during EUS-FNB is important, various methods such as use of a stylet, suction, capillary sampling, or rapid on-site cytologic evaluation (ROSE) have been applied.<sup>[4]</sup> A recent study demonstrated that because the method of handling samples is highly variable, the diagnostic accuracy is also highly variable.<sup>[5]</sup> Although ROSE can increase the diagnostic yield and reduce the number of needle passes, it is not available in many centers because of the limited financial and human resources.<sup>[6,7]</sup>

Owing to the limited availability of ROSE, macroscopic on-site evaluation (MOSE) has been used as an alternative. Although a few studies have demonstrated that MOSE can be useful when ROSE is unavailable, little is known thus far about the clinical usefulness of MOSE for EUS-FNB.<sup>[6-8]</sup> Furthermore, blood contamination of specimens during MOSE may hinder histologic interpretation. We hypothesized that as filter paper absorbs blood, it may help endosonographers in determining the adequacy of gross specimens. Therefore, we aimed to evaluate the efficacy of MOSE using filter paper during EUS-FNB for the diagnosis of intra-abdominal masses.

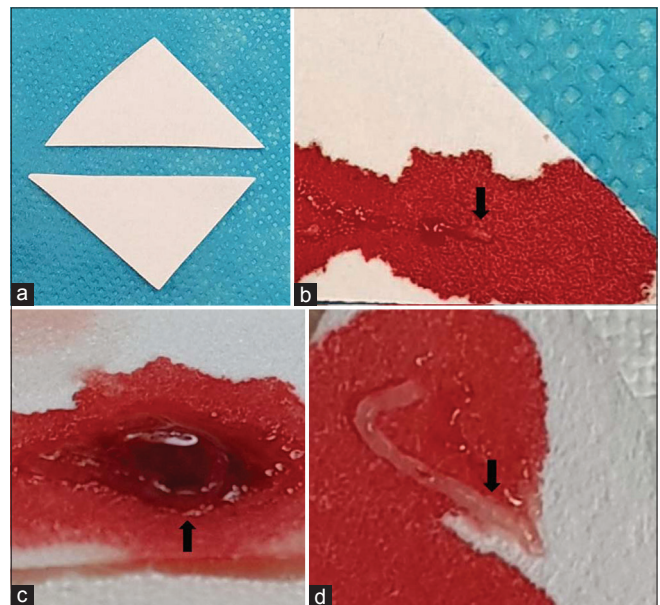
## MATERIALS AND METHODS

### Patients

Consecutive patients who underwent EUS-FNB between March 2017 and October 2018 for the diagnosis of an intra-abdominal mass were included in this study. All patients were aged >20 years and had a solid mass lesion detected on imaging studies (*i.e.*, ultrasound or computed tomography). None of the patients were given antiplatelet agents 5 days before EUS-FNB. The exclusion criteria of this study were as follows: (1) age <20 years, (2) pregnancy, or (3) severe coagulopathy (international normalized ratio >1.5) or thrombocytopenia (platelet count <50,000). All patients provided informed consent for participation in the study. This study was approved by the Institutional Review Board of Asian Medical Center (approval no. 2019-0077).

### EUS-guided fine-needle biopsy procedures

EUS-FNB was performed by an experienced endosonographer (D.W.S.). With patients under conscious sedation with intravenous midazolam and meperidine, all procedures were performed using a conventional linear array echoendoscope (GF-UCT 260; Olympus Optical, Tokyo, Japan). In this study, a 20-gauge needle (EchoTip Procore; Cook Endoscopy, Winston-Salem, NC, USA) and a 22-gauge needle (Acquire; Boston Scientific, Natick, MA, USA) were used for tissue acquisition from March 2017 to January 2018 and from February 2018 onward, respectively. After a careful EUS evaluation of the target lesion, including regional vasculature assessment with real-time Doppler, FNB was performed either from the stomach or duodenum. The needle was inserted into the target tissue under EUS guidance. Once the lesion was penetrated, the stylet was removed. Specimens were obtained by moving the needle back and forth within the lesion while applying negative pressure using a 10-mL syringe. When the specimen obtained by the first pass showed blood clots, the capillary sampling method was applied for tissue acquisition. The suction was released before removing the needle. Biopsy specimens were expelled onto a small piece of filter paper by reinserting the stylet. Blood clots were absorbed by the filter paper [Figure 1]. The material on filter paper was then carefully inspected for the presence of



**Figure 1.** Macroscopic on-site examination of specimens from EUS-guided fine-needle biopsy. (a) Filter paper for specimen processing. (b) Scanty tissue core mainly with blood clots. (c) Visible tissue core with moderate blood clots. (d) Definite visible tissue core with scanty blood clots

visible cores. A visible core was defined as a whitish piece of tissue with apparent bulk. Visible cores were collected and placed on a small piece of filter paper.<sup>[9]</sup> The cores on the filter paper were then placed in formalin solution for histologic examination. The biopsy procedure was repeated until enough specimens were obtained, as determined with MOSE. The patients were observed for immediate complications for 1 h in the recovery room.

### *Histopathologic examination*

As ROSE was not available during the procedure, sample processing was performed by the endosonographer. The core samples were macroscopically assessed as follows: (1) definite visible tissue core with scanty blood clots, (2) visible tissue core with moderate blood clots, or (3) scanty tissue core with mainly blood clots.<sup>[10]</sup> The first two types were considered the optimal samples on MOSE. Histologic examinations were then performed by experienced pathologists. The obtained tissue samples were fixed in formalin and embedded in paraffin. A paraffin block was cut into serial sections and stained with hematoxylin and eosin. Samples with tissue cores were pathologically graded as either optimal or suboptimal, *i.e.*, optimal if the material allowed satisfactory histologic architecture assessment and immunohistochemical evaluation and suboptimal if the core sample was inadequate for these assessments.<sup>[10]</sup>

A definite diagnosis was made on the basis of one of the following reference methods: (1) a definite benign or malignant histologic diagnosis was made using surgically resected specimens; (2) in patients with a definite proof of unresectable malignancy on imaging findings, histologic diagnosis was made in the presence of compatible clinical findings; and (3) in patients with benign disease, the diagnosis was made on the basis of negative FNB results for malignancy with a lack of deterioration or spontaneous resolution based on imaging findings for a minimum clinical follow-up of 6 months.<sup>[11]</sup>

### *Outcome measurements*

In the present study, the procurement rate of histologic cores on MOSE was primarily evaluated. A histologic core was defined as an intact piece of tissue with sufficiently preserved histologic architecture for further evaluation by pathologists.<sup>[12]</sup> The efficacy of EUS-FNB in diagnosing tumors was determined by calculating its sensitivity, specificity, and diagnostic accuracy. Technical

success, histopathologic sample adequacy, number of needle passes required to reach a diagnosis, and procedural adverse events were evaluated. Procedural adverse events were evaluated according to American Society for Gastrointestinal Endoscopy workshop reports.<sup>[13]</sup>

### *Statistical analysis*

Statistical analysis was performed using SPSS Statistics version 22.0 (SPSS Inc., Chicago, IL, USA). The results were expressed as mean and standard deviation. Categorical variables were compared using the Fisher's exact test. Continuous parameters were compared using the *t*-test or the Mann–Whitney *U*-test.  $P \leq 0.05$  was considered statistically significant.

## RESULTS

### *Baseline characteristics*

A total of 79 patients (40 men and 39 women; mean age,  $58.6 \pm 10.3$  years) who underwent EUS-FNB for the diagnosis of an intra-abdominal mass were enrolled in this study. The baseline characteristics of the patients and target lesions are summarized in Table 1. The main indication for EUS-FNB was a suspicion of malignant lesions (57%, 45/79), followed by benign lesions (30.4%, 24/79) and indeterminate lesions (12.7%, 10/79). Sixty (75.9%) of the obtained lesions were from the pancreas and 19 (24.1%) were extrapancreatic lesions.

### *Outcomes of EUS-guided fine-needle biopsy*

The procedural and histopathologic outcomes are presented in Tables 2 and 3. Tissue acquisition was successful in all patients (100%, 79/79). The mean size of the target lesions was  $28.6 \pm 14.5$  mm. A 22-gauge needle was mainly used for EUS-FNB (64.6%, 51/79). The suction method was applied in 70 cases of EUS-FNB.

The transgastric approach of EUS-FNB (59.5%) was more commonly used than the transduodenal approach (40.5%). The mean number of needle passes was  $2.8 \pm 0.8$ . Procedural adverse events, including transient fever ( $n = 1$ ) and acute pancreatitis ( $n = 1$ ), occurred in two patients, who completely recovered after conservative treatment.

On MOSE, visible cores were identified in 75 of 79 patients (94.9%). Among the patients, a definite visible tissue core with scanty blood clots and a visible

**Table 1. Baseline characteristics of the patients and target lesions**

Characteristics	Total (n=79)
Age, mean (SD), years	58.6 (10.3)
Male, n (%)	40 (50.6)
Indication for EUS-FNB, n (%)	
Benign lesion	24 (30.4)
Malignant lesion	45 (57)
Indeterminate lesion	10 (12.7)
Lesion location, n (%)	
Pancreas	60 (75.9)
Lymph node	7 (8.9)
Liver	5 (6.3)
Left adrenal gland	4 (5.1)
Common bile duct	1 (1.3)
Gallbladder	1 (1.3)
Stomach	1 (1.3)
Final diagnosis, n (%)	
Benign	34 (43)
Chronic pancreatitis	9
Solid pseudopapillary neoplasm	9
Pancreatic neuroendocrine tumor	8
Serous cystic neoplasm	3
Autoimmune pancreatitis	2
Gastrointestinal tumor	1
Schwannoma	1
Adrenal adenoma	1
Malignant	45 (57)
Pancreatic adenocarcinoma	26
Metastatic cancer	6
Cholangiocarcinoma	3
Lymphoma	3
Hepatocellular carcinoma	2
Gallbladder cancer	2
Sarcoma	2
Neuroendocrine carcinoma	1

SD: Standard deviation, EUS-FNB: EUS-guided fine needle biopsy

**Table 2. Procedural outcomes of EUS-FNB**

Characteristics	Total (n=79)
Technical success, n (%)	79 (100%)
Size of target lesions on EUS, mean (SD), mm	28.6 (14.5)
Type of needle, n (%)	
20-gauge procure needle	28 (35.4)
22-gauge acquire needle	51 (64.6)
Echoendoscope position during FNB, n (%)	
Trans-gastric	47 (59.5)
Trans-duodenal	32 (40.5)
Specimen acquisition method, n (%)	
Suction method	70 (88.6)
Capillary sampling method	9 (11.4)
Number of needle passes, mean (SD)	2.8 (0.84)
Procedural adverse events, n (%)	2 (2.5)
Transient fever	1 (1.3)
Pancreatitis	1 (1.3)

EUS-FNB: EUS-guided fine needle biopsy, SD: Standard deviation

tissue core with moderate blood clots were observed in 88.6% (70/79) and 6.3% (5/79), respectively. Blood-contaminated specimens were obtained in 5.1% (4/79) of the cases.

Seventy-three samples (92.4%) were pathologically graded as optimal. Two cases of serous cystic neoplasm were considered optimal on MOSE but were revealed to be suboptimal on histopathologic examination. The diagnostic accuracy, sensitivity, and specificity were 94.5%, 94.3%, and 100%, respectively.

## DISCUSSION

In the present study, we evaluated the procurement rate of histologic cores on MOSE using filter paper during EUS-FNB and the diagnostic accuracy. EUS-FNB was successful in all patients. Visual inspection of the specimen expelled on filter paper provided adequate histologic samples while minimizing blood contamination in the absence of ROSE (94.9%, 75/79). The diagnostic accuracy of EUS-FNB was 94.5%. The results of our analyses showed that gross identification of histologic cores using filter paper was associated with a high diagnostic yield.

EUS-FNA has been the standard method for obtaining samples from gastrointestinal tumors. Although EUS-FNA has been shown to be effective and safe for sampling, its diagnostic accuracy is highly variable, ranging from 78% to 95%, in patients with solid pancreatic tumors.<sup>[1]</sup> Furthermore, the diagnostic accuracy for extrapancreatic lesions is lower.<sup>[14]</sup> To overcome these limitations, ROSE has been applied during EUS-FNA. Several studies have demonstrated that ROSE during EUS-FNA is significantly associated with a higher diagnostic accuracy and a fewer number of needle passes.<sup>[15,16]</sup> Rapid determination by endosonographers of the adequacy of the obtained sample may prevent the need for repeat procedures. Fewer needle passes may reduce potential procedure-related adverse events.<sup>[7]</sup> However, ROSE during EUS-FNA is not available in all institutes. According to a recent survey, ROSE was available for 48% of responders from Europe and 55% of responders from Asia.<sup>[5,14]</sup> Another major limitation of EUS-FNA is its inability to obtain histologic core tissue. Obtaining adequate histologic core specimens is important in the diagnosis of not only certain tumors such as neuroendocrine tumors and lymphoma but also benign diseases such as autoimmune pancreatitis.<sup>[17]</sup> In

**Table 3. Histopathologic outcomes and diagnostic performance of EUS-FNB**

Characteristics	Total (n=79)
Presence of visible core on MOSE, n (%)	75 (94.9)
Definite visible tissue core with scanty blood clots	70 (88.6)
Visible tissue core with moderate blood clots	5 (6.3)
Scanty tissue core mainly with blood clots	4 (5.1)
Histopathologic sample adequacy, n (%)	73 (92.4)
Diagnostic accuracy (%)	94.5
Sensitivity (%), 95% CI	94.3 (86-98.4)
Specificity (%), 95% CI	100 (66.4-100)

EUS-FNB: EUS-guided fine needle biopsy, MOSE: Macroscopic on-site evaluation, CI: Confidence interval

addition, ROSE also increases the costs and procedure time.<sup>[17]</sup>

Recently, EUS-FNB has been adopted for tissue sampling to overcome the disadvantages of EUS-FNA including limited diagnostic accuracy, suboptimal histologic cores for molecular profiling, and morphologic characterization.<sup>[18]</sup> Considering the limited availability of ROSE, MOSE has been used to determine the adequacy of histologic core specimens obtained using EUS-FNB. In a study by Iwashita *et al.*,<sup>[7]</sup> a visible histologic core of  $\geq 4$  mm length, which was obtained using EUS-FNA with a 19-gauge needle, was associated with a higher diagnostic yield. In a more recent study by Ishiwatari *et al.*,<sup>[8]</sup> MOSE performed by endosonographers during EUS-FNA with a 22-gauge needle was also demonstrated to predict the correct diagnosis when ROSE was not available. In most studies on MOSE, the specimen was expelled onto a glass slide or plate.<sup>[6-8]</sup> Therefore, there is a possible risk of blood contamination. In the present study, we expelled the specimen on filter paper to absorb blood. Histologic cores were identified in 94.9% (75/79) of the MOSE cases. On gross visual inspection of the obtained histologic specimen expressed on filter paper, a definite visible core was observed in 88.6% (70/79) of the cases. Among the specimens obtained using EUS-FNB, 5.1% (4/79) showed blood contamination. The obtained visible core was optimal for histologic examination in 92.4% (73/79) of the cases. Our results showed that the use of filter paper could reduce blood contamination and may increase the sample quality. As many centers do not have on-site pathologists, macroscopic visual assessment of a specimen by an endosonographer can be helpful to ensure the adequacy of histologic tissue cores.

However, the sampling method, such as the use of suction or capillary sampling, during EUS-FNB has

not been standardized. EUS-guided sampling with suction has been reported to have a high risk of blood contamination, which might decrease the sample quality.<sup>[19]</sup> On the other hand, capillary sampling may yield better diagnostic accuracy with reduced blood contamination.<sup>[20]</sup> However, the impact of suction or capillary sampling has not been fully evaluated and remains uncertain. The current guideline recommends EUS-guided sampling with suction.<sup>[14]</sup> In our study, most (88.6%, 70/79) of the samples were obtained using the suction method during EUS-FNB. Although applying suction during EUS-FNB has a possible risk of blood contamination of the samples, the use of filter paper, which absorbs blood, may minimize the blood contamination risk. Further prospective comparative studies are warranted to evaluate the efficacy of filter paper.

A more important point is that MOSE during EUS-FNB significantly improves diagnostic accuracy. Recently, dedicated FNB needles have been developed for histologic sample procurement. Several studies have reported that EUS-FNB using dedicated needles showed high diagnostic accuracy ranging from 87% to 98%.<sup>[10,21-23]</sup> In this study, EUS-FNB was performed using two dedicated FNB needles (20-gauge Procore and 22-gauge Acquire). The diagnostic accuracy of EUS-FNB without ROSE was 94.5%. Considering that the present study showed results similar to those of other reports, our study supports the view that EUS-FNB using dedicated core needles without ROSE can replace EUS-FNA with ROSE in terms of optimal histologic procurement and diagnostic accuracy. In a recent study by Rodrigues-Pinto *et al.*, EUS-FNB without ROSE using a dedicated core needle showed similar diagnostic efficacy as EUS-FNA with ROSE.<sup>[24]</sup> Although EUS-FNB showed a high diagnostic yield, the diagnostic yield was different for each needle pass. Furthermore, the optimal number of needle passes for obtaining appropriate histologic cores has not been standardized, and fewer passes were associated with suboptimal performance. Depending on the type of tissue and the extent of necrotic portion in the target lesions, the histologic procurement rate may also be reduced. In a more recent study by Leung Ki *et al.*,<sup>[25]</sup> MOSE was reported to reduce the number of needle passes by accurately estimating the histologic core. Our results also support the view that gross visual inspection for the presence of a histologic core is associated with a significantly higher diagnostic performance. Gross visual inspection of histologic cores on filter paper

may be a reliable method for the identification of histologic cores of optimal quality; therefore, it could be associated with a higher diagnostic performance with fewer needle passes.

The present study has several limitations. First, EUS-FNB was performed by an experienced endosonographer at tertiary referral centers. Therefore, the results may not be generalized to less experienced endosonographers. Second, considering the use of dedicated FNB needles, tissue acquisition may be different when using different types of needles. This single-arm study used prospectively collected and retrospectively analyzed data. A prospective randomized trial that compares EUS-FNB with or without filter paper may be warranted to confirm our results.

## CONCLUSIONS

MOSE using filter paper could be used to identify visible histologic cores and reduce blood contamination. It may also predict the adequacy of histologic specimens and is associated with a higher diagnostic accuracy when ROSE is not available.

*Financial support and sponsorship*  
Nil.

## Conflicts of interest

There are no conflicts of interest.

## REFERENCES

- Itoi T, Sofuni A, Itokawa F, et al. Current status of diagnostic endoscopic ultrasonography in the evaluation of pancreatic mass lesions. *Dig Endosc* 2011;23 Suppl 1:17-21.
- Majumder S, Chari ST. EUS-guided FNA for diagnosing autoimmune pancreatitis: Does it enhance existing consensus criteria? *Gastrointest Endosc* 2016;84:805-7.
- Levy MJ, Wiersema MJ. EUS-guided trucut biopsy. *Gastrointest Endosc* 2005;62:417-26.
- Wani S, Muthusamy VR, Komanduri S. EUS-guided tissue acquisition: An evidence-based approach (with videos). *Gastrointest Endosc* 2014;80:939-59.
- van Riet PA, Cahen DL, Poley JW, et al. Mapping international practice patterns in EUS-guided tissue sampling: Outcome of a global survey. *Endosc Int Open* 2016;4:E360-70.
- Nguyen YP, Maple JT, Zhang Q, et al. Reliability of gross visual assessment of specimen adequacy during EUS-guided FNA of pancreatic masses. *Gastrointest Endosc* 2009;69:1264-70.
- Iwashita T, Yasuda I, Mukai T, et al. Macroscopic on-site quality evaluation of biopsy specimens to improve the diagnostic accuracy during EUS-guided FNA using a 19-gauge needle for solid lesions: A single-center prospective pilot study (MOSE study). *Gastrointest Endosc* 2015;81:177-85.
- Ishiwatari H, Sato J, Fujie S, et al. Gross visual inspection by endosonographers during endoscopic ultrasound-guided fine needle aspiration. *Pancreatol* 2019;19:191-5.
- Iwashita T, Nakai Y, Samarasekera JB, et al. High single-pass diagnostic yield of a new 25-gauge core biopsy needle for EUS-guided FNA biopsy in solid pancreatic lesions. *Gastrointest Endosc* 2013;77:909-15.
- Kim DH, Kim GH, Cho CM, et al. Feasibility of a 20-gauge proCore needle in EUS-guided subepithelial tumor sampling: A prospective multicenter study. *BMC Gastroenterol* 2018;18:151.
- Iglesias-Garcia J, Poley JW, Larghi A, et al. Feasibility and yield of a new EUS histology needle: Results from a multicenter, pooled, cohort study. *Gastrointest Endosc* 2011;73:1189-96.
- Bang JY, Hebert-Magee S, Trevino J, et al. Randomized trial comparing the 22-gauge aspiration and 22-gauge biopsy needles for EUS-guided sampling of solid pancreatic mass lesions. *Gastrointest Endosc* 2012;76:321-7.
- Cotton PB, Eisen GM, Aabakken L, et al. A lexicon for endoscopic adverse events: Report of an ASGE workshop. *Gastrointest Endosc* 2010;71:446-54.
- Polkowski M, Jenssen C, Kaye P, et al. Technical aspects of endoscopic ultrasound (EUS)-guided sampling in gastroenterology: European Society of Gastrointestinal Endoscopy (ESGE) technical guideline – March 2017. *Endoscopy* 2017;49:989-1006.
- Nasuti JF, Gupta PK, Baloch ZW. Diagnostic value and cost-effectiveness of on-site evaluation of fine-needle aspiration specimens: Review of 5,688 cases. *Diagn Cytopathol* 2002;27:1-4.
- Hayashi T, Ishiwatari H, Yoshida M, et al. Rapid on-site evaluation by endosonographer during endoscopic ultrasound-guided fine needle aspiration for pancreatic solid masses. *J Gastroenterol Hepatol* 2013;28:656-63.
- Khan MA, Grimm IS, Ali B, et al. A meta-analysis of endoscopic ultrasound-fine-needle aspiration compared to endoscopic ultrasound-fine-needle biopsy: Diagnostic yield and the value of onsite cytopathological assessment. *Endosc Int Open* 2017;5:E363-75.
- Bang JY, Hebert-Magee S, Navaneethan U, et al. EUS-guided fine needle biopsy of pancreatic masses can yield true histology. *Gut* 2018;67:2081-4.
- Wallace MB, Kennedy T, Durkalski V, et al. Randomized controlled trial of EUS-guided fine needle aspiration techniques for the detection of malignant lymphadenopathy. *Gastrointest Endosc* 2001;54:441-7.
- Paik WH, Park Y, Park DH, et al. Prospective evaluation of new 22 gauge endoscopic ultrasound core needle using capillary sampling with stylet slow-pull technique for intra-abdominal solid masses. *J Clin Gastroenterol* 2015;49:199-205.
- van Riet PA, Larghi A, Attili F, et al. A multicenter randomized trial comparing a 25-gauge EUS fine-needle aspiration device with a 20-gauge EUS fine-needle biopsy device. *Gastrointest Endosc* 2019;89:329-39.
- Bang JY, Hebert-Magee S, Hasan MK, et al. Endoscopic ultrasonography-guided biopsy using a Franseen needle design: Initial assessment. *Dig Endosc* 2017;29:338-46.
- Mitri RD, Rimbaş M, Attili F, et al. Performance of a new needle for endoscopic ultrasound-guided fine-needle biopsy in patients with pancreatic solid lesions: A retrospective multicenter study. *Endosc Ultrasound* 2018;7:329-34.
- Rodrigues-Pinto E, Jalaj S, Grimm IS, et al. Impact of EUS-guided fine-needle biopsy sampling with a new core needle on the need for onsite cytopathologic assessment: A preliminary study. *Gastrointest Endosc* 2016;84:1040-6.
- Leung Ki EL, Lemaistre AI, Fumex F, et al. Macroscopic onsite evaluation using endoscopic ultrasound fine needle biopsy as an alternative to rapid onsite evaluation. *Endosc Int Open* 2019;7:E189-94.