




# Acute Groin Pain Syndrome Due to Internal Obturator Muscle Injury in a Professional Football Player

Gian N. Bisciotti<sup>1</sup>  Alessandro Corsini<sup>2</sup> Emanuele Cena<sup>1</sup> Andrea N. Bisciotti<sup>3</sup> Alessandro L. Bisciotti<sup>3</sup>  
Andrea Belli<sup>2</sup> Piero Volpi<sup>2,3,4</sup>

<sup>1</sup> NSMP Department, Qatar Orthopaedic and Sport Medicine Hospital, Doha, Qatar

<sup>2</sup> Viale dello Sport, FC Internazionale, Milano, Italy

<sup>3</sup> Centro Studi Kinemove Rehabilitation Centers, Pontremoli, Italy

<sup>4</sup> Istituto Clinico Humanitas, Milano, Italy

**Address for correspondence** Gian N. Bisciotti, MSc, PhD, Centro Studi Kinemove Rehabilitation Centers, Via Veterani dello Sport, 54027 Pontremoli (MS), Italy (e-mail: giannicola.bisciotti@aspetar.com).

Joints 2019;7:205–208.

## Abstract

### Keywords

- ▶ internal obturator
- ▶ indirect lesion
- ▶ groin pain syndrome
- ▶ treatment

Traumatic groin pain syndrome is the result of an acute trauma, usually an indirect muscle injury (i.e., an overstretching of the muscle fibers). The most affected muscles in traumatic groin pain syndrome are rectus abdominis, adductors, and iliopsoas. The internal obturator muscle lesion is very rare. The internal obturator muscle externally rotates the thigh and contributes to the stabilization of the hip joint and its indirect injury may cause the onset of traumatic groin pain syndrome. This case report describes a rare indirect injury of internal obturator in a 29-year-old professional male soccer player.

## Introduction

Groin pain syndrome (GPS) is an important and wide cause of disability both in professional and amateurs athletes and is relatively frequent in sport requiring quick accelerations and decelerations, changes of direction, and kicking.<sup>1</sup> In a soccer team, 21% of players experienced GPS during each season.<sup>2</sup> GPS as proposed by the “Groin Pain Syndrome Italian Consensus Conference on Terminology, the Clinical Evaluation and Imaging Assessment in Groin Pain in Athletics”<sup>3</sup> can be defined as “Any clinical symptom reported by the patient, located at the inguinal-pubic-adductor area, affecting sports activities and/or interfering with Activities of Daily Living and requiring medical attention.”

GPS can also be divided into three main categories. The first category is represented by the GPS of traumatic origin in which the onset of pain was due to any acute trauma, and this

hypothesis is supported by medical history, clinical examination, and imaging. The second category is represented by the GPS due to functional overload, characterized by insidious and progressive onset, without an acute trauma or a situation to which the onset of pain symptoms can be attributed with certainty. Finally, the third category is represented by the long-standing GPS or chronic GPS in which the cohort of symptoms reported by the patient continues for a long period (over 12 weeks) and is recalcitrant to any conservative therapy.

Traumatic GPS is generally the consequence of an acute indirect muscle-tendon injury. The most affected muscle groups in traumatic GPS are rectus abdominis, adductors, and iliopsoas muscles.<sup>3</sup> The internal obturator (IO) muscle lesion is very rare, and to our knowledge, there are only six studies concerning IO injuries in literature.<sup>4–9</sup> This study is presented as a case of a traumatic GPS caused by an indirect injury at the level of IO in a professional soccer player.

received  
December 29, 2017  
accepted  
April 18, 2021  
published online  
June 22, 2021

DOI <https://doi.org/10.1055/s-0041-1730976>.  
ISSN 2282-4324.

© 2021. The Author(s).

This is an open access article published by Thieme under the terms of the Creative Commons Attribution-NonDerivative-NonCommercial-License, permitting copying and reproduction so long as the original work is given appropriate credit. Contents may not be used for commercial purposes, or adapted, remixed, transformed or built upon. (<https://creativecommons.org/licenses/by-nc-nd/4.0/>)

Georg Thieme Verlag KG, Rüdigerstraße 14, 70469 Stuttgart, Germany

## Case Presentation

A 29-year-old professional male soccer comes to our clinical evaluation complaining GPS at the anterior level of the left hip that radiated obliquely and medially downward. The patient referred the onset of pain to a violent hip intra-rotation movement, with hip and knee flexed at approximately 90 degrees during a training session 5 days earlier. Passive internal rotation maneuvers with and without muscle opposition at 90 degrees of knee flexion caused pain (visual analog scale [VAS] score: 6/10). Examination of magnetic resonance imaging (MRI; ► **Fig. 1**) showed a grade I° lesion (LMIn I°), according to the classification proposed by the Italian Consensus Conference on guidelines for conservative treatment on lower limb muscle injuries in athletes<sup>3</sup> at the left internal obturator level. The patient was assigned to a rehabilitation path that included three phases<sup>3</sup> that are briefed hereinafter.

### Phase I (5 Days)

The first phase was focused on pain control and mobilization. In this phase, isometric exercises with progressive intensity increasing and hydrokinesitherapy were introduced.

### Phase II (7 Days)

The transition criteria between phases I and II were based on both the clinical assessment and the imaging examination.<sup>3</sup> The clinical criteria adopted were the absence of pain during maximum isometric contraction, no pain during both passive stretching and active stretching tests, and the reaching of full range of motion of the hip joint. The imaging criteria used were the decrease of the lesion gap and the presence of granulation repair tissue within the lesion gap at MRI examination. During the second phase active and passive stretching, concentric exercises with progressive intensity increasing, and proprioceptive training were introduced. Furthermore, in this phase straight run with progressive speed increasing was also introduced.

### Phase III (7 Days)

The transition criteria between the phases II and III were still based on the clinical assessment and the imaging examination.<sup>3</sup> The clinical criteria used were no pain during both maximal concentric contractions and submaximal eccentric

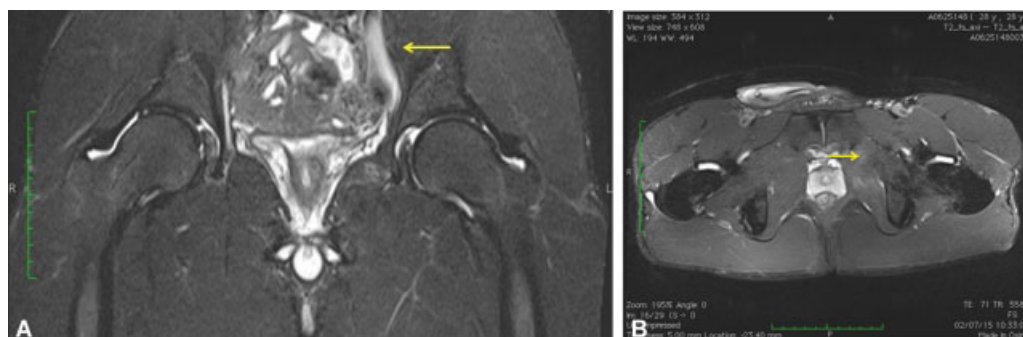
contractions. The imaging criteria adopted were the disappearance of the lesion gap and the presence of compact granulation repair tissue within the lesion gap in MRI examination. During this last phase eccentric exercises with progressive increased intensity, run whit cutting movements at progressive speed, and football individual technique exercises were introduced. At the same time, in this phase, a progressive integration with the team was introduced.

About 1 year after the injury, no reinjury occurred and the patient is fully satisfied of the rehabilitation path.

## Discussion

IO is a flat-muscle triangular-shaped part of the hip extra-rotator muscles. It originates from the inner surface of the obturator membrane and the surrounding bony margins of the obturator foramen. Its muscular bands converge posteriorly, then pass the ischial foramen to become extra pelvic and to give origin to a tendon that moves forward. Finally, IO enters into the medial surface of the great trochanter in front and above respect to the trochanteric pit. At the level of its distal insertion, the IO blends with the tendon of the gemelli muscles (triceps coxae), forming a common tendon.<sup>10</sup> This anatomical association with the gemelli tendon can explain the lower injuries that the IO shows in comparison to the external obturator muscle.<sup>9</sup> The IO extra rotates the thigh by abducting it when the hip and the leg are flexed, acting as a stabilizer of the hip joint. It is innervated by the obturator nerve (L5 and S2) and its blood supply depends on obturator artery. The IO maximum strength depends on the flexion degree of the hip joint and is maximal at the beginning of the oscillation phase during the run stride.<sup>11</sup> In addition to the IO, the other muscles working as hip external rotators are piriformis, external obturator, gemelli, and quadratus femoris. These muscles are known under the collective name of “short lateral rotators.”<sup>12</sup> This muscle group performs a major hip-joint stabilizing action, stabilizing the femoral head within the acetabulum during hip movements.<sup>10</sup> Despite the important work done by this muscle group, little is found in the literature.

The studies present in literature mainly describe chronic syndromes such as piriformis syndrome or ischial-femoral impingent<sup>13</sup> and only a few studies are based on acute



**Fig. 1** Coronal STIR magnetic resonance imaging (MRI) imaging (A) and axial T2 MRI imaging (B) showing a grade I° lesion (LMIn I°) at the left internal obturator level. STIR, short tau inversion recovery.

**Table 1** Synthesis of the studies present in literature focused on internal obturator acute indirect injuries

Study (year)	Study design	Evidence level	Participants	Study setting	Injury etiology	Diagnosis	Type of treatment	Time loss injury	Outcome
Wong-On et al <sup>9</sup> (2018)	Retrospective observational study	IV	16	Professional soccer players. Average age was 25.5 ± 5.0 (range: 18–36) years The study was focused on both internal and external obturator injury	Unstable change of direction trying to control the ball: 4 Anterior or lateral hip slide in an unstable position: 2 Repetitive ball kicking: 2 Kicking the ball in an unstable position: 2 Not clear: 6 No differentiated between internal and external obturator	Clinical assessment and imaging (MRI)	Conservative	11.5 ± 8.8 days. Not differentiated between internal and external obturator	Positive. Not differentiated between internal and external obturator
Byrne et al <sup>7</sup> (2016)	Case report	IV	1	28-year-old male Gaelic football player (level not specified)	Twisting movement in competition	Clinical assessment and imaging (MRI)	Conservative	3 weeks	Positive
Kelm et al <sup>6</sup> (2016)	Case report	IV	1	28-year-old male professional soccer player	During a header in competition	Clinical assessment and imaging (MRI)	Conservative	3 days	Positive
Velleman et al <sup>8</sup> (2015)	Case report	IV	1	28-year-old male professional rugby player	During a fall in competition	Clinical assessment and imaging (MRI)	Conservative	14 days	Positive
Khodaei et al <sup>5</sup> (2015)	Case report	IV	1	14-year-old male amateur football player	During a bending movement in competition	Clinical assessment and imaging (MRI)	Conservative	6 weeks	Positive
Busfield Romero <sup>4</sup> (2009)	Case report	IV	1	13-year-old male amateur soccer player	During a kicking ball movement. Not specified if in training or in competition	Clinical assessment and imaging (MRI)	Conservative	6 weeks	Positive

Abbreviation: MRI, magnetic resonance imaging.

injuries. In particular, to our knowledge, only six studies are present in literature focusing on IO acute indirect injuries of which five are constituted by case reports<sup>4–8</sup> and one is a retrospective observational study.<sup>9</sup> A synthesis of the studies is showed in ► **Table 1**. All the case reports are focused on IO acute indirect injuries as follows: the first case report<sup>4</sup> describes an indirect IO injury in a 13-year-old male amateur soccer player, the second<sup>5</sup> in a young American football player, the third<sup>6</sup> in a professional football player, the fourth<sup>7</sup> in a 28 year-old male Gaelic football player, and the last one<sup>8</sup> in a 28 year-old male professional rugby player. The retrospective observational study<sup>9</sup> reports injury data recorded in four seasons in the professional Spanish football league (La Liga). During the considered period, the external obturator recorded injuries were 12, while the IO injuries were reported only in 4.

In any case, it should be emphasized that the clinical diagnosis of IO injury presents some objective difficulties. Indeed IO-related lesion usually causes painful symptoms at the anterior hip-joint level. For this reason, IO injuries are in differential diagnosis with many other clinical frameworks causing GPS. The differential diagnosis to consider are piriformis syndrome femoroacetabular impingement, hip-joint labral tear, rectus femoris tear, iliopsoas-related GPS, adductor-related GPS, inguinal-related GPS, and pubic-related GPS.<sup>3,14,15</sup>

The most reliable clinical test for IO injury is the passive internal rotation maneuver with and without muscle opposition by the patient.<sup>6,7</sup> Despite the fact that in general hip extrarotatory muscle lesions and those of the IO in particular represent a rare occurrence,<sup>6,7</sup> these latter must necessarily be considered in clinical evaluation of a traumatic GPS framework.

The main mechanisms causing traumatic injury to the IO are essentially three: the first is an unstable pelvis position with a sudden change in body weight distribution;<sup>9,16</sup> the second is a sudden change of direction in condition of pelvic instability;<sup>9,16</sup> and, finally, the third, which represents the etiopathogenetic situation described in this study, is represented by a sudden hip intrarotation with hip and knee flexed at approximately 90 degrees.<sup>17</sup> The fact that reinjuries of the IO are not described in literature,<sup>9</sup> it confirms the hypothesis that these latter are dependent on a well-defined mechanical situation, such those above described, and are independent of predisposing intrinsic factors such as excessive retraction or stiffness of the IO.<sup>9</sup> The case presented in this study shows, in line with other studies, that the IO injuries present a good prognosis and a relatively short recovery time.<sup>7,9</sup>

## Conclusion

The IO lesions represent the rarest lesions among the hip external rotators muscle group which shows a very low incidence of lesion. Despite their low incidence, they must

be considered in the case of a traumatic GPS framework. The IO injury etiopathogenesis is linked to well-defined mechanical situations and would seem independent from intrinsic factors. In any case, IO injuries show a good prognosis and relatively short recovery times.

### Conflict of Interest

None declared.

## References

- Macintyre J, Johnson C, Schroeder EL. Groin pain in athletes. *Curr Sports Med Rep* 2006;5(06):293–299
- Mosler AB, Weir A, Eirale C, et al. Epidemiology of time loss groin injuries in a men's professional football league: a 2-year prospective study of 17 clubs and 606 players. *Br J Sports Med* 2018;52(05):292–297
- Bisciotti GN, Volpi P, Zini R, et al. Groin Pain Syndrome Italian Consensus Conference on terminology, clinical evaluation and imaging assessment in groin pain in athlete. *BMJ Open Sport Exerc Med* 2016;2(01):e000142
- Busfield BT, Romero DM. Obturator internus strain in the hip of an adolescent athlete. *Am J Orthop* 2009;38(11):588–589
- Khodae M, Jones D, Spittler J. Obturator internus and obturator externus strain in a high school quarterback. *Asian J Sports Med* 2015;6(03):e23481
- Kelm J, Ludwig O, Schneider G, Hopp S. Injury of the obturator internus muscle – a rare differential diagnosis in a soccer player] (*in German*). *Sportverletz Sportschaden* 2016;30(01):50–53
- Byrne C, Alkhatat A, O'Neill P, Eustace S, Kavanagh E. Obturator internus muscle strains. *Radiol Case Rep* 2016;12(01):130–132
- Velleman MD, Jansen Van Rensburg A, Janse Van Rensburg DC, Strauss O. Acute obturator internus muscle strain in a rugby player: a case report. *J Sports Med Phys Fitness* 2015;55(12):1544–1546
- Wong-On M, Turmo-Garuz A, Arriaza R, et al. Injuries of the obturator muscles in professional soccer players. *Knee Surg Sports Traumatol Arthrosc* 2018;26(07):1936–1942
- Yoo S, Dedova I, Pather N. An appraisal of the short lateral rotators of the hip joint. *Clin Anat* 2015;28(06):800–812
- Solomon LB, Lee YC, Callary SA, Beck M, Howie DW. Anatomy of piriformis, obturator internus and obturator externus: implications for the posterior surgical approach to the hip. *J Bone Joint Surg Br* 2010;92(09):1317–1324
- Gudena R, Alzahrani A, Railton P, Powell J, Ganz R. The anatomy and function of the obturator externus. *Hip Int* 2015;25(05):424–427
- Meknas K, Kartus J, Letto JJ, Christensen A, Johansen O. Surgical release of the internal obturator tendon for the treatment of retro-trochanteric pain syndrome: a prospective randomized study, with long-term follow-up. *Knee Surg Sports Traumatol Arthrosc* 2009;17(10):1249–1256
- Griffin DR, Dickenson EJ, O'Donnell J, et al. The Warwick Agreement on femoroacetabular impingement syndrome (FAI syndrome): an international consensus statement. *Br J Sports Med* 2016;50(19):1169–1176
- Weir A, Brukner P, Delahunt E, et al. Doha agreement meeting on terminology and definitions in groin pain in athletes. *Br J Sports Med* 2015;49(12):768–774
- Cass SP. Piriformis syndrome: a cause of nondiscogenic sciatica. *Curr Sports Med Rep* 2015;14(01):41–44
- Delp SL, Hess WE, Hungerford DS, Jones LC. Variation of rotation moment arms with hip flexion. *J Biomech* 1999;32(05):493–501