



Contents lists available at ScienceDirect

## Journal of Hand Surgery Global Online

journal homepage: [www.JHSGO.org](http://www.JHSGO.org)

## Review Article

# What is Operative? Conceptualizing Neuralgia: Neuroma, Compression Neuropathy, Painful Hyperalgesia, and Phantom Nerve Pain



Elspeth J.R. Hill, MD, PhD,<sup>\*</sup> J. Megan M. Patterson, MD,<sup>†</sup> Andrew Yee, BSc,<sup>‡</sup> Lara W. Crock, MD, PhD,<sup>§</sup> Susan E. Mackinnon, MD<sup>‡</sup>

<sup>\*</sup> Department of Orthopedic Surgery, Division of Hand and Microsurgery, Washington University in St. Louis School of Medicine, St. Louis, MO

<sup>†</sup> Department of Orthopedic Surgery, University of North Carolina, Chapel Hill, NC

<sup>‡</sup> Division of Plastic and Reconstructive Surgery, Washington University in St. Louis School of Medicine, St. Louis, MO

<sup>§</sup> Division of Pain Management, Washington University in St. Louis School of Medicine, St. Louis, MO

## ARTICLE INFO

## Article history:

Received for publication September 14, 2021

Accepted in revised form November 30, 2021

Available online January 14, 2022

## Key words:

Nerve pain  
Neuralgia  
Nerve surgery  
Neuroma  
Neuropathy

Neuralgia, or nerve pain, is a common presenting complaint for the hand surgeon. When the nerve at play is easily localized, and the cause of the pain is clear (eg, carpal tunnel syndrome), the patient may be easily treated with excellent results. However, in more complex cases, the underlying pathophysiology and cause of neuralgia can be more difficult to interpret; if incorrectly managed, this leads to frustration for both the patient and surgeon. Here we offer a way to conceptualize neuralgia into 4 categories—compression neuropathy, neuroma, painful hyperalgesia, and phantom nerve pain—and offer an illustrative clinical vignette and strategies for optimal management of each. Further, we delineate the reasons why compression neuropathy and neuroma are amenable to surgery, while painful hyperalgesia and phantom nerve pain are not.

Copyright © 2022, THE AUTHORS. Published by Elsevier Inc. on behalf of The American Society for Surgery of the Hand. This is an open access article under the CC BY-NC-ND license (<http://creativecommons.org/licenses/by-nc-nd/4.0/>).

While research within the fields of surgery, pain management, and anesthesia has continued to further our understanding of neuralgia, there is still much to be understood about the mechanisms, diagnosis, and treatment of pain. The International Association for the Study of Pain defines pain as “an unpleasant sensory and emotional experience associated with actual or potential tissue damage or described in terms of such damage.”<sup>1</sup> By definition, pain is a subjective experience, and for this reason, the treatment of pain must be individualized based on the patient’s unique clinical context, experiences, and anatomy.<sup>2–4</sup> The physical and psychologic ramifications of neuralgia to our patients are substantial. Yet, our understanding of pain chronification and its mechanisms remain nascent.

Increasingly, research findings indicate that the entire pathway connecting the brain to the periphery is relevant to nerve injury, regeneration, and neuralgia. This corresponds to the upper motor

neuron, through the lower motor neuron, through the neuromuscular junction, to muscle; or, if sensory from the peripheral nerve, through the dorsal root ganglion, to the second-order sensory neurons. This new attention to the nerve pathway highlights the importance of Schwann cell senescence and of nonnerve cells in nerve regeneration.<sup>5,6</sup> Cattin et al’s<sup>7</sup> key work highlights the mechanism whereby hypoxia triggers macrophage migration and blood vessel formation at nerve injury sites, which guide Schwann-cell regeneration.

Pain associated with compression neuropathy is reasonably well-understood, with research outlining a pathophysiologic process of ischemia, with ischemia leading to segmental demyelination, diffuse demyelination, and eventually axonal loss.<sup>8,9</sup> This progression corresponds to Sunderland degrees of injury I, II, and III, respectively (Table).<sup>10,11</sup> More recently, we have focused on the preliminary ischemia in this pathway, and noted Sunderland degree 0, ischemic compression, that has normal electrodiagnostic studies and responds to release immediately with resolution of pain. Ischemia is potentially the cause of the majority of compressive pain.<sup>10</sup> However, injury to another area of the nerve and traction across the nerve can exacerbate damage via disruption of the axonal flow.<sup>12,13</sup>

**Declaration of interests:** No benefits in any form have been received or will be received related directly or indirectly to the subject of this article.

**Corresponding author:** Elspeth J.R. Hill, MD, PhD, Department of Orthopedic Surgery, Division of Hand and Microsurgery, Washington University in St. Louis School of Medicine, 660 S Euclid Ave, St. Louis, MO 63110.

E-mail address: [mail@elspethhill.com](mailto:mail@elspethhill.com) (E.J.R. Hill).

<https://doi.org/10.1016/j.jhsg.2021.11.004>

2589-5141/Copyright © 2022, THE AUTHORS. Published by Elsevier Inc. on behalf of The American Society for Surgery of the Hand. This is an open access article under the CC BY-NC-ND license (<http://creativecommons.org/licenses/by-nc-nd/4.0/>).

Painful neuromas represent perhaps the best understood neuralgic phenomena.<sup>14–18</sup> Studies led by Campbell et al<sup>15</sup> on neuroma pathophysiology showed ephaptic conduction within the neuroma that was mechanically sensitive but also spontaneously active; this pathophysiologic phenomenon resonates with the clinical narratives given by those with neuroma pain. An injury with Sunderland degree V—complete transection—is a typical neuroma, with degree IV representing a neuroma in continuity (with potential for a degree VI mixed injury in the nerve in this context).<sup>15</sup>

Dorsi et al<sup>19</sup> showed in animal models the possibility of differentiating between hyperalgesia from collateral sprouting of adjacent nerves and the pain from direct mechanical stimulation of a neuroma site.<sup>15</sup> This furthers our understanding of the pain associated with numbness compared to pain from direct stimulation of an injured nerve. Abdo et al's<sup>20</sup> recent work with Schwann cells and nociceptive Schwann cells that wrap free nerve endings contributes further to the concept of collateral sprouting nerves and their ability to generate neuralgia. This also potentially explains the mechanism by which the sensory collapse test is useful in examining patients with pain.

However, pain from nerve injury is complex and not simply from compression neuropathy (injuries with Sunderland degrees 0, I, II, and III) or neuroma (injuries with Sunderland degrees IV, V, or VI; Table), but is also centrally maintained.<sup>3,21–23</sup> Extremes such as phantom limb pain or central poststroke pain highlight the importance and complexity of the central nervous system's contribution to the experience and persistence of pain.<sup>21–23</sup> If pain originates centrally (ie, poststroke pain) or is the result of cortical remodeling, the treatment(s) and potential for meaningful pain relief are less clear.

Nerve surgeons need to be cognizant of their role in treating not just neurotmetic neuromas but also compression injuries. Similarly, surgeons must recognize that hyperalgesia from collateral sprouting or phantom nerve pain (anesthesia dolorosa or deafferentation pain) cannot be reliably treated surgically.

## A Framework to Conceptualize Types of Nerve Pain

We frame neuralgia, or nerve pain, into 4 categories, each with differing etiologies, nerve pathologies, and treatment strategies. Only 2 are amenable to surgical intervention (compression and neuroma formation). By contrast, centralized neuropathic pain—including hyperalgesia and phantom nerve pain—is resistant to surgical intervention, and not typically recognized by surgeons. Further, appropriate primary surgery has the potential to prevent centralized neuropathic pain and neuroma formation. Inspired by the painting “Pain,” by Antanas Zmuidzinavicius, and the illustrations of nerves, synapses, and histopathology by Santiago Ramon y Cajal,<sup>24</sup> we created “nerve trees” to illustrate each type of nerve pain (Figs. 1–6).<sup>25</sup>

### Compression Pain

Compression pain is common and well-understood, with carpal tunnel syndrome and cubital tunnel compression seen regularly by extremity surgeons (Fig. 2). By contrast, the approximately 2 dozen other entrapment points in the body are less well-recognized (eg, median nerve compression in the forearm).<sup>26</sup> Chronic compression neuropathy patients may give a history of bothersome pain, numbness and tingling (and later weakness), waking from sleep, and worsening with repetitive motions, work, or activities. Typically, compression pain is much less severe than other pain, such as

**Table**  
Classification of Nerve Injury

Sunderland Degree	Mackinnon Classification Modifications	Seddon Classification
0*	Ischemic conduction block	Neurapraxia
I	Demyelination conduction block	Neurapraxia
II	Axonal injury and endoneurial scarring (mild/moderate)	Axonotmesis
III	Axonal injury and endoneurial scarring (severe)	Axonotmesis
IV	Nerve transection in-continuity with scar	Neurotmesis
V	Nerve transection	Neurotmesis
VI†	Mixed injury	

Copyright Susan Mackinnon (permission to print from Dr. Susan Mackinnon).

\* Recent Pripotnev and Mackinnon modification.<sup>10</sup>

† Mackinnon modification.<sup>11</sup>

neuroma pain. Patients suffering from compression pain may be guarded on exam but are unlikely to be in extremis. They will allow you to touch and move their hand, and maximal Tinel will be over the known compression point. Care should be taken when identifying a compression point that a concomitant compression does not also exist proximally or distally along the nerve. Due to secondary edema, postural compensation, and decreased neural glide, for example, a patient may develop concomitant median nerve compression at the wrist and forearm: the double crush phenomenon.<sup>12</sup>

Acute compression neuropathy presents differently from chronic compression neuropathy, usually after an inciting event, and with a far more severe and sudden onset of pain, numbness, or weakness; for example, acute carpal tunnel syndrome after distal radius fracture. It can also be associated with subsequent median nerve forearm compression and even trigger chronic regional pain syndrome. We recommend this be managed urgently with decompression to avoid axonal loss due to the extent of compression and related edema.

### Compression pain: clinical vignette 1

A 64-year-old man with longstanding left knee osteoarthritis and varus knee deformity undergoes an uncomplicated total knee arthroplasty. After surgery, the patient has complete common peroneal nerve palsy (CPN) and severe pain in the lateral leg in the superficial peroneal nerve distribution as the postoperative block wears off. On postoperative day 1, the patient has no resolution in paralysis and pain, and you are consulted for a potential CPN injury. The patient has complete peroneal nerve paralysis, and dull burning pain and dense numbness in the lateral calf. The patient is taken for urgent CPN exploration and decompression; the nerve is found to be completely in continuity without trauma, but severely compressed with tight bands of fascia. After surgery in the recovery bay, the patient has resolution of pain and return of motor function.

### Management

This case illustrates a case of acute CPN compression. The patient may have been anatomically predisposed and, after surgical correction of varus deformity and possible leg lengthening, the CPN was from extreme stretch and tension across the intermuscular septum and fibular head. We classify this as a Sunderland degree VI injury with axonotmesis (Sunderland degree II or III) and also with an obvious substantial component of ischemic neurapraxia, or Sunderland degree 0 injury, with neurapraxia resulting from



**Figure 1.** “Pain,” by Antanas Zmuidzinavicius (permission from The Art Museum of Lithuania, Vilnius). Animism and the worship of forests and trees are some of the elements of pagan religion in the Baltic states. When Lithuania embraced Christianity in the 14<sup>th</sup> century, these beliefs and nature worship were condemned, although remnants of pagan customs survived. The old religion passed into folklore and into legends that often feature the theme of an enchanted forest populated by evil spirits and ghosts to be avoided and treated with respect. This painting taps into these mental images. The trees have metamorphosed into hideous, fantastical creatures attacking the man seated in the center. Here, nature, which has become threatening, symbolizes human pain. This painting served as inspiration for our “nerve tree” explanatory diagrams in this manuscript.

ischemia rather than demyelination, hence the fast recovery after decompression.<sup>10</sup>

### Neuroma Pain

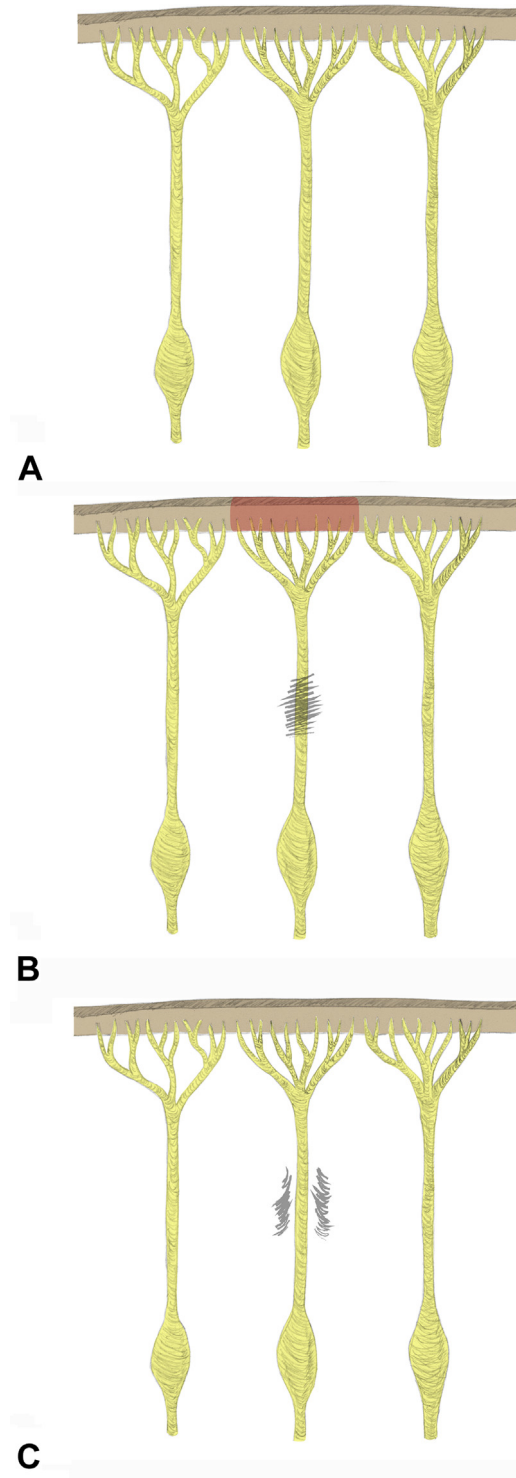
Neuroma pain is often seen and relatively well-understood by surgeons. Direct injury to the nerve causes neuroma formation and pain at the site of the injury. In incomplete or mixed injuries, pain is in the distribution of the nerve, especially with tension, usually with a burning electrical pain (Fig. 3).<sup>14–18</sup> While numerous techniques have been described to treat painful neuromas, the optimal surgical technique for management and treatment of neuroma patients remains elusive.<sup>27</sup>

#### Neuroma pain: clinical vignette 1

A 64-year-old man undergoes right open carpal tunnel release. After surgery, he initially does well and his diffuse numbness and tingling resolves, but he does note new, dense numbness in the radial aspect of the ring finger and the ulnar aspect of the middle finger. This is accompanied by increasing, severe, sharp, shooting electrical pain in the palm, radiating into the third web space, particularly when gripping objects. After being managed conservatively with hand therapy and desensitization by his initial surgeon, he presents to your clinic 6 months later for a second opinion. On examination, he has marked Tinel at the distal aspect of his carpal tunnel incision radiating into the third web space, and numbness in the third web space distribution.

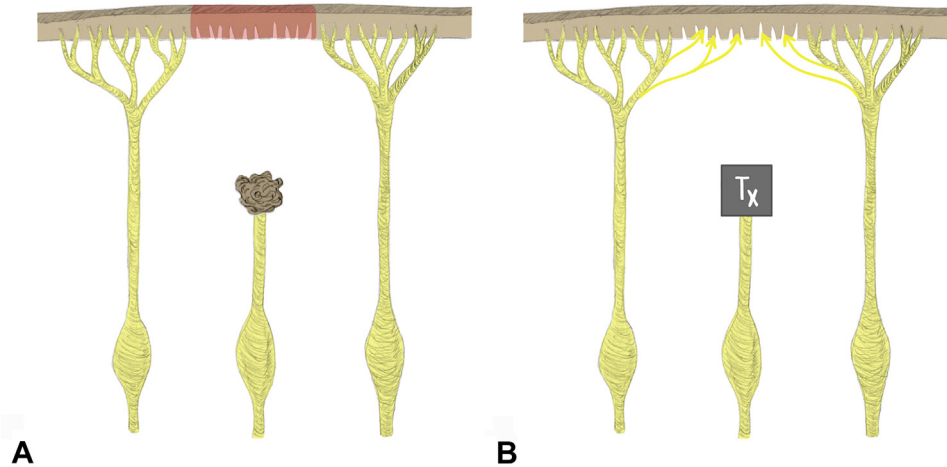
#### Management

This patient presents with a neuroma of the common digital nerve to the third web space, the most commonly injured nerve in carpal tunnel release.<sup>28</sup> The patient likely has a transection to the



**Figure 2.** Compression pain that is amenable to surgery. **A** The response of adjacent normal nerves to nerve injury is variable and critical to understanding neuropathic pain. This cartoon depicts a central nerve (eg, SBRN) with adjacent nerves (eg, LABC nerve of the forearm and the dorsal cutaneous branch of the ulnar nerve). **B** Nerve compression, such as SBRN compression, causes pain within that cutaneous distribution. **C** Compression pain is typically quickly relieved with surgical decompression.

third web space digital nerve (typically more painful with stretch across the nerve). Our approach would be to neurolyse the third web space branch proximally past the carpal tunnel, crush the third web fascicle as proximally as possible to begin a new regenerative

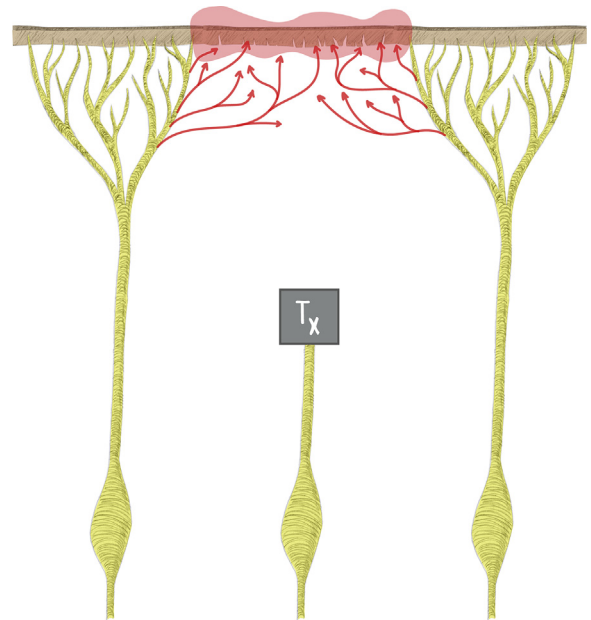


**Figure 3.** Neuroma pain that is amenable to surgery. **A** Neurotmetic injuries may result in painful neuroma formation. **B** There are many techniques described to treat neuroma formation, and these are typically successful in managing neuroma pain. Nerve growth factor increases with denervation and stimulates collateral sprouting of the adjacent normal nerves, resulting in the return of nonpainful sensation over time.<sup>25</sup> Tx, treated neuroma.

front, and transpose into the muscle in the distal forearm (extending with an acellular nerve allograft to blunt recurrent neuroma formation if needed).<sup>14,16</sup> Distally, we would advocate for identifying the third web space branch and coapting it to the side of the second web space branch of the median nerve to allow inline sensory recovery and prevent pathologic collateral sprouting of adjacent nerves.<sup>29</sup> This forearm transposition approach is tailored to this particular case, as the palm is a high-demand contact surface with poor soft tissue coverage; our practice in this context is based in theory, not yet supported by clinical data.<sup>30</sup> Alternatively, if a neuroma (Sunderland degree V injury) or neuroma in continuity (Sunderland degree IV injury) is found in an area where there is better soft tissue coverage and not such a high-demand contact surface as the palm, we would advocate excision and tension-free grafting, and would use an acellular nerve allograft in areas of noncritical sensation<sup>14,16</sup>

### Collateral Sprouting (Painful Hyperalgesia)

The capacity for sensory nerves to spontaneously collaterally sprout into adjacent areas of denervated skin, and the role of the sensory nerve growth factor in this process, has long been recognized.<sup>31</sup> Adjacent normal nerves will collaterally sprout to restore sensation to a denervated cutaneous area. This process is routinely observed by surgeons following a sural nerve graft harvest. This process is usually helpful for restoring nonpainful sensation over time, and is nonpathologic (Fig. 3B). In contrast, collateral sprouting can cause hyperalgesia and pain, stemming from aberrant regeneration from uninjured neighboring nerves into a deinnervated area of an injured nerve (Fig. 4). A neuralgia develops that can be highly distressing; hyperalgesia, tingling, numbness, and unpleasant or disturbing sensations can occur. This is elicited by touching the area, or even from air or clothing brushing the skin. The patient will be resistant to tactile stimuli, and typically flinch or grimace if you touch the area. This pain is often misunderstood or mistaken for neuroma pain. Clinically, this circumstance often presents after a neuroma is treated (eg, by proximal transposition into muscle), resulting in a period of relief and appropriate numbness in the corresponding cutaneous distribution, followed by onset of horrible recurrent pain in that same area; a surgeon's instinct may be to perform surgery for recurrent neuroma, which will not work. If a neuroma treatment has been well-performed, then the recurrent



**Figure 4.** Collateral sprouting pain (painful hyperalgesia) that is not amenable to surgery. Collateral sprouting can result in painful hyperalgesia (red zone), best managed with modalities such as GMI and desensitization, and is not amenable to nerve surgical intervention. Repeated operations directed at the neuroma will not be successful.<sup>19</sup> Tx, treated neuroma.

pain in the same territory is not a recurrent neuroma. For example, this painful hyperalgesia can be seen after successful treatment of a superficial branch of radial nerve (SBRN) neuroma when the lateral antebrachial cutaneous (LABC), palmar cutaneous median, and/or dorsal cutaneous ulnar nerves collaterally sprout to restore sensation into the SBRN distribution in a pathologic fashion; the recurrent pain in the SBRN distribution may be misinterpreted as a failed neuroma surgery.<sup>32</sup> Distinguishing between neuroma and collateral sprouting may be assisted by physical examination. A neuroma presents with shooting pain into a nerve territory, reproduced with maximal Tinel at the injury site into that distribution. Collateral sprouting pain will be a burning, unpleasant painful hyperalgesia (not numbness), with hypersensitivity to the touch, not reproduced

by palpation or Tinel at the site of injury of the nerve previously innervating that area (or at the site of a successfully treated neuroma). However, there may be a Tinel at a known compression point of the adjacent collaterally sprouting nerve(s). A local anesthetic nerve block can help distinguish these phenomena; if a block at the site of a previously untreated SBRN neuroma does not help, but blocking the adjacent pathologic collaterally sprouting LABC and palmar cutaneous nerves relieves the symptoms, this would confirm a hypothesis of collateral sprouting hyperalgesia.

We use the analogy of a dimmer light switch to describe this phenomenon. In nonpathologic collateral sprouting, a dimmer switch is gradually turned up and nonpainful sensation gradually returns. In pathologic collateral sprouting, the dimmer switch malfunctions: the light rapidly flicks on and off, creating an annoying and distressing strobe effect. This is seen in sural nerve harvest where, over time, the area of numbness slowly resolves with successful nonpainful collateral sprouting. However, in sural nerve neuroma (perhaps after injury from an ankle trauma or surgery), the neuroma can be treated, but severe pain can be triggered by pathologic collateral sprouting of the adjacent superficial peroneal nerve into the previously numb sural nerve distribution. This can occur whether the injured nerve that originally supplied the cutaneous area is spontaneously recovering or has permanently denervated the cutaneous region. Surgeons treating neuromas with targeted muscle reinnervation have reported subsequent “unmasking” of pain from other nerves; this likely represents, in part, collateral sprouting hyperalgesia.<sup>33</sup>

Treatment of painful hyperalgesia from collateral sprouting nerves is not surgical; if this pain is misinterpreted as neuroma pain, not only will repeat neuroma surgery be unsuccessful, but pain can also worsen with repeated neuroma procedures. The exception is if there is also superimposed compression on the collaterally sprouting nerve(s), in which case we recommend decompression surgery on the nerve that is collaterally sprouting. Otherwise, this collateral sprouting pain has pathologic central processes in the distribution of the peripheral nerve; treatment focuses on desensitization therapy, graded motor imagery (GMI), and pain management intervention (such as optimization of neuropathic pain medication, stellate ganglion blocks, and pain psychology).

*Collateral sprouting pain: clinical vignette 1: collateral sprouting without associated compression neuropathy, not amenable to surgical release*

A 51-year-old man undergoes cubital tunnel release complicated by a medial antebrachial cutaneous (MABC) neuroma and presents with severe electrical shooting pain into the MABC distribution with percussion of the scar. A targeted muscle reinnervation procedure is undertaken from both the anterior and posterior branches of the MABC into small, local muscle branches, with expected numbness and pain relief in the MABC distribution for several weeks. Unfortunately, the patient presents to your clinic with the return of very painful dysesthesia in the same MABC distribution as pre-targeted muscle reinnervation surgery. The pain is unpleasant and disconcerting, and is worse with air or clothing brushing the area or with touch.

#### Management

Despite successful treatment of the MABC neuroma, this patient has aberrant collateral sprouting of adjacent sensory nerves into the MABC distribution, causing painful dysesthesia. This is not amenable to surgery. Treatment should include prompt

desensitization therapy, GMI, and pain management, but not repeated operative intervention.

*Collateral sprouting pain: clinical vignette 2: collateral sprouting with associated compression neuropathy, amenable to surgical release*

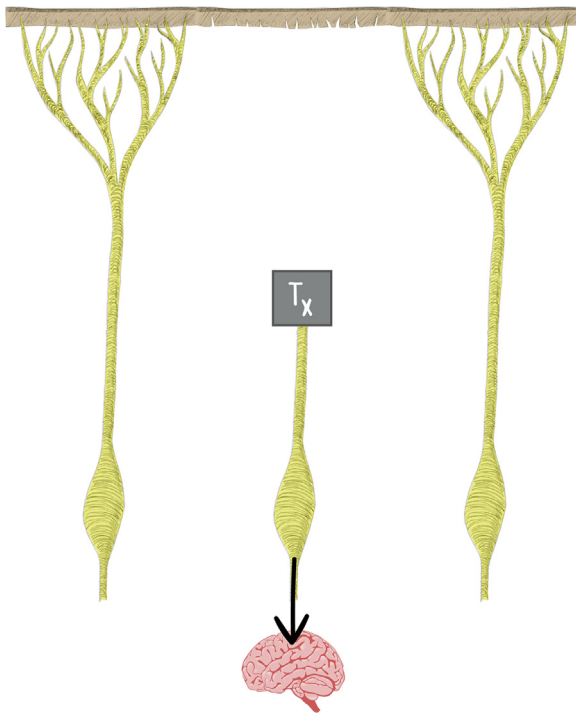
A 53-year-old man, intermittently on steroids for asthma, ruptured his distal biceps tendon arm-wrestling a friend. He underwent distal biceps tendon repair into the radial tubercle with a suture anchor. After surgery, he had a Tinel sign over the LABC at the antecubital fossa and pain in the LABC distribution that resolved over the coming weeks, with some persistent numbness in the volar radial forearm; an LABC nerve injury was suspected and treated conservatively. However, 3 months after surgery he began to have burning pain in the radial forearm and into the thumb, associated with unpleasant itching, tingling, and indescribable pains that gradually worsened. In your clinic 6 months after injury, the patient has a well-healed surgical incision and no Tinel over the LABC. The patient has pain in the radial sensory distribution, flinches when you touch the area, and has a positive Tinel, sensory collapse test, and provocative testing (with the wrist in pronation, ulnar deviation, and flexion) at the SBRN entrapment point where the SBRN emerges between the brachioradialis and extensor carpi radialis longus in the radial forearm.<sup>34</sup>

#### Management

This patient has an LABC injury that has largely recovered, with new hypersensitivity in the SBRN distribution. The diagnosis of painful hyperalgesia from a collaterally sprouting SBRN is made, with superimposed compression found at a known compression site using provocative tests. Our approach would entail surgical decompression of the SBRN with brachioradialis tenotomy for pain, pain management, and desensitization and GMI focused on both the LABC and SBRN distributions.<sup>35</sup>

#### Phantom Nerve Pain (Anesthesia Dolorosa or Deafferentation Pain)

We use the phrase “phantom nerve pain” for pain described by patients related to the absence of sensation. Though simple numbness is often well-tolerated and not bothersome, phantom nerve pain develops for some patients (Fig. 5). The painful area is essentially numb yet painful, hence the term “anesthesia dolorosa,” which translates as “painfully numb.” In a similar way to amputees who have phantom limb pain in a limb no longer present, patients with peripheral nerve injury can have phantom nerve pain in the denervated area. We hypothesize that damage to the peripheral first-order neurons, along with spontaneously firing second-order neurons (deafferentation), causes this pain and, if not treated in a timely manner, results in cortical remodeling and centrally mediated pain (as in phantom limb pain).<sup>20,25,36</sup> Often described as unpleasant, difficult to describe, cold, or numbing pain, it is constant, with fluctuating severity, but is not reproducible by palpation or examination. Physicians can easily dismiss this pain if not understood or, worse, attempt to treat it surgically with repeated neuroma surgery. This is not a peripheral nerve issue, but a more central process, and is not helped by surgery; we propose optimal supportive treatment with pain management specialist input, GMI, pain psychology, and medical management. Again, the exception occurs when a nearby collaterally sprouting nerve with a known entrapment point is causing pain and can be relieved via decompression (Fig. 6).



**Figure 5.** Phantom nerve pain (anesthesia dolorosa or deafferentation pain) that is not amenable to surgery. Despite appropriate neuroma treatment and relief of neuroma pain, some patients will have numbness in the distribution of the treated nerve that is numb yet very painful; we term this phantom nerve pain (anesthesia dolorosa or deafferentation pain). This is not amenable to nerve surgical treatment. Tx, treated neuroma.

#### Phantom nerve pain: clinical vignette 1

A 41-year-old female presents 3 years after an endoscopic carpal tunnel release complicated by complete median nerve transection with failed attempt at a nerve repair. She has severe shooting pain in the hand in the median nerve distribution, with numbness in the radial digits and marked Tinel at the carpal tunnel incision. She does not want anyone to touch her hand and does not want to touch it herself. Her quality of life is substantially affected. You take her to the operating room for exploration, neuroma excision, and anatomic reconstruction with MABC nerve grafting. After surgery, she has resolution of the sharp shooting pains, and a negative Tinel along the median nerve. However, she complains of persistent, severe, painful numbness in the hand that affects her sleep and concentration. She will now let you massage and percuss the hand and the pain is not reproducible with palpation, but she still reports life-altering pain in the median nerve distribution.

#### Management

This patient has had surgical intervention that has treated her neuroma pain, but due to the longstanding nature of her injury has developed centralized phantom nerve pain that cannot be alleviated by surgery. Although the grafts allow inline recovery, due to the time elapsed and Schwann cell senescence, the distal median nerve does not provide a supportive pathway; nerve regeneration likely will dwindle across the nerve graft and will not reach its distal target or reinnervate the digits.<sup>5,30</sup> This, coupled with centralized changes in pain receptors, causes chronic centralized pain syndrome. These patients may mistakenly be perceived by their surgeons as malingering, and this further exacerbates the

patient's distress. This warrants optimal nonsurgical management of persistent nerve pain.

#### Phantom nerve pain: clinical vignette 2

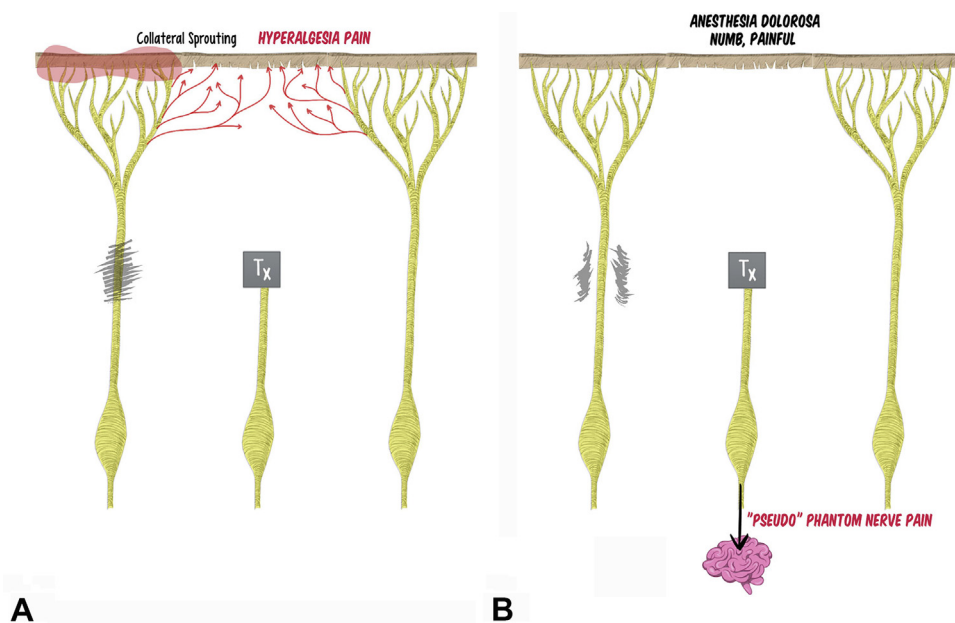
A 42-year-old female presents 6 years after treatment of an ankle fracture. She had pain at the site of a percutaneous drill hole at the lateral ankle, severe enough that her surgeons performed early exploration and found the sural nerve in continuity but caught in the screw. The nerve was released and neurolysed, but pain persisted. With no improvement 2 years after surgery, she underwent repeat exploration and neuroma excision, and the distal nerve was buried into muscle. After some short-term relief, 3 years from the initial surgery she sought a second opinion and underwent another exploration and neuroma excision more proximally at the midcalf with transection and transposition into muscle. She presents to your clinic 6 years after her initial surgery, after 3 failed neuroma excisions, with numbness in her sural nerve distribution that she describes as debilitatingly painful. On examination she has no sensation in the sural distribution, but describes an unpleasant, cold, numbing pain. There are no positive provocative test findings in the extremity (negative Tinel, sensory collapse test, and pressure provocation tests). A proximal sural nerve block gives no relief. She asks for a definitive surgical cure for this issue.

#### Management

This patient presents 6 years after a mixed sural nerve injury at the ankle after 3 failed neuroma surgeries. The painful numbness—*anesthesia dolorosa*—is characteristic of what we coin phantom nerve pain due to centralized processes. Repeat neuroma surgery is futile. In this case, our management strategy would be pain management, desensitization, GMI, pain psychology, and nonsurgical management, with a referral for a dorsal column stimulator trial.

#### Conclusions

We offer a conceptual framework separating neuralgia into 4 types: compression neuropathy, neuroma, painful hyperalgesia, and phantom nerve pain. This can guide surgeons to operate on those that will benefit from surgery and, more importantly, avoid operations for nerve pain that cannot be surgically treated (painful hyperalgesia from collateral sprouting or central sensitization and phantom nerve pain). For example, a persistent painful neuroma after multiple surgeries is likely not neuroma pain. An etiology of painful hyperalgesia from collateral sprouting (associated with hypersensitivity in the area) or phantom nerve pain (associated with painful numbness in the area) should be considered and treated without surgery. If present, any associated nerve entrapment points should be decompressed. Our approach uses a pain diagram and questionnaire ([Appendix](#), available on the *Journal's* website at [www.jhsgo.org](http://www.jhsgo.org)) in combination with a patient history and physical examination to assess pain in the clinic. The Tinel sign and sensory collapse test can be used as clinical provocative tests to assist with diagnoses.<sup>20,34,36</sup> In this paper, we have attempted to provide a conceptual framework to practically think about neuralgia. Notably, we have not specifically addressed chronic regional pain syndrome, injury from nerve blocks, needle sticks, injection injuries, and neuralgia amyotrophy (Parsonage Turner syndrome); all are beyond the scope of this article. Recognizing the underlying cause of neuralgia through a careful history and physical examination equips surgeons with the tools required to more successfully treat nerve-injured patients who so desperately seek relief from their symptoms.



**Figure 6.** Superimposed compression in collaterally sprouting and phantom nerve pain contexts. In the setting of **A** collateral sprouting with painful hyperalgesia or **B** phantom nerve pain, there is potential for superimposed compression neuropathy of adjacent nerves. If recognized and released, this can alleviate pain in the context of both collateral sprouting and phantom nerve pain. Tx, treated neuroma.

## References

- Merskey H, Albe F, Bonica JJ, et al. Pain terms: a list with definitions and notes on usage. Recommended by the IASP subcommittee on taxonomy. *Pain*. 1979;6:249–252.
- Heary KO, Wong AWK, Lau SCL, et al. Quality of life and psychosocial factors as predictors of pain relief following nerve surgery. *Hand (N Y)*. Published online March 19, 2020. <https://doi.org/10.1177/1558944720911213>
- Fillingim RB. Individual differences in pain: understanding the mosaic that makes pain personal. *Pain*. 2017;158(Suppl 1):S11–S18.
- Swieboda P, Filip R, Prystupa A, Drozd M. Assessment of pain: types, mechanism and treatment. *Ann Agric Environ Med*. 2013;1:2–7.
- Saheb-Al-Zamani M, Yan Y, Farber SJ, et al. Limited regeneration in long acellular nerve allografts is associated with increased Schwann cell senescence. *Exp Neurol*. 2013;247:165–177.
- Pan D, Mackinnon SE, Wood MD. Advances in the repair of segmental nerve injuries and trends in reconstruction. *Muscle Nerve*. 2020;61:726–739.
- Cattin AL, Burden JJ, Van Emmenis L, et al. Macrophage-induced blood vessels guide Schwann cell-mediated regeneration of peripheral nerves. *Cell*. 2015;162:1127–1139.
- Bentley FH, Schlapp W. The effects of pressure on conduction in peripheral nerve. *J Physiol*. 1943;102:72–82.
- Dang AC, Rodner CM. Unusual compression neuropathies of the forearm, part I: radial nerve. *J Hand Surg Am*. 2009;34:1906–1914.
- Peters BR, Pripotnev S, Chi D, Mackinnon SE. Complete foot drop with normal electrodiagnostic studies: Sunderland “zero” ischemic conduction block of the common peroneal nerve. *Ann Plast Surg*. Published online December 3, 2021. <https://doi.org/10.1097/SAP.0000000000003053>
- Mackinnon SE, Dellon AL. *Surgery of the Peripheral Nerve*. Thieme; 1988.
- Mackinnon SE. Double and multiple “crush” syndromes. Double and multiple entrapment neuropathies. *Hand Clin*. 1992;8:369–390.
- Szabo RM, Gelberman RH. The pathophysiology of nerve entrapment syndromes. *J Hand Surg Am*. 1987;12:880–884.
- Domeshek LF, Krauss EM, Snyder-Warwick AK, et al. Surgical treatment of neuromas improves patient-reported pain, depression, and quality of life. *Plast Reconstr Surg*. 2017;139:407–418.
- Meyer RA, Raja SN, Campbell JN, Mackinnon SE, Dellon AL. Neural activity originating from a neuroma in the baboon. *Brain Res*. 1985;325:255–260.
- Nath RK, Mackinnon SE. Management of neuromas in the hand. *Hand Clin*. 1996;12:745–756.
- Sosin M, Weiner LA, Robertson BC, DeJesus RA. Treatment of a recurrent neuroma within nerve allograft with autologous nerve reconstruction. *Hand (N Y)*. 2016;11:NP5–NP9.
- Vernadakis AJ, Koch H, Mackinnon SE. Management of neuromas. *Clin Plast Surg*. 2003;30:247–268.
- Dorsi MJ, Chen L, Murinson BB, Pogatzki-Zahn EM, Meyer RA, Belzberg AJ. The tibial neuroma transposition (TNT) model of neuroma pain and hyperalgesia. *Pain*. 2008;134:320–334.
- Abdo H, Calvo-Enrique L, Lopez JM, et al. Specialized cutaneous Schwann cells initiate pain sensation. *Science*. 2019;365:695–699.
- Kaur A, Guan Y. Phantom limb pain: a literature review. *Chin J Traumatol*. 2018;21:366–368.
- Kumar B, Kalita J, Kumar G, Misra UK. Central poststroke pain: a review of pathophysiology and treatment. *Anesth Analg*. 2009;108:1645–1657.
- Subedi B, Grossberg GT. Phantom limb pain: mechanisms and treatment approaches. *Pain Res Treat*. 2011;2011:864605.
- Swanson LW, Newman E, Araque A, Dubinsky JM. *The Beautiful Brain*. Abrams; 2017.
- Taniuchi M, Clark HB, Johnson EM. Induction of nerve growth factor receptor in Schwann cells after axotomy. *Proc Natl Acad Sci USA*. 1986;83:4094–4098.
- El-Haj M, Ding W, Sharma K, Novak C, Mackinnon SE, Patterson JMM. Median nerve compression in the forearm: a clinical diagnosis. *Hand (N Y)*. 2019;16(5):586–591.
- Poppler LH, Parikh RP, Bichanich MJ, et al. Surgical interventions for the treatment of painful neuroma: a comparative meta-analysis. *Pain*. 2018;159:214–223.
- Palmer AK, Toivonen DA. Complications of endoscopic and open carpal tunnel release. *J Hand Surg Am*. 1999;24:561–565.
- Felder JM, Hill EJ, Power HA, Hasak J, Mackinnon SE. Cross-palm nerve grafts to enhance sensory recovery in severe ulnar neuropathy. *Hand (N Y)*. 2020;15:526–533.
- Pan D, Hunter DA, Schellhardt L, et al. The accumulation of T cells within acellular nerve allografts is length-dependent and critical for nerve regeneration. *Exp Neurol*. 2019;318:216–231.
- Jackson PC, Diamond J. Regenerating axons reclaim sensory targets from collateral nerve sprouts. *Science*. 1981;214:926–928.
- Mackinnon SE, Dellon AL. The overlap pattern of the lateral antebrachial cutaneous nerve and the superficial branch of the radial nerve. *J Hand Surg Am*. 1985;10:522–526.
- Souza JM, Cheesborough JE, Ko JH, Cho MS, Kuiken TA, Dumanian GA. Targeted muscle reinnervation: a novel approach to postamputation neuroma pain. *Clin Orthop Relat Res*. 2014;472:2984–2990.
- Kahn LC, Yee A, Mackinnon SE. Important details in performing and interpreting the scratch collapse test. *Plast Reconstr Surg*. 2018;141:399–407.
- Hill EJ, Padovano WE, Patterson MM, Yee A, Crock LW, S E. Decompression with complete brachioradialis tenotomy improves pain and quality of life for patients with compression of the sensory branch of the radial nerve. *Plast Reconstr Surg*. 2021. In press.
- Doan RA, Monk KR. Glia in the skin activate pain responses. *Science*. 2019;365:641–642.