

Piezoelectric Versus Conventional Rotary Techniques for Impacted Third Molar Extraction

A Meta-analysis of Randomized Controlled Trials

Qian Jiang, MD, Yating Qiu, MD, Chi Yang, MD, Jingyun Yang, PhD, Minjie Chen, MD, and Zhiyuan Zhang, MD

Abstract: Impacted third molars are frequently encountered in clinical work. Surgical removal of impacted third molars is often required to prevent clinical symptoms. Traditional rotary cutting instruments are potentially injurious, and piezosurgery, as a new osteotomy technique, has been introduced in oral and maxillofacial surgery. No consistent conclusion has been reached regarding whether this new technique is associated with fewer or less severe postoperative sequelae after third molar extraction.

The aim of this study was to compare piezosurgery with rotary osteotomy techniques, with regard to surgery time and the severity of postoperative sequelae, including pain, swelling, and trismus.

We conducted a systematic literature search in the Cochrane Library, PubMed, Embase, and Google Scholar.

The eligibility criteria of this study included the following: the patients were clearly diagnosed as having impacted mandibular third molars; the patients underwent piezosurgery osteotomy, and in the control group rotary osteotomy techniques, for removing impacted third molars; the outcomes of interest include surgery time, trismus, swelling or pain; the studies are randomized controlled trials.

We used random-effects models to calculate the difference in the outcomes, and the corresponding 95% confidence interval. We calculated the weighted mean difference if the trials used the same measurement, and a standardized mean difference if otherwise.

A total of seven studies met the eligibility criteria and were included in our analysis. Compared with rotary osteotomy, patients undergoing piezosurgery experienced longer surgery time (mean difference 4.13 minutes, 95% confidence interval 2.75–5.52, $P < 0.0001$). Patients receiving the piezoelectric technique had less swelling at postoperative

days 1, 3, 5, and 7 (all $P_s \leq 0.023$). Additionally, there was a trend of less postoperative pain and trismus in the piezosurgery groups.

The number of included randomized controlled trials and the sample size of each trial were relatively small, double blinding was not possible, and cost analysis was unavailable due to a lack of data.

Our meta-analysis indicates that although patients undergoing piezosurgery experienced longer surgery time, they had less postoperative swelling, indicating that piezosurgery is a promising alternative technique for extraction of impacted third molars.

(*Medicine* 94(41):e1685)

Abbreviations: BMP = bone morphogenic protein, CI = confidence interval, MD = mean difference, RCT = randomized controlled trial, SMD = standardized mean difference, VAS = visual analog scale.

INTRODUCTION

Impacted third molars are frequently encountered in clinical work, with a prevalence of 33% to 58.7%.^{1–4} It has been well documented that impacted third molars, either partial or complete, are associated with several complications, including pericoronitis, regional pain, odontogenic abscesses, trismus, distal caries, cysts, tumors, and arch crowding.^{5–8} Therefore, symptomatic or asymptomatic impacted third molars are often extracted to reduce the above-mentioned clinical symptoms.

The surgical removal of impacted third molars may lead to various postoperative side effects, including pain, swelling, trismus, nerve injury, bleeding, and dry sockets.^{9,10} Different strategies are adopted to reduce these complications, including changing the technique of the osteotomy.¹¹

Traditionally, impacted third molars are often removed using rotary osteotomy techniques. However, conventional rotary cutting instruments are potentially injurious because they can generate excessively high temperatures during bone drilling, which leads to marginal osteonecrosis, and can impair osseous regeneration and healing.^{12–14} Recently, along with the tendency toward minimally invasive surgery, piezosurgery—a new osteotomy technique—has been introduced in oral and maxillofacial surgery. Using a piezoelectric device, piezosurgery has a much lower risk of visible injury to the adjacent soft tissues, leading to more favorable osseous repair and remodeling.¹³ Randomized controlled trials (RCTs) have been conducted to compare piezosurgery with traditional rotary techniques regarding postoperative sequelae after third molar extraction, with inconsistent results reported.^{15–21}

Therefore, in this study, we performed an extensive literature search of RCTs and conducted meta-analyses to compare piezosurgery with conventional rotary osteotomy techniques, with regard to surgery time and postoperative sequelae, including pain, swelling, and trismus.

Editor: Barbara Buffoli.

Received: March 31, 2015; revised: August 31, 2015; accepted: September 4, 2015.

From the Department of Oral and Maxillofacial Surgery, Shanghai Ninth People's Hospital, Shanghai Jiaotong University School of Medicine, Shanghai, China (QJ, YQ, CY, MC, ZZ); Rush Alzheimer's Disease Center (JY); and Department of Neurological Sciences, Rush University Medical Center, Chicago, Illinois (JY).

Correspondence: Chi Yang, Department of OMFS, Shanghai Ninth People's Hospital, School of Medicine, Shanghai Jiaotong University, Shanghai Key Laboratory of Stomatology, 639 Zhi-zao-ju Road, Shanghai 200011, China (e-mail: yangchi163@yeah.net).

Funding: This work was supported by National Science Foundation of China (No.81100824 and No. 81070848) and Foundation of Shanghai Municipal Education Commission (No. 12YZ044, 13XD1402300 and 14DZ2294300). Dr. Jingyun Yang's research was supported by NIH/NIA R01AG036042 and the Illinois Department of Public Health.

The authors have no funding and conflicts of interest to disclose.

Supplemental Digital Content is available for this article.

Copyright © 2015 Wolters Kluwer Health, Inc. All rights reserved.

This is an open access article distributed under the Creative Commons Attribution License 4.0, which permits unrestricted use, distribution, and reproduction in any medium, provided the original work is properly cited. ISSN: 0025-7974

DOI: 10.1097/MD.0000000000001685

METHODS

Eligibility Criteria

The following inclusion criteria were used to determine study eligibility: the patients were clearly diagnosed as having impacted mandibular third molars; the patients underwent piezosurgery osteotomy techniques, and in the control group rotary osteotomy techniques, for removing the impacted third molars; the outcomes of interest included surgery time, trismus, swelling, or pain, as assessed using the visual analog scale (VAS); and the studies were RCTs. Ethical approval was not necessary, as this study was based on published data.

Search Strategy

Two authors (QJ and JY) performed an extensive literature search in the Cochrane Library, PubMed, Embase, and Google Scholar for papers published up to December 23, 2014. The keywords used in the literature search can be found in the supplementary file.

We retrieved all potential relevant publications, which were evaluated for inclusion in this study. We also searched for additional studies that might be missed by the database search by manually searching the reference list for all relevant publications. The two authors performed the literature search independently, and any disagreement was resolved by a group discussion.

Data Extraction

The following data were extracted and recorded independently by the two reviewers (QJ and YQ), following a pre-specified protocol: first author's name, year of publication, country of origin, hospital name, study design, mean age of participants, sample size, impacted type, duration of surgery time, postoperative pain, swelling, and trismus. Any disagreement or lack of clarity was resolved through a group discussion. If a trial reported data through a figure, Engauge Digitizer version 4.1 (<http://digitizer.sourceforge.net/>) was used to read the data and efforts were made to contact the authors if additional data were needed. An assessment of study validity was done using Cochrane Collaboration's tool, which is one of the most popular tools for assessing the risk of bias for RCTs.²² It is composed of the following six dimensions: random sequence generation; allocation concealment; blinding; addressing of incomplete outcome data; selective outcome reporting; and other apparent risks of bias.

Data Analysis

Random-effects models were used to calculate the difference in the outcomes and the corresponding 95% confidence intervals (CIs). Forest plots were used to represent the pooled mean differences and 95% CIs. If the trials used the same measurement instrument, the weighted mean difference (WMD) and its 95% CIs were calculated. Otherwise, the standardized mean differences (SMDs) and their 95% CIs were calculated. We first conducted our meta-analyses by study design (parallel study and split-mouth design), and then pooled the analysis results for both designs. I^2 was used to assess the between-study heterogeneity, and a P value <0.20 was considered to indicate statistically significant heterogeneity among the studies.

This study was reported according to the PRISMA guidelines.²³ All statistical analyses were performed using Stata 11.2 (StataCorp LP, College Station, TX), and a P value <0.05 was considered to be statistically significant.

RESULTS

Study Selection and Characteristics

The selection of eligible studies included in the meta-analyses is presented in Figure 1. Following our predefined search strategy, our initial search identified 305 potential publications. We excluded 288 publications because they were not RCTs, not about humans, or because they were published abstracts or were irrelevant, leading to 17 studies which were retrieved for more detailed evaluations. Nine additional studies were excluded because they were not published, were reviews, included the upper third molar, or there were no sufficient data. This led to 8 potentially relevant publications to be included in our meta-analysis. Finally, we further excluded 1 more study because there were insufficient data despite efforts to contact the authors.²⁴ As a result, a total of 7 studies met the eligibility criteria and were included in our meta-analysis. These 7 eligible studies were published from 2008 through 2014.^{15–21} Among them, 3 used a parallel-group design (each patient as a study unit),^{15,16,18} and 4 used a split-mouth design (each tooth as a study unit).^{17,19–21} Antibiotics were prescribed in all studies. Table 1 summarizes the characteristics of the 7 included studies.

Risk of Biases in Included Studies

Figure 2 summarizes the assessment of the risk of bias of the included studies. Because double blinding was not possible, all of the studies were judged as having an unclear risk of performance bias. Two studies reported that the patients were allocated into the piezosurgery and rotary groups according to a computer-generated randomization list,^{16,17} 1 study used a table

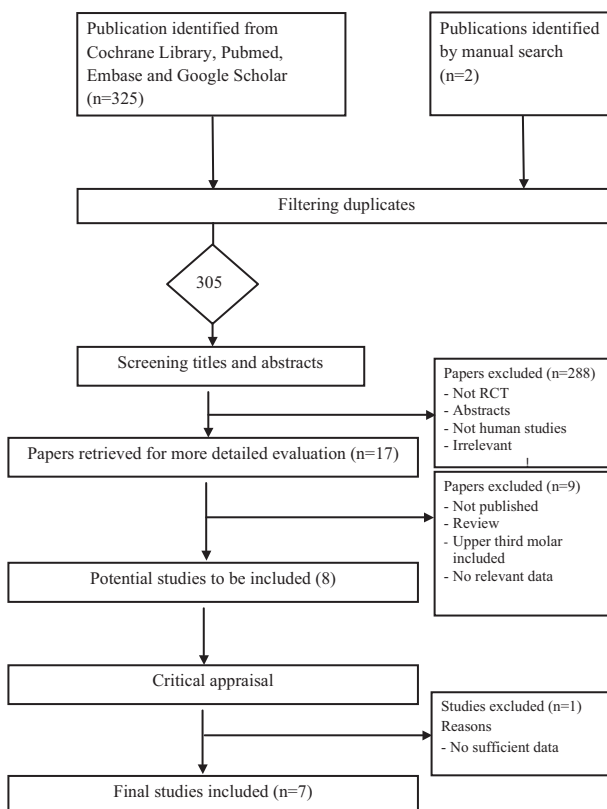


FIGURE 1. Flow diagram of the literature search and selection process. Please refer to the “Methods” section for more details.

TABLE 1. Characteristics of Included Studies

Study	Year of Publication	Time of Study	Place of Study	Design	Age (y), Mean ± SD	Sample Size Per Arm	Impacted Type	Outcomes
Sortino et al ¹⁵	2008	*	University of Catania, Italy	Parallel	23.8 ± 6.43	50	Bony	Surgery time; trismus; swelling
Barone et al ¹⁶	2010	Feb–Sept, 2008	Versilia Hospital, Italy, Italy	Parallel	31.2	23	Bony	Surgery time; pain; trismus; swelling
Sivolella et al ¹⁷	2011	Jan–Dec, 2008	University of Padua, Italy	Split-mouth	15.4 ± 1.29	26	Full-bony	Surgery time; pain; trismus
Goyal et al ¹⁸	2012	*	Santosh Dental College, India	Parallel	29	20	Bony	Surgery time; pain; trismus; swelling
Rullo et al ¹⁹	2013	*	Italy	Split-mouth	26.2	52	Bony	Surgery time; pain
Mantovani et al ²⁰	2014	June–Sept., 2010	University of Turin, Italy	Split-mouth	24.0 ± 4.21	100	Bony	Surgery time; swelling
Piersanti et al ²¹	2014	Jan–Oct, 2013	S Orsola-Malpighi Hospital, Italy	Split-mouth	22.4 ± 2.3	10	Bony	Surgery time; pain; trismus; swelling

SD = standard deviation.
* Not provided.

of random numbers,²⁰ and another study used a coin toss.¹⁹ These 4 studies were considered to be at low risk and the other 3 studies were considered to be at an unclear risk in the random sequence generation.

Surgery Time

All of the trials evaluated the surgery time, and indicated longer average surgery time in the piezosurgery group than in the rotary group (eTable 1, <http://links.lww.com/MD/A449>). The meta-analysis indicated significantly longer surgery time in the piezosurgery group, compared with the rotary group (WMD 4.13 minutes, 95% CI 2.75–5.52, $P < 0.0001$) (Figure 3). The subgroup analysis by study design revealed significantly longer surgery time in the piezosurgery group for both the parallel design and the split-mouth design studies. There was low heterogeneity among the included studies (all $I^2 < 19\%$).

Pain

With the exception of 1 trial,¹⁵ all of the trials reported pain scores using the VAS (10-unit or 100-unit) on different postoperative days (eTable 2, <http://links.lww.com/MD/A449>). Furthermore, the postoperative pain decreased following the third molar extraction for both groups. The meta-analysis indicated that there was no statistically significant difference in pain between the piezosurgery group and the rotary group on any of the postoperative days (Figure 4). However, in the first few days after surgery, there was a trend of less pain in the piezosurgery group than in the rotator group; the difference is nominal, but not statistically significant (day 1: SMD -0.61, 95% CI -1.29 to 0.07, $P = 0.078$; day 3: SMD -0.85, 95% CI -1.71 to 0.006, $P = 0.052$).

Trismus

Five studies evaluated postoperative trismus, all of which measured the maximum mouth opening at specific time points (eTable 3, <http://links.lww.com/MD/A449>).^{15–18,21} The meta-analysis did not indicate a significant difference in trismus between the piezosurgery group and the rotary group on any

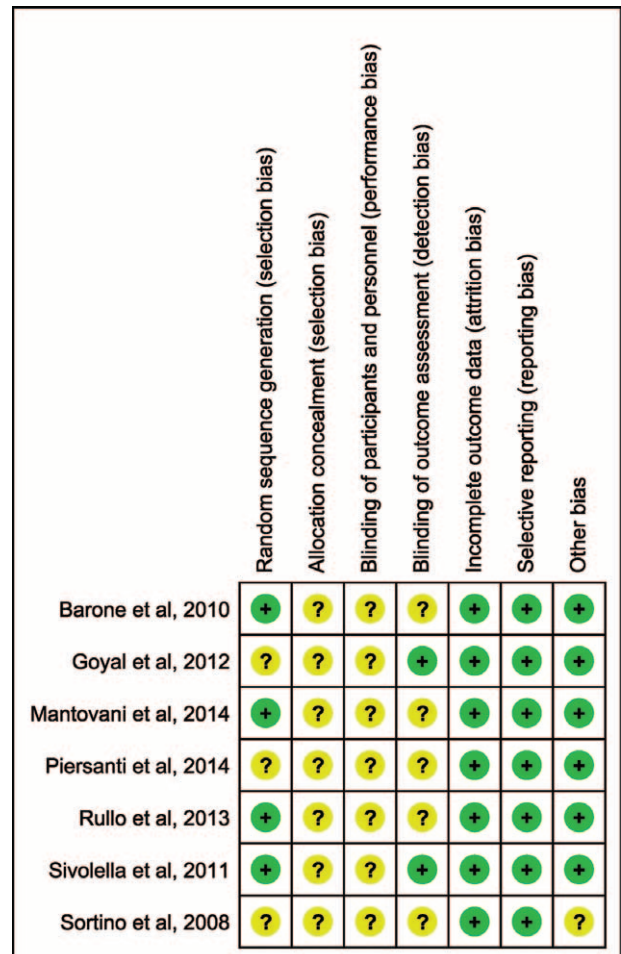


FIGURE 2. Assessment of risk of bias of included studies.

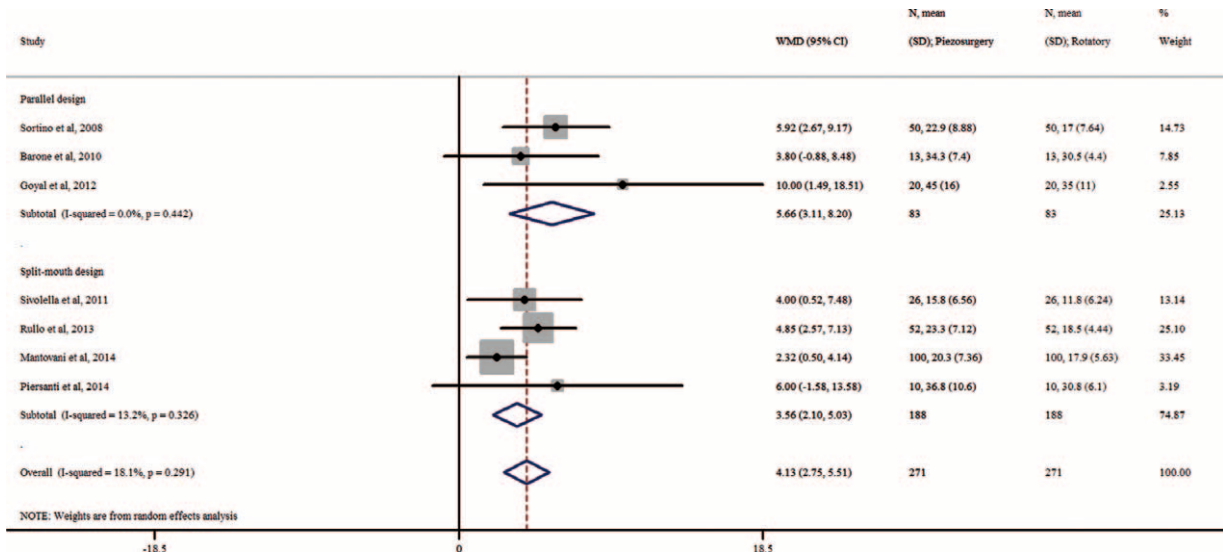


FIGURE 3. Forest plot for meta-analysis of the difference in surgery time between piezosurgery versus rotary osteotomy technique in third molar extraction.

of the postoperative days (Figure 5). However, a subgroup analysis indicated a statistically significant decrease in trismus on all of the postoperative days (1, 3, 5, and 7) in the piezosurgery group in studies with a parallel design, but not in studies with a split-mouth design, probably due to the small sample size.

Swelling

Five studies reported swelling at specific time points, but used different measurements (eTable 4, <http://links.lww.com/MD/A449>).^{15,16,18,20,21} The meta-analysis indicated that patients in the piezosurgery group had significantly reduced facial swelling than those in the rotary group on all postoperative days (all *Ps* ≤ 0.023; Figure 6). A subgroup analysis by study design is only available for postoperative day 7, which indicated a significant difference for both the parallel design and the split-mouth design studies.

DISCUSSION

In this study, we performed a systematic literature search and conducted meta-analysis to compare piezosurgery and conventional rotary osteotomy techniques in third molar extraction. We found that although the patients undergoing piezosurgery experienced longer surgery time, they developed less swelling when compared with those undergoing conventional rotary techniques. Patients who underwent piezosurgery also seemed to have experienced less pain during piezosurgery, and developed less postoperative trismus, although these findings are not conclusive due to the limited sample size. To the best of our knowledge, this is the first meta-analysis of RCTs to compare piezosurgery with rotary osteotomy techniques in third molar extraction.

Compared with surgery using rotary techniques, piezosurgery was more time-consuming due to the slower




FIGURE 4. Forest plot for meta-analysis of the difference in postoperative pain between piezosurgery versus rotary osteotomy technique in third molar extraction. A, Day 1 after surgery; B, day 3 after surgery; C, day 5 after surgery; D, day 7 after surgery.

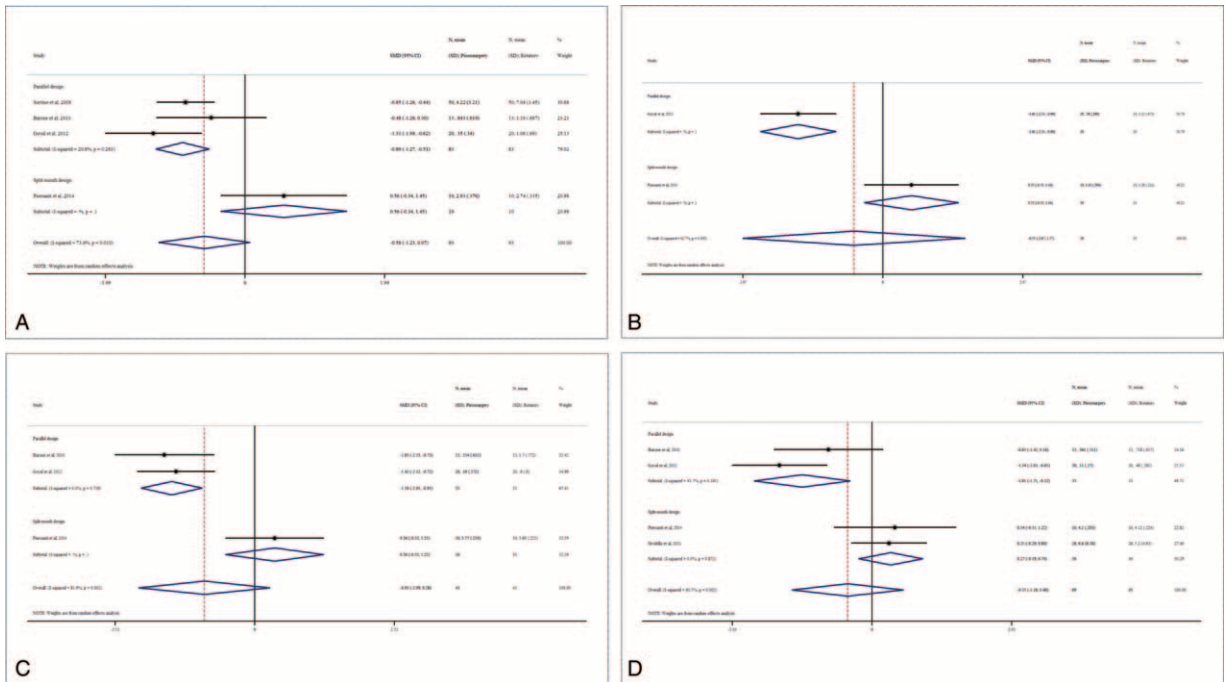


FIGURE 5. Forest plot for meta-analysis of the difference in postoperative trismus between piezosurgery versus rotary osteotomy technique in third molar extraction. A, Day 1 after surgery; B, day 3 after surgery; C, day 5 after surgery; D, day 7 after surgery.

micrometric cutting action of the piezoelectric device. Surgery time using the ultrasonic osteotomy tended to be shorter as the surgeons accumulated more experience.²⁵ Therefore, although the piezoelectric technique is associated with longer surgery time, we believe that with increased experience and the

improvement of the technique, piezosurgery will witness reduced surgery time.

Although there was a trend of less pain in piezosurgery, the difference did not reach statistical significance; however, we may not have sufficient power due to the limited sample size. In

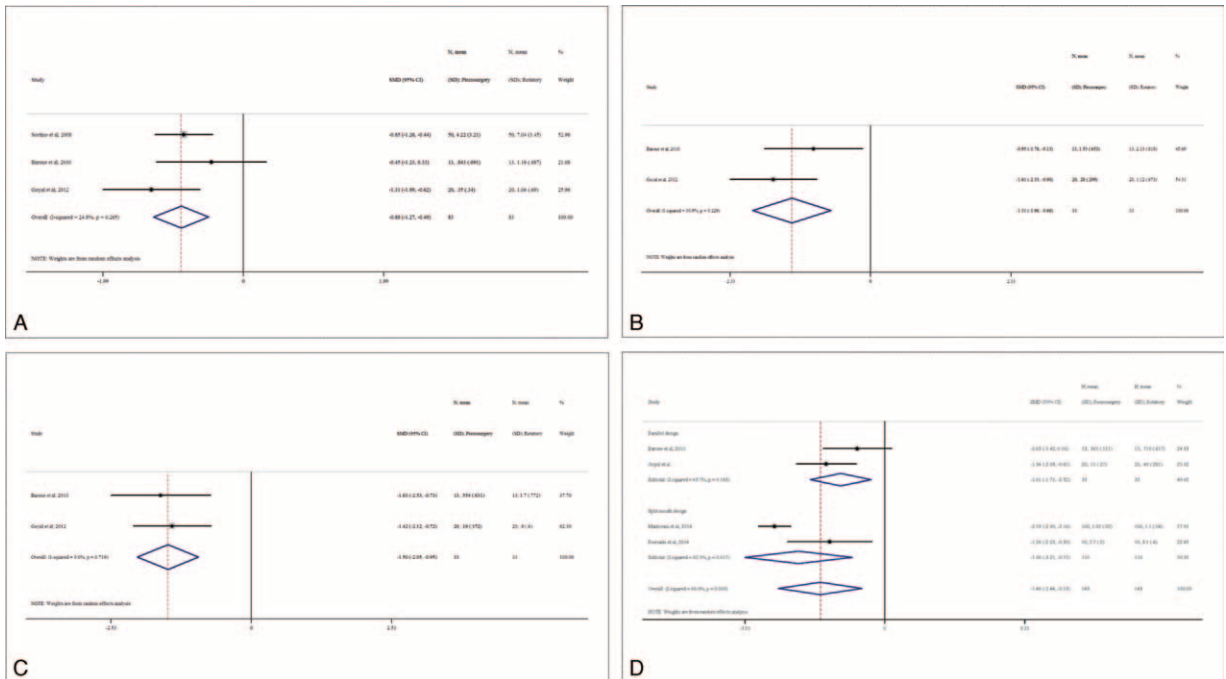


FIGURE 6. Forest plot for meta-analysis of the difference in postoperative swelling between piezosurgery versus rotary osteotomy technique in third molar extraction. A, Day 1 after surgery; B, day 3 after surgery; C, day 5 after surgery; D, day 7 after surgery.

addition, the validity of the results might be affected by several factors. Piezosurgery and high-speed air turbine hand pieces are not the same across studies. The impacted types of the mandibular third molars also differ among trials. Moreover, the surgeons' skills and experiences and patients' pain sensitivity might be different, which could influence the assessment of the level of postoperative pain. More or larger homogeneous RCTs are needed to validate our findings.

In addition to less swelling, and possibly less trismus, piezosurgery has other advantages. The bone samples harvested using piezosurgery were characterized by the integrity of the bony structure, a well defined osteotomy, but no evidence of bone heat osteonecrosis.¹⁹ Other clinical trials of the maxillary sinus floor elevation also confirmed a lack of coagulative necrosis on the surfaces of the bony segments via ultrasound osteotomy.^{26,27} Research on the osseointegration of oral titanium implants reported that piezosurgery induced an earlier increase in bone morphogenic proteins (BMPs), controlled the inflammatory process better, and stimulated bone remodeling.^{10,28} These data suggest that the alveolar bone removed by the use of a piezoelectric device for third molar extraction can be used for bone augmentation in implant placement.

Our study has some limitations. First, the number of included RCTs and the sample size of each trial were relatively small. Second, double blinding was not possible for obvious reasons, leading to unclear performance bias. Third, piezoelectric devices generally cost more than rotary devices; however, a cost analysis was unavailable in this meta-analysis due to the lack of data. Moreover, data are scarce on other postoperative complications after the extraction of impacted mandibular third molars, such as alveolitis, infection, and paresthesia; therefore, a meta-analysis of such complications was not feasible. Future studies are needed to compare the incidence of other common postoperative complications between the two approaches.

In summary, in this study, we conducted an extensive literature search and performed meta-analysis to compare piezosurgery with rotary osteotomy techniques in third molar extraction. We found that the patients undergoing piezosurgery had significantly less swelling. There was also a trend of less pain and trismus in piezosurgery, when compared with rotary osteotomy. More large-scale and multicenter RCTs using a unified grading system and evaluation index are needed to validate our findings and provide guidance for clinical applications.

ACKNOWLEDGMENTS

We thank Dr Jing Gao from The State Key Laboratory of Oncogene and Related Genes & Department of Epidemiology of Renji Hospital, Shanghai Jiaotong University School of Medicine, Shanghai, China for her help with the evaluation of bias.

REFERENCES

1. Waite PD, Reynolds RR. Surgical management of impacted third molars. *Semin Orthod*. 1998;4:113–123.
2. Breik O, Grubor D. The incidence of mandibular third molar impactions in different skeletal face types. *Aust Dent J*. 2008;53:320–324.
3. Celikoglu M, Miloglu O, Kazanci F. Frequency of agenesis, impaction, angulation, and related pathologic changes of third molar teeth in orthodontic patients. *J Oral Maxillofac Surg*. 2010;68:990–995.
4. Kumar BS, TS MV, Raman U. To compare standard incision and comma shaped incision and its influence on post-operative complications in surgical removal of impacted third molars. *J Clin Diagn Res*. 2013;7:1514–1518.
5. Guven O, Keskin A, Akal UK. The incidence of cysts and tumors around impacted third molars. *Int J Oral Maxillofac Surg*. 2000;29:131–135.
6. Fernandes MJ, Ogen GR, Pitts NB, et al. Incidence of symptoms in previously symptom-free impacted lower third molars assessed in general dental practice. *Br Dent J*. 2009;207:E10(discussion 218–219).
7. Sidlauskas A, Trakiniene G. Effect of the lower third molars on the lower dental arch crowding. *Stomatologija*. 2006;8:80–84.
8. Rakprasitkul S. Pathologic changes in the pericoronal tissues of unerupted third molars. *Quintessence Int*. 2001;32:633–638.
9. Eshghpour M, Nejat AH. Dry socket following surgical removal of impacted third molar in an Iranian population: incidence and risk factors. *Niger J Clin Pract*. 2013;16:496–500.
10. Preti G, Martinasso G, Peirone B, et al. Cytokines and growth factors involved in the osseointegration of oral titanium implants positioned using piezoelectric bone surgery versus a drill technique: a pilot study in minipigs. *J Periodontol*. 2007;78:716–722.
11. Pippi R, Alvaro R. Piezosurgery for the lingual split technique in mandibular third molar removal: a suggestion. *J Craniofac Surg*. 2013;24:531–533.
12. Kerawala CJ, Martin IC, Allan W, et al. The effects of operator technique and bur design on temperature during osseous preparation for osteosynthesis self-tapping screws. *Oral Surg Oral Med Oral Pathol Oral Radiol Endod*. 1999;88:145–150.
13. Vercellotti T, Nevins ML, Kim DM, et al. Osseous response following resective therapy with piezosurgery. *Int J Periodontics Restorative Dent*. 2005;25:543–549.
14. Maurer P, Kriwalsky MS, Block Veras R, et al. Light microscopic examination of rabbit skulls following conventional and piezosurgery osteotomy. *Biomed Tech (Berl)*. 2007;52:351–355.
15. Sortino F, Pedulla E, Masoli V. The piezoelectric and rotatory osteotomy technique in impacted third molar surgery: comparison of postoperative recovery. *J Oral Maxillofac Surg*. 2008;66:2444–2448.
16. Barone A, Marconcini S, Giacomelli L, et al. A randomized clinical evaluation of ultrasound bone surgery versus traditional rotary instruments in lower third molar extraction. *J Oral Maxillofac Surg*. 2010;68:330–336.
17. Sivoilella S, Berengo M, Bressan E, et al. Osteotomy for lower third molar germectomy: randomized prospective crossover clinical study comparing piezosurgery and conventional rotatory osteotomy. *J Oral Maxillofac Surg*. 2011;69:e15–e23.
18. Goyal M, Marya K, Jhamb A, et al. Comparative evaluation of surgical outcome after removal of impacted mandibular third molars using a Piezotome or a conventional handpiece: a prospective study. *Br J Oral Maxillofac Surg*. 2012;50:556–561.
19. Rullo R, Addabbo F, Papaccio G, et al. Piezoelectric device vs. conventional rotative instruments in impacted third molar surgery: relationships between surgical difficulty and postoperative pain with histological evaluations. *J Craniomaxillofac Surg*. 2013;41:e33–e38.
20. Mantovani E, Arduino PG, Schierano G, et al. A split-mouth randomized clinical trial to evaluate the performance of piezosurgery compared with traditional technique in lower wisdom tooth removal. *J Oral Maxillofac Surg*. 2014;72:1890–1897.
21. Piersanti L, Dilorenzo M, Monaco G, et al. Piezosurgery or conventional rotatory instruments for inferior third molar extractions? *J Oral Maxillofac Surg*. 2014;72:1647–1652.
22. Zeng X, Zhang Y, Kwong JS, et al. The methodological quality assessment tools for preclinical and clinical studies, systematic review and meta-analysis, and clinical practice guideline: a systematic review. *J Evid Based Med*. 2015;8:2–10.

23. Moher D, Liberati A, Tetzlaff J, et al. Preferred reporting items for systematic reviews and meta-analyses: the PRISMA statement. *PLoS Med.* 2009;6:e1000097.
24. Bartuli FN, Luciani F, Caddeo F, et al. Piezosurgery vs high speed rotary handpiece: a comparison between the two techniques in the impacted third molar surgery. *Oral Implantol (Rome)*. 2013;6:5–10.
25. Beziat JL, Bera JC, Lavandier B, et al. Ultrasonic osteotomy as a new technique in craniomaxillofacial surgery. *Int J Oral Maxillofac Surg.* 2007;36:493–500.
26. Vercellotti T. Technological characteristics and clinical indications of piezoelectric bone surgery. *Minerva Stomatol.* 2004;53:207–214.
27. Vercellotti T, De Paoli S, Nevins M. The piezoelectric bony window osteotomy and sinus membrane elevation: introduction of a new technique for simplification of the sinus augmentation procedure. *Int J Periodontics Restorative Dent.* 2001;21:561–567.
28. Di Alberti L, Donnini F, Di Alberti C, et al. A comparative study of bone densitometry during osseointegration: piezoelectric surgery versus rotary protocols. *Quintessence Int.* 2010;41:639–644.