

## CASE REPORT

# Clinically mild encephalitis/encephalopathy with reversible splenic lesion (MERS) associated with *Mycoplasma pneumoniae* pneumonia: An adult case and review of the literature

Michito Sadohara<sup>1</sup>  | Tatsuya Arai<sup>2</sup> | Kou Matsuura<sup>3</sup>

<sup>1</sup>Department of Community, Family, and General Medicine, Kumamoto University Hospital, Kumamoto, Japan

<sup>2</sup>Department of Nephrology, Sakai City Medical Center, Sakai, Japan

<sup>3</sup>Department of Gastroenterology, Kishiwada Tokushukai Hospital, Kishiwada, Japan

## Correspondence

Michito Sadohara, Department of Community, General, and Family Medicine, Kumamoto University Hospital, 1-1-1 Honjo, Chuo-ku, Kumamoto, 860-8556, Japan.  
Email: msadohara@kumamoto-u.ac.jp

## Abstract

*Mycoplasma pneumoniae* with mild CNS involvements should be considered of MERS, even in adult. From the case series, splenic single lesions by MRI and prodromal fever with varied neurological manifestations recovered completely by antibiotics were seen.

## KEY WORDS

adult-onset MERS, clinically mild encephalitis, encephalopathy, encephalopathy with reversible splenic lesion (MERS), *Mycoplasma pneumoniae* pneumonia, reversible splenic lesion

## 1 | INTRODUCTION

Mild encephalitis/encephalopathy with a reversible splenic lesion (MERS) is a rare clinico-radiological syndrome mainly seen in pediatric cases. Adult cases are relatively rare, and the etiology of *Mycoplasma pneumoniae* is also rare in both pediatric and adult cases.

Mild encephalitis/encephalopathy with a reversible splenic lesion (MERS) is a clinico-radiological syndrome, first identified by Tada et al in 2004,<sup>1</sup> in a case series of 15 patients. Magnetic resonance imaging (MRI) findings are characterized with a reversible lesion in the splenium of the corpus callosum (SCC). The prodromal symptoms include fever, vomiting, diarrhea, and cough. The most common neurological symptom is delirious behavior, followed by disturbance of consciousness and seizures, all of which completely resolve within a month.<sup>2</sup>

Although most case reports of MERS mainly pertain to pediatric patients, an increase in the use of MRI for encephalitis

or encephalopathy has led to a recent increase in the number of adult MERS reports. However, reports of MERS associated with *M pneumoniae* infections are very rare in both adults and children.

## 2 | CASE

A previously healthy 17-year-old male presented at a medical clinic with a 39°C fever, a cough, a sore throat, and sputum 5 days prior to hospital admission. His rapid diagnostic influenza test was negative, and he was prescribed acetaminophen and cefcapene pivoxil. Showing no signs of improvement, he visited the clinic a second time and a plain chest radiograph showed an abnormal shadow, and levofloxacin was prescribed for suspected *M pneumoniae* infection 3 days prior to hospital admission. His verbal responses to his parents were poor, and he often engaged in monologues. On the day prior

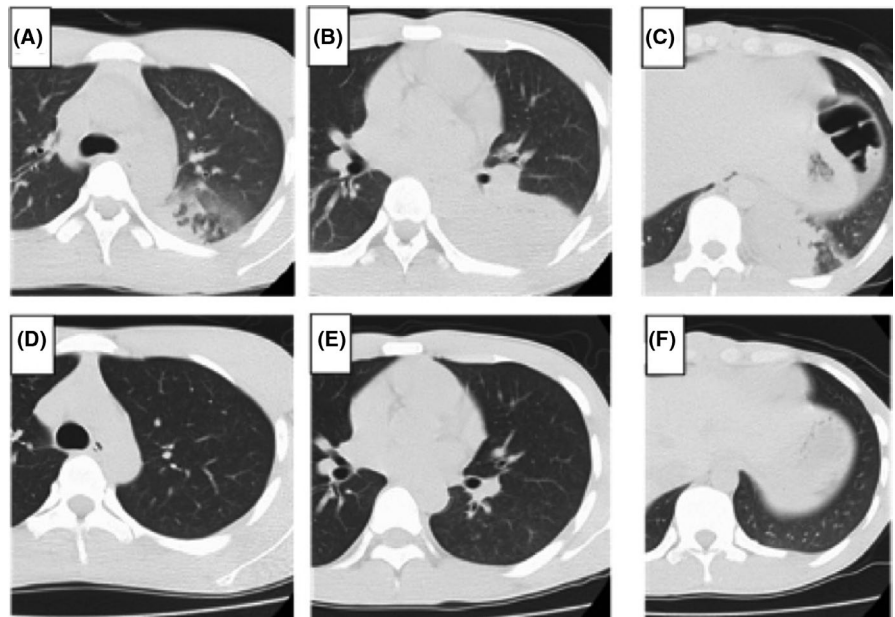
This is an open access article under the terms of the Creative Commons Attribution-NonCommercial-NoDerivs License, which permits use and distribution in any medium, provided the original work is properly cited, the use is non-commercial and no modifications or adaptations are made.

© 2020 The Authors. *Clinical Case Reports* published by John Wiley & Sons Ltd

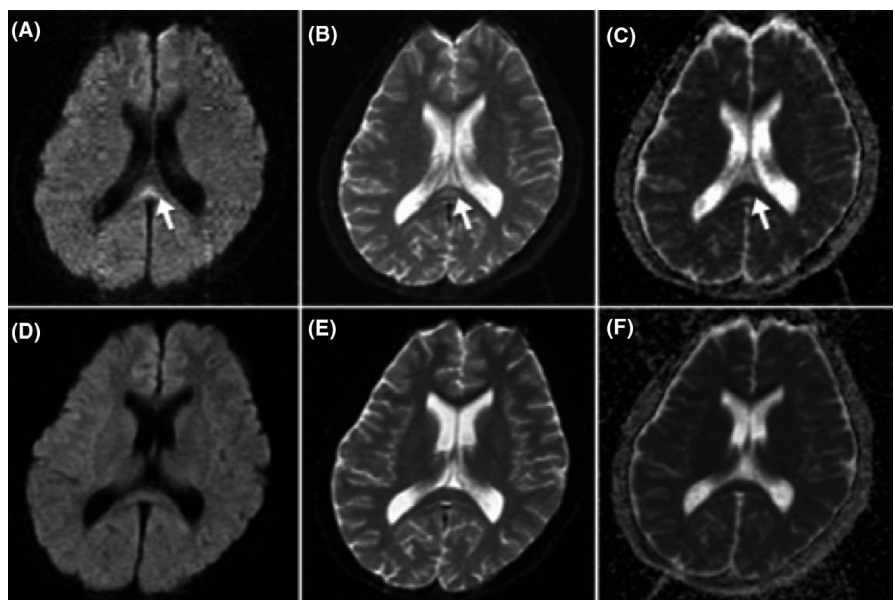
to admission, communication with his parents was no longer possible. He was admitted to the hospital by ambulance, unresponsive, and sweating.

His vital signs were as follows: body temperature, 38.2°C; blood pressure, 162/82 mm Hg; pulse rate, 97 beats/min; respiratory rate, 24/min; SpO<sub>2</sub>, 96% on room air; with a Glasgow Coma Score of E4-V2-M4. Laboratory data showed an elevated C-reactive protein (10.7 mg/dL) and an erythrocyte sedimentation rate of 27 mm/hour, a normal white blood cell count, and mild hyponatremia (Na 132 mEq/L). His cerebrospinal fluid (CSF) was clear and colorless with normal initial pressure (<180 mm of water), and CSF cell count was 1 cell/mm<sup>3</sup>, glucose of 71 mg/dL, protein of 12.8 mg/dL. A chest computed tomography (CT)

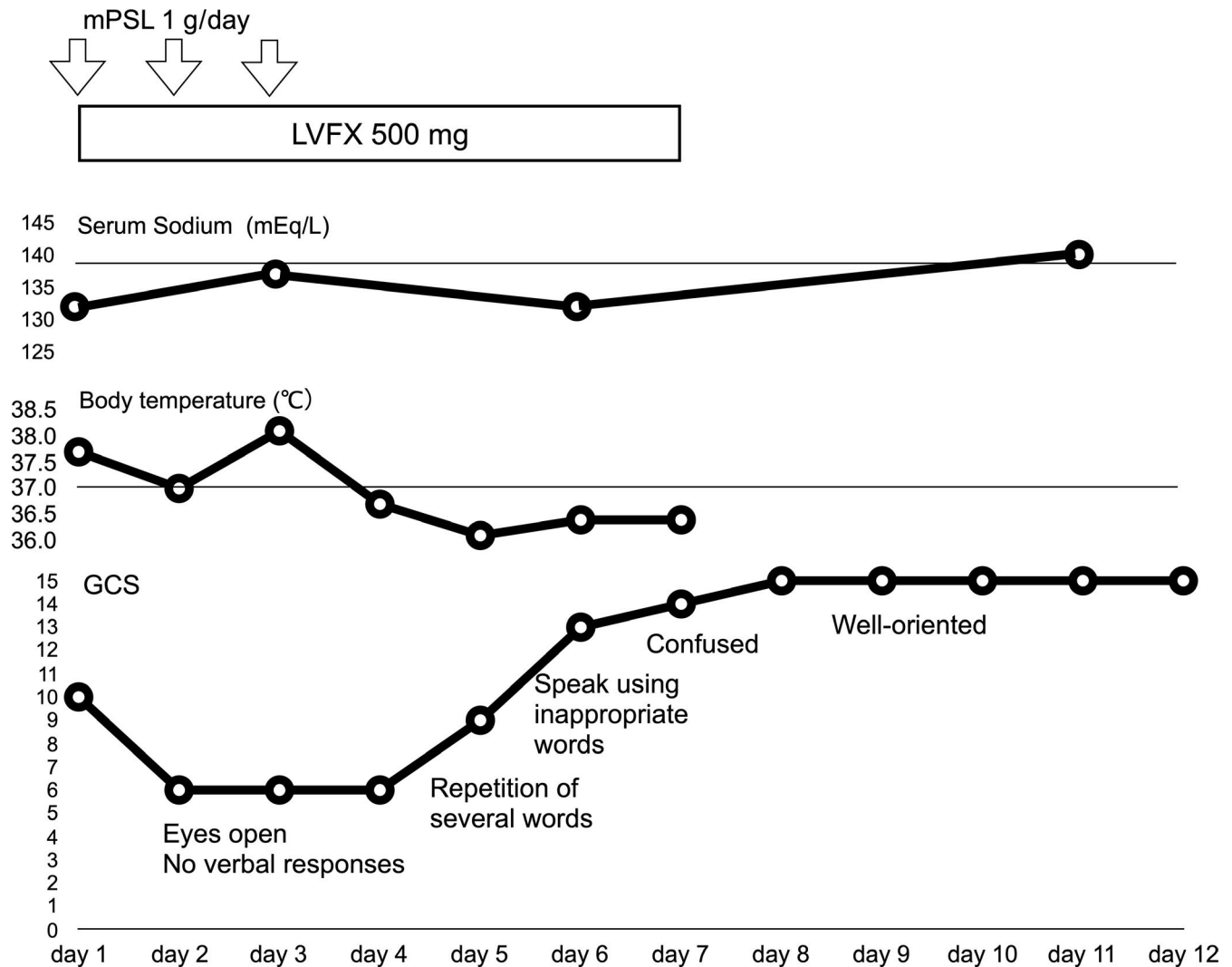
scan showed an air-space consolidation mainly within his left lower lung lobe (Figure 1A,B,C). *Mycoplasma pneumoniae* DNA tests were positive using loop-mediated isothermal amplification (LAMP) assay. MRI revealed an SCC lesion (Figure 2A,B,C). MERS associated with *M pneumoniae* pneumonia was suspected, levofloxacin was continued parenterally, and steroid pulse therapy by 3 days of 1 g of prednisolone was administered. His fever and cough resolved on day 4 of hospital admission. He gradually regained consciousness and was able to form simple sentences on day 6 and was fully alert and coherent on day 8 (Figure 3). On day 7, the air-space consolidation that had been identified on the chest CT disappeared completely (Figure 1D,E,F), and the brain MRI showed complete resolution of the SCC lesion



**FIGURE 1** Chest CT. Chest CT showing nonsegmental dense air-space consolidation in the left lower lung lobe (B) with a confluent air-space nodule around its edge in a centrilobular distribution and ground-grass attenuation (A, C) on admission, that had completely disappeared on day 7 following hospital admission



**FIGURE 2** Brain MRI. (A) Brain MRI scan showing hyperintensity on diffusion-weighted images, (B) T2-weighted images, (C) low signal of the apparent diffusion coefficient map in the selenium of the corpus callosum (SCC) on admission (white arrow indicates the SCC lesion), (D) complete resolution of the SCC lesion on diffusion-weighted images, (E) and on T2-weighted images (F) the apparent diffusion coefficient map on day 7 after admission



**FIGURE 3** Clinical course. Abbreviation: GCS, Glasgow Coma Scale; mPSL, methyl prednisolone; LVFX, levofloxacin

(Figure 2D,E,F). In addition to the detection of *M pneumoniae* DNA using LAMP assay, *M pneumoniae* infection was serologically confirmed using a PA test for *M pneumoniae* antibodies that showed a four-fold increase from <40-fold on admission day to 320-fold on day 10. Our patient fully recovered without neurological sequelae and was discharged from hospital on day 12.

### 3 | DISCUSSION

Hoshino et al<sup>3</sup> advocated using diagnostic criteria of MERS, based on a Japanese nationwide survey on the epidemiology of acute encephalopathy in Japan, derived from a questionnaire in 2012 (Table 1). In addition to its clinical course, *M pneumoniae* pneumonia has been diagnosed using radiology, serology, and DNA detection. We considered our case to be an adult case of MERS associated with *M pneumoniae* pneumonia.

**TABLE 1** Mild encephalitis/encephalopathy with a reversible splenial lesion diagnostic criteria<sup>3</sup>

1. Onset with neuropsychiatric symptoms, such as abnormal speech and/or behavior, and impaired consciousness and convulsion, within 1 wk after the onset of fever.
2. Complete recovery without sequelae, mostly within 10 d after the onset of neuropsychiatric symptoms.
3. High-signal-intensity lesion in the splenium of the corpus callosum, in the acute stage. T1 and T2 signal changes are mild.
4. The lesion may involve the entire corpus callosum and the cerebral white matter in a symmetric fashion.
5. The lesion disappears within a week, with neither residual signal changes nor atrophy.

Since MERS was identified by Tada et al in 2004, various causative pathogens have been reported, including the influenza virus (the most common pathogen in pediatric cases), adenovirus, mumps virus, varicella-zoster virus, hepatitis A virus, rotavirus, herpes simplex virus, human herpes virus 6, flavivirus, respiratory syncytial virus, *Legionella*

TABLE 2 Adult cases of MERS associated with *M pneumoniae* infection

No.	Age, y/Sex	Prodrome	Days from onset to admission	CNS manifestation	Therapy	Prognosis		
1	18/M	FE, AC	6 d	AC	LVFX, 1 g of mPSL pulse therapy for 3 d	CR 14 d from onset; SCC lesion on MRI subsided on 7th hospital days		
2	17/F	FE, H, N/V, myalgia	NA	H, MS	AZM	CR 15 d from onset		
3	30/M	FE, AC	NA	AC	LVFX	Consciousness went alert on 3rd hospital days; MRI results were normal 1 wk from onset		
4	26/F	FE	6 d	AC, H, S	MLs, MFLX, mannitol, diazepam	CR within 10 d; SCC lesion on MRI subsided on 22nd days from onset		
5	45/M	FE	4 d	AC	MINO	CR clinically 8 d from onset; SCC lesion on MRI subsided on 17th days from onset		
6	37/M	FE, limb tremors	3 d	AC, S, Vertigo	LVFX, AZM	CR clinically 4 d from onset; SCC lesion on MRI subsided on 24th days from onset		
7	21/F	FE	4 d	H	MINO	CR clinically 10 d from onset; SCC lesion on MRI subsided on 21st days from onset; EEG and SPECT abnormal findings lasted beyond 1 mo		
8	44/M	FE, H	1-3 d	H	MFLX	CR		
9	31/F	FE, H	3 d	MS, AC, H	AZT	CR after 6 d on admission; SCC lesion on MRI disappeared at day 10 following admission		
10	33/F	FE, H	7 d	AC, Blurred vision, amaurosis, limb weakness, MS	Mannitol, ganciclovir, AZT, mPSL (20 mg/kg/day) for a week, Ig	CR including right limb muscle weakness after 10 d of admission SCC lesion on MRI on day 24 revealed no abnormalities		
11	40/M	FE, H	More than 10 d	AC, Blurred vision, limb weakness, MS	Mannitol, ganciclovir, CTRX, AZT	Headache and blurred vision improved on 7th day on admission; fever subsided on day 14; SCC lesion on follow-up MRI scan on did not show obvious anomalies		
No.	Age, y/Sex	Diagnostic test for MP	Laboratory data	Chest CT	CSF	MRI	EEG	Reference, Country, Year of report
1	18/M	PA, LAMP	Na 132 mEq/L, WBC 7800/ $\mu$ L, CRP 10.7 mg/dL	ASC	Normal	Type I	ND	Our case, Japan, 2017

(Continues)

TABLE 2 (Continued)

No.	Age, y/Sex	Diagnostic test for MP	Laboratory data	Chest CT	CSF	MRI	EEG	Reference, Country, Year of report
2	17/F	MP IgM in CSF, serum MP Ab	Na: normal WBC: normal	NA	MP IgM detected	Type I	NA	(ref. 12), China, 2012
3	30/M	PA	NA	Infiltrative shadows	NA	Type I	ND	(ref. 8), Japan, 2012
4	26/F	MP IgM in CSF	NA	NA	EP, MP IgM detected	Type I	SLW	(ref. 9), China, 2012
5	45/M	PA	WBC 7100/ $\mu$ L, CRP 20.55 mg/dL	ASC	Normal	Type I	ND	JSIM RC DB, Japan, 2012
6	37/M	MP Ag test	NA	Abnormal shadow	ND	Type I	ND	JSIM RC DB, Japan, 2017
7	21/F	PA	WBC 4700/ $\mu$ L, CRP 11.5 mg/dL	ASC	Normal	Type I	SHW	JSIM RC DB, Japan, 2017
8	44/M	LAMP	NA	Consolidation	Normal	Type I	ND	JSIM RC DB, Japan, 2017
9	31/F	Serum MP IgM, Paired titers of serum MP IgG	NA	Infective lesion	EP, High WCC	Type I	NA	(ref 13), China, 2018
10	33/F	Serum MP IgM, Paired titers of serum MP IgG	NA	Infective lesions	EP, high WCC	Type I	NA	(ref 13), China, 2018
11	40/M	Serum MP Ab	NA	Infective lesions	EP, high WCC high protein, low glucose	Type I	NA	(ref 13), China, 2018

Abbreviations: Ab, antibody; AC, altered consciousness; Ag, antigen; ASC, air-space consolidation; AZM, azithromycin; CNS, central nervous system; CRP, C-reactive protein; CSF, cerebrospinal fluid; CT, computer tomography; CTRX, ceftriaxone; EEG, electroencephalogram; EP, elevated pressure; F, female; FE, fever elevation; H, headache; Ig, immunoglobulin; IgM, immunoglobulin M; JSIM RC DB, Japanese Society of Internal Medicine regional conference database; LAMP, loop-mediated isothermal amplification; LVFX, levofloxacin; M, male; MFLX, moxifloxacin; MINO, minocycline; MLS, macrolides; MP, *M pneumoniae*; mPSL, methylprednisolone; MRI, magnetic resonance imaging; MS, meningeal sign; NV, nausea and vomiting; NA, not available; ND, not done; PA, particle agglutination assay; S, seizures; SCC, splenium of corpus callosum; SHW, sharp wave; SLW, slow wave; SPECT, single photon emission computed tomography; WBC, white blood cells; WCC, white cell count.

*pneumophila*, *Streptococcus pneumoniae*, *Escherichia coli*, and *Enterococcus faecalis*.<sup>1,3</sup> *Mycoplasma pneumoniae* is the most common pathogen identified in outpatient settings (27.4%) and has been reported to be the third most causative inpatient pathogen (9.3%) of all pathogens concerning community-acquired pneumonia in Japan.<sup>4</sup> *Mycoplasma pneumoniae* can cause extrapulmonary manifestations including central nervous system manifestations.<sup>5,6</sup> According to nationwide surveillance of acute encephalopathy data in Japan, the median age for the onset of MERS is 5 years of age (average and standard deviation,  $5.6 \pm 3.7$  years).<sup>3</sup> Okoshi et al<sup>7</sup> first reported MERS associated with *M pneumoniae* pneumonia in a child in 2009. The first adult case (a 30-year-old male) was reported by Shibuya et al<sup>8</sup> in 2012. Both case reports involved Japanese patients.

We searched PubMed for retrospective literature to identify adult MERS associated with *M pneumoniae* infections, and we identified 5 additional Chinese cases that had been associated with *M pneumoniae*.<sup>9–13</sup> An additional search through the abstracts database of the Japanese Society of Internal Medicine regional conferences identified 4 additional cases. Table 2 is a list of adult cases of MERS associated with *M pneumoniae* infections, including our case, and all patients were young- to middle-aged adults (range, 17–45 years; six males: five females). All initial symptoms included fever elevation. Central nervous system manifestations varied from mild symptoms such as headache alone (case 7, 8), vertigo (case 6), blurred vision (case 10, 11), and conscious disturbance (case 1, 3–6, 9–11) to meningeal signs (case 2, 9, 10, 11), limb weakness (case 10, 11), seizures (case 4) that resolved clinically, except in one case where it had been reported that abnormal electroencephalogram (EEG) and single photon emission computed tomography (SPECT) findings lasted longer than 1 month from the onset of the disease (case 8). MERS MRI findings have been classified according to lesion location into type I, presenting as a single lesion in the middle of SCC, and type II, involving additional lesions of similar MRI signal characteristics in other parts of the brain. Time to recovery, as determined using MRI findings, and the risks of neurological sequelae were more common in type 2 than in type 1 in pediatric MERS cases associated with *M pneumoniae*.<sup>14</sup> Of all cases listed in Table 2, all of the MRI findings are listed as type I, and all lesions disappeared within 1 month of onset.

The possible pathogenesis of central nervous system manifestations of *M pneumoniae* infection is classified using three overlapping pathomechanisms: a direct type, with neural damage due to cytokines, for example; a vascular occlusion type, with vasculitis and thrombosis or vasculopathy and embolism; and an indirect type, due to autoimmunity.<sup>5,15</sup> It has been suggested that intrathecally detectable antibodies against the bacterium, arising both from intrathecal synthesis and outside the central nervous system through

the immune-mediated process, can mediate the disease.<sup>16</sup> *Mycoplasma* IgM were detected in two cases among those where CSF studies had been undertaken (case 2, 4).

Mechanisms through which the SCC signal changes in MERS have been proposed as follows: hyponatremia<sup>17</sup> (in case 1) and febrile illness (evident in all cases) evoking an inflammatory cytokine release resulting in overexpression of the excitatory neurotransmitter glutamate and ultimately leading to cellular swelling and cytotoxic edema.<sup>18</sup> Moreover, it has been suggested that intramyelinic edema results in a decreased apparent diffusion coefficient of the lesions.<sup>1</sup>

All therapies targeting *M pneumoniae* used antibiotics such as levofloxacin, azithromycin, minocycline, and moxifloxacin. Concerning the emergence and spreading of macrolide-resistant *M pneumoniae*, in cases where macrolide treatment fails, a change to second-line antibiotics other than macrolides is recommended.<sup>19</sup> All antibiotic treatments for *M pneumoniae* were successful in this case series. Two patients (case 2, 9) were treated with macrolides alone. In two patients including our case (case 1, 10), steroid therapy was used. In a pediatric case series of MERS associated with *M pneumoniae*, almost half the patients were prescribed steroid therapy in addition to antibiotic therapy<sup>16</sup> and, in another adult case series of MERS, approximately one-third of patients were administered steroid therapy.<sup>10</sup> We consider steroid therapy can be used depending on neurological severity.

Together with advances in the diagnostic imaging by MRI for encephalitis/encephalopathy and their active utilization, and the technology using validated reliable diagnostic methods for *M pneumoniae*, case reports, and the resulting accumulation of comprehensive findings including pathomechanisms, diagnosis, and treatments are likely to increase.

## 4 | CONCLUSION

We encountered a young adult case of MERS associated with *M pneumoniae* pneumonia. Most case studies concerning MERS have reported pediatric cases, and reports of MERS associated with *M pneumoniae* infections are very rare in both adults and children. Our case report also identified *M pneumoniae* as the pathogen of MERS in an adult. Further studies concerning the clinical findings, pathomechanisms, diagnosis, and treatment of adult MERS cases are needed.

## ACKNOWLEDGMENTS

Published with written consent of the patient.

## CONFLICT OF INTEREST

All authors have no conflicts of interest to declare.

## AUTHOR CONTRIBUTIONS

All authors participated in the management of this case, and the drafted and revised the manuscript. MS: involved in conception and design and submission of manuscript. TA and KM: performed searching and analyzed the relevant cases, and contributed to obtain informed consent from the patient.

## ETHICAL APPROVAL

Ethical approval was obtained from the Ethical Committee of the medical institution this case were encountered.

## CONSENT FOR PUBLICATION

The patient and a parent gave written informed consent for publication of this case report.

## ORCID

Michito Sadohara  <https://orcid.org/0000-0003-3095-676X>

## REFERENCES

1. Tada H, Takanashi J, Barkovich AJ, et al. Clinically mild encephalitis/encephalopathy with a reversible splenial lesion. *Neurology*. 2004;63:1854-1858.
2. Takahashi J. Two newly proposed infectious encephalitis/encephalopathy syndromes. *Brain Dev*. 2009;31:521-528.
3. Hoshino A, Saitoh M, Oka A, et al. Epidemiology of acute encephalopathy in Japan, with emphasis on the association of viruses and syndromes. *Brain Dev*. 2012;34:337-343.
4. Miyashita N, Fukano H, Mouri K, et al. Community-acquired pneumonia in Japan; a prospective ambulatory and hospitalized patient study. *J Med Microbiol*. 2005;54:395-400.
5. Narita M. Classification of extrapulmonary manifestations due to *Mycoplasma pneumoniae* infection on the basis of possible pathogenesis. *Front Microbiol*. 2016;7:23.
6. Tsiodras S, Kelesidis I, Kelesidis T, et al. Central nervous system manifestation of *Mycoplasma pneumoniae* infections. *J Infect*. 2005;51:343-354.
7. Okoshi Y, Sakai T, Nonaka S, et al. A case of encephalopathy in the splenium of the corpus callosum accompanied by *Mycoplasma pneumoniae* pneumonia. (in Japanese). *Nihon Shonika Gakkai Zasshi (J Jpn Pediatr Soc)*. 2009;113(2):350.
8. Shibuya H, Osamura K, Hara K, et al. Clinically mild encephalitis/encephalopathy with a reversible splenial lesion due to *Mycoplasma pneumoniae* infection. *Intern Med*. 2012;51:1647-1648.
9. Zhang S, Ma Y, Feng J. Clinicoradiological spectrum of reversible splenial lesion syndrome (RESLES) in adults: a retrospective study of a rare entity. *Med*. 2015;94(6):e512.
10. Yuan J, Yang S, Wang S, et al. Mild encephalitis/encephalopathy with reversible splenial lesion (MERS) in adults—a case report and literature review. *BMC Neurol*. 2017;17:103.
11. Pan JJ, Zhao YY, Lu C, et al. Mild encephalitis/encephalopathy with reversible splenial lesion: five cases and a literature review. *Neurol Sci*. 2015;36:2043-2051.
12. Dong XY, Xian JF. Four cases of mild encephalopathy with reversible lesion. (in Chinese.). *Zhongguo Zonghe Linchuang Zazhi (Clin Med China)*. 2012;28(11):1166-1167.
13. Dang X, Cong S. Reversible splenial lesion syndrome associated with acute *Mycoplasma pneumoniae*-associated encephalitis: a report of four cases and literature review. *Exp Ther Med*. 2018;16(3):2152-2159.
14. Ueda N, Minami S, Akimoto M. *Mycoplasma pneumoniae*-associated mild encephalitis/encephalopathy with a reversible splenial lesion: report of two pediatric cases and a comprehensive literature review. *BMC Infect Dis*. 2016;16:671.
15. Bitnum A, Richardson SE. *Mycoplasma pneumoniae*: innocent bystander or a true cause of central nervous system disease? *Curr Infect Dis Rep*. 2010;12:282-290.
16. Meyer Sauter PM, Jacobs BC, Spuesens EB, et al. Antibody responses to *Mycoplasma pneumoniae*: role in pathogenesis and diagnosis of encephalitis? *PLOS Pathog*. 2014;10(6):e1003983.
17. Takanashi J, Tada H, Maeda M, et al. Encephalopathy with reversible splenial lesion is associated with hyponatremia. *Brain Dev*. 2009;31:217-220.
18. Lin D, Rheinboldt M. Reversible splenial lesions presenting in conjunction with febrile illness: a case series and literature review. *Emerg Radiol*. 2017;24:599-604.
19. Yamazaki T, Kenri T. Epidemiology of *Mycoplasma pneumoniae* infections in Japan and therapeutic strategies for macrolide-resistant *M pneumoniae*. *Front Microbiol*. 2016;7:693.

**How to cite this article:** Sadohara M, Arai T, Matsuura K. Clinically mild encephalitis/encephalopathy with reversible splenial lesion (MERS) associated with *Mycoplasma pneumoniae* pneumonia: An adult case and review of the literature. *Clin Case Rep*. 2020;8:2954–2960. <https://doi.org/10.1002/ccr3.3342>