

Received: 2012.11.15
Accepted: 2013.01.02

Usefulness of spinal magnetic resonance imaging in patients with myelodysplastic syndromes

Anna Kwiatkowska-Pamuła^{1,2}, Ewa Ziółko^{1,2}, Małgorzata Muc-Wierżgoń¹,
Ewa Nowakowska-Zajdel¹, Ewa Podwińska³, Tomasz Adamczyk⁴

¹ Clinical Department of Internal Diseases, Medical University of Silesia in Katowice, Hospital No.1 in Bytom, Bytom, Poland

² Department of Hematology, Hospital No. 1 in Bytom, Bytom, Poland

³ Clinic of Anesthesiology and Intensive Care, Medical University of Silesia in Katowice, Katowice, Poland

⁴ NZOZ 'Voxel', Medical Diagnostic Centres, Magnetic Resonance Laboratory, Hospital No. 1 in Bytom, Bytom, Poland

Author's address: Ewa Ziółko, Department and Clinical Ward of Internal Diseases of the Medical University of Silesia, Bytom, Poland, e-mail: evavita@poczta.onet.pl

Summary

Background:

Myelodysplastic syndrome is a rare, chronic hematological disease characterized by heterogeneous clinical presentations. Subtypes of myelodysplastic syndrome are characterized by different survival times and ability to transform into acute myeloid leukemia.

Objectives:

The objective of the study included the assessment of the relationship between the images obtained by magnetic resonance scans of lumbar spine and the clinical symptoms of the disease in patients diagnosed with myelodysplastic syndrome, as well as the assessment of the correlation of the images with the phase of transformation into acute myeloid leukemia.

Material/Methods:

The study-related tests were carried out in Specialist Hospital No. 1 in Bytom between 2006 and 2011 and involved 53 patients aged 55÷77, divided into groups according to the diagnosed subtype of myelodysplastic syndrome. The study also included the prognosis of overall survival and time to transformation into AML on the basis of valid classifications.

The spinal magnetic resonance scans were obtained from medical documentation. The analysis included images obtained using T1- and T2-weighted sequences in sagittal, transverse and frontal planes in all patients, images obtained using the STIR sequence from 21 patients as well as 40 images obtained after contrast administration.

The statistical analysis of the results was carried out using STATISTICA software.

Conclusions:

The obtained results demonstrated that the magnetic resonance scans revealed statistically significant changes in the images of bone marrow in vertebral body scans; with a decrease in the intensity of MRI signals correlated with the RAEB subtype, particularly with transformation into acute myeloid leukemia as well as with the high IPSS risk score with regard to the time of survival and transformation into acute myeloid leukemia. The research-related test results indicate the importance of magnetic resonance imaging in diagnostics and the assessment of the disease dynamics.

Key words:

myelodysplastic syndrome • MRI of the spine • marrow imaging

PDF file:

<http://www.polradiol.com/fulltxt.php?ICID=883766>

Background

Myelodysplastic syndromes (MDSs) are clonal hematopoietic stem cell disorders characterized by heterogenous clinical presentation. Ineffective hematopoiesis, characteristic for

myelodysplastic syndromes, is associated with abnormalities in differentiation, maturation and survival or hematopoietic stem cells, manifesting in refractory cytopenia with unilineage or multilineage dysplasia frequently requiring hematopoietic transfer or causing severe recurring infections that

require hospitalization [1–4]. The average incidence of myelodysplastic syndromes is 4 cases per 100,000 patients per year; the disease is more common in males and about 80% of new cases are diagnosed in subjects above the age of 60 [5–7].

In terms of their etiology and pathogenesis, myelodysplastic syndromes may be classified as primary or secondary. Primary myelodysplastic syndromes are characterized by lack of noticeable causal factors, and their incidence is associated with genetic predisposition and somatic mutations within stem cells [8–10]. The secondary, or treatment-related myelodysplastic syndrome (t-MDS) is associated with previous anticancer treatment and is observed in patients after chemotherapy or radiation therapy [11,12]. Factors that might impact the occurrence of myelodysplastic syndromes include numerous chemical substances, such as benzene, toluene, herbicides, pesticides, tobacco smoke, hair dyes, silica dusts or heavy metal compounds. The disease may also be caused by cytostatic drugs, e.g. alkylating agents, topoisomerase II inhibitors, purine analogs, hydroxycarbamide, as well as by physical factors such as ionizing radiation [5,13].

Chromosome disruptions are detected in 40–70% of patients with primary MDS and in 80–95% of patients with secondary MDS. These include mainly unbalanced chromosome aberrations not pathognomic for MDS and observed also in acute myeloid leukemias [14].

The first classification of myelodysplastic syndrome – FAB – was developed by French-American-British Cooperative Group and based on cytological evaluation of peripheral blood smear and the cytology of bone marrow [15,16]. The new MDS classification system, i.e. the WHO system modified in 2008, lists 7 subtypes of MDS [9,17,18]. The most commonly diagnosed forms of myelodysplastic syndrome include RA and RAEB subtypes [9].

An important element of the course of MDS is the risk of transformation into acute myeloid leukemia [17,19]. The risk can be as high as 100% in patients with unfavorable prognostic factors. In 1997, the international prognostic scoring system (IPSS), facilitating prognosis of mean overall survival and mean time to transformation into acute myeloid leukemia, was developed [20,21].

Magnetic resonance imaging (MRI) is a method of continuously increasing usefulness in clinical practice. MRI makes use of high static magnetic forces (usually 30,000–60,000 times stronger than the magnetic field of the Earth); the scanning process also involves emission of radiofrequency energy pulses [22]. The magnetic resonance imaging of human body is based on the protons of hydrogen nuclei that align with the lines of a uniform external magnetic field. The patient is placed in a strong magnetic field and subjected to a radiofrequency pulse, absorbing it and emitting it afterwards [23]. The radiofrequency pulse emitted by human body is recorded by the receiver coils of the device, and then converted into an image. The energy absorbed by the object makes part of the protons flip their magnetic moments from parallel to antiparallel to the external magnetic field. The process of protons regaining their initial state is called relaxation; it is responsible for the differentiated images of various tissues [24].

The magnetic resonance technique generates images based on the signal changes in several sequences dependent on time variables for individual types of tissue structures, thus allowing for the assessment of soft tissues [25], fluid structures and adipose tissue remodeling. Magnetic resonance imaging is the only imaging technique facilitating the assessment of bone marrow and detection of bone marrow remodeling in myeloproliferative diseases; it also allows to detect and evaluate infiltrations and tumors in the spinal canal region [26–30], which accounts for its usability in hematology and oncology.

The magnetic resonance imaging of bone marrow consists in detection of differences in the intensities of signals originating from adipose tissue and water which are the components of yellow and red marrow [31,32]. The intensity of the magnetic resonance signals of bone trabeculae is low due to the lack of mobile protons; at the same time, the trabecular structure affects the magnetic resonance image by generation of a local magnetic field [33,34]. Hematopoietic elements account for as much as 60% of the cellular composition of red marrow, while the yellow bone marrow is composed mainly of adipocytes, accounting for 95% of all cells [33]. Water accounts for ca. 15% of yellow marrow content and ca. 40% of red marrow content, while fat accounts for ca. 80% of yellow marrow content and ca. 40% of red marrow content. This structure is best imaged in using spin echo sequences or selective fat saturation sequences [33,35]. In images acquired using the T1-weighted spin echo sequence, most commonly used for bone marrow imaging, the yellow marrow fat has the signal intensity similar to that of the subcutaneous adipose tissue, while the red marrow, which contains more water, is hypointensive compared to the yellow marrow. Imaging using this sequence also makes use on the hyperintensity of the red marrow signals compared to these of the muscle tissue [32–34]. In the T2-weighted sequence, tissues with higher water content are characterized by higher signal intensities compared to tissues with low water content [35]. Similar as in the case of the T1-weighted sequence, the yellow marrow image acquired using the T2-weighted sequence is similar in terms of intensity to the subcutaneous adipose tissue, while the intensity of the red marrow signals is higher than in T1-weighted images and similar to the intensity of the yellow marrow [32]. Figure 1 presents a T1-weighted magnetic resonance scan obtained in a patient not diagnosed with myelodysplastic syndrome. The T2-weighted sequence is less important in the evaluation of bone marrow pathologies due to lower differences in relaxation times and signal intensities between individual marrow, leading to lower usefulness in diagnosing infiltrative lesions [35]. Figure 2 presents a T2-weighted magnetic resonance scan obtained in a patient not diagnosed with myelodysplastic syndrome. Of much importance in the magnetic resonance diagnostics of the bone marrow are sequences with selective tissue (in this case, fat) suppression – the suppressed tissue is shown as dark shading in the images. Thus, an inversion recovery, fat-suppression sequence STIR provides high contrast between yellow marrow and pathological processes [35,36]. Magnetic resonance imaging facilitates visualization of pathophysiological changes within the bone marrow, such as bone marrow atrophy and hypoplasia with hematopoietic elements being

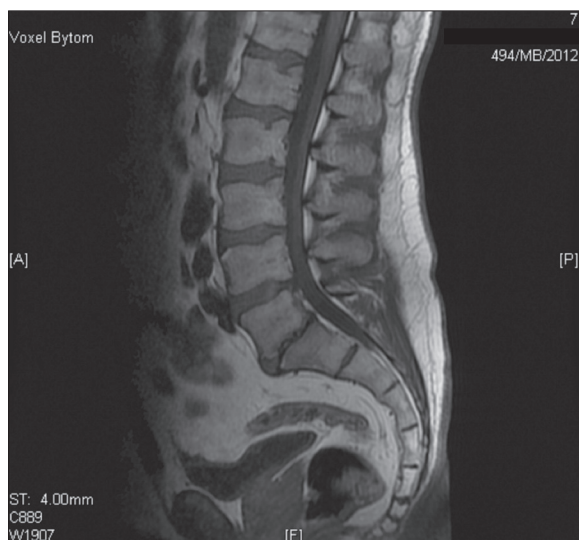


Figure 1. T1-weighted magnetic resonance scan obtained in a patient not diagnosed with myelodysplastic syndrome.

replaced by adipocytes in the course of hematological disorders, as well as treatment-related bone marrow edema (following radiation therapy or chemotherapy) due to non-specific increase in the water content in the course of inflammatory or malignant diseases, as well bone marrow ischemia or reconversion of the yellow marrow into the red fat (in certain hematological disorders characterized by increased demand for hematopoiesis) [36]. Remodeling and infiltration of bone marrow are oftentimes detected much earlier than lesions visualized using standard radiographic techniques.

Assumptions and objectives

The goal of the study is to assess the relationship between the images obtained in the magnetic resonance scans of lumbar spine and the clinical symptoms of the disease in patients diagnosed with myelodysplastic syndromes, to examine the correlation of radiograms with the myelodysplastic syndrome subtypes, particularly with the phase of transformation into acute myeloid leukemia and to assess whether magnetic resonance imaging could be a valuable tool in the diagnostics of myelodysplastic syndrome.

Material and Methods

The assessments were conducted in years 2006–2011 in the Oncology Ward and the Internal Diseases Ward of the Specialist Hospital No. 1 in Bytom. The study group consisted of 53 patients diagnosed with myelodysplastic syndrome of varied clinical presentation. The study population included individuals aged 50 to 77 years, including 22 women (41.5%) and 31 men (58.5%). Patients were divided into subgroups according to the diagnosed subtype of the myelodysplastic syndrome. The first group consisted of patients diagnosed with refractory thrombocytopenia (11 patients, accounting for 20.7% of study population); the second group consisted of patients with refractory anemia (9 patients, 17% of the study population); the third group consisted of patients diagnosed with refractory cytopenia with multilineage dysplasia (16 patients, 30.2 of the study

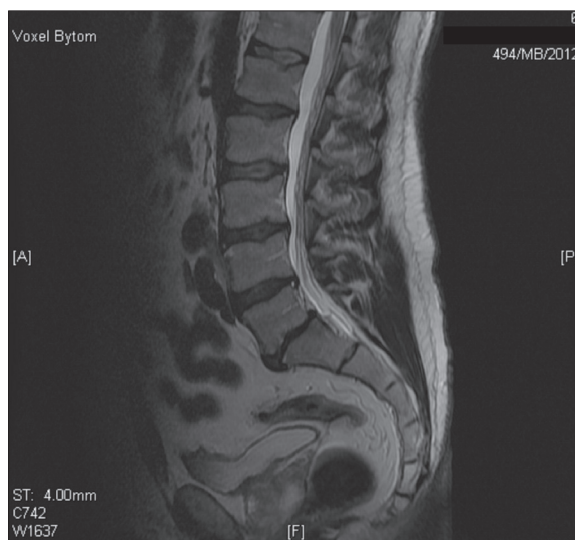


Figure 2. T2-weighted magnetic resonance scan obtained in a patient not diagnosed with myelodysplastic syndrome.

population), while the last group consisted of patients with refractory anemia with increased percentage of blast cells in the bone marrow (17 patients, 32.1% of study population). The groups did not differ significantly in gender and age distribution.

Based on the medical documentation of patients, the disease was classified according to the FAB and the WHO criteria using the results of bone marrow aspiration biopsy and peripheral blood counts with leukocyte differentiation. The study also included the prognosis of survival times and transformability into AML on the basis of valid classifications, i.e. the IPSS.

The spinal magnetic resonance scans were obtained from medical documentation. The scans were performed in a hospital or an outpatient setting. Indications for the magnetic resonance scan included suspected tumor infiltration within the lumbar spine in 9 patients (33.3%) and suspected pathological fracture in this region in 18 patients (66.7%).

Lumbar spine MRI scans were performed at the "Voxel" Magnetic Resonance Lab at the Specialist Hospital No. 1 in Bytom using a 1.5 T GE SIGNA LX HS and SIGNA EXCITE, apparatus with a dedicated quadrature coil. The FSE, frFSE and frFSE+fs sequences were used to acquire T1 and T2-weighted images in sagittal, transverse and frontal planes. The contrast medium (Magnevist 0.2 mL/kg body weight) was administered intravenously in 40 patients (75.5%); in 13 patients (24.5%), examination was performed without contrast administration. In patients who received the contrast agent, the FSE, frFSE and frFSE+fs sequences were used once again to acquire T1 and T2-weighted images. The decision to administer the contrast medium was made by the radiologist performing the MRI scans following the analysis of images acquired using T1 and T2-weighted sequences. The reporting radiologists analyzed the signal intensity and uniformity in studied sequences along with the features of uniform or focal enhancement of signals following contrast administration. A region of interest (ROI) encompassing vertebral bodies excluding

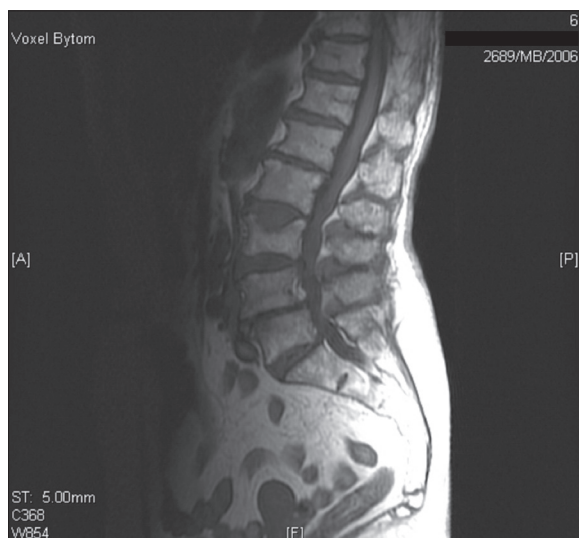


Figure 3. T1-weighted magnetic resonance scan obtained in a patient diagnosed with the RA subtype of myelodysplastic syndrome.

endplates was defined to calculate the relative intensity of the signal. The analysis included images obtained using T1- and T2-dependent sequences in sagittal, transverse and frontal planes in all patients (100%), images obtained using the STIR sequence from 21 patients (39.6%) as well as 40 images (75.5%) obtained after contrast administration.

The obtained results were collected in an Excel spreadsheet and exported into the STATISTICA software to perform statistical calculations. Average age and standard deviation values were calculated for patients in all study subgroups. Since the age distribution did not follow the normal distribution curve, the comparisons between groups were made using a non-parametric Mann-Whitney U-test. The frequency of MRI signals was calculated as the function of the examined factors. The frequencies were then compared using a chi-square test. Statistical significance was assumed for $P < 0.05$.

Results

Signal intensity suppression was observed in 22 patients (41.5%) in the T1-FSE MRI scan of the lumbar spine. Signal enhancement was observed in the study in 23 patients (43.4%), while non-uniform signal intensity was observed in 8 patients (15.1%). The T2-FSE sequence enhanced the signal intensity in 23 patients, accounting for 43.4% of study population; suppression of signal intensity was observed in 21 patients (39.6%), while non-uniform signal intensity was observed in 9 patients (17%). STIR images were acquired in 21 patients, accounting for 39.6% of patients. Analysis of the images acquired using this sequence revealed enhanced signal intensity in 12 patients (57%), suppressed signal intensity in 5 patients (23.8%) and non-uniform intensity signals in 4 (19.1%) patients.

In the second part of the study, the contrast medium (Magnevist 0.2 mL/kg body weight) was administered intravenously in 40 patients (75.5%), and image analysis was repeated. Significant signal enhancement was observed

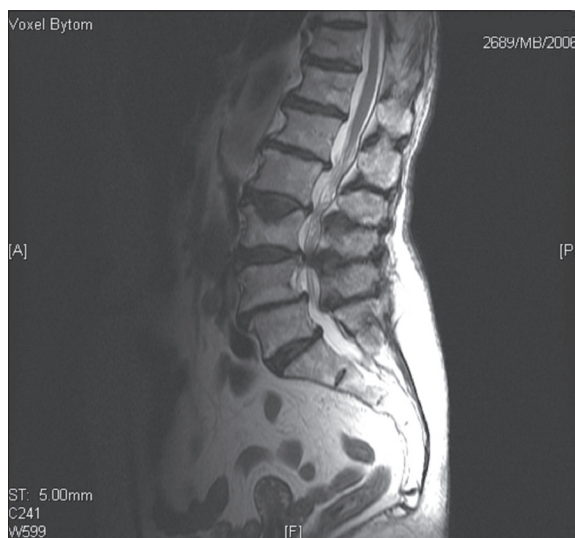


Figure 4. T2-weighted magnetic resonance scan obtained in a patient diagnosed with the RA subtype of myelodysplastic syndrome.

following contrast administration in 22 cases (41.5%), slight signal enhancement was observed in 9 patients (17.0%) while no signal enhancement was observed following contrast administration in the remaining 9 patients (17.0%). Combined T1- and T2-weighted images were also analyzed. In dubious cases where one sequence led to signal enhancement or suppression while the other revealed non-uniform signal intensity, all scans obtained for that particular patient were analyzed again by the radiologist. Markedly different magnetic resonance images were observed for individual diagnostic subtypes. The higher the stage of the disease, the larger was the percentage of suppressed signals in the MRI scans. In 11 patients (20.7%) diagnosed with refractory thrombocytopenia, 100% of T1- and T2-weighted lumbar spine images, when analyzed together, showed an enhancement in signal intensity. Similar results were obtained in 9 patients (17%) diagnosed with the RA subtype. Figures 3 and 4 present example T1- and T2-weighted magnetic resonance images illustrating the aforementioned results and acquired in a patient diagnosed with myelodysplastic syndrome of the RA subtype. Among the 16 subjects (30.2%) diagnosed with RCMD, the scans revealed significant signal suppression in 7 cases (43.8%), signal enhancement in 3 cases (18.7%) and non-uniform signal intensity in 6 cases (37.5%). Patients diagnosed with both grade I and grade II RAEB (32.1%) are characterized by significant MRI signal suppression, as evidenced by 13 scans (76.5%), with only 4 scans (23.5%) revealing non-uniform intensity of signals in the combined analysis of both sequences. Figures 5 and 6 present example T1- and T2-weighted magnetic resonance images acquired in a patient diagnosed with myelodysplastic syndrome of the RAEB II subtype and characterized by significant signal suppression in both sequences.

Risk category was calculated for every patient in the study as regarded the overall survival and transformability of transformation into acute myeloid leukemia using the IPSS score. The largest group consisted of IPSS score 0, low-risk patients: 36 individuals (67.9%); the group with the overall score of 0.5 corresponding to the medium-1 risk

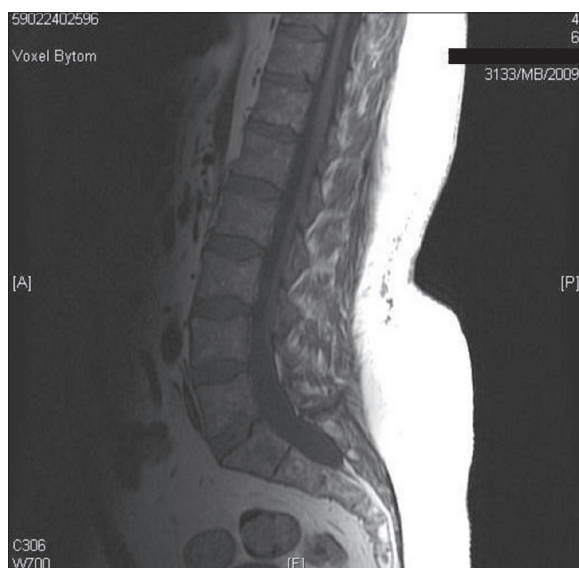

Figure 5. T1-weighted magnetic resonance scan obtained in a patient diagnosed with the RAEB II subtype of myelodysplastic syndrome.

consisted of 7 patients (13.2%); the score of 1.5 corresponding to medium-2 risk was measured in 8 patients (15.1%), while the score of 2.5 corresponding to high risk was measured in 2 patients (3.8%). In the group of IPSS score 0, low risk patients, MRI scans were characterized most frequently by the enhancement of signals in the combined analysis of T1- and T2-weighted sequences (23 patients, 53.9%); signal suppression was observed in 7 patients (19.4%), and non-uniform signal intensity was observed in 6 patients (16.7%). Patients with medium-1 risk and the overall score of 0.5 were most frequently characterized by non-uniform signal intensity in the combined analysis of T1 and T2-weighted images (4 patients, 57.1%); in 3 patients (42.9%) signal suppression was observed. Patients with medium-2 risk and the overall score of 1.5 showed suppressed intensity of signals in the combined analysis of both sequences in 100% of cases (8 patients). Patients with high risk and the overall IPSS score of 2.5 were characterized by suppressed signal intensity in the combined analysis of both T1 and T2-weighted images in 100% of cases (2 patients). Since the numbers of patients in individual risk groups were low, the patients were divided into two subgroups according to their prognosis of overall survival and transformability into AML. The first group consisted of patients with the IPSS score of: 0–36 patients (67.9%), while the other group consisted of patients with the IPSS score of >0 – patients (32.1%). In patients with the IPSS score of >0 suppressed intensity of MRI signals was significantly more common and observed in 76.5% of cases (13 patients); non-uniform signals were observed in 23.5% of cases (4 patients). At the same time, in patients with the IPSS score of 0, suppression of signal intensity was observed in 19.4% of cases (7 patients), non-uniform signal intensity was observed in 16.7% of cases (6 patients), while signal enhancement was observed in a vast majority of cases (23 patients, 63.9%).

10 patients with the RAEB subtype (58.8%) were diagnosed with grade II RAEB with features of blastic transformation,

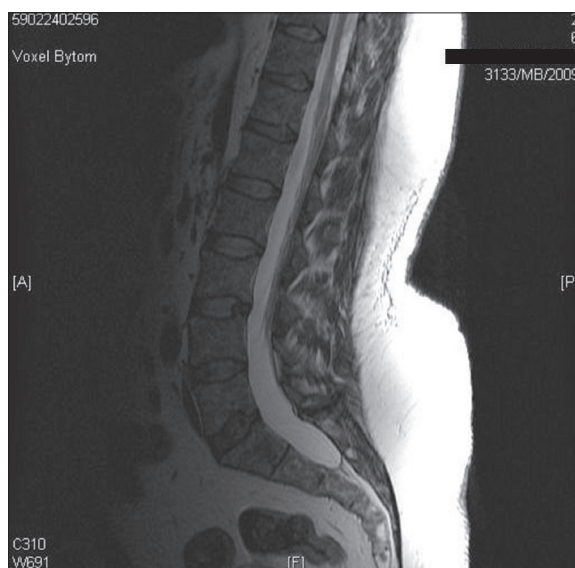

Figure 6. T2-weighted magnetic resonance scan obtained in a patient diagnosed with the RAEB II subtype of myelodysplastic syndrome.

while 7 patients (41.2%) were diagnosed with grade I RAEB; patients in this group presented no signs of blastic transformation. Features of blastic transformation were detected in 18.9% of the entire study population (10 patients). No signs of blastic transformation were observed in 81.1% of cases (43 patients). In the group of patients without signs of blastic transformation, magnetic resonance imaging signal suppression was observed in 23.3% of cases (10 patients), with no signal suppression being observed in 86.8% of scans (33 patients). In this group of patients, 53.4% of images (23 subjects) were characterized by enhanced signal intensity, while non-uniform signal intensity was observed in 23.3% of images (10 subjects). In the group of patients with blastic transformation, signal intensity suppression was observed in 100% of magnetic resonance images.

Discussion

Differences in clinical presentation and diagnostic parameters between individual subtypes of myelodysplastic syndrome led to the development of numerous prognostic scales taking into account different prognostic factors with regard to overall survival and time to transformation into acute myeloid leukemia [7,37].

The most popular prognostic scale, IPSS, was designed on the basis of the following variables: peripheral cytopenia, percentage of blast cells in the bone marrow and patient's karyotype. This allowed to divide patients into four risk groups with regard to the overall survival and time to progression into AML [20,38,39], determine the average survival (in years) in patients before and after 60 years of age, as well as to prognosticate the time to progression into acute myeloid leukemia (in years) [15,20,40].

The patients were divided into two categories according to their IPSS score: the low risk group (including IPSS low and medium 1 risk patients) and the high risk group (including

IPSS medium 2 and high risk patients). The researchers have established different algorithms for the management of patients in both groups, starting from symptomatic treatment of cytopenia, through the use of immunosuppressants and high-dose chemotherapy to bone marrow transplants based on the overall condition of patients and the likelihood of progression into AML [41–43]. The above scale is poorly correlated with overall survival or transformability into acute myeloid leukemia in patients with secondary myelodysplastic syndromes who constitute a large percentage of patients [44].

Scales used to date were not based on imaging results. However, according to the literature, bone marrow changes observed in the magnetic resonance images acquired in patients with hematological diseases may be observed earlier than changes diagnosed by classic radiography and leading to vertebral damage or pathological fractures [33,45].

In the available literature, authors describing the magnetic resonance image of the bone marrow point out the relationship between the image and the amounts of the yellow and the red marrow as well as on the number of bone trabeculae [33,34,46]. The intensity of yellow bone marrow signals in T1- and T2-weighted sequences is similar to that of the subcutaneous adipose tissue, while the intensity of the red bone marrow in T1-weighted images is lower than that of the yellow marrow and, at the same time, higher than that of the muscles and intervertebral discs. The intensity of the red bone marrow signals in T2-weighted images is higher than in T1-weighted images, similar to the intensity of the yellow marrow and lower than the intensity of signals obtained in imaging of fluid structures [30,31,33,47,48]. The short inversion time inversion recovery (STIR) sequence differentiates between both marrow structures as the fat signal is suppressed in this sequence and thus the intensity of the red marrow signal may be higher than that of the yellow marrow signal. Therefore, some authors point to the T2 and STIR sequences as being more sensitive for detection of numerous pathological changes within the bone marrow [16,49].

According to the literature, the best regions for the imaging of bone marrow include vertebral bodies, where the red marrow is maintained in high quantities throughout the human life and certain long bones (femoral or humeral bone) [30,32,34,36].

An important element of changes occurring within the bone marrow is the reverse transformation of yellow marrow into red marrow associated with increased demand on hematopoietic processes [46]. The process reverses physiological transformations, starting in the axial skeleton to spread onto the peripheral skeleton. The changes may be caused by chronic anemia, advanced chronic concomitant diseases and diseases associated with bone marrow displacement or infiltration [33,48].

Administration of contrast medium is considered useful for differentiation between normal marrow and neoplastic lesions which are intensely enhanced following administration of the contrast medium, contrary to the normal

hematopoietic bone marrow which is little or not enhanced following contrast administration [33,47].

In patients with erythrocytopenia who require numerous blood transfers, excess iron is accumulated in the reticulo-endothelial system of the spleen, liver and bone marrow. This leads to the suppression of red marrow signals in all imaging sequences, as described in the literature. The changes in signal intensity are observed mainly within the axial skeleton, i.e. the vertebral bodies [31,50,51].

Radiograms of patients with leukemic infiltrations are characterized by features of bone atrophy, radiolucent bones and bone structure densification bands. Such lesions can be observed mainly in acute leukemias in children (50–70%), and sometimes in adults; however, they are rare in chronic leukemias [32]. The reported leukemic infiltrations in magnetic resonance images are diffuse and located within the axial skeleton due to the involvement of red bone marrow. The T1-weighted sequence images are characterized by suppressed signal intensity, while the T2-weighted images are varied, sometimes showing significant signal enhancement. According to the authors, the STIR sequence allows for better assessment of leukemic lesions compared to the T2 sequence due to suppression of the fat signal and hyperintensity of the signal of the lesion [52,53].

The magnetic resonance technique facilitates monitoring the treatment of leukemic lesions [54]. Observation of signal intensity enhancement in T1-weighted images may suggest good response to chemotherapy.

Blastic transformation-free time follow-up in 42 patients with myelodysplastic syndromes (average follow-up time was 18 months), who were subjected to magnetic resonance imaging of the femoral bone marrow led to the conclusion that MRI may provide much information relevant for prognosis and further management of MDS [55].

The reviewed literature also contained a comparison of magnetic resonance images of femoral bone marrow in patients with a plastic anemia and hypoplastic myelodysplastic syndrome. The obtained results of enhanced signal intensity in STIR sequence images of diffuse lesions in patients with myelodysplastic syndrome or aplastic anemia allowed to conclude that such magnetic resonance signals transformation of the disease into an aggressive form [56].

The magnetic resonance imaging of femoral bone marrow of 85 patients, 27 of whom were diagnosed with myelodysplastic syndrome produced images varying variability depending on the diagnosed MDS subtype and prognosis. Study patients with MDS were divided into groups according to their FAB-based classification of myelodysplastic syndrome. It was determined that the vast majority of patients with good prognosis and diagnosis of RA and RARS had the following marrow structures visualized in their MRI scans: normal or fatty marrow, fatty marrow with a follicular structure or with diffuse remodeling and STIR signal intensity similar or suppressed compared to that of the muscle tissue. In patients with poor prognoses and diagnosed with RAEB and RAEB-t, structures with diffuse or uniform remodeling were observed, with STIR signals enhanced as

compared to those of the muscle tissue. Similar images were observed in most patients who experienced transformation into acute myeloid leukemia during the study [57].

Similarly, a study published in 2009 in *Polish Journal of Radiology* demonstrated statistically significant changes in the bone marrow of lumbar vertebral bodies in patients diagnosed with myelodysplastic syndrome. The observed changes in the intensity of signals from 10 patients diagnosed with myelodysplastic syndromes pertained to T1, T2 and T2 f.s. sequences and were compared to the intensity of signals in a control group. In the T1-weighted sequence, signal suppression was observed in the study group compared to the control group, while no significant changes were observed in the T2-weighted and T2 f.s. images. Significant signal enhancement was observed in the T1-weighted sequence following contrast administration. The authors underscore the high potential use of magnetic resonance imaging in hematological diagnostics [58].

Based on the bibliographic data and the cited studies one may conclude that the magnetic resonance imaging is of potentially high importance in diagnostics and monitoring of patients with myelodysplastic syndromes, as the

images are correlated with the disease subtype and clinical presentation. Judging from the analysis of the literature data, it seems rational to consider bone marrow MRI scans as prognostic factors in patients with myelodysplastic syndromes.

Conclusions

1. Statistically significant changes in the bone marrow and vertebral body images are observed in the magnetic resonance imaging scans.
2. MRI signal suppression is correlated with the RAEB subtype, particularly with transformation into acute myeloid leukemia.
3. Signal suppression was observed in lumbar spine MRI scans of all patients with the IPSS score of 2.5 and high IPSS risk as regards overall survival and time to transformation into AML.
4. Despite the fact that MRI assessment of bone marrow is difficult and requires much experience from the radiologist, the obtained results suggest potentially high usefulness of thin imaging method in the diagnostics and the assessment of the dynamics of myelodysplastic syndromes.

References:

1. Kuliczowski K, Podolak-Dawidziak M, Urbaniak-Kujda D: Postępy w diagnostyce i leczeniu zespołów mielodysplastycznych. Postępy Nauk Medycznych, 2000; 4: 40–43 [in Polish]
2. Nishino H T, Chung-Che C: Myelodysplastic Syndromes. Clinicopathologic Features, Pathobiology, and Molecular Pathogenesis. Arch Pathol Lab Med, 2005; 129(10): 1299–310
3. Maryniak R: Klasyfikacja morfologiczna zespołów mielodysplastycznych według zaleceń WHO 2008. Acta Haematologica Polonica, 2011; 42(2): 165–169 [in Polish]
4. Hoffbrand A V, Pettit J E: Atlas hematologii klinicznej 2003; 172–76 [in Polish]
5. Sawczuk-Chabin J, Seferyńska I: Leczenie zespołów mielodysplastycznych. Postępy Nauk Medycznych, 2003; 3–4: 93–98 [in Polish]
6. Dwilewicz-Trojaczek J, Deptała A, Hellmann A et al: Diagnostyka, klasyfikacja i leczenie zespołów mielodysplastycznych – zalecenia ekspertów polskich. Acta Haematologica Polonica, 2010; 41(1): 101–14 [in Polish]
7. Warzocha K: Praktyczne zalecenia leczenia zespołów mielodysplastycznych ze szczególnym uwzględnieniem zastosowania lenalidomidu w przypadku obecności del(5q). Hematologia, 2010; 1: 71–79 [in Polish]
8. Szymała K, Komarnicki M: Zespoły mielodysplastyczne. Współczesna Onkologia 2003;7(9): 692–701 [in Polish]
9. Dwilewicz-Trojaczek J, Mądry K: Zespoły mielodysplastyczne. [In:] Dmoszyńska A (ed.), Wielka Interna Hematologia. Medical Tribune Polska, 2011; 398–416 [in Polish]
10. Sulek K, Rzepecki P, Hałka J: Diagnostyka cytomorfologiczna szpiku. Wydawnictwo Salezjańskie, 2003; 146–54 [in Polish]
11. Smith SM, Le Beau MM, Huo D et al: Clinical cytogenetic associations in 306 patients with therapy-related myelodysplasia and myeloid leukemia the University of Chicago series. Blood, 2003; 102: 43–52
12. Maryniak RK, Prochorec-Sobieszek M, Pałynyczko G et al: Wielośrodkowe badania retrospektywne cech histopatologicznych i klinicznych u 85 pacjentów z rozpoznaniem MDS. Acta Haematologica Polonica, 2001; 32(3): 277–85 [in Polish]
13. Warlick ED, Smith BD: Myelodysplastic Syndromes: Review of Pathophysiology and Current Novel Treatment Approaches. Current Cancer Drug Targets, 2007; 7: 541–58
14. Skotnicki AB, Śledziowski P: Zespoły mielodysplastyczne. [In:] Dmoszyńska A, Robak T (eds.), Podstawy hematologii. Wydawnictwo Czelej, 2008; II(11): 213–50
15. Mądry K: Klasyfikacja i czynniki prognostyczne w zespołach mielodysplastycznych. Acta Haematologica Polonica, 2011; 42(2): 171–76 [in Polish]
16. Czyż A, Dworacki G, Komarnicki M: Przydatność badania immunofenotypu komórek szpiku metodą cytometrii przepływową w diagnostyce zespołów mielodysplastycznych. Postępy Hig Med Dosw, 2008; 62: 354–63 [in Polish]
17. Heleniak H, Król M, Świeboda-Sadej A, Dwilewicz-Trojaczek J: Odreślności immunofenotypu komórek blastycznych w zespołach mielodysplastycznych. Acta Haematologica Polonica, 2009; 40(4): 813–21 [in Polish]
18. Brunning RD, Orazi A, Germing U et al: Myelodysplastic syndromes/ neoplasms overview. [In:] Sverdlov SH, Campo R, Harris NL et al (eds.), WHO Classification of Tumors. Pathology and Genetics. Tumors of Haematopoietic and Lymphoid Tissues. IARC Press. Lyon, 2008; 2: 88–107
19. Shi J, Shao Z H, Liu H et al: Transformation of myelodysplastic syndromes into acute myeloid leukemias. Chin Med J (Engl), 2004; 117(7): 963–67
20. Greenberg P, Cox C, Le Beau M M et al: International scoring system for evaluating prognosis in myelodysplastic syndromes. Blood, 1997; 36: 2079–88
21. Aul C, Giagounidis A, Germing U, Ganser A: Evaluating the prognosis of patients with myelodysplastic syndromes. Ann Hematol, 2002; 81(9): 485–97
22. Glenn N, Levine MD: Obrazowanie metodą rezonansu magnetycznego u chorych z wszczepionymi urządzeniami kardiologicznymi – bilans korzyści i ryzyka. Aktualne stanowisko American Heart Association. Medycyna Praktyczna, 2008; 02: 20–22 [in Polish]
23. Tacikowska M: Leksykon pojęć i definicji w onkologii – rezonans magnetyczny. Nowotwory, 2006; 56(4): 477–82 [in Polish]
24. Siczek M: Tomografia Komputerowa i Rezonans Magnetyczny dla studentów kierunku Informatyka. Uniwersytet Marii Skłodowskiej-Curie w Lublinie, 2011; 51 [in Polish]
25. Wehrli FW, MacFall JR, Breger R, Herfkens JR: Mechanisms of contrast in NMR imaging. J Comput Assist Tomogr, 1984; 8(3): 369–80
26. Harel R, Angelov L: Spine metastases: current treatments and future directions. Eur J Cancer, 2010; 46: 2696–707

27. Walker R, Barlogi B, Haessler J, Tricot G et al: Obrazowanie metodą rezonansu magnetycznego w szpiczaku mnogim: znaczenie diagnostyczne i kliniczne. *Journal of Clinical Oncology*, 2007; 5(5): 327–35 [in Polish]
28. Husband JE, Guy R: Magnetic resonance imaging in oncology. *Gut*, 1992; 33: 1587–89
29. Tokuda O, Hayashi N, Matsunaga N: MRI of bone tumors: Fast STIR imaging as a substitute for T1-weighted contrast-enhanced fat-suppressed spin-echo imaging. *J Magn Reson Imaging*, 2004; 19(4): 475–81
30. Stäbler A: Bone Marrow Disorders. [In:] Hodler J, Schulthess GK, Zollikofer ChL (eds.), *Musculoskeletal Diseases. Diagnostic Imaging and International Techniques*. IDKD, 2005; 73–82
31. Carrol KW, Feller JF, Tirman PEJ: Distinguishing Infiltrative Marrow Pathology From Hematopoietic Marrow at MRI. *JMRI*, 1997; 7(2): 394–98
32. Burgener FA, Meyers SP, Tan RK, Zaunbauer W, Bogusławska R, Bekiesińska-Figatowska M. (eds.), *Diagnostyka różnicowa w obrazowaniu metodą rezonansu magnetycznego*. MediPage, 2010; 571–80 [in Polish]
33. Hwang S, Panicek DM: Magnetic resonance imaging of bone marrow in oncology, Part 1. *Skeletal Radiol*, 2007; 36: 913–20
34. Vanel D, Dromain C, Tardivon A: MRI of bone marrow disorders. *Eur Radiol*, 2000; 10(2): 224–29
35. Dytfeld D, Sosnowski P, Czyż A, Komarnicki M: Rola rezonansu magnetycznego w diagnostyce szpiczaka mnogiego. *Polski Merkuriusz Lekarski*, 2007; 23(134): 85–88 [in Polish]
36. Feller JF: MRI of Bone Marrow. *Advances MRI* 2002; 1–3. URL: http://mri.cpson.com/pdf/MRI_of_the_Bone_Marrow.pdf
37. Cheson BD, Bennett JM, Kantarjian H et al: Report of an international working group to standardize response criteria for myelodysplastic syndromes. *Blood*, 2000; 96: 3671–74
38. Bowen D, Culligan D, Jowitt S et al: Guidelines for the diagnosis and therapy of adult myelodysplastic syndromes. *Britt J Haematol*, 2003; 120: 187–200
39. Greenberg P, Cox C, Le Beau MM et al: Erratum: International scoring system for evaluating prognosis in myelodysplastic syndromes. *Blood*, 1998; 91: 1100
40. Lichtman MA, Rowe JM: The relationship of patients age to the pathobiology of the clonal myeloid disease. *Semin Oncol*, 2004; 31: 185
41. Cutler C, Lee SJ, Greenberg PI et al: A decision analysis of allogeneic bone marrow transplantation for myelodysplastic syndromes: delayed transplantation for low risk myelodysplasia in associated with improved outcome. *Blood*, 2004; 104: 579–85
42. Beran M, Shen Y, Kantarjian H et al: High- dose chemotherapy in high risk myelodysplastic syndrome: covariante – adjusted comparison of five regimens. *Cancer*, 2001; 92: 1999–2015
43. Hellstrom-Lindberg E: Update on supportive care and new therapies: immunomodulatory drugs, growth factors and epigenetic- acting agents. *ASH Hematology Education Program BOOK*, 2005; 161–66
44. Guerci AP, Feldmann L, Humbert JC, Guerci O: Refractory anemia with excess of blasts: a multivariate analysis of prognostic factors in 91 patients and a simplified scoring system for predicting survival. *Eur J Haematol*, 1995; 54(4): 241–44
45. Zaleska-Dorobisz U, Sokolska V, Kuliszkiwicz-Janus M, Czapiga E et al: Znaczenie badań kregosłupa piersiowego i lędźwiowego metodą rezonansu magnetycznego (MR) u chorych ze schorzeniami hematologicznymi, ze szczególnym uwzględnieniem szpiczaka mnogiego. *Ann Un M Curie-Skłodowska Lublin-Polonia*, 2005; 60(16): 653 [in Polish]
46. Takagi S, Tanaka O: The Role of Magnetic Resonance Imaging in the Diagnosis and Monitoring of Myelodysplastic Syndromes or Leukemia. *Leukemia & Lymphoma*, 1996; 23 (5–6): 443–50
47. Vande Berg B, Malghem F, Lecouvet B, Maldague B: Imaging of bone marrow Disorders in Musculoskeletal Diseases. *Diagnostic Imaging and International Techniques*. IDKD, 2005; 68–72
48. Takagi S, Tanaka O, Miura Y: Magnetic Resonance Imaging of Femoral Marrow in Patients With Myelodysplastic Syndromes or Leukemia. *Blood*, 1995; 86(1): 316–22
49. Waldman SD: Atlas zespołów bólowych. Urban & Partner, 2009; 239–47 [in Polish]
50. Baert AL, Knauth M, Davies AM, Sundaram M, James SLJ (eds.), *Imaging of bone tumors and tumor-like lesions: Techniques and applications*. Springer, 2009. 354
51. Lewis S, Wainscoat JS, Moore NR, Golding SJ: Magnetic resonance imaging in myelodysplastic syndromes. *Br J Radiol*, 1995; 68 (806): 121–27
52. Ross JS, Brant-Zawadzki M, Moore KR et al: *Diagnostic Imaging. Spine*. 1st ed. Amirsys, 2004; IV(1): 58–61
53. Olson DO, Shields AF, Scheurich CJ et al: Magnetic resonance imaging of the bone marrow in patients with leukemia, aplastic anemia, and lymphoma. *Invest Radio*, 1986; 21(7): 540–46
54. Wang J, Zhang X, Niu J: Clinical significance of magnetic resonance imaging of bone marrow in patients with leucaemia. *J Tongji Med Univ*, 2001; 21(3): 242–45
55. Takagi S, Tanaka O, Origasa H, Miura Y: Prognostic significance of magnetic resonance imaging of femoral marrow in patients with myelodysplastic syndromes. *J Clin Oncol*, 1999; 17(1): 277–83
56. Lorand-Metze I, Santiago GF, Lima CS et al: Magnetic resonance imaging of femoral marrow cellularity in hypocellular haemopoietic disorders. *Clin Radiol*, 2001; 56(2): 107–10
57. Takagi S, Tanaka O: Magnetic resonance imaging of femoral marrow predicts outcome in adult patients with acute myeloid leukaemia in complete remission. *Br J Haematol*, 2002; 117(1): 70–75
58. Wojtek P, Ziółko E, Adamczyk T i wsp: Wyniki tomografii komputerowej rezonansu magnetycznego kregosłupa u pacjentów z zespołem mielodysplastycznym. *Pol J Radiol*, 2009; 74(2): 46–50