

Phacoviscocanalostomy for open-angle glaucoma with concomitant age-related cataract

Alexandros N Stangos¹
Anestis Mavropoulos²
Gordana Sunaric-
Megevand^{1,3}

¹Division of Ophthalmology,
Department of Clinical
Neurosciences, University Hospitals
of Geneva, Geneva, Switzerland;

²Division of Bone Diseases,
Department of Rehabilitation
and Geriatrics, University Hospitals
of Geneva, Geneva, Switzerland;

³Department of Ophthalmology,
Clinique Générale Beaulieu,
Fondation Rothschild, Geneva,
Switzerland

Purpose: To evaluate the efficacy and safety of combined viscocanalostomy and phacoemulsification (phacoviscocanalostomy) for medically uncontrolled open-angle glaucoma (OAG) with concomitant age-related cataract.

Design: Prospective, noncomparative, interventional case-series study.

Methods: Phacoviscocanalostomy was performed on 50 eyes of 50 consecutive patients with medically uncontrolled OAG and clinically significant age-related cataract. Surgical outcome was defined as an overall success by the following criteria: no visual field deterioration; no optic-neuropathy progression; postoperative intraocular pressure (IOP) \leq 20 mmHg and IOP reduction \geq 30% compared to baseline values with or without medication. When medications were not required, success was defined as complete. The surgical outcome and the complication rates were documented and analyzed up to 36 months postoperatively.

Results: Mean follow-up (\pm SD) was 29.02 \pm 7.09 months. Mean, baseline IOP (\pm SD) had significantly decreased from 23.51 \pm 4.48 mmHg to 14.06 \pm 1.64 mmHg at the last follow-up visit for each patient ($p < 0.001$). The overall success was 94% at 12 months, 92% at 24 months, and 82% at 36 months. The success was complete in 74% at 12 months, and in 67% at 24 months and at 36 months. No serious complications were documented.

Conclusion: Phacoviscocanalostomy can be considered an efficient and safe alternative surgical modality for medically uncontrolled OAG with concomitant age-related cataract.

Keywords: age-related cataract, non-penetrating glaucoma surgery, open-angle glaucoma, phacoemulsification, phacoviscocanalostomy, viscocanalostomy

Introduction

The prevalence of both cataract and glaucoma increases with age. Thus, with an ageing population, a large proportion of observed blindness is necessarily related to these two pathologies (Kocur and Resnikoff 2002). The increased risk of cataract development in some glaucoma patients (Heijl et al 2002; Kass et al 2002), the significantly increased risk of cataract development after glaucoma surgery (Hylton et al 2003), and the need to minimize both trauma and cost induced by two separate surgical procedures, has made combined cataract and glaucoma surgery an appealing therapeutic approach (Casson and Salmon 2001; Vass and Menapace 2004; Verges et al 2005). Indeed, combined phacoemulsification with trabeculectomy (phacotrabeulectomy) has become a popular treatment for glaucomatous eyes with visually significant cataract (Lemon et al 1998; Shingleton et al 1999; Vyas et al 1999; Li et al 2000). However, both trabeculectomy and phacotrabeulectomy are associated with potentially serious complications (Bellucci et al 1997; Sihota et al 1998; DeBry et al 2002; Edmunds et al 2002) such as bleb leaks, hypotony, flat anterior chamber, choroidal detachment, and endophthalmitis. In order to avoid these complications, alternative surgical modalities have before emerged. Viscocanalostomy, a relatively new, non-penetrating filtering surgical procedure, has been reported to efficiently and safely reduce intraocular pressure (IOP) in various types of open-angle

Correspondence: Gordana Sunaric-
Megevand
16 Plateau de Champel,
1206 Geneva, Switzerland
Tel +41 22 34 74 980
Fax +41 22 34 74 981
Email gsm@cqi.com

glaucoma (OAG) (Stegmann et al 1999; Drusedau et al 2000; Sunaric-Megevand and Leuenberger 2001; Carassa et al 2002; Miserocchi et al 2004; Stangos et al 2005). When combined with phacoemulsification surgery, viscocanalostomy (phacoviscocanalostomy) has similarly been reported to efficiently and safely reduce IOP while improving visual acuity (Gimbel et al 1999; Wishart et al 2002; Park et al 2004, 2006; Wishart and Dages 2006), yet more data are necessary. We conducted a study on phacoviscocanalostomy for uncontrolled OAG with concomitant age-related cataract, and we herein present our results.

Patients and methods

This was a prospective, non-comparative study of 50 eyes of 50 consecutive patients with medically uncontrolled OAG and age-related cataract, on whom phacoviscocanalostomy was performed. The same, experienced phacoemulsification and viscocanalostomy surgeon (GSM) operated on all of the cases using the same standardized surgical technique between September 2002 and July 2004. Surgery and post-operative follow-up were offered either in the University Eye Clinic or in the Clinique Générale Beaulieu, Fondation Rothschild in Geneva, Switzerland. We included cases of medically uncontrolled OAG with concomitant clinically significant age-related cataract. Cases with dysgenetic, uveitic, traumatic, neovascular or angle-closure glaucoma, as well as cases with cataract other than age-related or cases with a known life-threatening disease, were excluded from the study. Preoperative baseline evaluation included: best-corrected visual acuity (BCVA); IOP measurement (under maximal tolerated medication, and without diurnal fluctuation taken into account); slit-lamp biomicroscopy; gonioscopy; ultrasound corneal pachymetry; indirect funduscopy with recording of the optic disc size, the vertical and horizontal cup/disc ratio, the presence of rim notching or splinter hemorrhages and the morphology of the peripapillary area; optic-disc stereoscopic photography; automated perimetry (Octopus 101, Interzeag, Switzerland); medication and family history documentation. The study protocol and consent forms were approved by the Institutional Review Boards of both participating institutions. Patients were informed on the purpose of the study and they provided written informed consents.

Surgical procedure and postoperative care

In all cases, anesthesia was peribulbar (Lidocaine-Adrenalin). Viscocanalostomy was the first step of the combined procedure,

and it was based on the original description by Stegmann and coworkers (Stegmann et al 1999). The conjunctival flap was fornix-based. To avoid damage to Schlemm's canal (SC), to the collector channels and to the episcleral vascular bed, diathermy was not used. Instead, hemostasis was achieved by terlipressin-embedded (Glypressine, Ferring AG, Malmö, Sweden) sponge application on the surgical wound. A site with at least one apparent collecting channel was chosen and a 5 × 5 mm limbal-based rectangular or parabolic, thin superficial scleral flap was dissected 1.5 mm into clear cornea. By using a specially designed scleral knife (Scleral Pocket Knife 681.26, Grieshaber and Co. AG, Schaffhausen, Switzerland), a second, deep scleral flap was dissected close to the ciliary body. When reaching SC, the latter was unroofed by gently pulling on the scleral flap and concomitantly peeling the fibrotic lining from the bottom of the canal by means of a triangular cellulose sponge. This same procedure was continued into a cleavage plane, between the corneal stroma and the Descemet's membrane, creating a trabeculo-Descemet-membrane (TDM) window. As soon as the TDM window was created, percolation of the aqueous humor through the remaining peripheral Descemet's membrane and/or SC was observed. A 150 µm canula (Visco Canalostomy Canula, 149.40, Grieshaber and Co. AG, Schaffhausen, Switzerland) was then inserted, through the two ostia, far inside SC and a high-molecular-weight sodium hyaluronate (Healon GV; Advanced Medical Optics Uppsala AB, Uppsala, Sweden) was repeatedly injected inside. The deep flap was excised with micro-scissors and the superficial flap sutured with three separate 10-0 nylon sutures, creating an intrascleral space. Healon GV was then injected under the flap, into this intrascleral space. The conjunctiva was sutured using one or two separate 10-0 nylon sutures. The surgeon proceeded with the cataract extraction. Accordingly, a different-site, clear-cornea, temporal incision followed by a standard phacoemulsification with a 3-piece intraocular lens (IOL) implantation was performed in all eyes. Patients were discharged one day after surgery. Topical antibiotic and anti-inflammatory drops were prescribed postoperatively for 1 month.

Follow-up visits were scheduled on the first day, first week, first month and at 3-month intervals thereafter, throughout 36 months postoperatively. Best-corrected visual acuity measurement, IOP measurement, biomicroscopy, and funduscopy were performed at each visit. On biomicroscopy, attention was paid to the appearance of the surgical wound and to the presence or absence of a conjunctival bleb, anterior-chamber inflammation, hyphema, and secondary

cataract development. During funduscopy, the optic nerve was meticulously examined. Automated perimetry and optic-disc stereo photography were performed every 6 months and 12 months respectively.

The intraocular pressure was measured with a Goldmann applanation tonometer (without diurnal fluctuation taken into account). Three measurements were recorded in each eye, and the mean value was used in the calculations. Best-corrected visual acuity was analyzed for study purposes by means of the logMAR score, proposed by Holladay (1997). The logMAR score derives by taking the logarithm (base 10) of the minimum angle of resolution (MAR) or practically, $\log\text{MAR} = \log(1/\text{Decimal Acuity})$. A score of 0.0 in logMAR units is equivalent to a visual acuity of 20/20 on the Snellen acuity chart (1.0 being the Decimal equivalent), whereas a score of +1.0 is equivalent to 20/200 (0.1 being the Decimal equivalent). Visual field deterioration was graded according to the Hodapp-Anderson-Parrish severity scores (Hodapp et al 1993). If additional visits were needed, their results were included only if relevant for the main outcome measures. For patients referred only for surgery in the two participating institutions, detailed preoperative information was obtained from the referring ophthalmologist and they were brought in for further examination. Follow-up visits were always performed in either of the two participating institutions.

Outcome criteria and statistical analysis

Overall success was defined through the following criteria: no visual field deterioration; no optic-neuropathy progression; postoperative IOP ≤ 20 mmHg and IOP reduction $\geq 30\%$ compared to baseline values with or without medication. When medications were not required, success was defined as complete. Cases not fulfilling the aforementioned criteria and cases where a surgical revision or further goniotomy was performed were defined as a failure. All statistical analyses were carried out using the SPSS 15.0 statistical software.

Results

Fifty eyes of 50 consecutive patients with medically uncontrolled OAG and age-related cataract underwent phacoviscocanalostomy. The surgical outcome, as well as the intraoperative and postoperative complication rates were documented and analyzed up to 36 months postoperatively. Mean follow-up (\pm SD) was 29.02 ± 7.09 months (range, 12 to 36 months). One patient died 6 months after surgery due to a cardiovascular pathology, and was therefore excluded from the data analysis. Forty-nine, 39 and 16 of the remaining subjects reached the 12-, 24-, and 36-month follow-up visit

Table 1 Patients' characteristics before phacoviscocanalostomy

Diagnosis	POAG	43 (88%)
	PEX	6 (12%)
Gender	Male	28 (57%)
	Female	21 (43%)
Race	Caucasian	44 (90%)
	Non-Caucasian	5 (10%)
Eye	Right	22 (45%)
	Left	27 (55%)
Mean age \pm SD (range) ^a		75.24 \pm 6.23 years (59–86)
Mean axial length \pm SD (range)		23.53 \pm 1.41 mm (20.97–26.05)
Mean IOP \pm SD ^b		23.51 \pm 4.48 mmHg
Mean BCVA \pm SD ^c		0.26 \pm 0.11 logMAR
Mean number of antiglaucoma medications \pm SD		2.28 \pm 0.91
Previous Surgery		2 (4%)

Abbreviations: BCVA, best-corrected visual acuity; IOP, intraocular pressure; PEX, pseudoexfoliation glaucoma; POAG, primary open-angle glaucoma.

^aAt the time of operation.

^bMeasured with a Goldmann applanation tonometer under maximal tolerated medication (without diurnal fluctuation taken into account).

^cVisual acuity in the logarithm of the minimum angle of resolution (logMAR).

respectively. The preoperative patients' characteristics are synopsized in Table 1. Forty-three subjects (87.8%) were diagnosed with primary open-angle glaucoma (POAG), whereas the remaining six with pseudoexfoliation glaucoma (PEX). The mean age (\pm SD) at the time of operation was 75.2 ± 6.4 years (range, 59–86 years). Preoperative dynamic gonioscopy revealed an open angle in all subjects. The mean ocular axial length (\pm SD) was 23.53 ± 1.41 mm. Seven subjects (14.3%) had a positive family history of glaucoma. The gender distribution was 28 male (57%) and 21 female. Forty-four patients (90%) were Caucasians, whereas five cases belonged to the black-African race. Mean number of preoperative glaucoma medications (\pm SD) was 2.28 ± 0.91 . The mean preoperative BCVA (\pm SD) in logMAR units was 0.26 ± 0.11 .

Mean IOP change after surgery is depicted in Figure 1. The mean preoperative IOP (\pm SD) under maximal tolerated medication of 23.51 ± 4.48 mmHg decreased to a mean postoperative IOP of 7.84 ± 3.32 mmHg on the first day, 11.30 ± 4.12 mmHg at 1 week, 13.00 ± 3.36 mmHg at 6 months, 13.60 ± 2.60 mmHg at 12 months, 14.30 ± 3.50 mmHg at 24 months, and 14.30 ± 1.70 mmHg at 36 months. The mean baseline IOP (\pm SD) had significantly decreased from 23.51 ± 4.48 mmHg to 14.06 ± 1.64 mmHg at the last follow-up visit for each patient (paired Student's t-test, $p < 0.001$). Similarly, the mean number of antiglaucoma medication (\pm SD) had dropped to 0.38 ± 0.86 in comparison with preoperative values (chi-square test, $p < 0.001$). Our results indicate a 98% overall success rate at 6 months, 94% at

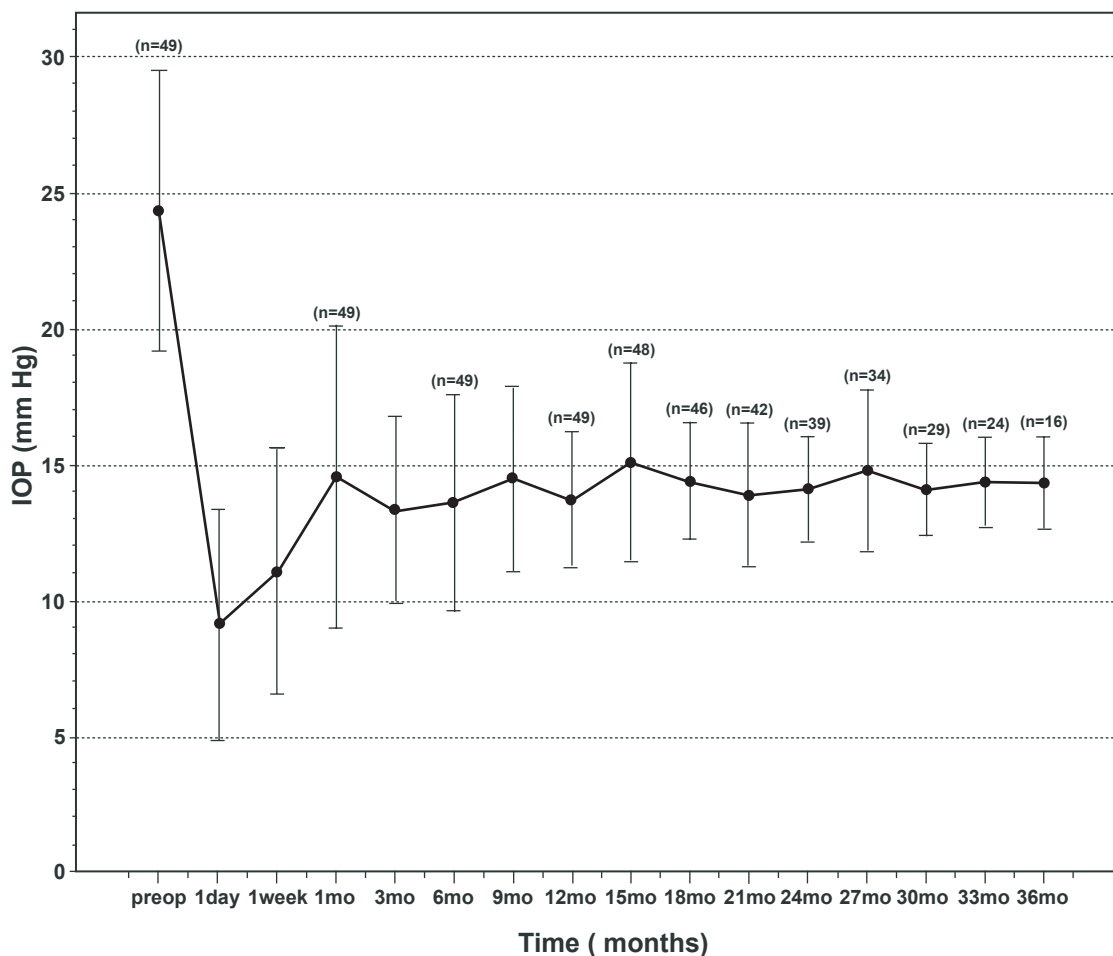


Figure 1 Mean intraocular pressure (IOP) change with standard deviation in patients following phacoviscocanalostomy.

12 months, 92% at 24 months, and 82% at 36 months. The success was complete in 88% of cases at 6 months, in 74% at 12 months, and in 67% at 24 months and at 36 months. The cumulative probability curves for overall and complete success are depicted in Figure 2. As it would be expected after phacoemulsification with IOL implantation, the mean preoperative BCVA (\pm SD) in logMAR units of 0.26 ± 0.11 had significantly improved to 0.07 ± 0.10 at the last follow-up visit for each patient (paired Student's t-test, $p < 0.001$). An improvement by 3 or more lines was achieved in 34 eyes (69%). Thirteen eyes (27%) gained up to 2 lines. However, one subject developed an idiopathic macular hole and lost 3 lines of BCVA despite receiving a standard pars-plana vitrectomy with internal limiting membrane peeling. One other patient developed a recalcitrant, postoperative cystoid macular edema and lost 2 lines of BCVA. During the follow-up period, 3 eyes (6%) were subjected to neodymium-yttrium aluminum garnet (Nd:YAG) laser posterior capsulotomy due to secondary cataract development.

No serious complication was documented either during or after the operation (Table 2). In five cases (10%) we documented a microhyphema, which disappeared spontaneously within 48 hours. Microperforation of the TDM was reported intraoperatively in three cases (6%), neither of which necessitated a peripheral iridectomy. One other case (2%) with a TDM perforation and iris prolapse was treated by peripheral iridectomy. Descemet's membrane detachment was not reported in any case. At the final follow-up visit for each patient, 7 subjects were defined as failure. In five of these failures, IOP was higher than 21 mmHg despite additional antiglaucoma medication use, needing antiglaucoma surgery revision. Trabeculectomy with antimetabolite use was offered to one patient, whereas the remaining 4 cases received a same-site viscocanalostomy revision. In two subjects, glaucomatous optic-neuropathy progression was documented by fundus stereo photography and/or automated perimetry, despite sufficient IOP control ($IOP \leq 20$ mmHg with or without antiglaucoma medication).

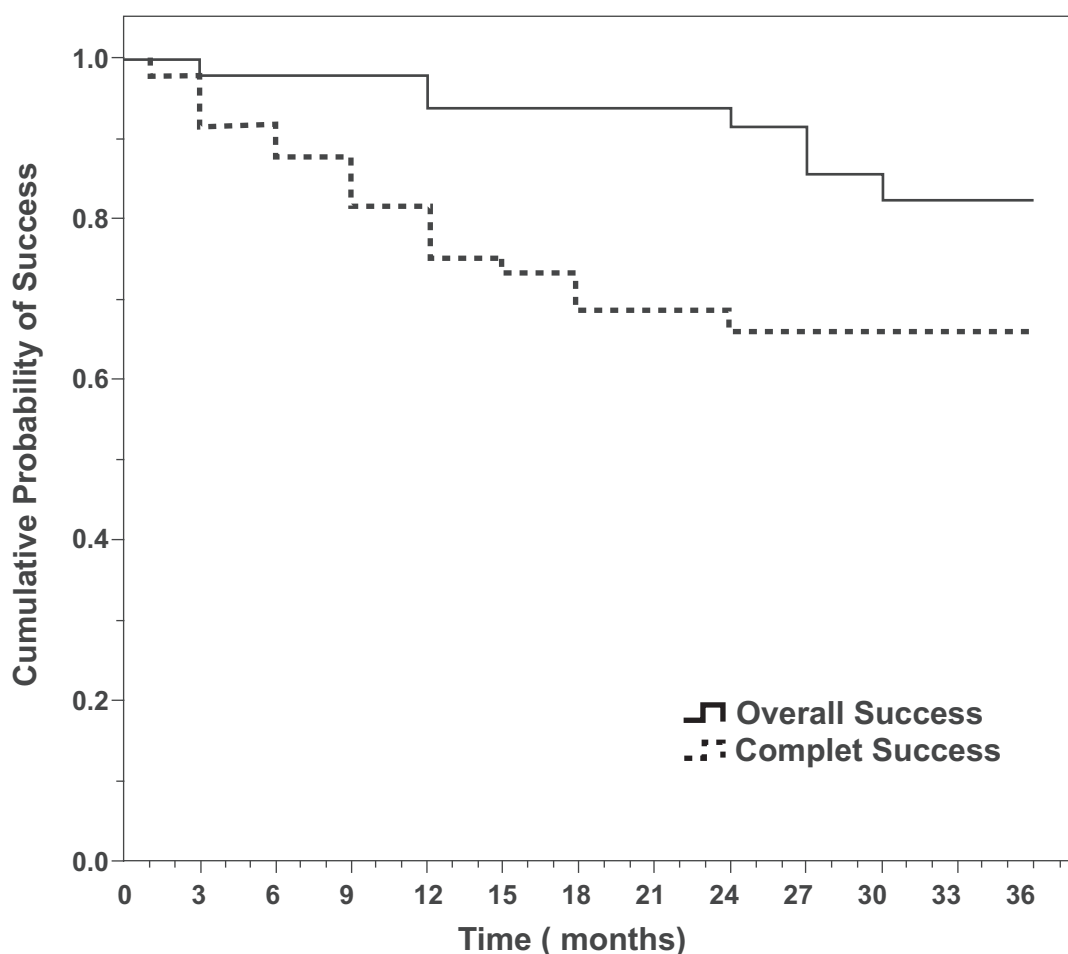


Figure 2 Cumulative probability of overall (solid line) and complete (dotted line) success in patients following phacoviscocanalostomy. Overall success was defined through the following criteria: no visual field deterioration; no optic-neuropathy progression; postoperative IOP \leq 20 mmHg and IOP reduction \geq 30% compared to baseline values with or without medication. When medications were not required, success was defined as complete.

Postoperatively, shallow filtration blebs were documented in 16 cases (33%). Nine (56%) of these blebs regressed spontaneously during the first 12-month follow-up period. Neither persisting nor non-persisting blebs influenced success rates (Mantel-Cox, $p > 0.05$ for each variable). None of the 49 subjects developed a bleb-related complication (ie, hypotony, hypotony-related maculopathy, blebitis or endophthalmitis) during the follow-up period. Throughout the measurement period, there was no effect of gender, ethnicity or diagnosis (ie, POAG, PEX) on the overall success over time (Mantel-Cox, $p > 0.05$ for each variable).

Discussion

Trabeculectomy is the standard procedure in managing medically uncontrolled OAG (Cairns 1968). In patients suffering from both OAG and cataract, phacotrabeculectomy appears to be a rational approach owing to a superior hypotensive effect compared to cataract surgery alone (Friedman et al

2002). Interestingly, trabeculectomy alone appears to be more effective in lowering IOP than phacotrabeculectomy (Bellucci et al 1997; Lochhead et al 2003). Alone or in combination with phacoemulsification, trabeculectomy is associated with potentially serious postoperative complications (Bellucci et al 1997; Sihota et al 1998; DeBry et al 2002; Edmunds et al 2002). Non-penetrating glaucoma surgery, in the form of viscocanalostomy, has gained increasing interest because it can both reduce IOP and significantly minimize the surgical complications related to conventional filtration

Table 2 Intraoperative and postoperative complications

None	40 (82%)
Microhyphema ^a	5 (10%)
TDM Microperforation	3 (6%)
TDM perforation with peripheral iridectomy	1 (2%)

Abbreviation: TDM, trabeculo-Desemet's-membrane.

^aSpontaneously regressed (within 48 hours).

procedures (Stegmann et al 1999; Drusedau et al 2000; Sunaric-Megevand and Leuenberger 2001; Carassa et al 2002; Stangos et al 2005). Similarly, phacoviscocanalostomy has shown to efficiently and safely reduce IOP in cases with OAG and clinically significant cataract (Gimbel et al 1999; Tanito et al 2002; Wishart et al 2002; Uretmen et al 2003; Park et al 2004, 2006; Wishart and Dages 2006; Kobayashi H and Kobayashi K 2007).

In accordance with previously published phacoviscocanalostomy studies (Gimbel et al 1999; Tanito et al 2002; Wishart et al 2002; Uretmen et al 2003; Park et al 2004, 2006; Wishart and Dages 2006; Kobayashi H and Kobayashi K 2007), in the current study, the mean baseline IOP (\pm SD) had significantly dropped from 23.51 ± 4.48 mmHg to 14.06 ± 1.64 mmHg at the last follow-up visit for each patient (paired Student's t-test, $p < 0.001$). Similarly, the mean number of antiglaucoma medication (\pm SD) had dropped to 0.38 ± 0.86 in comparison with preoperative values (paired Student's t-test, $p < 0.001$). The overall success of phacoviscocanalostomy at the last visit for each patient was 86% (42 from 49 eyes) and the complete success was 67% (33 from 49 eyes). Seven eyes (14%) were classified as a failure. Two of these failures have shown progression of glaucomatous neuropathy irrespective of good IOP control with or without antiglaucoma medication. Four of the 5 cases that experienced unsatisfactory postoperative IOP values received a viscocanalostomy revision through the same surgical site with excellent results (IOP ≤ 20 mmHg with concomitant reduction $\geq 30\%$ compared to baseline values). Previous favorable results of surgical revision (same site approach) for viscocanalostomy failures in POAG make us advocates of that approach (Sunaric-Megevand G. unpublished data, 2004).

Viscocanalostomy avoids intraoperative and postoperative complications related to penetrating filtration procedures (Bellucci et al 1997; Sihota et al 1998; DeBry et al 2002; Edmunds et al 2002). Similarly to previous viscocanalostomy and phacoviscocanalostomy studies (Gimbel et al 1999; Stegmann et al 1999; Drusedau et al 2000; Sunaric-Megevand and Leuenberger 2001; Carassa et al 2002; Tanito et al 2002; Wishart et al 2002; Uretmen et al 2003; Miserocchi et al 2004; Park et al 2004, 2006; Stangos et al 2005; Wishart and Dages 2006), in the present study, no serious complications were documented either during or after the operation. In five cases (10%), however, we documented a spontaneously reabsorbed microhyphema, which was attributed to blood reflux through the collector channels and the SC. Microperforation of the TDM was reported intraoperatively in three cases (6%), neither of which necessitated a peripheral iridectomy.

One other case (2%) with a TDM perforation and iris prolapse was treated by peripheral iridectomy. During the follow-up period, none of the 49 subjects developed a bleb-related complication, such as hypotony, hypotony-related maculopathy, blebitis or endophthalmitis.

The exact mode of action of this non-penetrating antiglaucoma surgical modality is not completely understood. However, viscocanalostomy has been proven to create a direct communication between SC and the juxtacanalicular space (Smit and Johnstone 2002; Takahashi et al 2004; Tamm et al 2004), overcoming the major element of aqueous outflow resistance, the juxtacanalicular tissue (Seiler and Wollensak 1985; Ethier et al 1986). Furthermore, the viscoelastic material (high-molecular-weight sodium hyaluronate) injected into SC and the intrascleral lake, could play an important role in healing modulation (Forrester and Balazs 1977; Forrester and Balazs 1980; Forrester and Wilkinson 1981), decreasing postoperative fibrosis on the surgical wound, a well-known risk factor for filtration-surgery failure (Skuta and Parrish 1987). Although viscocanalostomy was not originally designed to rely on external filtration as the principal mode of action, the sub-conjunctival outflow pathway cannot be excluded. Previous ultrabiomicroscopy studies have sporadically shown shallow filtering blebs in POAG cases after successful, uneventful viscocanalostomy surgery (Sunaric-Megevand G. unpublished data, 2002). Similarly, in the current study, shallow filtration blebs were documented after surgery in 16 cases (33%). Nine (56%) of these blebs regressed spontaneously during the first 12-month follow-up period. However, neither persisting nor non-persisting blebs influenced success rates (Mantel-Cox, $p > 0.05$ for each variable).

The unfavorable influence of previous filtering surgery on the outcome of a subsequent filtration surgery has already been shown (Schwartz and Anderson 1974). In our series, only two eyes (4%) have been previously operated for glaucoma (ie, trabeculectomy). Both cases were classified as a failure during the follow-up period, representing almost a third of all failures. Accordingly, we believe the fact that viscocanalostomy was the primary surgical modality offered to the majority of our cases (96%), positively influenced the surgical outcome of this study. Viscocanalostomy is a challenging technique to master, partly due to its long learning curve (Sunaric-Megevand G. ARVO Meeting, 2003, Abstract, and Stangos A.N. 6th International Glaucoma Symposium, 2007, Abstract). Thus, the surgical outcome may have been positively influenced also by the fact that the performing physician was an experienced phacoemulsification and viscocanalostomy surgeon.

In contrast to phacotrabeculectomy, which appears to be less effective than trabeculectomy alone (Bellucci et al 1997; Lochhead et al 2003), phacoviscocanalostomy was reported to produce a similar hypotensive effect compared to viscocanalostomy alone (Wishart et al 2002). If we also take into consideration the cost effectiveness of combined versus two-stage procedures, phacoviscocanalostomy appears to be a rational therapeutic approach for the treatment of uncontrolled OAG with concomitant age-related cataract. In accordance with previously published phacoviscocanalostomy studies (Gimbel et al 1999; Tanito et al 2002; Wishart et al 2002; Uretmen et al 2003; Park et al 2004, 2006; Wishart and Dages 2006), the current study offers very good results for the treatment of OAG with concomitant age-related cataract, with relatively few and mild complications. Furthermore, taking into account the potentially serious complications of phacotrabeculectomy (Bellucci et al 1997; Sihota et al 1998; DeBry et al 2002; Edmunds et al 2002), the need for safer and still effective alternative surgical procedures is mandatory. Phacoviscocanalostomy can be considered an efficient and safe alternative surgical modality for medically uncontrolled OAG with concomitant age-related cataract. Nevertheless, larger, randomized, comparative studies would provide stronger evidence of the efficiency and safety of phacoviscocanalostomy for such cases.

Conflict of Interest

None

Financial Support

None

References

Bellucci R, Perfetti S, Babighian S, et al. 1997. Filtration and complications after trabeculectomy and after phaco-trabeculectomy. *Acta Ophthalmol Scand Suppl*, 44–5.

Cairns JE. 1968. Trabeculectomy. Preliminary report of a new method. *Am J Ophthalmol*, 66:673–9.

Carassa RG, Bettin P, Brancato R. 2002. Viscocanalostomy vs trabeculectomy. *Ophthalmology*, 109:410–11.

Casson RJ, Salmon JF. 2001. Combined surgery in the treatment of patients with cataract and primary open-angle glaucoma. *J Cataract Refract Surg*, 27:1854–63.

DeBry PW, Perkins TW, Heatley G, et al. 2002. Incidence of late-onset bleb-related complications following trabeculectomy with mitomycin. *Arch Ophthalmol*, 120:297–300.

Drusedau MU, Von Wolff K, Bull H, et al. 2000. Viscocanalostomy for primary open-angle glaucoma: the Gross Pankow experience. *J Cataract Refract Surg*, 26:1367–73.

Edmunds B, Thompson JR, Salmon JF, et al. 2002. The National Survey of Trabeculectomy. III. Early and late complications. *Eye*, 16:297–303.

Ethier CR, Kamm RD, Palaszewski BA, et al. 1986. Calculations of flow resistance in the juxtacanalicular meshwork. *Invest Ophthalmol Vis Sci*, 27:1741–50.

Forrester JV, Balazs EA. 1977. Effect of hyaluronic acid and vitreous on macrophage phagocytosis. *Trans Ophthalmol Soc UK*, 97:554–7.

Forrester JV, Balazs EA. 1980. Inhibition of phagocytosis by high molecular weight hyaluronate. *Immunology*, 40:435–46.

Forrester JV, Wilkinson PC. 1981. Inhibition of leukocyte locomotion by hyaluronic acid. *J Cell Sci*, 48:315–31.

Friedman DS, Jampel HD, Lubomski LH, et al. 2002. Surgical strategies for coexisting glaucoma and cataract: an evidence-based update. *Ophthalmology*, 109:1902–13.

Gimbel HV, Penno EE, Ferensowicz M. 1999. Combined cataract surgery, intraocular lens implantation, and viscocanalostomy. *J Cataract Refract Surg*, 25:1370–5.

Heijl A, Leske MC, Bengtsson B, et al. 2002. Reduction of intraocular pressure and glaucoma progression: results from the Early Manifest Glaucoma Trial. *Arch Ophthalmol*, 120:1268–79.

Hodapp E, Parrish IRK, Anderson DR. 1993. Clinical decisions in glaucoma. St. Louis: Mosby. p 84–126.

Holladay JT. 1997. Proper method for calculating average visual acuity. *J Refract Surg*, 13:388–91.

Hylton C, Congdon N, Friedman D, et al. 2003. Cataract after glaucoma filtration surgery. *Am J Ophthalmol*, 135:231–2.

Kass MA, Heuer DK, Higginbotham EJ, et al. 2002. The Ocular Hypertension Treatment Study: a randomized trial determines that topical ocular hypotensive medication delays or prevents the onset of primary open-angle glaucoma. *Arch Ophthalmol*, 120:701–13; discussion 829–30.

Kobayashi H, Kobayashi K. 2007. Randomized comparison of the intraocular pressure-lowering effect of phacoviscocanalostomy and phacotrabeculectomy. *Ophthalmology*, 114:909–14.

Kocur I, Resnikoff S. 2002. Visual impairment and blindness in Europe and their prevention. *Br J Ophthalmol*, 86:716–22.

Lemon LC, Shin DH, Kim C, et al. 1998. Limbus-based vs fornix-based conjunctival flap in combined glaucoma and cataract surgery with adjunctive mitomycin C. *Am J Ophthalmol*, 125:340–5.

Li KK, Lai JS, Lam DS. 2000. Phacotrabeculectomy: limbus-based versus fornix-based conjunctival flaps. *Ophthalmology*, 107:621–2.

Lochhead J, Casson RJ, Salmon JF. 2003. Long term effect on intraocular pressure of phacotrabeculectomy compared to trabeculectomy. *Br J Ophthalmol*, 87:850–2.

Miserocchi E, Carassa RG, Bettin P, et al. 2004. Viscocanalostomy in patients with glaucoma secondary to uveitis: preliminary report. *J Cataract Refract Surg*, 30:566–70.

Park M, Hayashi K, Takahashi H, et al. 2006. Phaco-viscocanalostomy versus phaco-trabeculectomy: a middle-term study. *J Glaucoma*, 15:456–61.

Park M, Tanito M, Nishikawa M, et al. 2004. Combined viscocanalostomy and cataract surgery compared with cataract surgery in Japanese patients with glaucoma. *J Glaucoma*, 13:55–61.

Schwartz AL, Anderson DR. 1974. Trabecular surgery. *Arch Ophthalmol*, 92:134–8.

Seiler T, Wollensak J. 1985. The resistance of the trabecular meshwork to aqueous humor outflow. *Graefes Arch Clin Exp Ophthalmol*, 223:88–91.

Shingleton BJ, Chaudhry IM, O'donoghue MW, et al. 1999. Phacotrabeculectomy: limbus-based versus fornix-based conjunctival flaps in fellow eyes. *Ophthalmology*, 106:1152–5.

Sihota R, Sharma T, Agarwal HC. 1998. Intraoperative mitomycin C and the corneal endothelium. *Acta Ophthalmol Scand*, 76:80–2.

Skuta GL, Parrish RK 2nd. 1987. Wound healing in glaucoma filtering surgery. *Surv Ophthalmol*, 32:149–70.

Smit BA, Johnstone MA. 2002. Effects of viscoelastic injection into Schlemm's canal in primate and human eyes: potential relevance to viscocanalostomy. *Ophthalmology*, 109:786–92.

Stangos AN, Whatham AR, Sunaric-Megevand G. 2005. Primary viscocanalostomy for juvenile open-angle glaucoma. *Am J Ophthalmol*, 140:490–6.

- Stegmann R, Pienaar A, Miller D. 1999. Viscocanalostomy for open-angle glaucoma in black African patients. *J Cataract Refract Surg*, 25:316–22.
- Sunarić-Megevand G, Leuenberger PM. 2001. Results of viscocanalostomy for primary open-angle glaucoma. *Am J Ophthalmol*, 132:221–8.
- Takahashi H, Tanito M, Yokoyama M, et al. 2004. Two cases of intraoperative anterior chamber angle observation using ophthalmic endoscope in viscocanalostomy. *Am J Ophthalmol*, 138:1060–3.
- Tamm ER, Carassa RG, Albert DM, et al. 2004. Viscocanalostomy in rhesus monkeys. *Arch Ophthalmol*, 122:1826–38.
- Tanito M, Park M, Nishikawa M, et al. 2002. Comparison of surgical outcomes of combined viscocanalostomy and cataract surgery with combined trabeculotomy and cataract surgery. *Am J Ophthalmol*, 134:513–20.
- Uretmen O, Ates H, Guven S, et al. 2003. Comparison of outcomes of viscocanalostomy and phacoviscocanalostomy. *Can J Ophthalmol*, 38:580–6.
- Vass C, Menapace R. 2004. Surgical strategies in patients with combined cataract and glaucoma. *Curr Opin Ophthalmol*, 15:61–6.
- Verges C, Cazal J, Lavin C. 2005. Surgical strategies in patients with cataract and glaucoma. *Curr Opin Ophthalmol*, 16:44–52.
- Vyas AV, Bacon PJ, Percival SP. 1999. The benefits of phacotrabeculectomy using 10-0 polyglactin sutures. *Eye*, 13:215–20.
- Wishart MS, Dages E. 2006. Seven-year follow-up of combined cataract extraction and viscocanalostomy. *J Cataract Refract Surg*, 32:2043–9.
- Wishart MS, Shergill T, Porooshani H. 2002. Viscocanalostomy and phacoviscocanalostomy: long-term results. *J Cataract Refract Surg*, 28:745–51.