

Utilization of anterior lumbar interbody fusion for severe kyphotic deformity secondary to Pott's disease: illustrative case

*Gabrielle Luiselli, BS, Rrita Daci, MD, Peter Cruz-Gordillo, BS, Ashwin Panda, MS, Omar Sorour, AB, and Justin Slavin, MD

Department of Neurological Surgery, University of Massachusetts Medical School, Worcester, Massachusetts

BACKGROUND Spinal tuberculosis may result in severe kyphotic deformity. Effective restoration of lordosis and correction of sagittal balance often requires invasive osteotomies associated with significant morbidity. The advantages of focusing on symptomatic management and staging in the initial treatment of these deformities have not been well reported to date.

OBSERVATIONS The authors reported the case of a 64-year-old Vietnamese woman with a history of spinal tuberculosis who underwent anterior lumbar interbody fusion (ALIF) for symptomatic treatment of L5–S1 radiculopathy resulting from fixed kyphotic deformity. Postoperatively, the patient experienced near immediate symptom improvement, and radiographic evidence at 1-year follow-up showed continued lordotic correction of 30° as well as stable sagittal balance.

LESSONS In this case, an L5–S1 ALIF was sufficient to treat the patient's acute symptoms and provided satisfactory correction of a tuberculosis-associated fixed kyphotic deformity while effectively delaying more invasive measures, such as a vertebral column resection. Patients with adult spinal deformity may benefit from less invasive staging procedures before treating these deformities with larger surgeries.

<https://thejns.org/doi/abs/10.3171/CASE21126>

KEYWORDS anterior lumbar interbody fusion; spinal tuberculosis; Pott's disease; adult spinal deformity; *Mycobacterium tuberculosis*

Adults with spinal deformity often suffer from significant pain, limited mobility, and poor quality of life. Spinal deformities may arise from congenital conditions, infection, neoplasm, traumatic injury, or progression of aging. Treatment of adult spinal deformity (ASD) focuses on the correction of spinopelvic parameters to optimize sagittal balance. Pelvic incidence (PI), the angle between a line perpendicular to the sacral endplate and a line through the center of the femoral head, is a fixed parameter from adolescence and ultimately determines the alignment of the pelvis. Lumbar lordosis (LL), the angle between the superior endplate of L1 and the superior endplate of S1, should come within 10° of the PI to achieve optimal pain relief and functional outcomes. Global sagittal balance, also known as sagittal vertical axis (SVA), is influenced by PI, pelvic tilt (PT), and LL; therefore, surgically correcting LL improves SVA. Two main strategies exist for correcting kyphotic deformity, including

anterior column lengthening procedures and posterior column shortening procedures. In these procedures, release of the anterior longitudinal ligament (ALL) and application of hyperlordotic cages have been shown to be effective.¹ More invasive methods of correcting severe deformities involve spinal osteotomies, such as posterior column osteotomy, pedicle subtraction osteotomy (PSO), and vertebral column resection (VCR). Although these methods allow for maximal correction, they are associated with high risk of blood loss and morbidity.^{1–3}

Spinal tuberculosis, also known as Pott's disease, is a relatively common cause of ASD in people living in developing countries. It affects approximately 10% of patients with active disease and may result in long-term kyphotic deformity. Initially, cold abscesses arising from infected vertebrae, most commonly in the thoracic and lumbar spine, result in destruction of vertebral bodies and

ABBREVIATIONS ALIF = anterior lumbar interbody fusion; ALL = anterior longitudinal ligament; ASD = adult spinal deformity; CT = computed tomography; DVT = deep vein thrombosis; LL = lumbar lordosis; LLIF-ACR = lateral lumbar interbody fusion with anterior column realignment; MRI = magnetic resonance imaging; PI = pelvic incidence; PLL = posterior longitudinal ligament; PSO = pedicle subtraction osteotomy; PT = pelvic tilt; SVA = sagittal vertical axis; VCR = vertebral column resection.

INCLUDE WHEN CITING Published July 26, 2021; DOI: 10.3171/CASE21126.

SUBMITTED February 26, 2021. **ACCEPTED** April 30, 2021.

* G.L. and R.D. contributed equally to this work.

© 2021 The authors, CC BY-NC-ND 4.0 (<http://creativecommons.org/licenses/by-nc-nd/4.0/>).

predispose the patient to kyphotic deformity.⁴ Currently, corrective osteotomy and long segment fusion are the mainstays of treatment for patients with severe kyphosis.⁵ Numerous studies have reported superior treatment of tuberculosis-associated kyphosis with three-column osteotomies.^{6,7} Retrospective analyses of long-term outcomes of corrective osteotomies in the treatment of lumbar kyphosis reported favorable safety and efficacy; however, a tendency for sagittal decompensation, the loss of sagittal balance, was observed in the early postoperative period.^{8,9} The literature thus far has not reported use of initial stabilizing procedures such as anterior lumbar interbody fusion (ALIF) to delay invasive osteotomies in the treatment of kyphotic deformity.

Here, we present the case of a woman with a history of L3-4 Pott's disease with chronic low back pain and radiculopathy as a result of severe kyphotic deformity and subsequent development of adjacent segment degeneration with bilateral foraminal stenosis at L5-S1. Based on pelvic parameters, ideal lordotic correction was measured to be 64.4°. Instead of immediately pursuing a dramatic correction of the deformity, we offered to start with an L5-S1 ALIF to address acute symptoms and then assess the need for a long segment fusion. The patient experienced significant improvement in pain and mobility with the ALIF procedure alone, so we elected to defer any further corrective procedures. This case provides strong support for the strategy of less invasive staging procedures when applicable before larger surgeries for fixed kyphotic deformity correction.

Illustrative Case

A 64-year-old Vietnamese woman with a past medical history of L2-5 spinal tuberculosis presented to the clinic for evaluation of worsening low back pain. The patient received a noninstrumented lumbar fusion in the 1970s in Vietnam for spinal tuberculosis and had since suffered from chronic low back pain with progressive pain, numbness, and weakness, particularly worsening in the bilateral lower extremities during the past few years. At the time of presentation for surgical consultation, she characterized the pain as an 8 on a 10-point pain scale, exacerbated by standing and improved by lying down. The pain radiated down bilateral thighs, anterolateral shins, and dorsal aspects of both feet, with numbness on the dorsum of her right foot and great toe. She experienced difficulty ambulating prolonged distances because of the pain. Conservative treatments, including physical therapy, compression stockings, pain medication, and epidural steroids, were implemented over several years with minimal effect. Physical examination revealed 4/5 strength of the right anterior tibialis and sensory deficit in an L5 distribution bilaterally.

Lumbar spine computed tomography (CT) and magnetic resonance imaging (MRI) on initial presentation showed profound degenerative disc disease and facet arthropathy at L5-S1 causing severe central and foraminal stenosis (Figs. 1 and 2). There was a chronic finding of autofusion of L2-5 resulting in a fixed kyphotic deformity with almost complete destruction of L3 and L4. Scoliosis films showed a fixed kyphotic deformity that was unchanged in the standing and supine positions (Fig. 3A). PI was 40°, suggesting ideal LL to be 40°. Lumbar angulation was 24.4° in kyphosis, indicating 64.4° of correction necessary. Sacral slope was low and PT was 30.9°, which indicated significant retroversion of the pelvis to stand upright. Because of poor response to noninvasive therapies and progression of symptoms, the patient agreed to surgical intervention. Her vascular anatomy on the ventral surface of the spine was tortuous, with an area of redundancy to the aorta due to severe

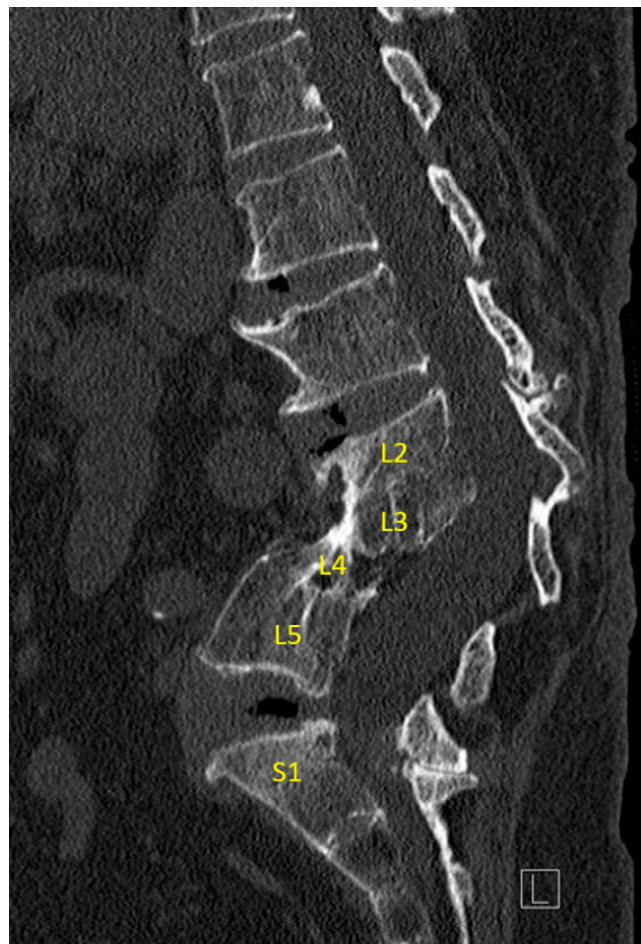

FIG. 1. Preoperative sagittal CT of the lumbar spine without contrast shows multilevel spondylosis as well as severe deformity of the lumbar spine predominately involving acute kyphosis of L2-5, deformity of vertebral bodies, and osseous bony bridging, likely secondary to reported history of Pott's disease.

anterior column shortening from Pott's disease. In creating a surgical strategy for adequate treatment of her concerns in light of severe kyphotic deformity, an L5-S1 ALIF was recommended to provide a solid base for fusion and provide indirect decompression of the L5-S1 foraminal stenosis that was contributing to her acute symptoms. If she remained symptomatic, this procedure would be followed by a T10-pelvis fusion with VCR at L4 1 to 2 weeks after ALIF to provide more substantial correction of the kyphotic deformity.

The vascular surgery team performed a standard anterior abdominal approach. After release of the ALL, discectomy at L5-S1 was carried out in piecemeal fashion to expose the posterior annulus and posterior longitudinal ligament (PLL). Once the disc space had been adequately cleaned, sizing discs were trialed, during which the posterior disc annulus and PLL were released to expose the thecal sac and the exiting nerve roots on either side. Lateral fluoroscopy visualization showed that a height of 21 mm at 30° lordosis provided good restoration of disc height. A 21 × 30 mm 30° lordosis interbody device from Globus Medical was selected and filled with bone putty as well as an allograft of OsteoAmp mixed with bone marrow aspirate. The device was lightly tapped into the

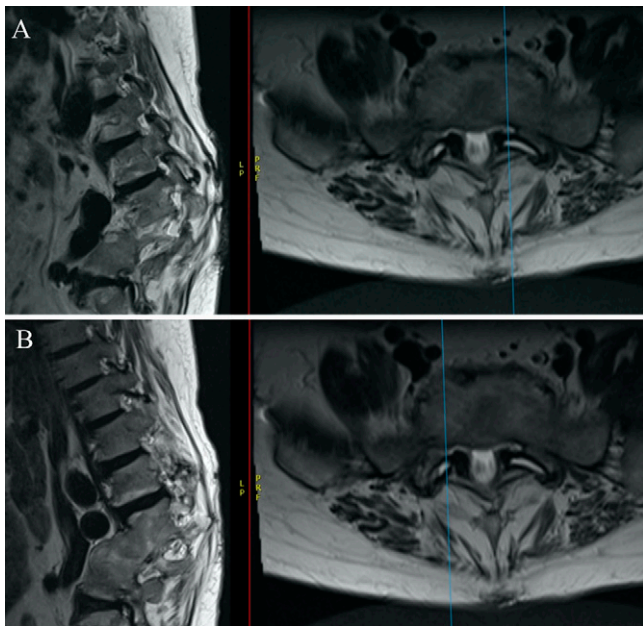


FIG. 2. Preoperative sagittal MRI of lumbar spine without contrast. At L5–S1, there is disc bulge, facet hypertrophy, and ligamentum flavum thickening causing severe bilateral foraminal stenosis and moderate to severe spinal canal stenosis. **A:** Left-sided foraminal stenosis at L5–S1. **B:** Right-sided foraminal stenosis at L5–S1. *Blue lines* show the plane of the sagittal view (left and right foramen).

disc space with a mallet to achieve arthrodesis. Three 25-mm screws were advanced into L5 and S1, respectively, using the integrated plate of the interbody. Fluoroscopy was performed to assess adequate placement of the interbody device and restoration of disc height. Locking screws covered the screw entry sites to prevent backing out. After copious irrigation, general surgeons proceeded with closure of the abdominal wound. Postoperative imaging showed an LL of -12.7° , an 11.7° correction from her preoperative LL of -24.4° (Fig. 3B).

On postoperative day 14, the patient presented for a wound check. The incision was clean, dry, and intact. The physical examination showed 5/5 normal strength with no focal or dermatomal symptoms. Her recovery was complicated by a deep vein thrombosis (DVT) extending from the common iliac vein to the peroneal vein. It was later determined to be May-Thurner syndrome, the development of an iliac thromboembolism secondary to an anatomical variant of the iliac vasculature. On postoperative day 36, the patient presented for continued follow-up. There was minor bleeding from the incision site, likely the result of therapeutic anticoagulation for the DVT, which resolved over time. Imaging at that time confirmed stable placement of the interbody cage and screws. We did not request a postoperative CT scan to confirm fusion status because the patient did not have neurological symptoms to warrant further imaging. We had considered performing percutaneous pedicle screw instrumentation at L5–S1 if a larger procedure was deemed unnecessary, but it was deferred because of her need for anticoagulation in the absence of neurological symptoms.

One year after the procedure, the patient presented to clinic for evaluation. She denied back pain, leg pain, or weakness in her legs. The patient believes she now stands straighter and has im-

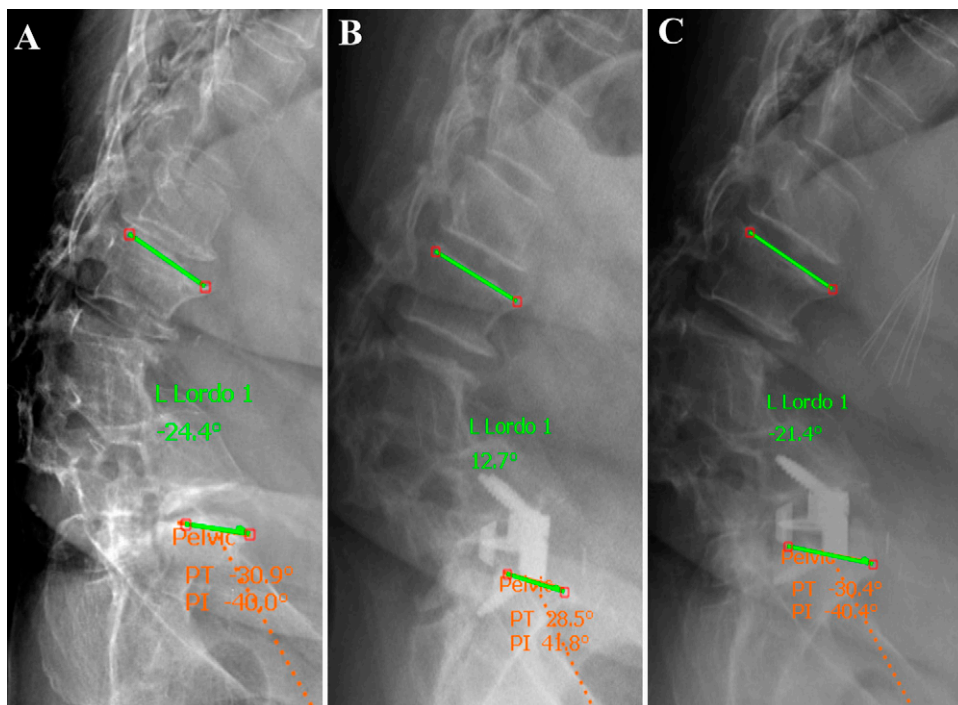


FIG. 3. **A:** Preoperative sagittal scoliosis radiograph. LL of -24.4° , PI of 40.0° , and PI-LL mismatch of 64.4° . **B:** Postoperative upright radiograph. LL of -12.7° , PI of 41.8° , and PI-LL of 54.5° . **C:** One-year follow-up scoliosis radiograph. Some regression of lordosis with LL of -21.4° , PI of 40.4° , and PI-LL of 61.8° .

proved mobility. On examination, her strength was 5/5 throughout, and no focal neurological deficits were identified. She endorsed some persistent sensitivity in her abdomen due to abdominal exposure from the ALIF procedure as well as the chronic DVT in her left iliac vein. Previous attempts at restoration of the vein were unsuccessful because of fibrinous chronic DVT. As a result, she continues to experience swelling in the left lower extremity when upright for long periods of time. Imaging at 1-year follow-up showed an intact anterior fusion plate at L5–S1 with an LL of -21.4° and a PI of 40.4° , for a mismatch of approximately 61.8° . This mismatch is improved from a preoperative mismatch of 64.4° . Although her ideal lordotic correction was measured to be 64.4° and there was regression of lordosis over 1 year, an ALIF in this case provided continued elimination of symptoms at 1-year follow-up, and the secondarily planned VCR was postponed.

Discussion

Observations

Kyphotic deformity as a sequela of spinal tuberculosis results from the destruction of vertebral bodies by *Mycobacterium tuberculosis* abscesses. Three types of reconstitution may result after resolution of active infection: Type A, with minimal vertebral body destruction and an intact posterior column; Type B, which causes 40° to 60° of kyphosis; and Type C, which causes more than 100° of kyphosis. Neurological deficits as a result of these deformities may continue to progress years after disease.^{4,10} Traditionally, surgeons have relied on combined anterior and posterior approaches to adequately correct fixed kyphotic deformities, particularly those caused by spinal tuberculosis.^{7,11–13} These procedures have been associated with risks such as paraplegia, damage to vascular elements, and spinal instability.^{5,13}

A retrospective study of 23 patients with fixed kyphosis determined that total vertebrectomy resulted in the most favorable safety profile and correction rate in patients with angular kyphosis more than 60° .¹¹ Alternatively, Deng et al. assessed the utility of posterior en bloc spondylectomy in the treatment of spinal tuberculosis–associated fixed kyphotic deformity using Odom's classification.⁵ Out of 34 cases, they reported an excellent outcome in 9 patients and a good outcome in 23 patients, with infrequent minor complications such as screw loosening. However, posterior en bloc spondylectomy remains technically challenging and carries significant risk of nerve injury during the excision.⁵ Furthermore, a study evaluating the use of VCR to treat spinal tuberculosis–associated kyphosis reported favorable long-term outcomes, such as stable instrumentation and low incidence of ASD after fusion. Even so, intraoperative and postoperative complications such as hemorrhage, dural tear, and respiratory failure were observed, as was a tendency for postoperative sagittal decompensation in lumbar tubercular kyphosis.⁹ Based on these reports, it is clear that the open procedures often used to correct severe kyphotic deformity secondary to spinal tuberculosis remain technically complex, carry substantial risk for the patient, and may eventually result in sagittal decompensation.

From the surgeon's perspective, planning ASD correction requires evaluation of the patient's spinopelvic parameters, identification of comorbidities, and discussion of the patient's goals regarding mobility and aesthetics. Several mathematical models have been proposed in the literature to aid decision-making in ASD surgery and typically involve parameters such as LL and thoracic kyphosis. Formulas that account for PT and PI, parameters associated with pelvic retroversion and risk of postoperative spinal deformity, respectively, have been shown to be most accurate in predicting

postoperative sagittal balance.¹⁴ Alternatively, algorithms such as the Minimally Invasive Spinal Deformity Surgery algorithm use the mismatch between PI and LL (PI-LL), SVA, and PT to categorize patients into treatment classes.^{15,16} In addition to evaluating spinopelvic parameters through either formulaic calculations or algorithms, it is critical to identify medical risk factors such as hypertension, smoking, and increased duration of symptoms, which have all been associated with a higher rate of infectious, cardiopulmonary, and gastrointestinal complications in ASD correction.¹⁷

Here, we describe the case of a 64-year-old woman with a history of spinal tuberculosis and low back surgery who had failed conservative management for low back and leg pain. Her history of fixed kyphotic deformity likely instigated L5–S1 degenerative disc disease and subsequent severe foraminal stenosis. The decision to begin with L5–S1 ALIF for this case was based on the patient's acutely worsening L5 radiculopathy and her preference to avoid a large, invasive surgery if possible. This patient underwent L5–S1 ALIF to relieve her radiculopathy and determine the need for long segment fusion to correct the chronic fixed kyphotic deformity. Significant decompression was achieved at the posterior disc space by releasing the entire ALL and PLL and placing a hyperlordotic cage to maximize correction. The patient experienced near immediate symptomatic improvement and remained pain-free throughout the postoperative period. Although the target lordotic correction for this patient was estimated by PI-LL mismatch to be 64.4° , an L5–S1 ALIF in this case accomplished an initial correction of 11.7° of lordosis and eradicated the patient's chronic low back and leg pain. Based on the patient's excellent outcome, the planned secondary T10–pelvis fusion with VCR at L4 was deferred. This case illustrates the potential benefit of staging procedures wherein a patient increases lordosis slightly and achieves excellent symptomatic relief despite not having a major corrective procedure and avoiding the risks of such a procedure.

Despite the encouraging result with the initial staging procedure alone, we planned for the possibility that the patient's global sagittal alignment could decompensate. Should the patient develop back pain without pseudarthrosis, we would proceed with the second stage as originally planned. If the patient developed pseudarthrosis, we would scale our approach based on the severity of the condition. For severe pseudarthrosis, we would perform a revision of the anterior procedure followed by posterior instrumentation and posterolateral fusion. If VCR were unwarranted at that time, we would stop at L4 and instrument across the L5–S1 segment. However, if VCR were required, we would perform the procedure at L3, thus leaving two segments between the VCR and prior interbody placement with thorough posterolateral fusion, multiple rods, and pelvic fixation.

Although ALIF was unsuccessful in achieving the ideal lordotic correction in this case, the strategy of placing an ALIF cage at L5–S1 provides a strong base for the fusion construct across the lumbosacral junction in a larger construct. Additionally, it provides greater stabilization and the option of hyperlordotic correction across the segment beyond what could be achieved with posterior interbody fusion. Although an ALIF was determined to be the safest and least invasive initial approach in this patient, this procedure carries its own risks of vascular injury and, in men, retrograde ejaculation.¹⁸ Nevertheless, a recent study comparing lumbar PSO to lateral lumbar interbody fusion with anterior column realignment (LLIF-ACR) found that LLIF-ACR not only minimized blood loss but also was equally effective as PSO in deformity correction.¹⁹ In

addition, a longitudinal multicenter analysis of minimally invasive surgery identified a shift toward ALIF surgery and away from three-column osteotomies with the advent of hyperlordotic cages; however, centers continue to differ in their use of lateral ACR and posterior osteotomy techniques.²⁰ It is evident that there is no singular approach to planning spinal deformity surgery, and various factors related to the patient's medical stability and surgeon's technical abilities must be considered.

Lessons

Correction of ASD requires the surgeon to evaluate risk and accommodate patient preference. Although it is common practice to use invasive procedures in the treatment of severe spinal deformities, both the surgeon and patient may benefit from smaller staged procedures with minimally invasive techniques before committing to more aggressive surgeries. This consideration is especially important for comorbid elderly patients who may be unable to tolerate perioperative complications associated with invasive osteotomies such as VCR.

In this case, the patient's deformity and quality of life were adequately improved by an ALIF procedure alone. Our case report is limited in scope because it describes observations made from a single female patient with fixed kyphosis resulting from spinal tuberculosis. This patient was also predisposed to developing a postoperative thromboembolism due to May-Thurner syndrome. However, this case and more recently proposed algorithms such as PI-LL mismatch strongly support both the assessment of spinopelvic parameters and use of minimally invasive techniques before more complex procedures.

References

- Makhni MC, Shillingford JN, Laratta JL, et al. Restoration of sagittal balance in spinal deformity surgery. *J Korean Neurosurg Soc.* 2018;61(2):167–179.
- Kose KC, Bozduman O, Yenigul AE, Iğrek S. Spinal osteotomies: indications, limits and pitfalls. *EFORT Open Rev.* 2017;2(3):73–82.
- Mehta VA, Amin A, Omeis I, et al. Implications of spinopelvic alignment for the spine surgeon. *Neurosurgery.* 2012;70(3):707–721.
- Khanna K, Sabharwal S. Spinal tuberculosis: a comprehensive review for the modern spine surgeon. *Spine J.* 2019;19(11):1858–1870.
- Deng Y, Lv G, An HS. En bloc spondylectomy for the treatment of spinal tuberculosis with fixed and sharply angulated kyphotic deformity. *Spine (Phila Pa 1976).* 2009;34(20):2140–2146.
- Boachie-Adjei O, Papadopoulos EC, Pellisé F, et al. Late treatment of tuberculosis-associated kyphosis: literature review and experience from a SRS-GOP site. *Eur Spine J.* 2013;22(suppl 4):641–646.
- Panchmatia JR, Lenke LG, Molloy S, et al. Review article: surgical approaches for correction of post-tubercular kyphosis. *J Orthop Surg (Hong Kong).* 2015;23(3):391–394.
- Lee SH, Kim KT, Suk KS, et al. Sagittal decompensation after corrective osteotomy for lumbar degenerative kyphosis: classification and risk factors. *Spine (Phila Pa 1976).* 2011;36(8):E538–E544.

- Liu C, Lin L, Wang W, et al. Long-term outcomes of vertebral column resection for kyphosis in patients with cured spinal tuberculosis: average 8-year follow-up. *J Neurosurg Spine.* 2016;24(5):777–785.
- Rajasekaran S. Kyphotic deformity in spinal tuberculosis and its management. *Int Orthop.* 2012;36(2):359–365.
- Cho WJ, Kang CN, Park YS, et al. Surgical correction of fixed kyphosis. *Asian Spine J.* 2007;1(1):12–18.
- Pappou IP, Papadopoulos EC, Swanson AN, et al. Pott disease in the thoracolumbar spine with marked kyphosis and progressive paraplegia necessitating posterior vertebral column resection and anterior reconstruction with a cage. *Spine (Phila Pa 1976).* 2006;31(4):E123–E127.
- Watts HG, Lifeso RM. Tuberculosis of bones and joints. *J Bone Joint Surg Am.* 1996;78(2):288–298.
- Ames CP, Smith JS, Scheer JK, et al. Impact of spinopelvic alignment on decision making in deformity surgery in adults: a review. *J Neurosurg Spine.* 2012;16(6):547–564.
- Mummaneni PV, Shaffrey CI, Lenke LG, et al. The minimally invasive spinal deformity surgery algorithm: a reproducible rational framework for decision making in minimally invasive spinal deformity surgery. *Neurosurg Focus.* 2014;36(5):E6.
- Choy W, Miller CA, Chan AK, et al. Evolution of the minimally invasive spinal deformity surgery algorithm: an evidence-based approach to surgical strategies for deformity correction. *Neurosurg Clin N Am.* 2018;29(3):399–406.
- Soroceanu A, Burton DC, Oren JH, et al. Medical complications after adult spinal deformity surgery: incidence, risk factors, and clinical impact. *Spine (Phila Pa 1976).* 2016;41(22):1718–1723.
- Chan AK, Mummaneni PV, Shaffrey CI. Approach selection: multiple anterior lumbar interbody fusion to recreate lumbar lordosis versus pedicle subtraction osteotomy: when, why, how? *Neurosurg Clin N Am.* 2018;29(3):341–354.
- Leveque JC, Yanamadala V, Buchlak QD, Sethi RK. Correction of severe spinopelvic mismatch: decreased blood loss with lateral hyperlordotic interbody grafts as compared with pedicle subtraction osteotomy. *Neurosurg Focus.* 2017;43(2):E15.
- Wang MY, Tran S, Brusko GD, et al. Less invasive spinal deformity surgery: the impact of the learning curve at tertiary spine care centers. *J Neurosurg Spine.* 2019;31(6):865–872.

Disclosures

The authors report no conflict of interest concerning the materials or methods used in this study or the findings specified in this paper.

Author Contributions

Conception and design: Slavin, Luiselli, Sorour. Acquisition of data: Slavin, Luiselli, Sorour. Analysis and interpretation of data: Slavin, Luiselli, Daci, Cruz-Gordillo, Sorour. Drafting the article: all authors. Critically revising the article: Slavin, Luiselli, Daci, Cruz-Gordillo, Panda. Reviewed submitted version of manuscript: Slavin, Luiselli, Daci, Cruz-Gordillo, Panda. Statistical analysis: Sorour. Administrative/technical/material support: Slavin, Sorour. Study supervision: Slavin.

Correspondence

Justin Slavin: University of Massachusetts Medical School, Worcester, MA. justin.slavin@umassmemorial.org.