

# Longitudinal shortening of sub-epicardial myocytes in severe ischaemic cardiomyopathy: insights from gadolinium contrast cardiac magnetic resonance imaging

Jenny Bjerre<sup>1</sup>, Kasper Kyhl<sup>2</sup>, Finn Gustafsson<sup>2</sup>, Henning Kelbæk<sup>3</sup>, Thomas Engstrøm<sup>2</sup>, Peter Skov Olsen<sup>4</sup>, Philip Hasbak<sup>5</sup>, Niels Vejstrup<sup>2</sup> and Per Lav Madsen<sup>2,6\*</sup>

<sup>1</sup>Department of Cardiology, Copenhagen University Hospital Herlev and Gentofte, Hellerup, Denmark; <sup>2</sup>Department of Cardiology, Rigshospitalet, Copenhagen, Denmark; <sup>3</sup>Department of Cardiology, Copenhagen University Hospital, Roskilde, Denmark; <sup>4</sup>Department of Cardiothoracic Surgery, Rigshospitalet, Copenhagen, Denmark; <sup>5</sup>Department of Clinical Physiology, Rigshospitalet, Copenhagen, Denmark; <sup>6</sup>Department of Cardiology, Copenhagen University Hospital Herlev and Gentofte, Herlev, Denmark

## Abstract

We present two patients with three-vessel disease and severely depressed left ventricular (LV) systolic function where viability analysis by cardiac magnetic resonance imaging demonstrated areas of near-transmural sub-endocardial fibrosis and hence little chance of regaining systolic function as judged by conventional analysis from radial function. Despite the pessimistic cardiac magnetic resonance imaging analysis, however, the patients underwent full revascularization and regained impressive increases in LV systolic function mainly based on improved longitudinal systolic segment function. The cases highlight that sub-epicardial, longitudinally oriented myocytes can contribute to overall LV systolic function and suggest taking their 'piston-function' into consideration when analysing viability.

**Keywords** CMR (Cardiovascular magnetic resonance); Viability; Ischaemic cardiomyopathy; Revascularization

Received: 29 April 2016; Revised: 11 April 2017; Accepted: 27 April 2017

\*Correspondence to: Per Lav Madsen, Department of Cardiology, Copenhagen University Hospital Herlev and Gentofte, Herlev Ringvej 75, DK-2730 Herlev, Denmark.  
Email: lav.madsen@gmail.com

## Introduction

Cardiac magnetic resonance imaging (CMR) with late gadolinium enhancement (LGE) has become a preferred technique for determination of fibrosis and hence viability in ischaemic cardiomyopathy. Analysis is based on studies demonstrating improvement in radial contractility (myocardial thickening) following revascularization in hypo- or akinetic segments without substantial transmural fibrosis.<sup>1,2</sup> With >75% transmural fibrosis, minimal improvement in radial contractility can be expected. However, analysis based on potential improvements in myocardial thickening mainly takes into account the function of mid-myocardial fibres and little account of the function of sub-epicardial fibres that (like the sub-endocardial) are involved in longitudinal function primarily.<sup>3</sup> In patients with severe ischaemic cardiomyopathy, we extend viability analysis to

potential gains in not only radial but also in longitudinal left ventricular (LV) systolic function. As a demonstration of this way of thinking, we here present two patients with three-vessel coronary artery disease and severely depressed systolic function in whom revascularization was decided on despite >75% transmural fibrosis on LGE CMR because alternative options were considered too difficult.

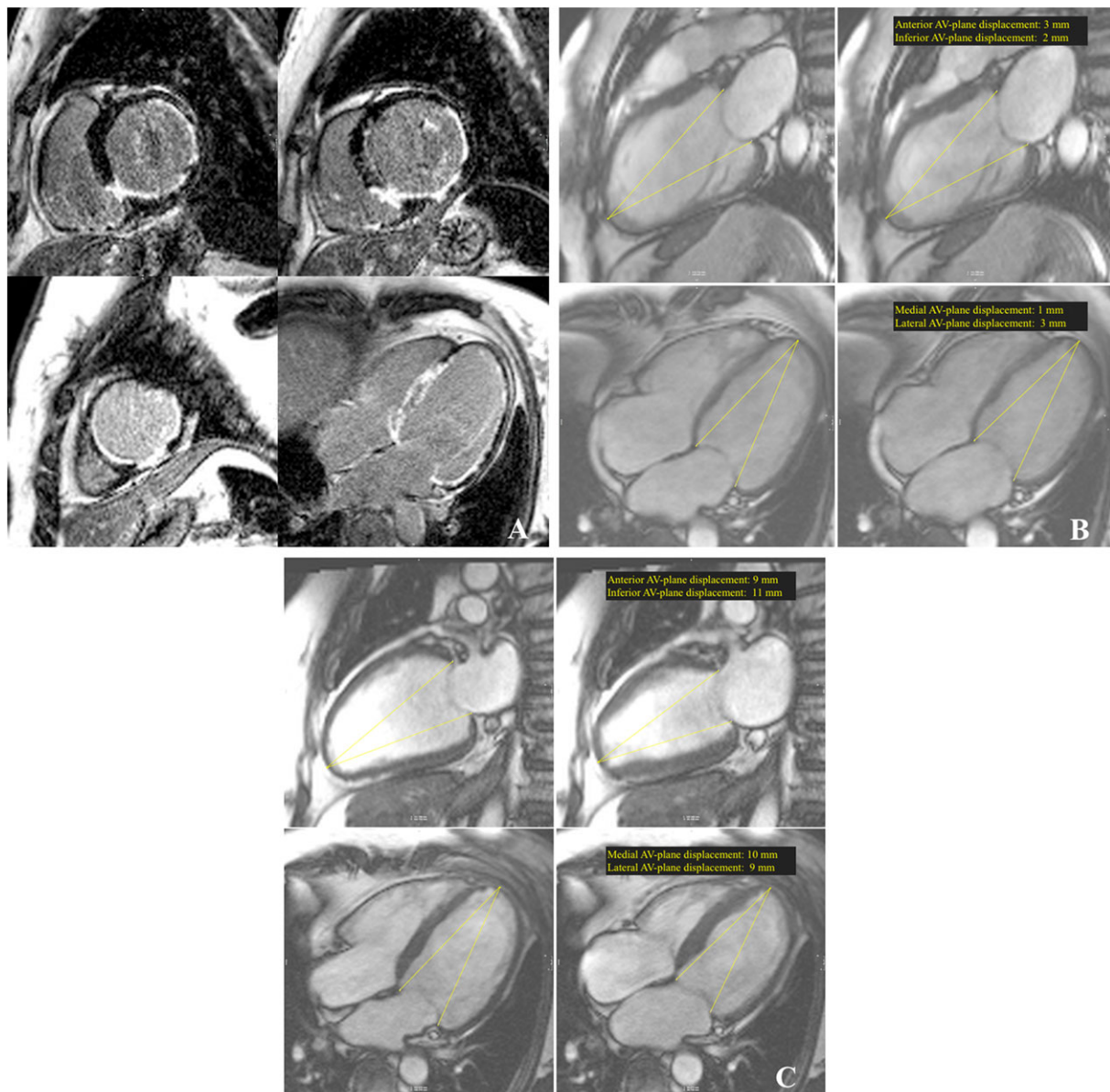
## Case reports

A 65-year-old woman presented with severe shortness of breath [New York Heart Association (NYHA) Class IV] and signs of a previous inferior wall infarction with pathologic Q-waves in II, III, and aVF on electrocardiogram. Coronary angiography proved severe three-vessel coronary artery disease, and following initial stabilization, the patient was initiated on guideline recommended heart failure medication. Four weeks

following initial admission, CMR showed a severely dilated LV [LV end-diastolic volume (LVEDV) of 265 mL (133 mL/m<sup>2</sup>)], an LVEF of 14%, and widespread areas of near-transmural fibrosis in the left circumflex artery (LCX) and right coronary artery territories, but little fibrosis in the left anterior descending artery territory (*Figure 1A*; *Movies S1* and *S2*). Heart transplantation was decided against, and percutaneous coronary intervention (PCI) of all three vessels was performed

with a total of seven drug eluting stents. Three months after the PCI and on guideline recommended target dose of spironolactone, metoprolol, and maximum tolerated dose of losartan, a follow-up CMR showed that the LVEDV had decreased to 234 mL and LVEF improved to 37% (*Movies S3* and *S4*). The LGE imaging demonstrated no procedural infarction. Radial function improved very little, including the inferior and lateral wall with up to >75% fibrosis (*Figure 3*).

**Figure 1** (A) Late gadolinium enhancement short axis images at a basal (upper left), midventricular (upper right), and apical (lower left) level and four-chamber image with widespread areas of near-transmural fibrosis in LCX and right coronary artery territories but little fibrosis in the left anterior descending artery territory. (B) Pre-percutaneous coronary intervention (PCI) two-chamber (upper panels) and four-chamber (lower panels) images with end-diastolic (left) and end-systolic (right) measurements of AV-plane displacement. (C) Post-PCI two-chamber (upper panels) and four-chamber (lower panels) images with end-diastolic (left) and end-systolic (right) measurements of AV-plane displacement, which improved to >9 mm in all segments.

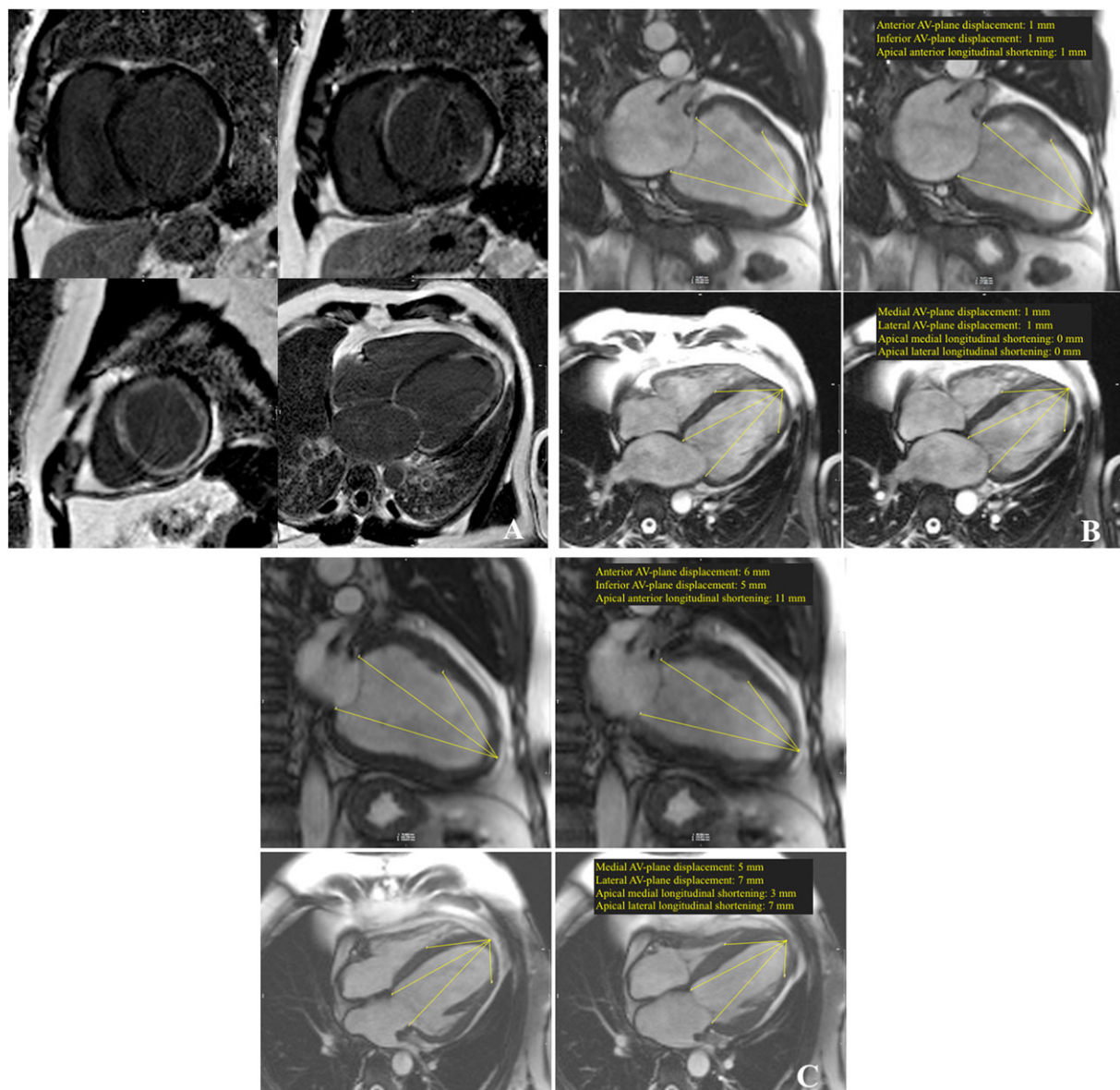


However, atrioventricular (AV)-plane displacement improved from <3 to 9–11 mm in all segments, including the inferior wall where only a little sub-epicardial viable tissue was found (Figure 1B–C). Six months after her revascularization, the patient was symptom-free (NYHA Class I).

A 47-year-old previously healthy man presented with gradually increasing shortness of breath over the previous 3 months, on admission corresponding to NYHA Class IV. Initial work-up with electrocardiogram and troponins found

no acute coronary syndrome or pulmonary embolism but signs of a previous lateral myocardial infarction. Echocardiography showed severely depressed systolic function. The patient was put on maximum tolerated doses of guideline heart failure medication, including ramipril, carvedilol, and spironolactone. Six weeks following initial admission, CMR demonstrated a severely dilated LV [LVEDV of 336 mL (149 mL/m<sup>2</sup>)], an LVEF of 15% and 50% transmural fibrosis in the anterolateral wall at a basal and

**Figure 2** (A). Late gadolinium enhancement short axis images at a basal (upper left), midventricular (upper right), and apical (lower left) level and four-chamber image with 50% transmural fibrosis in the anterolateral wall at a basal and midventricular level and up to 75% transmural fibrosis in the whole circumference at an apical level. (B) Pre-CABG two-chamber (upper panels) and four-chamber (lower panels) images with end-diastolic (left) and end-systolic (right) measurements of AV-plane displacement. (C) Post-CABG two-chamber (upper panels) and four-chamber (lower panels) images with end-diastolic (left) and end-systolic (right) measurements of AV-plane displacement, which improved from 1 mm in all areas to 6, 5, 5, and 7 mm in the two-plane (anterior and inferior) and four-plane (medial and lateral) views, respectively.

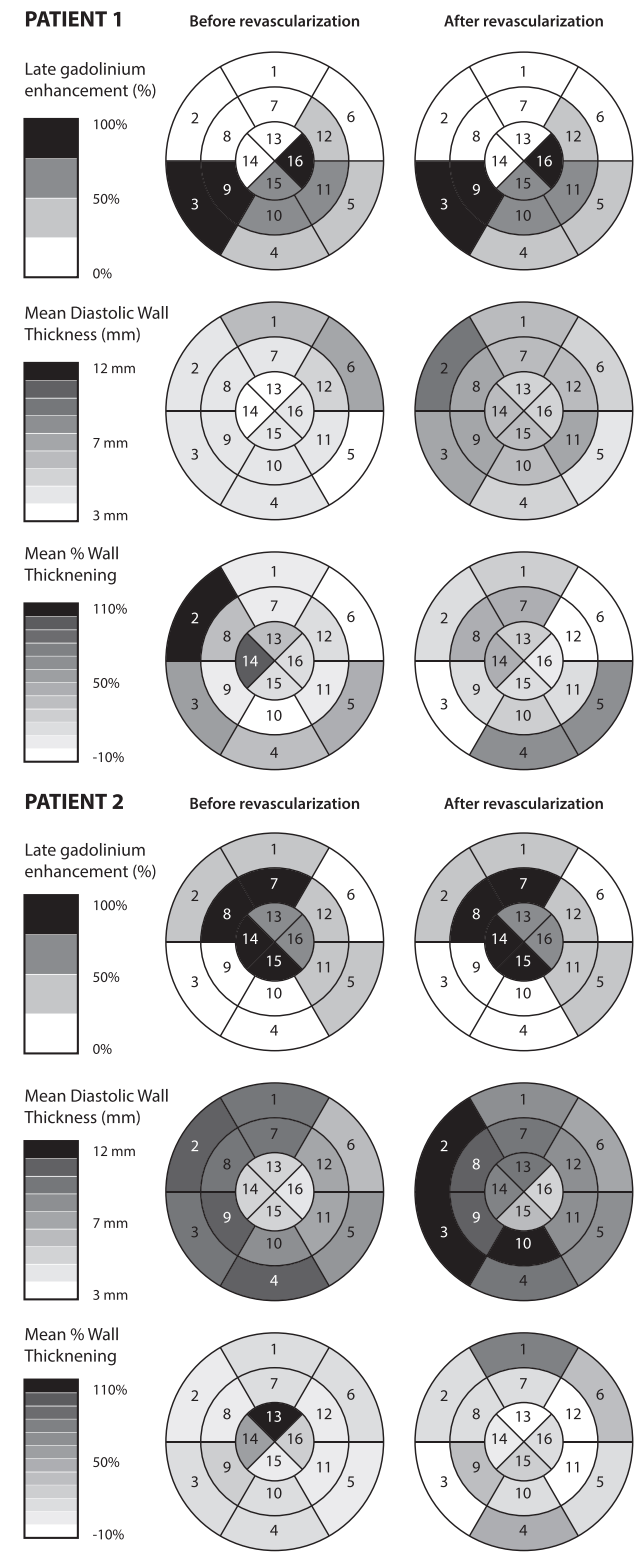


mid-ventricular level, and >75% transmural fibrosis in the whole circumference at an apical level (Figure 2A; Movies S5 and S6). Positron Emission Tomography (PET) imaging did not suggest significant viability, but based on LGE CMR, it was decided to pursue coronary artery bypass grafting (CABG) and following grafting of all territories, LV function improved. The patient recovered to NYHA Class I, the LVEDV decreased to 284 mL, and the LVEF improved to 28% (Movies S7 and S8). There was no additional LGE, documenting no CABG-related infarction. Radial function improved only slightly in the basal anterior wall (with approximately 50% fibrosis) and not at all in the mid-ventricular and apical segments with >75% fibrosis (Figure 3). Thus, the improvement of LV function was largely due to improvements in longitudinal motion. The AV-plane displacement improved from 1, 1, 1, and 1 mm to 6, 5, 5, and 7 mm in the two-plane (anterior and inferior) and four-plane (medial and lateral) views, respectively (Figure 2B–C). Longitudinal shortening of the mid-ventricular and apical part of the LV (with up to 75% transmural fibrosis) improved from 1, 0, and 0 mm to 11, 3 and 7 mm, respectively (determined corresponding to fixed anatomical points including insertion of papillary muscle and septal origin of the moderator band) (Figure 2B–C).

## Discussion

Mid-myocardial fibres have a predominantly circumferential orientation, and hence, shortening of these fibres will mainly contribute to radial contractility. Sub-endocardial and sub-epicardial fibres have longitudinal orientations with the sub-endocardial describing a right-handed helix (as seen from the apex) and the sub-epicardial describing a left-handed.<sup>3</sup> Based on this anatomical knowledge, it is understandable that >75% fibrosis will seriously limit radial contractility, whereas <25% fibrosis will not. If only the sub-epicardial layer is spared, substantial improvements in radial contractility cannot be expected with revascularization, but in our patients, revascularization of this viable sub-epicardial layer contributed to a significant improvement in longitudinal LV shortening. In these two cases, this improvement in longitudinal shortening helped improve overall systolic function as also reflected in ejection fractions. If findings from the STICH trial<sup>4</sup> (median LVEF 28% and 27% in the medically treated group and CABG group, respectively) had been extrapolated to our patients, they may not have been revascularized. Although we cannot tell what would have happened to our patients if not revascularized but conservatively treated with heart failure medication, we believe that the impressive increases in LVEF with concomitant improvements in NYHA class from IV to I were probably largely due to the revascularization in itself. Beta-blocker therapy can contribute to an increase in LV function,<sup>5,6</sup> but the effect of Angiotensin-converting enzyme

**Figure 3** Segmental (American Heart Association 16-segment model) late gadolinium enhancement (%) (Rows 1 and 4); mean diastolic wall thickness (mm) (Rows 2 and 5); and mean wall thickening (%) (Rows 3 and 6) before (left panels) and after revascularization (right panels).



inhibitors and mineralocorticoid receptor antagonists on LVEF is less well established. Some echocardiographic studies have found a minor increase in LVEF with the latter,<sup>7,8</sup> although not sufficient to explain the overall beneficial effect of treatment. These case reports may serve as an inspiration that in such patients, even in areas with only little sub-epicardial viable myocardium left, one should not completely dismiss such segments but consider applying analysis based on the kind of systolic function predominantly performed by these fibres, that is, the longitudinal shortening and hence 'piston-function' of the left ventricle. The cases may also serve as an inspiration for analysis with gadolinium analysis in future studies on revascularization in patients with ischaemic cardiomyopathy.

## Conflict of interest

None declared.

## Supporting information

Additional Supporting Information may be found online in the supporting information tab for this article.

**Movie S1** Four-chamber cine loop with a severely dilated left ventricle (LV) with depressed systolic function; LV ejection fraction 14%.

**Movie S2** Two-chamber cine loop with a severely dilated left ventricle (LV) with depressed systolic function; LV ejection fraction 14%.

**Movie S3** Post-percutaneous coronary intervention (PCI) four-chamber cine loop with improved LV systolic function (LV ejection fraction 37%) and markedly increased AV-plane displacement.

**Movie S4** Post-percutaneous coronary intervention (PCI) two-chamber (D) cine loop with improved LV systolic function (LV ejection fraction 37%) and markedly increased AV-plane displacement.

**Movie S5** Four-chamber cine loop with a severely dilated left ventricle (LV) with depressed systolic function; LV ejection fraction: 15%.

**Movie S6** Two-chamber cine loop with a severely dilated left ventricle (LV) with depressed systolic function; LV ejection fraction: 15%.

**Movie S7** Post-CABG four-chamber cine loop with improved LV systolic function (LV ejection fraction 28%) and markedly increased AV-plane displacement.

**Movie S8** Post-CABG two-chamber cine loop with improved LV systolic function (LV ejection fraction 28%) and markedly increased AV-plane displacement.

## References

- Kim RJ, Wu E, Rafael A, Chen EL, Parker MA, Simonetti O, Klocke FJ, Bonow RO, Judd RM. The use of contrast-enhanced magnetic resonance imaging to identify reversible myocardial dysfunction. *N Engl J Med* 2000; **343**: 1445–1453.
- Selvanayagam JB, Kardos A, Francis JM, Wiesmann F, Petersen SE, Taggart DP, Neubauer S. Value of delayed-enhancement cardiovascular magnetic resonance imaging in predicting myocardial viability after surgical revascularization. *Circulation* 2004; **110**: 1535–1541.
- Streeter DD Jr, Spotnitz HM, Patel DP, Ross J Jr, Sonnenblick EH. Fiber orientation in the canine left ventricle during diastole and systole. *Circ Res* 1969; **24**: 339–347.
- Velazquez EJ, Lee KL, Deja MA, Jain A, Sopko G, Marchenko A, Ali IS, Pohost G, Gradinac S, Abraham WT, Yui M, Prabhakaran D, Szwed H, Ferrazzi P, Petrie MC, O'Connor CM, Panchavinnin P, She L, Bonow RO, Rankin GR, Jones RH, Rouleau JL. Coronary-artery bypass surgery in patients with left ventricular dysfunction. *N Engl J Med* 2011; **364**: 1607–1616.
- Groenning BA, Nilsson JC, Sondergaard L, Fritz-Hansen T, Larsson HB, Hildebrandt PR. Antiremodeling effects on the left ventricle during beta-blockade with metoprolol in the treatment of chronic heart failure. *J Am Coll Cardiol* 2000; **36**: 2072–2080.
- Lechat P, Packer M, Chalon S, Cucherat M, Arab T, Boissel JP. Clinical effects of beta-adrenergic blockade in chronic heart failure: a meta-analysis of double-blind, placebo-controlled, randomized trials. *Circulation* 1998; **98**: 1184–1191.
- Abdulla J, Barlera S, Latini R, Kjoller-Hansen L, Sogaard P, Christensen E, Kober L, Torp-Pedersen C. A systematic review: effect of angiotensin converting enzyme inhibition on left ventricular volumes and ejection fraction in patients with a myocardial infarction and in patients with left ventricular dysfunction. *Eur J Heart Fail* 2007; **9**: 129–135.
- Cicoira M, Zanolla L, Rossi A, Golia G, Franceschini L, Brighetti G, Marino P, Zardini P. Long-term, dose-dependent effects of spironolactone on left ventricular function and exercise tolerance in patients with chronic heart failure. *J Am Coll Cardiol* 2002; **40**: 304–310.