

# Unusual Presentation of a Penetrating Aortic Arch Injury

Fikret Sami Vural, M.D., Atul Kumar Patel, M.B.B.S., Kashif Mustafa, M.B.B.S.

Department of Cardiothoracic Surgery, Charlotte Maxeke Johannesburg Academic Hospital, University of Witwatersrand

A 27-year-old man was admitted with a penetrating injury at the mid-manubrium. Computed tomographic (CT) angiography showed a filling defect in the aortic arch. This was evaluated as a sign of injury and the patient underwent an emergency operation. No active bleeding or clot was found in the mediastinum during the operation. The laceration point was between the innominate and the left carotid artery posteriorly. The injury was approached using hypothermic circulatory arrest. Aortotomy and exploration showed a 2-cm-long full-thickness aortic injury with an overlying clot. A filling defect on angiography as a sign of a penetrating arch injury has never been reported previously, but was the main pathological finding on CT angiography in our case. The aorta is a high-pressure system and injuries to it should be treated aggressively.

**Key words:** 1. Aorta, thoracic  
2. Hypothermia  
3. Circulatory arrest deep hypothermia induced  
4. Penetrating trauma

## Case report

Thoracic vascular injuries have long been a challenge for surgeons. Technological improvements such as computed tomography (CT) and magnetic resonance imaging have resulted in less invasive methods of diagnosis. These imaging techniques are changing the outcomes of patients with these potentially fatal injuries. We present a case of a penetrating aortic injury with unusual and inconsistent CT angiography findings.

A 27-year-old male patient presented to the emergency room with a puncture wound from a screwdriver. On examination, the wound entrance could be seen in the mid-manubrium region. On a physical examination, the patient showed no sign of distress: his blood pressure was 120/80 mm Hg, his heart rate was 70 beats per minute, his pulses were equal and normal, and his neurological examination was intact.

Lab results showed no abnormalities, and his haemoglobin was 13 g/dL. On imaging, the chest X-ray suggested a widened mediastinum; his CT angiography findings, however, were inconsistent with a penetrating aortic injury. CT angiography revealed a filling defect of the aortic arch proximal to the left carotid artery (LCA) with no extravasation of contrast (Figs. 1, 2).

A linear fracture of the vertebral body was present on CT, and oesophography excluded oesophageal injury. The decision was made to operate.

The right femoral artery was exposed and a mid-line sternotomy was performed. On exploration, no clot formation or active bleeding was found in the mediastinum. Pericardiotomy revealed insignificant haemorrhagic changes, including ecchymosis and blanching on the left side of the ascending aorta. Heparin was administered and an arterial cannula was inserted into the femoral artery and a venous

Received: October 25, 2016, Revised: March 13, 2017, Accepted: March 14, 2017, Published online: August 5, 2017

Corresponding author: Fikret Sami Vural, Department of Cardiothoracic Surgery, Charlotte Maxeke Johannesburg Academic Hospital, 5 Jubilee Road Parktown Johannesburg RSA, Republic of South Africa  
(Tel) 27-117172765 (Fax) 27-117172765 (E-mail) [fikretsamivural@yahoo.com](mailto:fikretsamivural@yahoo.com)

© The Korean Society for Thoracic and Cardiovascular Surgery. 2017. All right reserved.

© This is an open access article distributed under the terms of the Creative Commons Attribution Non-Commercial License (<http://creativecommons.org/licenses/by-nc/4.0>) which permits unrestricted non-commercial use, distribution, and reproduction in any medium, provided the original work is properly cited.

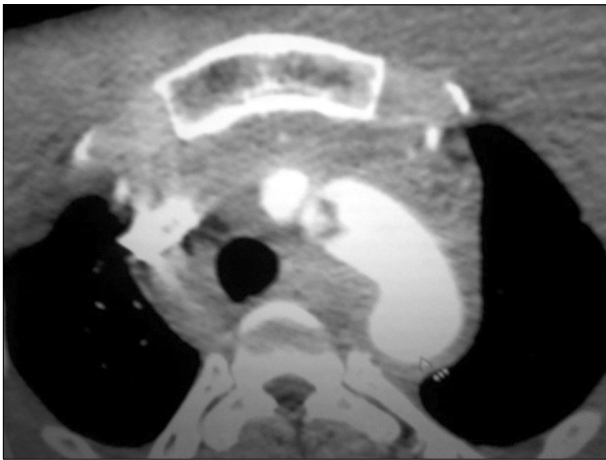


Fig. 1. Filling defect in the arch.

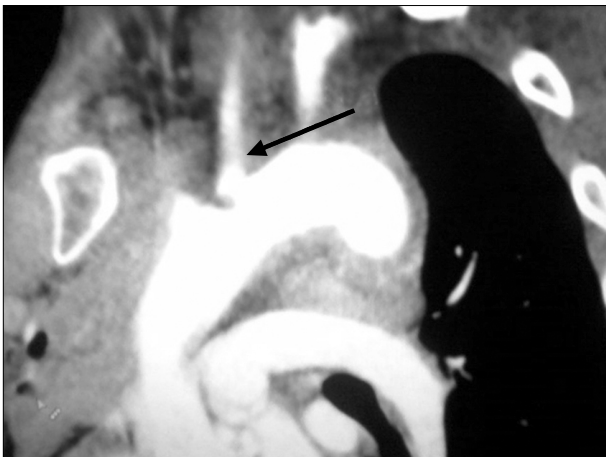


Fig. 2. Filling defect proximal to the LCA (arrow). LCA, left carotid artery.

cannula was inserted via the right atrial appendage. The bypass was commenced and the patient was cooled to 18°C. During cooling, the innominate vein, ascending aorta, and arch were freed from the surrounding tissues. The wound entrance was seen between the innominate and LCA orifices posteriorly. This case was an anomaly, as there was no bleeding. The aorta was cross-clamped 2 cm above the right coronary artery.

A left ventricular vent was inserted via the right superior pulmonary vein, and blood cardioplegia was administered into the aortic root.

Topical cooling was performed, the patient was put in the Trendelenburg position, and the bypass was stopped at 18°C. A 4-cm aortotomy was per-

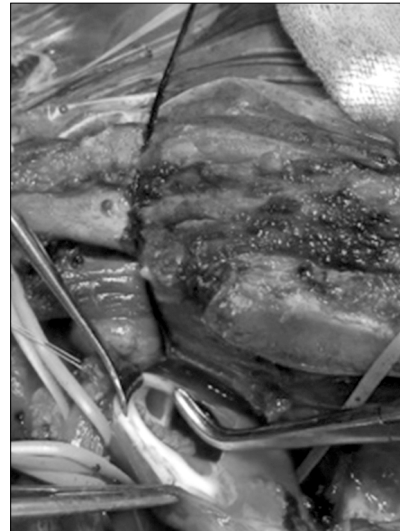


Fig. 3. Clot inside the aorta.

formed 1 cm below the first 2 main head vessels.

On inspection, there was a clot inside the aorta that extended into the LCA orifice. Upon removal of the clot, an aortic laceration approximately 2 cm in length was discovered (Fig. 3). There was a thick piece of adventitia protruding into the aorta. The aortic injury and aortotomy were closed with 4.0 Prolene sutures. The bypass was recommenced prior to aortic closure. Air was cleared from the intravascular bed. The heart started to beat spontaneously at 22°C and the bypass was terminated at 37°C. The bypass time was 108 minutes and the circulatory arrest time was 14 minutes.

The patient was extubated the next morning and discharged on the fifth day postoperatively. At a 6-month follow-up the patient was stable and complication free.

## Discussion

The repair of arch injuries is a major challenge for surgeons. Sternotomy has been recommended for proximal arch injuries and thoracotomy for subclavian and distal injuries [1,2]. In some cases, the external bleeding point was controlled with a finger, and after sternotomy, sudden exsanguinating bleeding was controlled in the same way [1,3,4]. Pate stated that anteriorly located aorta injuries can be repaired with finger control and a partial clamp [1]. Artificial ventricular fibrillation is recommended to control ex-

cessive bleeding and for completing the repair [3]. This type of approach requires dexterity. Neurological outcomes cannot be predicted easily [1].

All authors agree that injuries at the posterior surface of the arch are more challenging and have a poorer prognosis. CPB and hypothermic circulatory arrest represent a safe approach for complex injuries [2-4]. It is also recommended to carry out this type of repair with moderate hypothermia after axillary cannulation [5]. If aortic injuries are not operated on in the acute stage of injury, a pseudoaneurysm may develop, making subsequent repair more difficult [2,3]. These radiological features in a penetrating injury of the aorta have not previously been described. We assume that the patient's adventitia acted as a barrier to exsanguination and also caused clot formation. Such radiological features can be misleading, as most cases of penetrating injury present with either extensive bleeding or pseudoaneurysm formation. In emergency situations, CT angiography is superior to magnetic resonance imaging as a diagnostic modality due to its rapid scan time and wider availability. Following blunt traumatic injuries of the aortic isthmus, CT angiography might show a deformity of the aortic contour, intramural haematoma, intraluminal debris, and an intimal flap that may resemble a filling defect, but active extravasation is rarely seen [6]. Typically in cases of penetrating aortic injuries unlike that observed in our patient the CT angiography findings include extravasation of contrast, pseudoaneurysms, and early venous contrast material filling due to an arteriovenous fistula [7]. The aorta is a high-pressure system, so injuries to the aorta are not amenable for observation, unlike injuries to the venous system. The filling defect of the aortic arch

on CT angiography was due to clot formation over the laceration, and was a sign of the injury. We conclude that in such cases, despite inconsistent imaging findings, exploratory procedures should not be delayed.

### Conflict of interest

No potential conflict of interest relevant to this article was reported.

### References

1. Pate JW, Cole FH Jr, Walker WA, Fabian TC. *Penetrating injuries of the aortic arch and its branches*. Ann Thorac Surg 1993;55:586-92.
2. Peltz M, Douglass DS, Meyer DM, et al. *Hypothermic circulatory arrest for repair of injuries of the thoracic aorta and great vessels*. Interact Cardiovasc Thorac Surg 2006;5:560-5.
3. Seitelberger R, Bialy J, Rajek MA. *Repair of stab-wound laceration of the aortic arch using deep hypothermia and circulatory arrest*. Ann Thorac Surg 2004;77:703-4.
4. Hoffberger JD, Rossi H, Keen R, Savage EB. *Penetrating trauma to the aortic arch: a case report*. J Trauma 2005; 58:381-3.
5. Leshnower BG, Myung RJ, Chen EP. *Aortic arch surgery using moderate hypothermia and unilateral selective antegrade cerebral perfusion*. Ann Cardiothorac Surg 2013; 2:288-95.
6. Cullen EL, Lantz EJ, Johnson CM, Young PM. *Traumatic aortic injury: CT findings, mimics, and therapeutic options*. Cardiovasc Diagn Ther 2014;4:238-44.
7. Fisher RG, Ben-Menachem Y. *Penetrating injuries of the thoracic aorta and brachiocephalic arteries: angiographic findings in 18 cases*. AJR Am J Roentgenol 1987; 149:607-11.