

Original Publication

 OPEN ACCESS

Intravitreal Injection Technique

Kasra A. Rezaei, MD*, Joanne C. Wen, MD

*Corresponding author: kasrarezaei@yahoo.com

Citation: Rezaei KA, Wen JC. Intravitreal injection technique. *MedEdPORTAL*. 2016;12:10502. https://doi.org/10.15766/mep_2374-8265.10502

Copyright: © 2016 Rezaei and Wen. This is an open-access article distributed under the terms of the Creative Commons Attribution-NonCommercial-No Derivatives license.

Abstract

Introduction: Intravitreal injection of therapeutic medications has become one of the most commonly performed procedures in ophthalmology. Over the past decade, a number of guidelines have been published that recommend proper techniques to increase the safety of intravitreal injections. In this course, we teach and practice the skills necessary to perform safe intravitreal injections. **Methods:** The course was developed for first-year ophthalmology residents and was designed to be delivered in one 2-hour session. Associated materials include guidelines for faculty facilitators and residents to prepare them for safe intravitreal injection of therapeutic medications. Also included are a slide presentation, wet-lab practice guidelines, and an evaluation form. **Results:** Learner response has been universally very positive. Residents ($N = 15$) have reported that structured lectures with practice in the wet lab improved their skill for intravitreal injection of therapeutic medication. **Discussion:** Overall, we found that our curriculum improved learner knowledge about safe intravitreal injections and learners' self-assessed confidence in the three objectives of the curriculum.

Keywords

Ophthalmology, Ophthalmologic Surgical Procedures, Intravitreal Injection Technique

Appendices

- A. Intravitreal Injection Technique.docx
- B. PowerPoint Presentation .pptx
- C. Wet-Lab Practice.docx
- D. Evaluation Form.docx

All appendices are peer reviewed as integral parts of the Original Publication.

Educational Objectives

By the end of this module, the learner will be able to:

1. Understand the indications and contraindications for intravitreal injections.
2. Gain proficiency in the technical skills involved in performing intravitreal injections.
3. Accurately explain the steps of intravitreal injections to patients and obtain informed consent.

Introduction

Intravitreal injection of therapeutic agents has become one of the most commonly performed procedures in ophthalmology. Over the past few years, a number of guidelines have been proposed for proper techniques to increase the safety of intravitreal injections.¹⁻⁶ It is important to teach residents the proper skills for this procedure. This course is designed to introduce ophthalmology residents to the skills necessary to perform intravitreal injections. Through didactic lectures, learners are introduced to the clinical indications and contraindications for intravitreal injections (including risks and benefits). Learners become familiar with the steps of intravitreal injections, have the opportunity to practice in wet lab, and finally observe and perform intravitreal injections on patients in the retina clinic.

Methods

The target audience for this module includes first-year ophthalmology residents, but second- and third-year residents and fellows may also benefit. The module assumes that learners have basic knowledge of ocular anatomy. The curriculum is held over a 2-hour period, which includes both the pre- and posttest, lecture, and skills practice session. This course is held annually at the beginning of the academic year at our institution.

Instructors should review the instructor guide (Appendix A) prior to the session to ensure adequate understanding of and familiarity with the material. Teaching points to accompany the lecture slides

(Appendix B) are provided within the instructor guide. Sufficient numbers of pre- and posttests (Appendix D) should be printed for the class. Instructors should make sure they have the required materials for the wet-lab session (Appendix C).

The session starts with a pretest followed by a didactic lecture on safe intravitreal injection of therapeutic medication.

The topics of the didactic lecture include the common indications for intravitreal injections, common intravitreal medications, general considerations, guidelines for intravitreal injections, and injection protocols. After completing the lecture, the instructor and the audience go to the wet lab to practice the basic steps of intravitreal injection of therapeutic medication in pig eyes. At the end, the instructor evaluates the intravitreal injection technique in the wet lab and administers the posttest.

The appropriate sequences of steps are as follows:

1. Either a surgical mask should be used or providers should minimize speaking during the injection preparation and procedure.
2. Take a procedural time-out to verify patient, agent, and laterality.
3. Apply two or three sets of topical anesthetic drops or gel to the ocular surface or perform a subconjunctival injection of anesthetic.
4. Apply povidone-iodine (5%) to the ocular surface to remove the gel from the ocular surface.
5. (Optional!) Mark the location of injection: 3.5 mm posterior to the limbus for pseudophakic and 4.0 mm posterior to the limbus for phakic patients. The hub of a tuberculin syringe (without needle attached) can be used to mark 3.5-4.0 mm, or calipers can be used to mark the injection site. Then, apply povidone-iodine (5%) to the conjunctival surface, including the intended injection site, and wait for at least 30-60 seconds before injection.
6. Insert the needle perpendicular to the sclera, 3.5 to 4.0 mm posterior to the limbus (depending on the status of the lens), between the vertical and horizontal rectus muscles.
7. Rinse the injection site with copious balanced salt solution.

After practicing in the wet lab, the residents have the option to observe the instructor performing intravitreal injection on an actual patient (about 20 minutes). Then, the residents get the opportunity to perform safe intravitreal injection under direct supervision and assistance of the instructor (about 10 minutes per patient).

The residents should complete the pretest and posttest, while the evaluation form should be completed by the instructor as follows:

1. Evaluation of the intravitreal injection technique in the wet lab.
2. Five evaluations after first five intravitreal injections.
3. One evaluation after 20 intravitreal injections.
4. Final evaluation after 40 intravitreal injections.

Results

The use of intravitreal injection as a means of delivering intraocular therapeutics has grown dramatically over the past decade, and it is important all ophthalmology residents feel comfortable with this technique. There are five residents per class, for a total of 15 ophthalmology residents per year, at the University of Washington. Since its introduction in 2016, the course has been rated very useful for learning and practicing intravitreal injections.

We surveyed our first-year residents by mid-academic year before and after the course and practice in the wet lab and had them rate their experience on a scale of 1-10 (1 = *not at all confident*, 10 = *totally confident*) with the following questions:

1. How confident are you in explaining the risks of intravitreal injection to the patient?
2. How confident are you in preparing the patient for an intravitreal injection?
3. How confident are you in performing the intravitreal injection?

The Figure shows the results of the survey.

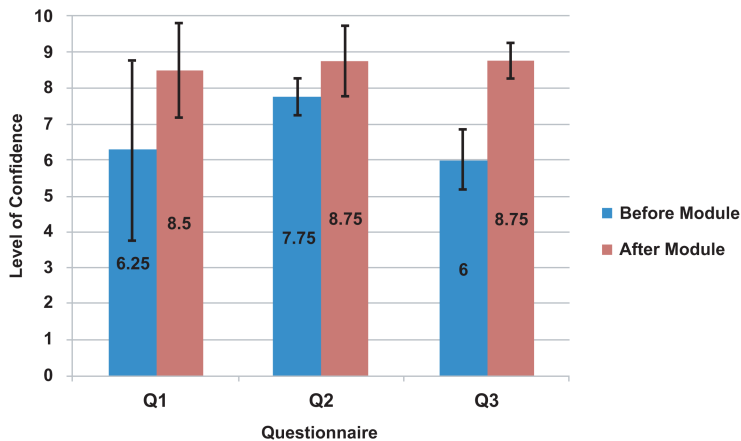


Figure. Growth of learner confidence after module completion. Q1: How confident are you in explaining the risks of intravitreal injection to the patient? Q2: How confident are you in preparing the patient for an intravitreal injection? Q3: How confident are you in performing the intravitreal injection?

Our results show that the instructional courses with practice in the wet lab significantly increased resident confidence in performing the intravitreal injection (2.75 ± 1.50 , $p = .01$). Also, resident confidence in preparing the patient for intravitreal injection improved after the wet lab ($p = .092$), and confidence in explaining the risk of intravitreal injection to the patient improved after the course (2.25 ± 1.50 , $p = .058$).

Residents commented that having the structured lecture at the beginning of the first year of residency familiarized them with clinical indications and contraindications for intravitreal injections, as well as with the steps of intravitreal injections, and that practicing the basic steps of intravitreal injections in the wet lab improved their skills before performing the procedure on actual patients.

Qualitative feedback on the course included the following comments:

- “I believe that the wet-lab was very useful. We received a lecture with valuable information that we had not formally learned. I think it is nice to have standardized teaching on intravitreal injections and to be able to practice on pig eyes. Even for those who have done multiple injections, it was a safe environment to practice. We also got individual instruction and feedback from the instructors.”
- “I thought that this wet-lab was excellent. This should be repeated every year as it gives everyone a basis . . . to work with and a foundation upon [which] adjustments can be made if another provider prefers a slightly different technique.”
- “The PowerPoint is quite thorough and helpful, and . . . being able to practice once or twice on the model would be very helpful for the first-year residents.”
- “Wet-lab was extremely helpful in breaking down each step of the process and highlighting the most important steps. Very important for efficient clinical functioning.”
- “The PowerPoint presentation has great information regarding the indications and special considerations to consider, as well as a helpful collection of injectable medications to keep as a reference sheet. The lab-based portion was helpful to review the best techniques for injection. Overall, this is probably most helpful for the first years, but also a good review for other classes as well.”

Discussion

Intravitreal injection of therapeutic medications has become one of the most commonly performed procedures in ophthalmology. Our first-year residents did not feel comfortable performing intravitreal injections towards the end of their first year of residency. Structural training has been shown to improve procedural skills and patient safety. Participating in a didactic lecture on intravitreal injection technique, practicing in the wet lab, and observing and performing intravitreal injections under direct supervision of the attending may improve the skills of intravitreal injections performed by residents and decrease the risk of complications.

From the feedback we have received from the first-year residents, the structural lecture followed by practicing the steps of intravitreal injection in the wet lab would be optimal. Ideally, each resident would perform multiple injections in the wet lab prior to observing and practicing the safe intravitreal injection on real patients.

Overall, we found that our curriculum improved learner knowledge about safe intravitreal injections and learners' self-assessed confidence in the three objectives of the curriculum. While pig eyes were selected as cost-effective ways to help facilitate learning skills involved with intravitreal injections, other models such as tomatoes also can be used to practice. Models for ophthalmic procedure simulation are in constant development, so in the future, this curriculum may be modified should an improved, cost-effective laser model be found.

Given the unanimous feedback from our learners, we feel that this course is valuable in improving learner knowledge and confidence in performing intravitreal injections. We plan on continuing to hold this training session every year with an emphasis on ensuring participation from the newest residents and encouraging more senior residents to consider refresher course participation.

Kasra A. Rezaei, MD: Assistant Professor of Ophthalmology, University of Washington School of Medicine

Joanne C. Wen, MD: Assistant Professor of Ophthalmology, University of Washington School of Medicine

Disclosures

None to report.

Funding/Support

None to report.

Ethical Approval

Reported as not applicable.

References

1. Avery RL, Bakri SJ, Blumenkranz MS, et al. Intravitreal injection technique and monitoring: updated guidelines of an expert panel. *Retina*. 2014;34(suppl 12):S1-S18. <http://dx.doi.org/10.1097/IAE.0000000000000399>
 2. Blaha GR, Tilton EP, Barouch FC, Marx JL. Randomized trial of anesthetic methods for intravitreal injections. *Retina*. 2011;31(3):535-539. <http://dx.doi.org/10.1097/IAE.0b013e3181eac724>
 3. Rao RR, Javey G, Rosenfeld PJ, Feuer WJ. Elimination of post-injection topical antibiotics after intravitreal injections [ARVO abstract]. *Invest Ophthalmol Vis Sci*. 2011;52(14):5608.
 4. Kim SJ, Toma HS. Ophthalmic antibiotics and antimicrobial resistance: a randomized, controlled study of patients undergoing intravitreal injections. *Ophthalmology*. 2011;118(7):1358-1363. <http://dx.doi.org/10.1016/j.ophtha.2010.12.014>
 5. Federici TJ. Intravitreal injections. *Focal Points*. 2009;28(8).
 6. Lai TY, Liu S, Das S, Lam DS. Intravitreal injection—technique and safety. *Asia Pac J Ophthalmol (Phila)*. 2015;4(6):321-328. <http://dx.doi.org/10.1097/APO.0000000000000146>
-

Received: June 2, 2016 | **Accepted:** November 1, 2016 | **Published:** November 18, 2016