



Tomographic Analysis of the Anatomical Parameters for the Insertion of Cortical Bone Screws*

Análise tomográfica dos parâmetros anatômicos para inserção dos parafusos de trajeto cortical

Carlos Fernando Pereira da Silva Herrero¹ Rafael Campos Fróes Marangoni¹

¹ Department of Orthopedic and Anesthesiology, Faculdade de Medicina de Ribeirão Preto, Universidade de São Paulo, Ribeirão Preto, São Paulo, SP, Brazil

Address for correspondence Rafael Campos Fróes Marangoni, MD, Rua Padre Diogo Feijó, 101, Taubaté, SP, Brazil, CEP 12030-160 (e-mail: rafaelfmarangoni@gmail.com).

Rev Bras Ortop 2022;57(1):47–54.

Abstract

Objective To study the parameters related to the insertion path of cortical screws and to describe this technique.

Methods Computed tomography (CT) scans of 30 patients, as well as the measurements from the L1 to the L5 vertebrae, were studied. A second observer evaluated ten randomly-selected exams. The parameters studied included the lateral angle (LA) and the screw diameter (SD) as axial variables, and the cranial angle (CA) and screw length (SL) as sagittal variables.

Results We studied 15 male patients (mean age: 31.33 years) and 15 female patients (mean age: 32.01 years). The LA varied between 13.8° and 20.89°, with a tendency to increase in the proximal to distal direction. The CA varied from 17.5° to 24.9°, with a tendency to decrease in the caudal direction. The SD ranged from 2.3 mm to 7.2 mm, with a tendency to increase as we progressed from proximal to distal. The SL varied from 19 mm to 45 mm, with a tendency to decrease as we proceeded from proximal (L1) to distal (L5). No statistical difference was observed between the genders or in the interobserver agreement regarding the values studied when comparing the sides.

Conclusion The path of insertion of the cortical screw shows a variation in different populations. Therefore, we recommend a preoperative imaging study to reduce the surgical risks related to the technique.

Keywords

- ▶ spine
- ▶ minimally invasive surgical procedures
- ▶ bone screws

* Study developed at Hospital das Clínicas de Ribeirão Preto, Faculdade de Medicina de Ribeirão Preto, Universidade de São Paulo, Ribeirão Preto, São Paulo, SP, Brazil.

received
July 27, 2020
accepted after revision
February 11, 2021

DOI <https://doi.org/10.1055/s-0041-1731672>.
ISSN 0102-3616.

© 2022. Sociedade Brasileira de Ortopedia e Traumatologia. All rights reserved.
This is an open access article published by Thieme under the terms of the Creative Commons Attribution-NonDerivative-NonCommercial-License, permitting copying and reproduction so long as the original work is given appropriate credit. Contents may not be used for commercial purposes, or adapted, remixed, transformed or built upon. (<https://creativecommons.org/licenses/by-nc-nd/4.0/>)
Thieme Revinter Publicações Ltda., Rua do Matoso 170, Rio de Janeiro, RJ, CEP 20270-135, Brazil

Resumo

Objetivo Estudar os parâmetros anatômicos do trajeto de inserção do parafuso cortical e descrever sua técnica.

Métodos Analisaram-se exames de tomografia computadorizada de 30 pacientes, e as medidas nas vértebras de L1 a L5 bilateralmente. Um segundo observador avaliou dez exames aleatoriamente. Os parâmetros incluíram o ângulo lateral (AL) e o diâmetro do parafuso (DP) como variáveis axiais, e o ângulo cranial (AC) e o comprimento do parafuso (CP) como variáveis sagitais.

Resultados No total, havia 15 pacientes do sexo masculino (média de idade de 31,33 anos) e 15 do sexo feminino (média de idade de 32,01 anos). O AL variou de 13,8° a 20,89°, com uma tendência de aumento no sentido de proximal a distal. O AC variou de 17,5° a 24,9°, com tendência de diminuição no sentido caudal. O DP variou de 2,3 mm a 7,2 mm, havendo uma tendência ao aumento conforme avançamos de proximal a distal. O CP variou de 19 mm a 45 mm, havendo uma tendência de diminuição conforme avançamos de proximal (L1) a distal (L5). Não houve diferença estatística entre os sexos, nem diferenças na confiabilidade interobservador, quanto aos valores estudados quando comparados os lados.

Conclusão A trajetória do parafuso de trajeto cortical apresenta variações em diferentes populações. Assim, recomendamos o estudo pré-operatório de imagens para reduzir os riscos cirúrgicos relacionados à técnica.

Palavras-chave

- ▶ coluna vertebral
- ▶ procedimentos cirúrgicos minimamente invasivos
- ▶ parafusos ósseos

Introduction

Posterior fixation of the lumbar spine is the treatment of choice for several spinal conditions. Numerous devices can be used in the treatment, including wiring, hooks, pedicle screws (PSs) and, more recently, cortical screws (CSs).^{1,2}

Currently, most fixation procedures use pedicle screw systems, which are based on implant anchoring at the cancellous bone of the pedicles and vertebral bodies. This fixation technique may be subject to failure, especially in subjects with osteoporosis.^{1,2}

In 2009, Santoni et al.¹⁷ introduced a method for the insertion of PSs known as the cortical bone trajectory. In this technique, screw insertion follows a distal-to-proximal path in a medial-to-lateral direction, increasing the contact with the cortical bone of the pedicle and vertebral body in comparison to the traditional fixation method using PSs.³⁻⁶ Biomechanical studies revealed that the outcomes of the technique with PSs are equivalent or superior compared to those of the traditional method.⁷⁻⁹

Even though the anatomy of the cortical bone trajectory has been documented in European and Asian populations,¹⁰⁻¹² its anatomical parameters may vary regarding different populations. Our hypothesis was that the morphometric parameters of the cortical bone trajectory in the Brazilian population differ from the data previously reported in the literature; in addition, the techniques used may lead to errors in interpretation. Thus, the present study aimed to describe a technique to measure the trajectory of the PS, with a detailed assessment of its entry point, trajectory and dimensions using computed tomography (CT) in a sample from the Brazilian population.

Material and Methods

The study protocol was approved by the institutional Ethics in Research Committee. The study included 15 male (average age: 31.33 ± 8.5 years) and 15 female patients (average age: 32.01 ± 6.1 years). We randomly selected CT scan images from a database to perform a retrospective evaluation. Scans from patients aged 18 to 45 years were included. Patients with history of previous spinal surgery, evidence of advanced spinal degenerative disease, and spinal traumatic injuries, infection, or neoplastic disease were excluded from the study based on radiological reports and subsequent review by the evaluator.

All CT scans were performed using the same equipment, Big Bore 16 Slice CT (Philips Healthcare, Cleveland, OH, US), following the standard institutional protocol. Reconstruction of axial, sagittal, and coronal images from the CT scans with a 1-mm thickness were available for each vertebra. Images from the first lumbar vertebra (L1) to the fifth lumbar vertebra (L5) were selected.

The axial parameters included the lateral angle (LA), that is, the angle between the trajectory of the screw and the sagittal plane, and the maximum screw diameter (SD), that is, the longest distance between two lines parallel to the trajectory and tangent to the pedicular cortices. The sagittal parameters included the cranial angle (CA), that is, the angle between the trajectory of the screw and the upper terminal plate, and the screw length (SL), that is, the distance between the entry point and the lateral cortex of the vertebra. The linear parameters were measured in millimeters, whereas the angular parameters were estimated in degrees.

Two observers performed the measurements independently using the OsiriX (Pixmeo SARL, Bernex, Switzerland)

image analysis software. The first evaluator analyzed the scans from all of the 30 patients, whereas the second evaluator analyzed scans from 10 patients randomly selected from the first 30 subjects to estimate the interobserver reliability.

The challenge of translating diagnostic imaging data into surgically-useful information lies in the difficulty to describe three-dimensional structures, such as the trajectory of the cortical screw, in two dimensions. Multiplanar (axial, sagittal, and coronal) CT scans were evaluated simultaneously to measure all the parameters and generate clinically-applicable data.

Imaging Analysis

The first stage to assess the trajectory of the cortical screw involved the alignment of the horizontal axis (dotted line) on sagittal and coronal images with the upper terminal plate, and alignment of the vertical axis (full line) on the axial

image with the central sagittal axis of the vertebra. Next, the center of the pedicle was located, and a fixed demarcation point (fixed point 1–black dot) was inserted in all three planes (► **Figure 1**).

The entry point was determined on a coronal image, which cuts the isthmus of the pedicles, and the axes were displaced so that the vertical axis (full line) touched the medial cortex of the pedicle and the horizontal axis (dotted line) was over the inferior cortex of the pedicle. A fixed point was marked in the axial image at projection of the vertical axis (full line) from the posterior cortex of the blade (► **Figure 2**–fixed point 2–white dot).

Next, the center of the axis was repositioned at the fixed point 1, in the center of the pedicle, and, on the coronal image, the horizontal axis (dotted line) was moved to the lower cortex of the pedicle (► **Figure 3**). On the axial image, the axis was then rotated so that the vertical axis (full line) met fixed point 2. Thus, sections of the sagittal image were

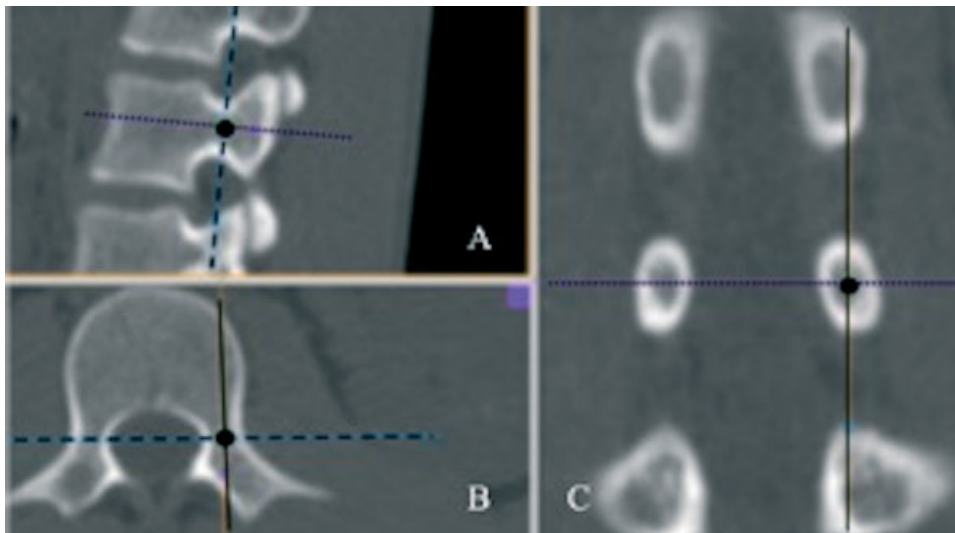


Fig. 1 Sagittal (A), axial (B), and coronal (C) computed tomography images showing the demarcation of fixed point 1.

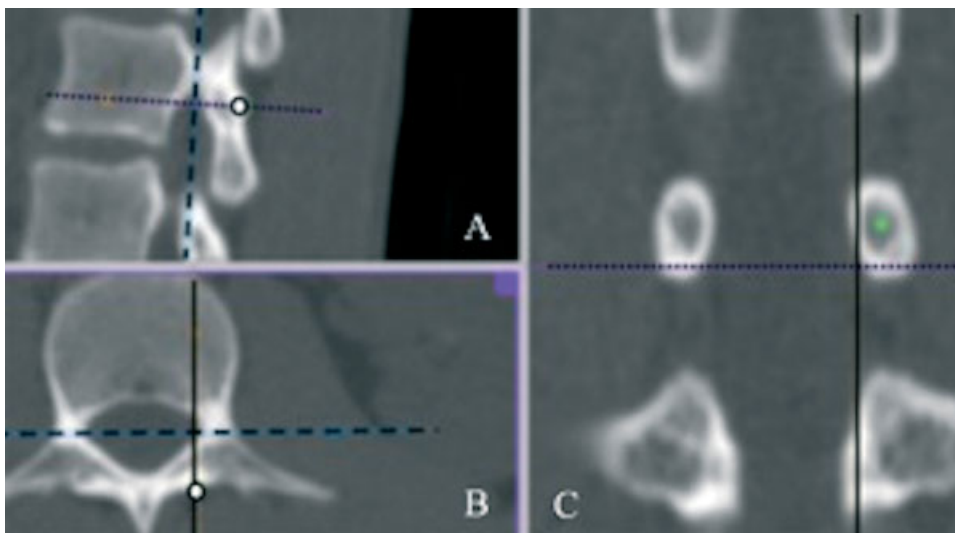


Fig. 2 Sagittal (A), axial (B), and coronal (C) computed tomography images showing the demarcation of fixed point 2.

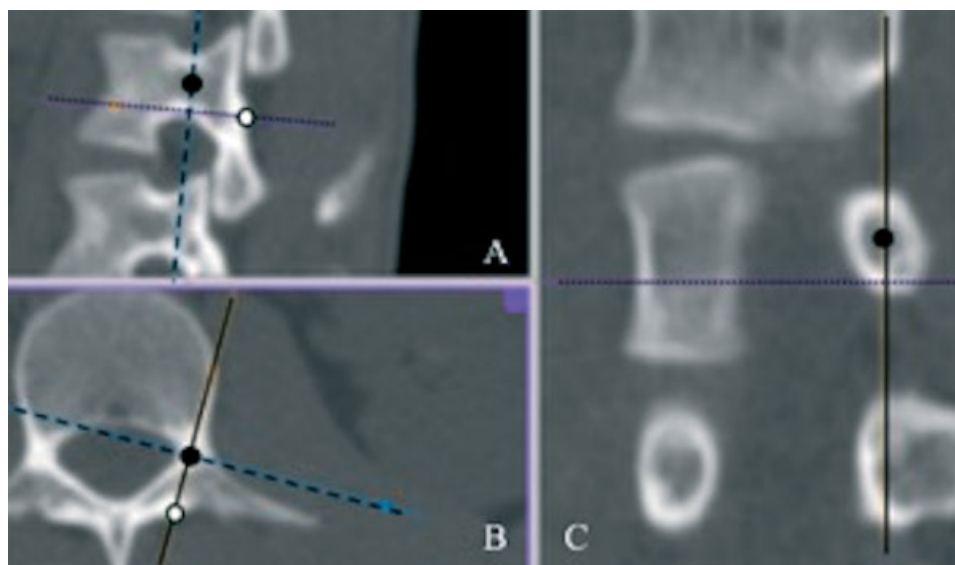


Fig. 3 Sagittal (A), axial (B), and coronal (C) computed tomography images showing the lateral trajectory of the screw.

generated on the axis of the trajectory of the screw, enabling its correct measurement. The trajectory of the screw in the axial plane was determined by a straight line joining fixed points 1 (center of the axis on an axial image) and 2 (► **Figures 3** and **4**).

The LA was measured on an axial image. The vertebral sagittal line, formed by the union of the axis of the spinous process and the lateral-lateral midpoint of the vertebral canal, was determined, and then the angle formed by the trajectory of the screw and this line was measured (► **Figure 4**).

The SL and the CA were measured on a sagittal section that passes through the screw axis. In this section, a straight line between fixed points 1 and 2, starting at the fixed point 1 and ending at the opposite cortex, determined the maximum SL. The CA was measured between a straight line on the upper

end plate and the trajectory of the screw on the inclined sagittal section (► **Figure 5**).

Lastly, to determine the SD, the axes on a sagittal section were found at the fixed point 1, and the horizontal axis was tilted until it equated with the drawn screw trajectory. The SD was determined as the distance between two straight lines parallel to the path, which touched the medial cortex and the lateral cortex of the pedicle (► **Figure 6**).

Statistical Analysis

In total, 300 lumbar vertebral pedicles from L1 to L5 were evaluated. The mean and standard deviation values of the linear and angular parameters were calculated separately at each level and for the female and male patients. The values

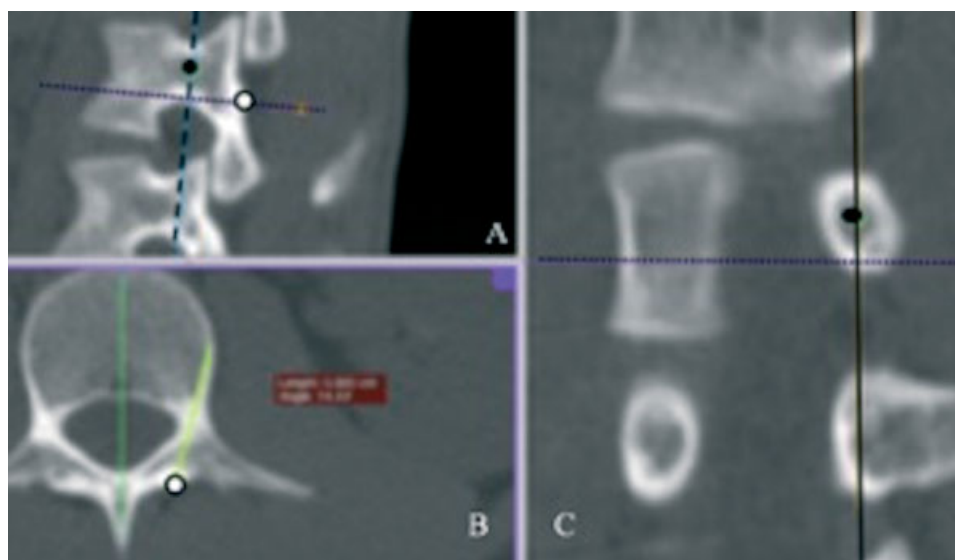

Fig. 4 Sagittal (A), axial (B), and coronal (C) computed tomography images showing the lateral angle evaluation.

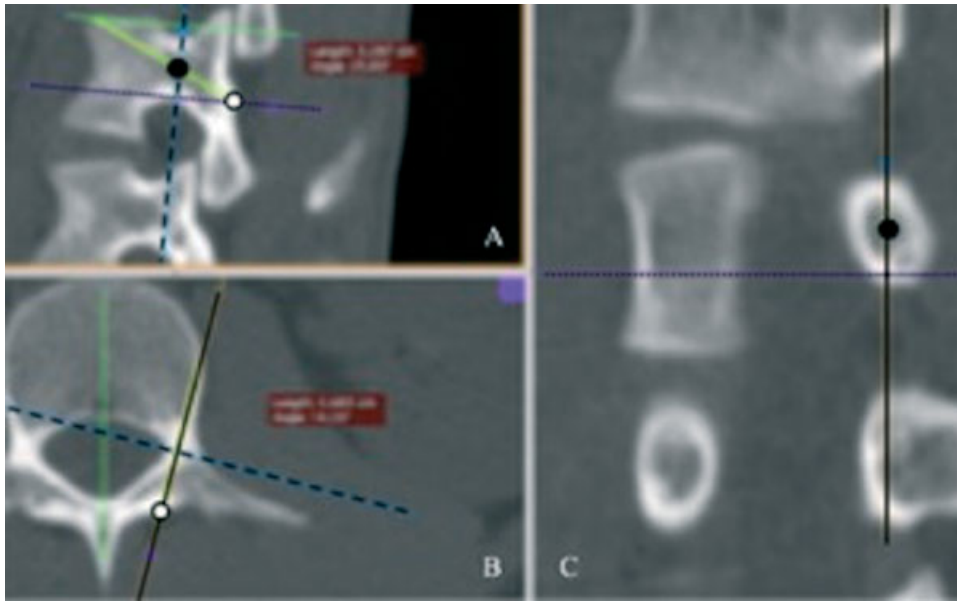


Fig. 5 Sagittal (A), axial (B), and coronal (C) computed tomography images evaluating the length of the trajectory of the cortical screw and the cranial angle.

were compared with those of the Student *t*-test after we performed a Shapiro-Wilk normality test.

Interobserver reliability was estimated using the Spearman test. A coefficient ranging from 0 to 0.21 indicated poor reliability; from 0.21 to 0.40, weak reliability; from 0.41 to 0.60, moderate reliability; from 0.61 to 0.80, good reliability; and from 0.81 to 1.0, very good reliability. Statistical signifi-

cance was set at values of $p < 0.05$ for all parameters. The statistical analysis was performed using the Stata (Statacorp, College Station, TX, US) software, version 14.1.

Results

Sagittal Parameters

Overall, the SL ranged from 19 mm to 45 mm. The mean SL was lowest at the level of L5 on the right side, of 2.65 cm among the female patients, and highest at the level of L2 on the right side, of 3.36 cm among the male patients. The SL values tended towards a decrease when moving from proximal (L1) to distal (L5) (► **Figure 7**). However, there was no statistical difference in SL values regarding the pedicles from both sides and both genders.

The mean CA ranged from 17.2° to 25.3°, and it was lowest at the level of L5 level and highest at the level of L1. There was no statistical differences regarding both genders or the right and left sides; in addition, the CA tended towards a decrease when moving from proximal (L1) to distal (L5) (► **Figure 8**).

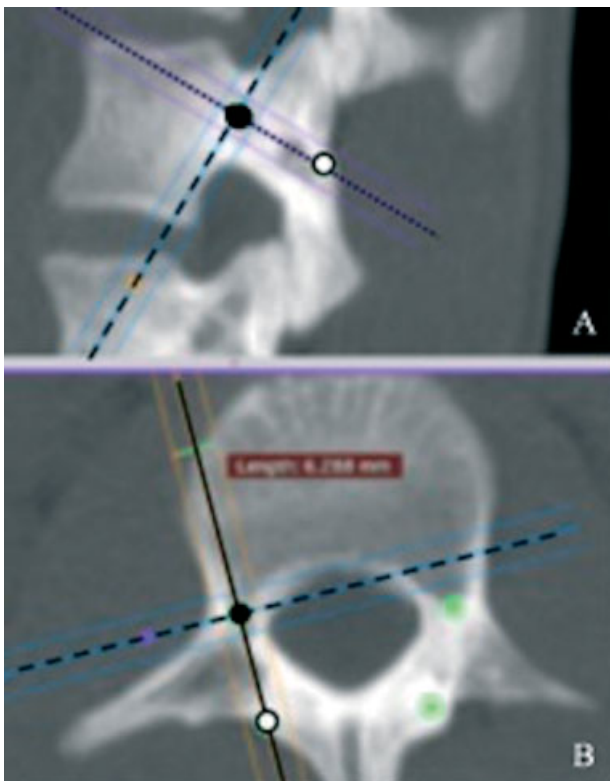


Fig. 6 Sagittal (A), and axial (B) computed tomography images showing the calculation of the screw diameter.

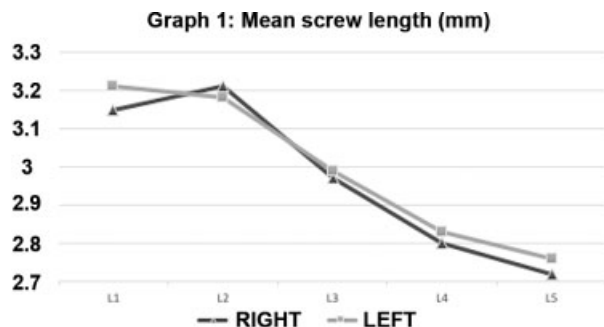


Fig. 7 Mean screw length per level.

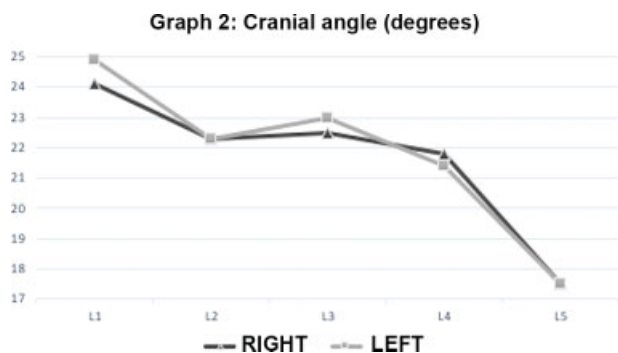


Fig. 8 Mean cranial angle (degrees) per level.

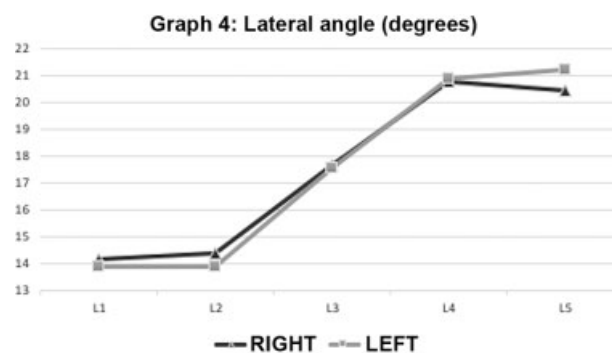


Fig. 10 Mean lateral angle (degrees) per level.

Axial Parameters

The general SD ranged from 2.3 mm to 7.2 mm. The mean SD was lowest at the level of L2 on the right side of female patients, of 4.14 mm, and highest at the level of L5 level on the right side of male patients, of 6.1 mm. The SD tended towards an increase when moving from proximal to distal (►Figure 9). No statistical differences were found when comparing SD values from different sides or genders.

The mean LA ranged from 12.8° to 22.0°, and it was lowest at the level of L1 level on the left side of female subjects, and highest at the level of L4 on the right side of male patients. There were no statistical differences regarding values from different genders or sides. The LA values tended towards an increase when moving from proximal to distal (►Figure 10).

►Table 1 summarizes parameters measured among patients of both genders per level of the lumbar spine.

Interobserver reliability

No differences were observed in terms of interobserver reliability using the Spearman test when comparing the sagittal and axial data found by both observers, with a moderate reliability.

Discussion

Cortical bone trajectory with the use of CSs is a new technique for lumbar spine instrumentation.³ Its caudal-cranial and medial-lateral path is expected to result in a greater fixation force, particularly in patients with osteoporotic bone and elderly subjects, as it is based on a greater

screw contact with dense cortical bone.⁴⁻⁶ As far as we known, this is the first time that the dimensions of the cortical bone trajectory are analyzed per gender and spinal level in a sample of the Brazilian population and.

This fixation has been shown to be promising, increasing the pullout strength by 30%, and the screw strength and in vivo insertion torque by 1.7-fold when compared to the fixation with PSs.^{3,7} Matsukawa et al.⁸ performed a finite-element analysis revealing that the fixation force per individual screw is greater with CSs compared to PSs. In addition, CSs present adequate stiffness for the flexion-extension test in an assembly of paired vertebrae, even though the assembly with PSs is superior when the lateral flexion and axial rotation are evaluated. On the other hand, Baluch et al.⁹ found that The CS has a greater resistance to the fatigue loss test when compared to the PS.

In addition to improved biomechanics, this technique requires less soft-tissue dissection due to its medial-lateral path. With a minimally-invasive approach, atrophy of the multifidus muscle and necrosis are reduced,^{13,14} diminishing the postoperative low-back pain, and resulting in an earlier rehabilitation.

A meta-analysis conducted by Hu et al.¹⁵ showed that the CS is associated with a lower amount of blood loss, shorter hospital stays, lower incidence of disease at the adjacent level, and shorter incision length compared to the PS. However, there is no statistical difference regarding both techniques in terms of clinical evaluation protocols, perioperative complication rates, or surgical time. Still, Sakaura et al.¹⁶ reported good outcomes during the follow-up of spondylolisthesis patients treated with minimally-invasive arthrodesis, although no statistical superiority of this technique was demonstrated when compared with the fixation with PSs. The fixation with CSs can present an advantage in obese patients, because the deep fatty tissue of the lumbar region makes PTP insertion a challenge.^{15,17}

The CS proved to be advantageous because it does not violate the pedicular medial or lateral cortices when compared to the PS, sparing neural structures; nevertheless, complications have been reported, especially at the beginning of the learning curve of the technique.¹⁸ Other potential complications include early implant loosening, infection, fracture of the pars interarticularis or of the pedicle, and nerve-root damage. A disadvantage of the CS is the limited

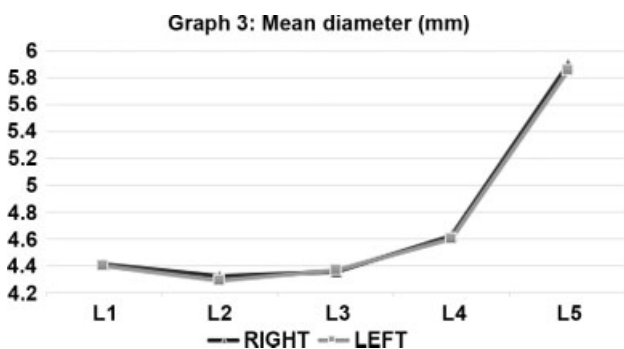


Fig. 9 Mean screw diameter (mm) per level.

Table 1 Mean parameters of the sample per level

	Mean screw length (cm)	Mean screw diameter (mm)	Mean lateral angle (°)	Mean cranial angle (°)
L1	3.18 ± 0.55	4.4 ± 0.77	14.04 ± 3.28	24.53 ± 3.59
L2	3.19 ± 0.37	4.30 ± 0.68	14.13 ± 2.88	22.54 ± 3.16
L3	2.98 ± 0.46	4.36 ± 0.81	17.64 ± 3.25	22.76 ± 3.34
L4	2.81 ± 0.38	4.61 ± 0.56	20.84 ± 3.76	21.6 ± 3.47
L5	2.74 ± 0.29	5.88 ± 0.64	20.82 ± 3,98	17.52 ± 3.0

ability to make hybrid assemblies because its heads are not in line with the PS, making the placement of the stem difficult.^{18,19}

Although this technique has gained some popularity in recent years, there are few studies evaluating the morphology of the trajectory and the suitable sizes of the implants for different populations, aiming at safer surgeries with a lower complication rate.¹⁰⁻¹² The first large study with a CT-based morphometric analysis was performed by Matsukawa et al.¹⁰ in a sample of the Japanese population, and it helped to develop the technique currently used. Next, Zhang et al.¹¹ and Senoglu et al.¹² conducted CT-based anatomical studies in China and Turkey respectively. Although their results are similar, they present important differences which, when not considered during surgery, can lead to complications.

Matsukawa et al.¹⁰ reported mean SL values of 3.68 cm to 3.98 cm; Zhan et al.,¹¹ 2.79 cm to 2.9 cm; and Senoglu et al.,¹² 2.70 cm to 4.0 cm, depending on the measurement standard used; in the present study, the mean SL ranged from 2.72 cm to 3.11 cm, which is consistent with previous data. In our sample, the SD showed a wide range of values. The mean SD values reported in the literature were of: 6.2 mm to 8.4 mm by Matsukawa et al.;¹⁰ 7.8 mm to 10.4 mm by Zhang et al.;¹¹ and 4.5 mm to 5.0 mm by Senoglu et al.,¹² while our results ranged from 4.3 mm to 5.9 mm. The CA values differed in these studies, with reports ranging from 25.5° to 26.2° by Matsukawa et al.,¹⁰ 22.9° to 26.7° by Zhang et al.,¹¹ and 31° to 48° by Senoglu et al.;¹² our measurements ranged from 17.5° to 24.9°.

Such differences can be justified by the heterogeneity of the populations, and the predominance of men (90%) in the first study, which was carried out in a military population; in addition, the three previous studies used different measurement protocols. These measurements were performed at the sagittal and axial planes in an anatomical position; however, the screw is not inserted at the anatomical axis of the vertebra, but tilted to the side. Thus, this form of measurement may distort the results, especially those of the SL.

Our measurement technique considers the ideal trajectory of the screw, changing the sagittal section axis to match it. As such, our measurements were accurate.

Screws with increased length and diameter can violate the lateral and medial cortices of the pedicle, which can put nerve structures at risk and result in pars fracture and vertebral-disc invasion.¹⁸ Thus, a radiological evaluation prior to a CS implant is critical.

Although our findings did not reveal any statistical difference regarding both genders, higher mean values were observed among male patients, potentially due to the relatively small sample size. This is a limitation of our study. However, it is the first study to encompass a sample of the Brazilian population, with a high level of miscegenation, and to describe a detailed technique for the exact measurement of screw dimensions, respecting the screw axis and its LA and CA.

Our measurement method proved to be effective, with good interobserver reproducibility. Further studies are required to validate the intraoperative measurements, comparing them with digital data.

Conclusion

The cortical bone trajectory presents a variation in morphometric features due to the anatomical insertion path in different lumbar vertebrae, with no statistical difference regarding gender among the sample of the present study. Thus, we recommend a detailed preoperative imaging study to reduce technique-related surgical risks.

Financial Support

There was no financial support from public, commercial, or non-profit sources.

Conflict of Interests

The authors have no conflict of interests to declare.

References

- Cook SD, Barbera J, Rubi M, Salkeld SL, Whitecloud TS 3rd. Lumbo-sacral fixation using expandable pedicle screws. an alternative in reoperation and osteoporosis. *Spine J* 2001;1(02):109-114
- Mobbs RJ. The "medio-latero-superior trajectory technique": an alternative cortical trajectory for pedicle fixation. *Orthop Surg* 2013;5(01):56-59
- Phan K, Ramachandran V, Tran TM, et al. Systematic review of cortical bone trajectory versus pedicle screw techniques for lumbosacral spine fusion. *J Spine Surg* 2017;3(04):679-688
- Kojima K, Asamoto S, Kobayashi Y, Ishikawa M, Fukui Y. Cortical bone trajectory and traditional trajectory—a radiological evaluation of screw-bone contact. *Acta Neurochir (Wien)* 2015;157(07): 1173-1178
- Mai HT, Mitchell SM, Hashmi SZ, Jenkins TJ, Patel AA, Hsu WK. Differences in bone mineral density of fixation points between lumbar cortical and traditional pedicle screws. *Spine J* 2016;16 (07):835-841

- 6 Zhang R, Gao H, Li H, et al. Differences in bone mineral density of trajectory between lumbar cortical and traditional pedicle screws. *J Orthop Surg Res* 2019;14(01):128–135
- 7 Matsukawa K, Yato Y, Kato T, Imabayashi H, Asazuma T, Nemoto K. In vivo analysis of insertional torque during pedicle screwing using cortical bone trajectory technique. *Spine (Phila Pa 1976)* 2014;39(04):E240–E245
- 8 Matsukawa K, Yato Y, Imabayashi H, Hosogane N, Asazuma T, Nemoto K. Biomechanical evaluation of the fixation strength of lumbar pedicle screws using cortical bone trajectory: a finite element study. *J Neurosurg Spine* 2015;23(04):471–478
- 9 Baluch DA, Patel AA, Lullo B, et al. Effect of physiological loads on cortical and traditional pedicle screw fixation. *Spine (Phila Pa 1976)* 2014;39(22):E1297–E1302
- 10 Matsukawa K, Yato Y, Nemoto O, Imabayashi H, Asazuma T, Nemoto K. Morphometric measurement of cortical bone trajectory for lumbar pedicle screw insertion using computed tomography. *J Spinal Disord Tech* 2013;26(06):E248–E253
- 11 Zhang H, Ajiboye RM, Shamie AN, Wu Q, Chen Q, Chen W. Morphometric measurement of the lumbosacral spine for minimally invasive cortical bone trajectory implant using computed tomography. *Eur Spine J* 2016;25(03):870–876
- 12 Senoglu M, Karadag A, Kinali B, Bozkurt B, Middlebrooks EH, Grande AW. Cortical Bone Trajectory Screw for Lumbar Fixation: A Quantitative Anatomic and Morphometric Evaluation. *World Neurosurg* 2017;103:694–701
- 13 Hung CW, Wu MF, Hong RT, Weng MJ, Yu GF, Kao CH. Comparison of multifidus muscle atrophy after posterior lumbar interbody fusion with conventional and cortical bone trajectory. *Clin Neurol Neurosurg* 2016;145:41–45
- 14 Chen YR, Deb S, Pham L, Singh H. Minimally Invasive Lumbar Pedicle Screw Fixation Using Cortical Bone Trajectory - A Prospective Cohort Study on Postoperative Pain Outcomes. *Cureus* 2016;8(07):e714–e726
- 15 Hu JN, Yang XF, Li CM, Li XX, Ding YZ. Comparison of cortical bone trajectory versus pedicle screw techniques in lumbar fusion surgery: A meta-analysis. *Medicine (Baltimore)* 2019;98(33):e16751–e16758
- 16 Sakaura H, Miwa T, Yamashita T, Kuroda Y, Ohwada T. Cortical bone trajectory screw fixation versus traditional pedicle screw fixation for 2-level posterior lumbar interbody fusion: comparison of surgical outcomes for 2-level degenerative lumbar spondylolisthesis. *J Neurosurg Spine* 2018;28(01):57–62
- 17 Santoni BG, Hynes RA, McGilvray KC, et al. Cortical bone trajectory for lumbar pedicle screws. *Spine J* 2009;9(05):366–373
- 18 Dayani F, Chen YR, Johnson E, et al. Minimally invasive lumbar pedicle screw fixation using cortical bone trajectory - Screw accuracy, complications, and learning curve in 100 screw placements. *J Clin Neurosci* 2019;61:106–111
- 19 Patel SS, Cheng WK, Danisa OA. Early complications after instrumentation of the lumbar spine using cortical bone trajectory technique. *J Clin Neurosci* 2016;24:63–67