

# SCIENTIFIC REPORTS



OPEN

## Clinical efficacy of laminectomy with instrumented fixation in treatment of adjacent segmental disease following ACCF surgery: a retrospective observational study of 48 patients

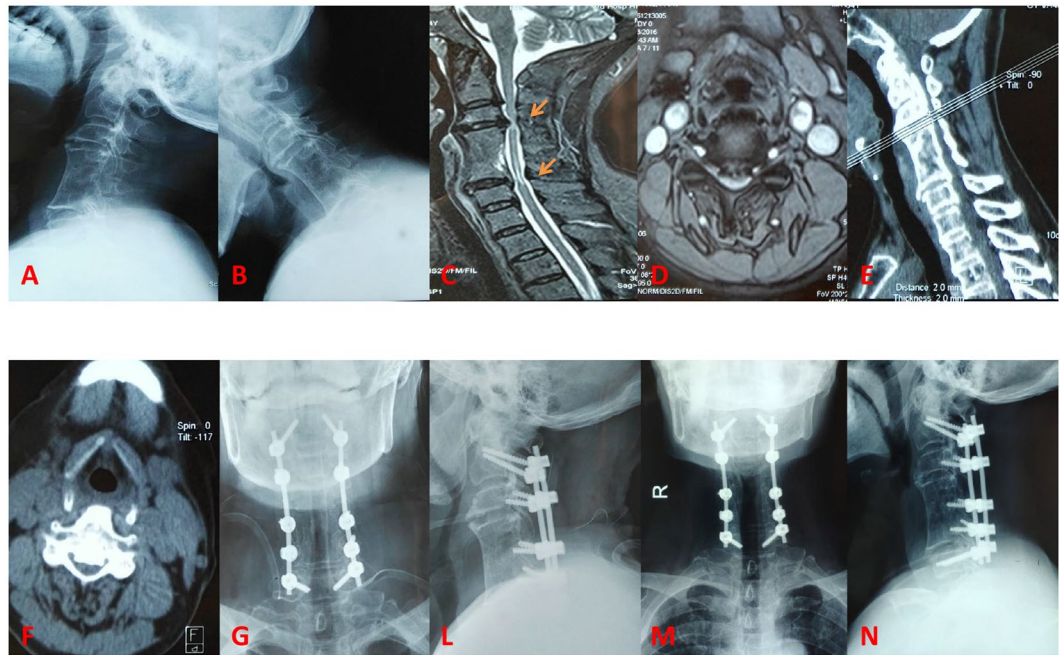
Sidong Yang<sup>1</sup>, Dalong Yang<sup>1</sup>, Lei Ma<sup>1</sup>, Hui Wang<sup>1</sup> & Wenyan Ding<sup>1,2</sup>

This study was designed to investigate the clinical efficacy of laminectomy with instrumented fixation in treatment of adjacent segmental diseases following anterior cervical corpectomy and fusion (ACCF) surgery. Between January 2008 and December 2015, 48 patients who underwent laminectomy with instrumented fixation to treat adjacent segmental diseases following ACCF surgery, were enrolled into this study. The patients were followed up at least 2 years. Pain assessment was determined by visual analogue scale (VAS) score and Neck Disability Index (NDI) score; neurological impairment was evaluated by Japanese Orthopaedic Association (JOA) score; and radiographic parameters were also compared. All comparisons were determined by paired t test with appropriate Bonferroni correction. VAS score preoperatively and at last follow-up was  $5.28 \pm 2.35$  vs  $1.90 \pm 1.06$  ( $P < 0.001$ ). JOA score preoperatively and at last follow-up was  $8.2 \pm 3.6$  vs  $14.5 \pm 1.1$  ( $P < 0.001$ ). NDI score preoperatively and at last follow-up was  $30.5 \pm 12.2$  vs  $10.6 \pm 5.8$  ( $P < 0.001$ ). Moreover, the losses of cervical lordosis and C2-C7 range of motion after laminectomy were significant (both  $P < 0.005$ ), but not sagittal vertical axis distance. Postoperative complications were few or mild. In conclusion, clinical effectiveness and safety can be guaranteed when the patients undergo laminectomy with instrumented fixation to treat adjacent segmental diseases following ACCF surgery.

Anterior cervical discectomy and fusion (ACDF) and anterior cervical corpectomy and fusion (ACCF) have been considered as the “gold standard” surgical treatment of cervical degenerative diseases. However, data from radiographic and clinical studies showed that the segments adjacent to the fused spinal segments would accelerate the progression of degeneration or become unstable after a certain years<sup>1-3</sup>.

Both ACDF and ACCF surgery have changed the original mechanical behavior of the cervical spine at the cost of the activity of the fused level, which is likely to cause the changes of adjacent vertebral stress distribution and the movement patterns, resulting in biomechanical changes including stress concentration of adjacent segments, compensatory increase in activity, and even instability; finally, adjacent segmental disease (ASD) developed<sup>4-6</sup>. Once the ASD progressed to a severe extent, the patients would usually undergo another surgery performed via a posterior way, including laminoplasty and laminectomy. However, both laminoplasty and laminectomy without fixation are likely to aggravate sagittal imbalance and contribute to the progression of cervical kyphosis<sup>7-10</sup>. Therefore, laminectomy with instrumented fixation would be better than that without any fixation when a second surgery is performed via a posterior way. To date, there have been few studies reporting clinical effectiveness in regards to posterior laminectomy with instrumented fixation in treating ASD following ACDF or ACCF.

<sup>1</sup>Department of Spinal Surgery, The Third Hospital of Hebei Medical University, Shijiazhuang, 050051, China. <sup>2</sup>Hebei Provincial Key Laboratory of Orthopedic Biomechanics, Shijiazhuang, 050051, China. Correspondence and requests for materials should be addressed to W.D. (email: [wenyuanding@hebmu.edu.cn](mailto:wenyuanding@hebmu.edu.cn))



**Figure 1.** Radiological images preoperatively and postoperatively. (A,B) preoperative X-ray images; (C,D) preoperative MRI scan; (E,F) preoperative CT scan; (G,L) postoperative X-ray immediately; (M,N) postoperative X-ray at final follow-up.

In this study, to minimize the confounding factors, it was designed to investigate the clinical effectiveness of laminectomy with instrumented fixation in treating ASD following only ACCF, based on a regular follow-up with a minimum of two years.

## Patients and Methods

**Ethical statement.** This study was approved by Ethics Committee of The Third Hospital of Hebei Medical University (Approval Number: KY2018-05-001). Informed consent was obtained from all participants and/or their legal guardian/s. The methods were carried out in accordance with the relevant guidelines and regulations.

**Patient selection.** In this study, all identified patients have undergone posterior cervical laminectomy and instrumented fixation with a history of previous ACCF surgery, as shown in Fig. 1. All patients were regularly followed up after surgery, at the timepoint of 1 week, 3 months, 1 year and thereafter.

**Surgical procedures.** Posterior cervical laminectomy and instrumented fixation was performed as follows. Briefly, a standard posterior approach was performed. In the first place, an incision was performed in the midline of the neck. Second, we separated the muscle along C2-C7 to expose spinous process, articular process, vertebral arch and laminae. In addition, two pedicle screws were implanted into C2 and C7, respectively. And then, two lateral mass screws were implanted into C3, C4, C5, and C6, respectively (where adjustment could apply). At last, we performed the laminectomy of C2-C7 using a ball mill drill to achieve thorough decompression of cervical spinal canal. Then two connecting rods were used to connect the screws together in both sides.

**Radiographic measurements.** Radiographic parameters were collected by screening neutral and dynamic flexion-extension lateral radiographs, including C2-C7 sagittal vertical axis (SVA) distance, cervical lordosis and range of motion (ROM). Neutral-position and dynamic flexion-extension lateral radiographs during each follow-up examination were evaluated with the PACS software and a PACS workstation (Centricity 2.0, General Electric Medical Systems, Milwaukee, WI).

**Assessment of clinical effectiveness.** All patients were required to return our hospital for regular follow-up after surgery. Clinical and radiological evaluations were performed postoperatively, at 1 week, 3 months, 1 year, and last follow-up (more than 2 years). Clinical effectiveness was assessed by visual analogue scale (VAS) score, Japanese Orthopaedic Association (JOA) score (17 points system, 1994 revised edition) and Neck Disability Index (NDI) score. Specifically, pain assessment was determined by visual analogue scale (VAS) score and Neck Disability Index (NDI) score; neurological impairment was evaluated by Japanese Orthopaedic Association (JOA) score. The recovery rate (RR) of JOA score was calculated according to the following formula:  $RR = (\text{postoperative scores} - \text{preoperative scores}) / (17 - \text{preoperative scores}) * 100\%$ .

**Statistical analysis.** SPSS for windows (version 18.0, IBM SPSS Inc., Chicago, USA) was applied to perform statistical analyses. Data are presented as Mean  $\pm$  SD (standard deviation) for measurement data. Comparisons

preoperatively	1 week postoperatively	3 months postoperatively	1 year postoperatively	Last follow-up	Statistics
5.28 ± 2.35	3.91 ± 2.31	2.85 ± 1.29	1.94 ± 1.12	1.90 ± 1.06	
	2.88	6.28	8.89	9.08	t
	0.005	<0.001	<0.001	<0.001	p*

**Table 1.** Comparison regarding VAS score. \*Compared with VAS score preoperatively. VAS, visual analogue scale.

preoperatively	1 week postoperatively	3 months postoperatively	1 year postoperatively	Last follow-up	Statistics
8.2 ± 3.6	10.1 ± 2.2	13.2 ± 1.6	14.3 ± 1.0	14.5 ± 1.1	
	3.12	8.79	11.31	11.60	t
	0.0024	<0.001	<0.001	<0.001	p*

**Table 2.** Comparison regarding JOA score. \*Compared with JOA score preoperatively. JOA, Japanese Orthopaedic Association.

preoperatively	1 week postoperatively	3 months postoperatively	1 year postoperatively	Last follow-up	Statistics
30.5 ± 12.2	24.5 ± 4.5	16.6 ± 5.4	11.0 ± 6.5	10.6 ± 5.8	
	3.20	7.22	9.77	10.21	t
	0.0019	<0.001	<0.001	<0.001	p*

**Table 3.** Comparison regarding NDI score. \*Compared with NDI score preoperatively. NDI, Neck Disability Index.

of VAS, JOA, NDI score, and radiographic parameters between pre- and post-surgery were determined by paired t test.  $P < 0.05$  with appropriate Bonferroni correction was defined as significant.

## Results

**Baseline and surgical data.** Between January 2008 and December 2015, 48 patients who underwent laminectomy with instrumented fixation to treat adjacent segmental diseases following ACCF surgery, were identified and enrolled into this study. In total, there were 26 males and 22 females. The patient age was  $61 \pm 17$  years. The duration between previous ACCF and posterior laminectomy was  $16 \pm 11$  years. The surgery took 160 min on average. Blood loss was 700 ml on average. Median blood transfusion was 400 ml (ranging from 200 to 800 ml). All cases completed regular follow-up of a minimum of 2 years, with an average of 38 months. Postoperative complications were few or mild. Five patients sustained lower-limb vein thrombosis but asymptomatic. Two patients suffered C5 palsy which was finally diminished. Besides, two patients experienced delayed wound healing but finally well healed.

**VAS score.** As shown in Table 1, VAS score preoperatively was  $5.28 \pm 2.35$ , and  $1.90 \pm 1.06$  postoperatively at last follow-up. Statistically, VAS score achieved significant improvement compared with the preoperative scores ( $P < 0.001$ ).

**JOA score and RR.** As shown in Table 2, JOA score preoperatively was  $8.2 \pm 3.6$ , and  $14.5 \pm 1.1$  postoperatively at last follow-up. Statistically, the difference was significant regarding JOA score compared with the preoperative scores ( $P < 0.001$ ). In addition, RR was calculated to be  $70.58\% \pm 4.6\%$  at last follow up.

**NDI score.** As shown in Table 3, NDI score preoperatively was  $30.5 \pm 12.2$ , and  $10.6 \pm 5.8$  postoperatively at last follow-up. Statistically, the difference was significant regarding NDI score compared with the preoperative scores ( $P < 0.001$ ).

**Radiographic parameters.** As shown in Table 4, preoperative cervical lordosis was  $12.5 \pm 6.3$  while it was  $8.7 \pm 6.0$  postoperatively at last follow-up ( $P = 0.003$ ). As shown in Table 5, C2-C7 ROM decreased after laminectomy to  $25.6 \pm 9.5$ , from  $43.6 \pm 5.9$  preoperatively ( $P < 0.001$ ). As shown in Table 6, preoperative SVA distance was  $28.05 \pm 5.4$  mm, and it increased to  $29.15 \pm 5.6$  mm postoperatively at last follow-up, but without any statistical significance ( $P = 0.330$ ).

## Discussion

In a clinical setting, ACDF and ACCF are widely used surgical procedures by neurosurgeons and spine surgeons in treatment of cervical spondylosis. However, data from radiographic and clinical studies showed that the segments adjacent to the fused spinal segments would accelerate the progression of degeneration or become unstable after a certain years. Both ACDF and ACCF would yield the loss of moter function in the fused level, which is likely to cause the changes of adjacent vertebral stress distribution and the movement patterns, resulting

preoperatively	1 week postoperatively	3 months postoperatively	1 year postoperatively	Last follow-up	Statistics
12.5 ± 6.3	12.1 ± 6.8	11.8 ± 6.2	10.2 ± 5.8	8.7 ± 6.0	
	0.30	0.55	1.86	3.03	t
	0.766	0.585	0.066	0.003	p*

**Table 4.** Comparison regarding cervical lordosis. \*Compared with cervical lordosis preoperatively.

preoperatively	1 week postoperatively	3 months postoperatively	1 year postoperatively	Last follow-up	Statistics
43.6 ± 5.9	32.5 ± 5.9	33.8 ± 6.3	28.6 ± 7.5	25.6 ± 9.5	
	9.22	7.87	10.89	11.15	t
	<0.001	<0.001	<0.001	<0.001	p*

**Table 5.** Comparison regarding C2-C7 ROM. \*Compared with C2-C7 ROM preoperatively. ROM, range of motion.

preoperatively (mm)	1 week postoperatively	3 months postoperatively	1 year postoperatively	Last follow-up	Statistics
28.05 ± 5.4	28.09 ± 6.5	28.20 ± 5.9	28.56 ± 4.4	29.15 ± 5.6	
	0.03	0.13	0.51	0.98	t
	0.974	0.897	0.613	0.330	p*

**Table 6.** Comparison regarding C2-C7 SVA. \*Compared with C2-C7 SVA preoperatively. SVA, sagittal vertical axis.

in biomechanical changes including stress concentration of adjacent segments, compensatory increase in activity, and even instability; finally, ASD may develop to a severe degree. As such, the patients are more likely to undergo a posterior surgery, such as laminoplasty and laminectomy.

As reported previously, laminoplasty, laminectomy, and laminectomy with instrumented fixation or fusion, all have improved cervical function in the near term<sup>11,12</sup>. The shortcoming of posterior approach (without thorough decompression and fusion) is that ventral compression may persist if the backward drift of the spinal cord is not enough, resulting in an unsatisfactory neurofunctional recovery. Laminectomy has shown a close association with late deterioration of kyphosis, segmental instability and neurological deterioration, compared with the other posterior surgery<sup>12</sup>. Laminoplasty should be avoided as a preferred approach in treating patients with preoperative kyphosis or instability, but it seems safer and less trauma and economic burden. Thus, for patients with adequate stabilization and lordosis, laminoplasty could be a good alternative, because laminoplasty can preserve the motor function of motor segments by widely decompressing, which is in line with the current concept of non-fusion. However, both laminoplasty and laminectomy (if without fixation) are likely to aggravate sagittal imbalance and contribute to the progression of cervical kyphosis<sup>7-10,12</sup>. Hence, laminectomy with instrumented fixation appears to be a better surgical procedure when a posterior operation is scheduled for ASD (especially when more than two levels) following a previous anterior operation, such like ACDF and ACCF.

Over the past few years, laminectomy has been shown as an effective and safe technique in treatment of multilevel cervical spondylotic myelopathy<sup>13-15</sup>. However, accumulating evidence has revealed increased rate of approach-related complications caused by the posterior approach as compared with the anterior approach, particularly in multilevel surgery<sup>16-19</sup>. It is well known that postoperative C5 palsy is not rare after cervical surgery. Although there remains controversy, C5 palsy is considered to be more common in patients who had laminectomy and fusion than those who had laminoplasty. However, the reason for the higher incidence of C5 palsy in patients with laminectomy and fusion has been poorly understood. A recent study<sup>20</sup> reported a high occurrence rate of 14.3% with C5 palsy and verified that C4-C5 foraminal stenosis was the only risk factor for C5 palsy after laminectomy. In our study, only two patients suffered C5 palsy after laminectomy, which was a much lower incidence rate.

By contrast to the posterior approach, the advantage of anterior approach is apparent; it is the most effective technique in a situation where a direct surgical decompression is urgently needed because it can directly remove such compressive anterior components as osteophytes, disc herniations or ossification of posterior longitudinal ligament<sup>21,22</sup>. Previously, it has been indicated that single posterior laminectomy would be insufficient in terms of decreasing intramedullary pressure<sup>23</sup>. In contrast, neurological deterioration due to increased intramedullary pressure may result from progressive kyphosis which can be caused by non-instrumented laminectomy<sup>9</sup>. Nevertheless, laminectomy remains to be a valuable surgical technique for decompression of cervical spinal canal, particularly when combined with instrumented fixation and fusion using lateral mass screws in order to prevent postoperative instability and progression of kyphosis. Therefore, cervical laminectomy with instrumented fixation/fusion is believed to be the best choice for ASD following ACDF/ACCF. In the current study, we only focus on the treatment of ASD due to ACCF, excluding the type caused by ACDF, because ACDF and ACCF are



different in terms of fusion levels, which is possibly a confounding factor to the further analysis. Thus, to minimize such a confounding factor, we here only investigated the clinical efficacy of laminectomy with instrumented fixation in treatment of ASD following ACCF.

To the best of our knowledge, there have been no reports on assessment of clinical outcomes of laminectomy with instrumented fixation in treatment of ASD following ACCF. Adjacent segment degeneration and related diseases have become major concerns following anterior fusion surgery. The data from a recent meta-analysis has shown that the pooled incidence of adjacent segment degeneration following a cervical fusion surgery is 32.8%, and approximately 1/4-1/3 of such degeneration would progress to ASD in the future<sup>24</sup>. Apparently, the incidence of ASD is really high; almost one of ten cases undergoing ACDF/ACCF surgery would progress to ASD some day. Thus, it is important to clarify the clinical efficacy and safety of laminectomy with instrumented fusion in treatment of ASD.

In this study, all of the neurological function improvements appear satisfying, with regard to JOA score, VAS score, and NDI score. It is consistent with the reported studies that have confirmed such improvements due to laminectomy with or without fusion<sup>25,26</sup>. As reported by recent meta-analysis<sup>25,26</sup>, laminectomy with fusion and laminoplasty yield similar results regarding the loss of cervical lordosis. In our study, only cervical lordosis at last follow-up is statistically lower than the preoperative one. Thus, the loss of lordosis due to laminectomy with instrumented fixation is progressive, but slower than the others. During the surgical procedures for the patients, the facet joints have been damaged by ball mill drill that we used to assist resection of the vertebral laminae. Owing to that, posterior fusion of cervical spine has formed, making the whole cervical structure more stable.

This study goes along with some limitations. First of all, the retrospective character of the study design was bound to cause some selection bias. In addition, this study was only an observational study; a comparative study would be better. Lastly, the small sample size was also a limitation in this study. Therefore, a randomized clinical trial with a large sample is needed to further clarify the clinical outcomes in the future.

## Conclusions

In summary, clinical effectiveness and safety can be guaranteed when the patients undergo laminectomy with instrumented fixation to treat adjacent segmental diseases following ACCF surgery.

## Data Availability

Data in this study are available.

## References

- Hisey, M. S. *et al.* Prospective, Randomized Comparison of One-level Mobi-C Cervical Total Disc Replacement vs. Anterior Cervical Discectomy and Fusion: Results at 5-year Follow-up. *Int J Spine Surg* **10**, 10 (2016).
- Rajakumar, D. V., Hari, A., Krishna, M., Konar, S. & Sharma, A. Adjacent-level arthroplasty following cervical fusion. *Neurosurg Focus* **42**, E5 (2017).
- Matsumoto, M. *et al.* Anterior cervical decompression and fusion accelerates adjacent segment degeneration: comparison with asymptomatic volunteers in a ten-year magnetic resonance imaging follow-up study. *Spine (Phila Pa 1976)* **35**, 36–43 (2010).
- Jawahar, A. & Nunley, P. Total disc arthroplasty and anterior cervical discectomy and fusion in cervical spine: competitive or complimentary? Review of the literature. *Global Spine J* **2**, 183–186 (2012).
- Hou, Y. *et al.* Cervical kinematics and radiological changes after Discover artificial disc replacement versus fusion. *Spine J* **14**, 867–877 (2014).
- Ding, F. *et al.* Fusion-nonfusion hybrid construct versus anterior cervical hybrid decompression and fusion: a comparative study for 3-level cervical degenerative disc diseases. *Spine (Phila Pa 1976)* **39**, 1934–1942 (2014).
- Lee, J. S. *et al.* The Predictable Factors of the Postoperative Kyphotic Change of Sagittal Alignment of the Cervical Spine after the Laminoplasty. *J Korean Neurosurg Soc* **60**, 577–583 (2017).
- Ma, L. *et al.* Comparison of laminoplasty versus laminectomy and fusion in the treatment of multilevel cervical ossification of the posterior longitudinal ligament: A systematic review and meta-analysis. *Medicine (Baltimore)* **97**, e11542 (2018).
- Chavanne, A., Pettigrew, D. B., Holtz, J. R., Dollin, N. & Kuntz, C. Spinal cord intramedullary pressure in cervical kyphotic deformity: a cadaveric study. *Spine (Phila Pa 1976)* **36**, 1619–1626 (2011).
- Mayer, M., Meier, O., Auffarth, A. & Koller, H. Cervical laminectomy and instrumented lateral mass fusion: techniques, pearls and pitfalls. *Eur Spine J* **24**(Suppl 2), 168–185 (2015).
- Mummaneni, P. V. *et al.* Cervical surgical techniques for the treatment of cervical spondylotic myelopathy. *J Neurosurg Spine* **11**, 130–141 (2009).
- Ryken, T. C. *et al.* Cervical laminectomy for the treatment of cervical degenerative myelopathy. *J Neurosurg Spine* **11**, 142–149 (2009).
- Kristof, R. A. *et al.* Comparison of ventral corpectomy and plate-screw-instrumented fusion with dorsal laminectomy and rod-screw-instrumented fusion for treatment of at least two vertebral-level spondylotic cervical myelopathy. *Eur Spine J* **18**, 1951–1956 (2009).
- Mummaneni, P. V., Haid, R. W. & Rodts, G. E. Combined ventral and dorsal surgery for myelopathy and myeloradiculopathy. *Neurosurgery* **60**, S82–89 (2007).
- Wiggins, G. C. & Shaffrey, C. I. Dorsal surgery for myelopathy and myeloradiculopathy. *Neurosurgery* **60**, S71–81 (2007).
- Bapat, M. R., Chaudhary, K., Sharma, A. & Laheri, V. Surgical approach to cervical spondylotic myelopathy on the basis of radiological patterns of compression: prospective analysis of 129 cases. *Eur Spine J* **17**, 1651–1663 (2008).
- Rao, R. D. *et al.* Degenerative cervical spondylosis: clinical syndromes, pathogenesis, and management. *Instr Course Lect* **57**, 447–469 (2008).
- Rao, R. D. *et al.* Degenerative cervical spondylosis: clinical syndromes, pathogenesis, and management. *J Bone Joint Surg Am* **89**, 1360–1378 (2007).
- Shamji, M. F. *et al.* Impact of surgical approach on complications and resource utilization of cervical spine fusion: a nationwide perspective to the surgical treatment of diffuse cervical spondylosis. *Spine J* **9**, 31–38 (2009).
- Kang, K. C. *et al.* Preoperative Risk Factors of C5 Nerve Root Palsy After Laminectomy and Fusion in Patients With Cervical Myelopathy: Analysis of 70 Consecutive Patients. *Clin Spine Surg* **30**, 419–424 (2017).
- Liu, T., Xu, W., Cheng, T. & Yang, H. L. Anterior versus posterior surgery for multilevel cervical myelopathy, which one is better? A systematic review. *Eur Spine J* **20**, 224–235 (2011).
- Tani, T. *et al.* Relative safety of anterior microsurgical decompression versus laminoplasty for cervical myelopathy with a massive ossified posterior longitudinal ligament. *Spine (Phila Pa 1976)* **27**, 2491–2498 (2002).

23. Winestone, J. S. *et al.* Laminectomy, durotomy, and piotomy effects on spinal cord intramedullary pressure in severe cervical and thoracic kyphotic deformity: a cadaveric study. *J Neurosurg Spine* **16**, 195–200 (2012).
24. Hashimoto, K., Aizawa, T., Kanno, H. & Itoi, E. Adjacent segment degeneration after fusion spinal surgery—a systematic review. *Int Orthop* **43**, 987–993 (2019).
25. Phan, K. *et al.* Laminectomy and fusion vs laminoplasty for multi-level cervical myelopathy: a systematic review and meta-analysis. *Eur Spine J* **26**, 94–103 (2017).
26. Liu, F. Y. *et al.* Laminoplasty versus laminectomy and fusion for multilevel cervical compressive myelopathy: A meta-analysis. *Medicine (Baltimore)* **95**, e3588 (2016).

### Author Contributions

Conceived and designed the study: W.D. Collected data: S.Y., L.M. and D.Y. Analyzed the data: S.Y. and H.W. Wrote the paper: S.Y.

### Additional Information

**Competing Interests:** The authors declare no competing interests.

**Publisher's note:** Springer Nature remains neutral with regard to jurisdictional claims in published maps and institutional affiliations.



**Open Access** This article is licensed under a Creative Commons Attribution 4.0 International License, which permits use, sharing, adaptation, distribution and reproduction in any medium or format, as long as you give appropriate credit to the original author(s) and the source, provide a link to the Creative Commons license, and indicate if changes were made. The images or other third party material in this article are included in the article's Creative Commons license, unless indicated otherwise in a credit line to the material. If material is not included in the article's Creative Commons license and your intended use is not permitted by statutory regulation or exceeds the permitted use, you will need to obtain permission directly from the copyright holder. To view a copy of this license, visit <http://creativecommons.org/licenses/by/4.0/>.

© The Author(s) 2019