

## Case Report

# Bilateral chylothorax following left supraclavicular lymph node dissection for breast cancer: one case report and literature review

De-Juan Yang, Guo-Sheng Ren and Xiao-Yi Wang

## Abstract

Chylothorax is a rare complication of neck dissection, and bilateral chylothorax is even rarer. However, both are potentially serious and sometimes life-threatening, especially those that are associated with left neck dissection for head and neck neoplasms. We report one case of bilateral chylothorax following left supraclavicular dissection for breast cancer. This case was treated successfully with a new conservative management approach.

**Key words** Bilateral chylothorax, treatment, neck dissection, supraclavicular, breast cancer

Isolated regional nodal recurrences after curative treatment of breast cancer are rare, especially in supraclavicular nodes<sup>[1,2]</sup>. Clinical outcomes are similar for patients with ipsilateral supraclavicular lymph node metastases at first presentation and for patients with recurrent ipsilateral supraclavicular lymph node metastases<sup>[3,4]</sup>. Per the last accepted staging system for breast cancer<sup>[5]</sup>, ipsilateral supraclavicular lymph node metastases is classified as regional disease (stage IIIC); but the survival rate was lower in patients with ipsilateral supraclavicular lymph node metastases than in patients with lower axillary or subclavian nodal involvement<sup>[6]</sup>. Nevertheless, patients with ipsilateral supraclavicular lymph node metastases who were treated with surgery or radiotherapy and achieved good neck control were reported to achieve better survival than those for whom surgical treatment or irradiation did not result in good local control<sup>[6-8]</sup>. Thus, neck dissection is sometimes necessary for breast cancer patients with ipsilateral supraclavicular lymph node metastases.

Chylous leakage is a common complication following neck dissection. However, postoperative chylothorax is uncommon, and bilateral chylothorax is even rarer. This condition may cause severe respiratory, metabolic, and immunologic dysfunctions and can even be fatal. Currently, there are no reported cases of bilateral chylothorax following neck dissection for breast cancer in the literature. Herein,

we report a case of bilateral chylothorax following left supraclavicular dissection for breast cancer, which was treated successfully using a novel conservative management strategy.

## Case Report

A 43-year-old woman presented with a 3-year history of a left-sided palpable breast mass. Physical examination revealed a 15 cm × 15 cm lump, fixed, invading the skin, accompanied with left supraclavicular lymphadenectasis. Results of chest X-ray, ventral ultrasonography, radioisotope bony scanning, and nuclear magnetic resonance imaging (MRI) of the head did not show distant metastasis. The pathologic diagnosis via core biopsy was adenocarcinoma, and clinical stage was IIIC (T4N3M0). The patient underwent 4 cycles of neoadjuvant chemotherapy, and therefore the mass was reduced to 25% of its original size (partial response). Radical mastectomy and left supraclavicular lymph node dissection were then performed. Chylous fluid output in the neck drainage tube was approximately 500 mL on the first day postoperation, but increased to 1,600 mL on the second day. An emergency operation was performed to ligate the fistula, and the leakage was ceased. Nevertheless, on the fourth day postoperation, the patient experienced dyspnea and chest discomfort. Physical examination revealed no neck edema or swelling, but bilateral breath sounds were diminished on auscultation. Chest X-ray, which did not show obvious abnormalities preoperatively (**Figure 1A**), revealed medium, bilateral pleural effusions (**Figure 1B**). Diagnostic thoracentesis was performed and milky fluid was aspirated from both sides. Biochemical analysis confirmed bilateral chylothorax.

We implemented a conservative management approach, which

**Authors' Affiliation:** Department of Breast and Endocrine Surgery, The First Affiliated Hospital of Chongqing Medical University, Chongqing 400016, P. R. China.

**Corresponding Author:** Xiao-Yi Wang, Department of Breast and Endocrine Surgery, The First Affiliated Hospital of Chongqing Medical University, No. 1 Youyi Road, Yuzhong District, Chongqing 400016, P. R. China. Tel: +86-23-89011463; Fax: +86-23-89011122; Email: cyfywxy@163.com.

**doi:** 10.5732/cjc.013.10102

involved insertion of bilateral pigtail catheters into the thoracic cavity, total parenteral nutrition with total enteric rest, and administration of somatostatin (250 µg/h) by continuous intravenous drip on the basis of the review of literature. On the 12th day postoperation, the patient achieved complete remission of dyspnea and chest discomfort; 970 mL of chyle-like liquid was aspirated intermittently from bilateral pleural spaces. A repeated chest X-ray showed no evidence of residual effusions (**Figure 1C**). Thus, the drainage tubes were removed, and the patient was started on a low fat and protein diet for 3 days before resuming a regular diet. On the 15th day postoperation, the patient had recovered completely.

## Discussion

Bilateral chylothorax is a rare complication that results from injury to the thoracic duct or one of its branches following neck dissection. We searched the English-language literature through PubMed and found 26 cases of bilateral chylothorax reported between 1951 and 2011<sup>[9-29]</sup>. We analyzed the primary diseases, treatment, and prognosis of bilateral chylothorax. The results showed that the majority of bilateral chylothorax cases followed neck dissection associated with head and neck cancers, such as thyroid cancer, laryngocarcinoma, and tongue cancer (**Table 1**). However, none of the reported cases described breast cancer as a cause for bilateral chylothorax.

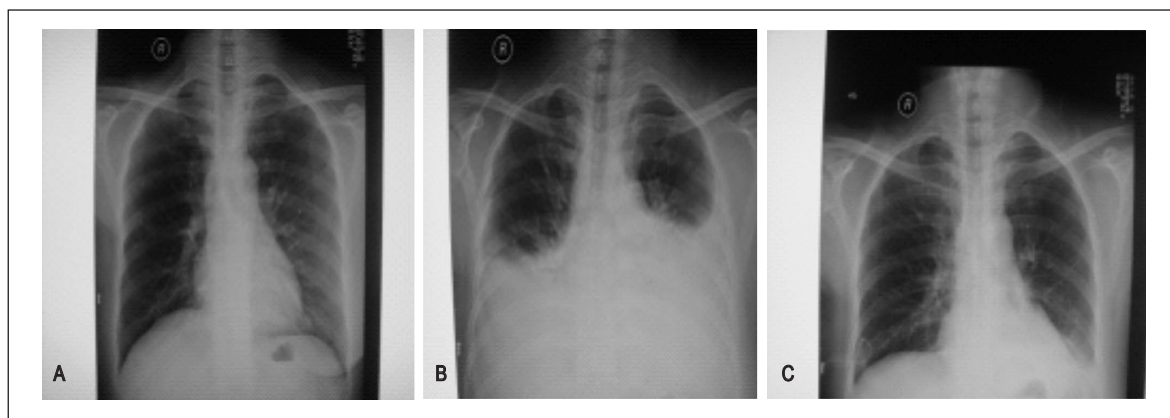
The majority of injuries to the thoracic duct cause merely chylous leakage; chylothorax, especially bilateral, is rare. Milky fluid suggests a chylous effusion, but the absence of a milky appearance does not preclude chylothorax, especially if the patient is fasting or on a low-fat diet. Biochemical analysis of the fluid should be the initial diagnostic test, with a triglyceride concentration greater than 1,100 mg/L confirming the diagnosis<sup>[30]</sup>. When the triglyceride level is between 550 and 1,100 mg/L, a lipoprotein analysis is

indicated to detect chylomicrons, whereas a triglyceride level less than 500 mg/L has no more than a 5% chance of being chylous<sup>[30]</sup>. Clinically, low-output chylothorax (<500 mL/day) could be treated using a conservative approach, such as drainage and a low-fat diet. High-output chylothorax (>500 mL/day) could cause a fluid and electrolyte imbalance and a loss of nutrients, and it can even be fatal. Thus, high-output chylothorax requires surgical intervention<sup>[31]</sup>. However, from the literature we reviewed, only 2 cases were treated with surgery<sup>[22,23]</sup>, whereas the remaining 24 cases were treated conservatively and recovered at length.

In this case, we performed an emergency operation to ligate the fistula on the second day postoperation, when the chylous leakage reached 1,600 mL in volume. Based on our clinical experience, postoperative adhesions develop by 3 days postoperation, making surgical intervention for chylous leakage a challenge. Although the surgery ceased the neck leakage, bilateral chylothorax was confirmed 4 days after operation. To treat this condition, we prefer to follow a conservative management plan rather than perform additional surgeries, unless the conservative approach is insufficient. Here, we chose nonsurgical treatments for the patient, including drainage, total parenteral nutrition with total enteric rest, continuous intravenous infusion of somatostatin (250 µg/h), and intermittent thoracentesis for aspirating effusion, and the patient was cured.

Our report also supports that the use of somatostatin may be a new conservative therapeutic approach. The exact mechanism of action of this neurohormonal and panacrine agent remains unknown. It may reduce gastrointestinal chyle production by decreasing splanchnic blood flow and decreasing gastric, biliary, pancreatic, and intestinal secretions<sup>[28]</sup>.

Taken together, our results and the results described in the previous literature suggest that conservative management is an effective treatment for bilateral chylothorax following neck dissection. Our report shows that the use of somatostatin may be a new



**Figure 1.** Bilateral chylothorax occurred after left supraclavicular dissection. A, no obvious abnormalities are present on the preoperative chest X-ray. B, on the fourth day postoperation, chest X-ray shows medium, bilateral pleural effusions, accompanied with dyspnea and chest discomfort. Bilateral breath sounds were diminished upon auscultation. C, after conservative management, a repeated chest X-ray shows no evidence of residual effusions. These results suggest that conservative treatment of chylous leakage is effective.

**Table 1. Cases of bilateral chylothorax following neck dissection reported in the literature**

Year	Authors (reference)	Disease	Neck dissection	Treatment	Prognosis
1951	Frazell <i>et al.</i> <sup>[9]</sup>	Carcinomataneumfaciale	Left	Conservative	Recovery
1976	Coates <i>et al.</i> <sup>[10]</sup>	Laryngocarcinoma	Left	Conservative	Recovery
1981	Saraceno <i>et al.</i> <sup>[11]</sup>	Carcinoma of the floor of the mouth	Left	Conservative	Recovery
1985	Har-El <i>et al.</i> <sup>[12]</sup>	Thyroid cancer	Left	Conservative	Recovery
1985	Ng <i>et al.</i> <sup>[13]</sup>	Carcinoma of the floor of the mouth	Left	Conservative	Recovery
1988	Pace-Balzet <i>et al.</i> <sup>[14]</sup>	Adenolymphoma	Left	Conservative	Recovery
1989	Oi <i>et al.</i> <sup>[15]</sup>	Maxillary sinus carcinoma	Left	Conservative	Recovery
1992	Biurrun <i>et al.</i> <sup>[16]</sup>	Unclear	Unclear	Conservative	Recovery
1995	Jabbar <i>et al.</i> <sup>[17]</sup>	Thyroid cancer	Bilateral	Conservative	Recovery
2000	Gregor <i>et al.</i> <sup>[18]</sup>	Nasopharyngeal carcinoma	Right	Conservative	Recovery
2001	Al-Sebeih <i>et al.</i> <sup>[19]</sup>	Laryngocarcinoma	Bilateral	Conservative	Recovery
2001	Jortay <i>et al.</i> <sup>[20]</sup>	Unclear	Left	Conservative	Recovery
2003	Kamasaki <i>et al.</i> <sup>[21]</sup>	Tongue cancer	Bilateral	Conservative	Recovery
2004	Busquets <i>et al.</i> <sup>[22]</sup>	Adenolymphoma	Left	Surgery + conservative	Recovery
2006	Srikumar <i>et al.</i> <sup>[23]</sup>	Nasopharyngeal carcinoma	Left	Surgery + conservative	Recovery
2007	Tsukahara <i>et al.</i> <sup>[24]</sup>	Thyroid cancer	Left	Conservative	Recovery
		Tongue cancer	Left	Conservative	Recovery
		Laryngocarcinoma	Bilateral	Conservative	Recovery
2007	Bae <i>et al.</i> <sup>[25]</sup>	Thyroid cancer	Left	Conservative	Recovery
		Thyroid cancer	Left	Conservative	Recovery
2009	Han <i>et al.</i> <sup>[26]</sup>	Thyroid cancer	Left	Conservative	Recovery
2010	AL-Khudaris <i>et al.</i> <sup>[27]</sup>	Laryngocarcinoma	Bilateral	Conservative	Recovery
2011	Rodier <i>et al.</i> <sup>[28]</sup>	Thyroid cancer	Left	Conservative	Recovery
2011	Tian W <i>et al.</i> <sup>[29]</sup>	Thyroid cancer	Bilateral	Conservative	Recovery
		Thyroid cancer	Bilateral	Conservative	Recovery

conservative therapeutic approach.

Received: 2013-05-27; revised: 2013-09-25;  
accepted: 2013-10-10.

## References

- [1] Recht A, Pierce SM, Abner A, et al. Regional nodal failure after conservative surgery and radiotherapy for early-stage breast carcinoma. *J Clin Oncol*, 1991;9:988–996.
- [2] Fentiman IS, Lavelle MA, Caplan D, et al. The significance of supraclavicular fossa node recurrence after radical mastectomy. *Cancer*, 1986;57:908–910.
- [3] Kiricuta IC, Willner J, Kolbl O, et al. The prognostic significance of the supraclavicular lymph node metastases in breast cancer patients. *Int J Radiat Oncol Biol Phys*, 1994;28:387–393.
- [4] van der Sagen MJ, Coebergh JW, Roumen RM, et al. Detection, treatment, and outcome of isolated supraclavicular recurrence in 42 patients with invasive breast carcinoma. *Cancer*, 2003;98:11–17.
- [5] Singletary SE, Allred C, Ashley P, et al. Revision of the American Joint Committee on Cancer staging system for breast cancer. *J Clin Oncol*, 2002;20:3628–3636.
- [6] Chen SC, CHang HK, Lin YC, et al. Prognosis of breast cancer after supraclavicular lymph node metastasis: not a distant metastasis. *Ann Surg Oncol*, 2006;13:1457–1465.
- [7] Huang EH, Tucker SL, Strom EA, et al. Predictors of locoregional recurrence in patients with locally advanced breast cancer treated with neoadjuvant chemotherapy, mastectomy, and radiotherapy. *Int J Radiat Oncol Biol Phys*, 2005;62:351–357.
- [8] Park HJ, Shin KH, Cho KH, et al. Outcomes of positron emission tomography-staged clinical N3 breast cancer treated with neoadjuvant chemotherapy, surgery, and radiotherapy. *Int J Radiat Oncol Biol Phys*, 2011;81:689–695.
- [9] Frazell EL, Harrold CC, Rasmussen L. Bilateral Chylothorax: an unusual complication of radical neck dissection with recovery. *Ann Surg*, 1951;134:135–137.
- [10] Coates HL, Desanto LW. Bilateral chylothorax as a complication of radical neck dissection. *J Laryngol Otol*, 1976;90:967–970.
- [11] Saraceno CA, Farrior RT. Bilateral chylothorax. Rare complication of neck dissection. *Arch Otolaryngol*, 1981;107:497–499.

- [12] Har-El G, Segal K, Sidi J. Bilateral chylothorax complicating radical neck dissection: report of a case with no concurrent external chylous leakage. *Head Neck Surg*, 1985,7:225–230.
- [13] Ng RS, Kerbavaz RJ, Hilsinger RL. Bilateral chylothorax from radical neck dissection. *Otolaryngol Head Neck Surg*, 1985,93:814–817.
- [14] Pace-Balzan A, Moriarty B. Bilateral chylothorax following left radical neck dissection (case report). *J Laryngol Otol*, 1988,102:288–290.
- [15] Oi K, Haraguchi N, Machida S. Dyspnea resulting from accumulation of pleural effusion after radical neck dissection. A case report. *Oral Surg Oral Med Oral Pathol*, 1989,67:258–261.
- [16] Biurrun O, Sabater F, Traserra J. Bilateral chylothorax after radical neck dissection. Apropos of a case. *Rev Laryngol Otol Rhinol (Bord)*, 1992,113:111–113. [in French]
- [17] Jabbar AS, al-Abdulkareem A. Bilateral chylothorax following neck dissection. *Head Neck*, 1995,17:69–72.
- [18] Gregor RT. Management of chyle fistulization in association with neck dissection. *Otolaryngol Head Neck Surg*, 2000,122:434–439.
- [19] Al-Sebein H, Sadeghi N, Al-Dhahri. S Bilateral chylothorax following neck dissection: a new method of treatment. *Ann Otol Rhinol Laryngol*, 2001,110:381–384.
- [20] Jortay A, Bisschop P. Bilateral chylothorax after left radical neck dissection. *Acta Otorhinolaryngol Belg*, 2001,55:285–289.
- [21] Kamasaki N, Ikeda H, Wang ZL, et al. Bilateral chylothorax following radical neck dissection. *Int J Oral Maxillo Surg*, 2003,32:91–93.
- [22] Busquets JM, Rullan PJ, Trinidad-Pinedo J. Bilateral chylothorax after neck dissection. *Otolaryngol Head Neck Surg*, 2004,130:492–495.
- [23] Srikumar S, Newton JR, Westin TA. Bilateral chylothorax following left-sided radical neck dissection. *J Laryngol Otol*, 2006,120:705–707.
- [24] Tsukahara K, Kawabata K, Mitani H, et al. Three cases of bilateral chylothorax developing after neck dissection. *Auris Nasus Larynx*, 2007,34:573–576.
- [25] Bae JS, Song BJ, Kim MR, et al. Bilateral chylothoraces without chyle leakage after left-sided neck dissection for thyroid cancer: report of two cases. *Surg Today*, 2007,37:652–655.
- [26] Han C, Guo L, Wang KJ, et al. Bilateral chylothorax following neck dissection for thyroid cancer. *Int J Oral Maxillofac Surg*, 2009,38:1119–1122.
- [27] AL-Khudaris, Vitale L, Ghanem T, et al. Recurrent high output chyle fistula post neck dissection resolution with conservative management. *Laryngoscope*, 2010,120:S141.
- [28] Rodier JF, Volkmar PP, Bodin F, et al. Thoracic duct fistula after thyroid cancer surgery: towards a new treatment? *Case Rep Oncol*, 2011,4:255–259.
- [29] Tian W, Li ZY, Wang P, et al. Chylothorax after neck dissection for thyroid carcinomas: report of three cases. *Surg Today*, 2012,42:89–92.
- [30] Valentine VG, Raffin TA. The management of chylothorax. *Chest*, 1992,102:586–591.
- [31] Binkert CA, Yucel EK, Davison BD, et al. Percutaneous treatment of high-output chylothorax with embolization or needle disruption technique. *J Vasc Interv Radiol*, 2005,16:1257–1262.





**2014** | DEC  
3-6  
**MELBOURNE  
AUSTRALIA**

**JOINING  
FORCES –  
ACCELERATING  
PROGRESS**



# SAVE THE DATE

IF THERE IS ONE  
EVENT YOU NEED  
TO ATTEND IN 2014,  
IT'S THE WORLD CANCER  
CONGRESS

**3-6 DECEMBER  
2014**

PRELIMINARY PROGRAMME NOW AVAILABLE

PLEASE VISIT  
**WORLDANCONGRESS.ORG**



Hosted by




Held in conjunction with the Clinical Oncology Society of Australia (COSA) Annual Scientific Meeting



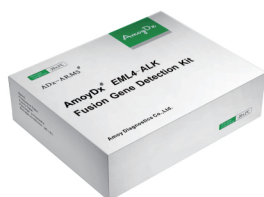## ADx-ARMS® Real-time PCR Technology

- One-step procedure
- Results in 90 minutes
- Detects 1% mutant allele
- GMP-compliant manufacturing
- ISO13485-certified laboratory
- CFDA approved for clinical use in China
- Compatible with multiple PCR instruments



## Amoy Diagnostics Product List

TEST	GENE	TEST	GENE
Mutation Detection	EGFR	Gene Expression	RET
	KRAS		TP 53
	BRAF		ERCC1
	EML4-ALK		TYMP
	PIK3CA		STMN1
	ROS1		TYMS
	HER2		TOP2A
	MEK1		TUBB3
	JAK2		BRCA1
	BCR-ABL		DPD
	PDGFRA		RRM1
	C-KIT	DNA/RNA Extraction	FFPE DNA
	AKT		FFPE RNA
	RET		FFPE DNA/RNA
	TP 53		Blood DNA

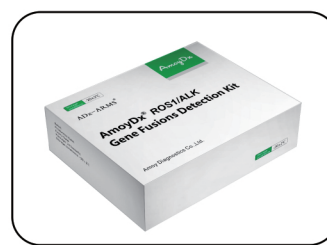

**EML4-ALK Kit**



**ROS1 Gene Fusions Kit**

- ◆ 21 ALK gene fusions and 14 ROS1 gene fusions can be detected
- ◆ Simultaneous testing for ROS1 and ALK with multiple sample types
- ◆ ROS1 test kits being used for pivotal clinical trial of Pfizer's crizotinib



**ROS1/ALK Gene Fusions Kit**

## Articles using Amoy Diagnostics

- 1) The diagnostic accuracy of pleural effusion and plasma samples versus tumour tissue for detection of EGFR mutation in patients with advanced non-small cell lung cancer: comparison of methodologies (*J Clin Pathol* 2013)
- 2) Targeted resequencing reveals ALK Fusions in non-small cell lung carcinomas detected by FISH, immunohistochemistry, and real-time RT-PCR: a comparison of four methods (*BioMed Research International* 2013)
- 3) A comparison of ARMS and direct sequencing for EGFR mutation analysis and tyrosine kinase inhibitors treatment prediction in body fluid samples of non-small-cell Lung cancer patients (*Journal of Experimental & Clinical Cancer Research* 2011)
- 4) Analysis of driver mutations in female non-smoker Asian patients with pulmonary adenocarcinoma (*Cell Biochem Biophys* 2013)
- 5) Association of EGFR mutation or ALK rearrangement with expression of DNA repair and synthesis genes in never-smoker women with pulmonary adenocarcinoma (*Cancer* 2012)
- 6) Comparative screening of K-ras mutations in colorectal cancer and lung cancer patients using a novel real-time PCR with ADx-K-ras kit and sanger DNA sequencing (*Cell Biochemistry and Biophysics* 2012)
- 7) Oncogenic driver mutations in patients with non-small-cell lung cancer at various clinical stages (*Annals of Oncology* 2012)
- 8) KIF5B-RET Fusions in Chinese Patients With Non-Small Cell Lung Cancer (*Cancer* 2013)