

Comparison between Results of Microdiscectomy and Open Discectomy in Management of High-Level Lumbar Disc Prolapse

Amr Abdelmonam Abdelaziz Mostafa Elkatatny*, Tarek M. Hamdy, Khaled Mamoun Moenes

Department of Neurosurgery Kasr Alainy Medical school, Cairo University, Cairo, Egypt

Abstract

Citation: Mostafa Elkatatny AAA, Hamdy TM, Moenes KM. Comparison between Results of Microdiscectomy and Open Discectomy in Management of High-Level Lumbar Disc Prolapse. Open Access Maced J Med Sci. 2019 Sep 15; 7(17):2851-2857. <https://doi.org/10.3889/oamjms.2019.679>

Keywords: High-level lumbar disc prolapse; Microdiscectomy; Open discectomy

***Correspondence:** Amr Abdelmonam Abdelaziz Mostafa Elkatatny, Department of Neurosurgery Kasr Alainy Medical school, Cairo University, Cairo, Egypt. E-mail: amramostafa2013@gmail.com

Received: 21-Apr-2019; **Revised:** 08-Jun-2019; **Accepted:** 09-Jun-2019; **Online first:** 30-Aug-2019

Copyright: © 2019 Amr Abdelmonam Abdelaziz Mostafa Elkatatny, Tarek M. Hamdy Khaled Mamoun Moenes. This is an open-access article distributed under the terms of the Creative Commons Attribution-NonCommercial 4.0 International License (CC BY-NC 4.0)

Funding: This research did not receive any financial support

Competing Interests: The authors have declared that no competing interests exist

AIM: This work aims to compare between results of microdiscectomy and open discectomy in management of high-level lumbar disc prolapse.

METHODS: This is a controlled randomised study, where patients having upper lumbar disc herniations were evaluated preoperatively both clinically and radiologically, randomisation was planned to perform open discectomy in odd number patients and to perform microdiscectomy in even number patients, patients were evaluated and followed up for deficits and outcomes.

RESULTS: We operated ten patients in this study, five cases were operated upon with microdiscectomy, and five cases were operated upon with open discectomy, the median age of presentation in this study was 44 years, there were five males and five females, postoperative pain improvement was better in microdiscectomy. Hospital stay, blood loss, bone loss and postoperative complications were less in microdiscectomy.

CONCLUSION: Microdiscectomy allows good surgical visualisation and is less traumatic to the involved tissues. The results of this study indicated that microsurgery reduces hospitalisation time, improves the overall surgery-related outcome. The main differences between the two procedures were the length of the incision and blood loss. We found that lumbar microdiscectomy allows patients earlier return to work and normal life with less reliance on postoperative narcotic analgesic agents.

Introduction

This is a prospective study of 10 cases of high-level lumbar disc prolapse which were surgically managed in the period between May 2014 and April 2015 in the neurosurgery department at Cairo university hospitals.

The rationale of this work was to compare the results of microdiscectomy and open discectomy in management of high-level lumbar disc prolapse.

This is a controlled randomised study where randomisation was planned to perform open discectomy in odd number patients while microdiscectomy was performed in even number patients.

Inclusion criteria: 1) Single level high lumbar disc prolapse (L1-2 or L2-3) and 2) Patients indicated for surgery with intractable low back pain associated

with radiculopathy.

Exclusion criteria: 1) Multiple levels high disc prolapses; 2) Recurrent cases (previous disc surgery); 3) Presence of another pathology; 4) Morbid obese patients, and 5) Patients with osteoporosis.

The following methods were applied for the studied cases:

History Taking

Personal history including name, age and sex, symptomatology including back pain, lower limb pain and claudication pain.

Pain analysed according to site, character, severity and distribution.

Patients were assessed for presence or absence of motor deficit, sensory deficit and cauda equina.

Examination

The patients were examined for 1. Vital signs (pulse, arterial blood pressure, temperature and respiratory rate); 2. Assessment of the pain. (Site, character, referral, severity, exaggerating and relieving factors); 3. Assessment of the presence of motor weakness, sphincteric manifestations and other neurological examination; and 4. Back examination and deformity and associated medical conditions.

Table 1: Visual analogue pain scale (Flynn D et al, 2004)

0	2	4	6	8	10
No hurt	Hurts a little bit	Hurts a little more	Hurts even more	Hurts whole lot	Hurts as much as you can imagine

Investigations

Routine laboratory investigations: During preoperative preparation of the patients, all cases were subjected to complete blood picture, blood glucose, liver and kidney functions, bleeding profiles and serum electrolytes, ESR, CRP.

Table 2: Master Table 1

Case	Age	Sex	Site of disc prolapse	Neurological deficit	Back pain	Femoralgia
1	56	M	L2-3	Motor & sensory deficit	+	+
2	34	M	L2-3	Sensory hypoesthesia	+	+
3	46	F	L1-2	Sensory deficit	-	+
4	44	M	L1-2	-	+	+
5	44	F	L1-2	Sensory hypoesthesia	+	+
6	24	F	L2-3	-	-	+
7	38	M	L1-2	Sensory hypoesthesia and urinary affection	+	+
8	37	M	L2-3	-	+	+
9	42	F	L2-3	Motor and sensory deficit	+	+
10	33	F	L2-3	-	-	+

Radiological investigations

1) Plain X-ray lumbosacral spine: - Anteroposterior view; - Lateral view; - Both oblique views to detect fracture pars; and - Dynamic flexion and extension views for determination of stability.

2) Magnetic resonance imaging lumbosacral spine. It was performed in all cases to define: - Cause and degree of neurological compression; - Bone marrow changes: Presence of Modic Type 1 changes suggests instability (hypointense on T1-weighted imaging and hyperintense on T2-weighted imaging and were shown to represent bone marrow oedema and inflammation); - Any abnormality of the pars interarticularis, pedicles, or facet joints; and - Nerve structures, including those exiting neural foramina, and the spinal canal should be evaluated for stenosis.

Operative management: five cases were operated upon with microdiscectomy and five cases were operated upon with open discectomy.

Postoperative Management: - Postoperative antibiotics (cephalosporins, penicillin) were continued for two days postoperatively; - Narcotic analgesics were used in the first twenty-four hours; - Oral diet was started in the second day; and - Patients were

ambulant in the first postoperative day.

Follow-Up

A. Clinical follow-up: immediately after surgery and on an outpatient basis.

B. Radiological follow-up: immediate postoperative and after six months.

Included: Plain radiography anteroposterior & lateral radiograph

Table 3: Master Table 2

Case no	Total laminectomy	Hemi laminectomy	Total facetectomy	Medial facetectomy	Blood loss during surgery	Time of surgery	Hospital stay
1	+	-	+	-	450 cc	110 minutes	2 days
2	-	+	-	+	250cc	133 minutes	2 days
3	+	-	+	-	500 cc	115 minutes	3 days
4	-	+	-	+	200cc	122 minutes	2 days
5	+	-	+	-	700 cc	120 minutes	2 days
6	-	+	-	-	150 cc	127 minutes	One day
7	+	-	+	-	500 cc	115 minutes	4 days
8	-	+	-	+	200 cc	130 minutes	2 days
9	+	-	+	-	400 cc	130 minutes	2 days
10	-	+	-	-	150 cc	125 minutes	One day

Clinical Evaluation:

- Patients are evaluated according to the presence or absence of neurological deficit, and sphincteric affection and - Patients are evaluated according to pain improvement using a visual analogue scale for pain immediately after surgery and after six months.

Table 4: Master Table 3

No.	The clinical indication of surgery		Dural tear	Clinical outcome	
	Intractable pain (LBP and LL pain)	Motor deficit		Post-operative pain (VAS)	Neurological deficit due to surgery
1	+	-	-	2	-
2	+	-	-	2	-
3	+	+	-	4	-
4	+	-	-	2	-
5	+	-	+	4	-
6	+	-	-	2	-
7	+	-	+	2	-
8	+	-	-	2	-
9	+	+	-	4	-
10	+	-	-	2	-

Results

The data collected from 10 cases of high-level lumbar disc prolapse were analysed prospectively. In our study, 50% of the cases were females, while 50% of the cases were males.

The mean age for patients that had upper lumbar disc surgery was (44.92) years old, the mean height for them was (162.6) cm, the mean weight was (82.8) kg, the mean BMI was 31.42.

Table 5: The average age, weight, height and duration of symptoms

	Minimum	Maximum	Mean
Age in years	24	56	44.92
Height in cm	150.00	175.00	162.60
Weight in Kg	65.00	95.00	82.80
BMI	27.06	42.22	31.42
Duration in Months	0.20	96.00	13.03

Five cases of high-level lumbar disc prolapse were operated upon with open discectomy; the other five cases were operated upon with microdiscectomy.

Table 6: Radiology of the herniated disc

	Calcified disc	Non calcified disc	Central	Para central	Diffuse	Focal
L1-2	3	1	2	2	1	3
L2-3	3	3	2	4	2	4

Incidence of L1-2 disc prolapse was 40% while the incidence of L2-3 was 60%.

Incidence of left-sided disc prolapse was 50%, right-sided disc prolapse was 10%, central disc prolapse was 40%.

Femoralgia was the most common indication for surgery 100% followed with low back pain 70%, sensory deficit 60%, motor deficit 20% and urinary affection 10%.

Table 7: Surgical procedure

	L1-2	L2-3
Open discectomy	3	2
Microdiscectomy	1	4

Total laminectomy was done in 50% of cases & hemilaminectomy was done in 50% of cases & unilateral total facetectomy was done in 50% of cases and medial facetectomy was done in 40% of cases.

Table 8: Differences between microdiscectomy and open discectomy

	Microdiscectomy	Open discectomy
Average blood loss	190 cc	510 cc
Average hospital stays	1,8 day	2,9 day
Average time of surgery	127 minutes	105 minutes
Average pain improvement (VAS)	2	2,3
Postoperative complications	0	Two cases of dural tear

Case No 1: Open Discectomy

History: Male patient 56 years old.

Complaint: severe right femoralgia for 4 months according to the pain scale (8).

Examination: weakness GIV in right knee extension and hypoesthesia in right L2, 3, 4 roots.

Diagnosis: L2-3 disc prolapse.

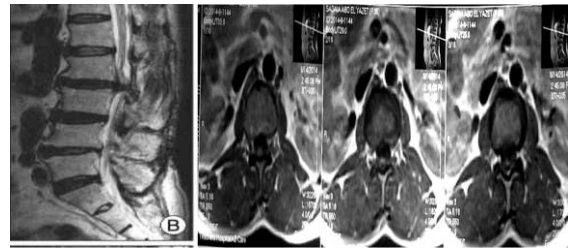


Figure 1: Preoperative MRI lumbar spine T2 axial and sagittal showing L2-3 disc prolapse

Operation: total laminectomy, facetectomy and L2-3 discectomy.

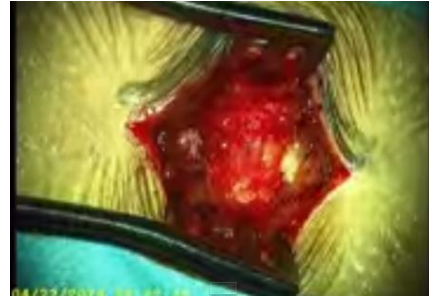


Figure 2: Intraoperative image showing skin incision during open discectomy

Postoperative: pain improved according to analogue pain scale [4].

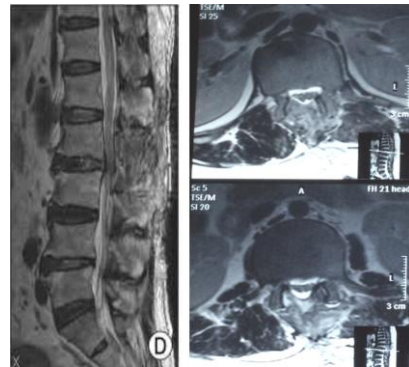


Figure 3: Postoperative MRI T2 axial and sagittal lumbar spine showing L2 total laminectomy and L2-3 discectomy

Case No. 2: Microdiscectomy

History: male patient 34 years old.

Complaint: Low back pain and severe pain in the lateral aspect of thigh for one month according to analogue pain scale hurts a whole lot [8].

Diagnosis: L2-3 disc prolapse.

Examination: FMP, hypoesthesia in the lateral aspect of the thigh and positive femoral stretch test.

Operation: hemilaminectomy, medial facetectomy and L2-3 microdiscectomy.

Postoperative: pain improved according to the scale hurts a little bit [2].

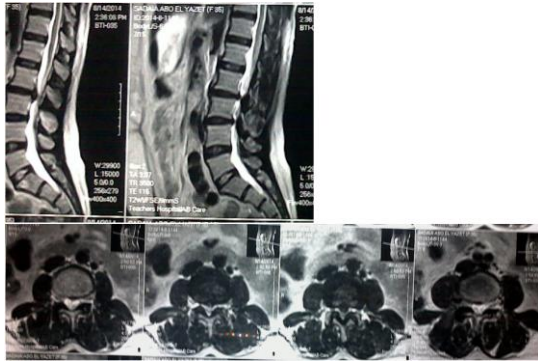

Figure 4: Preoperative MRI lumbar spine T2 axial and sagittal showing L2-3 disc prolapse

Discussion

Unique characteristics of upper lumbar disc herniation include ill-defined polyradiculopathies that cannot be clearly categorised into typical muscle group weakness or reflex deficits [1]. These polyradiculopathies may be associated with a narrower upper lumbar spinal canal compared with the lower spinal canal, resulting in compromise of multiple roots by a single disc herniation. Clinical symptoms are quite variable, localised sensory change or pain was rarely demonstrated [2].

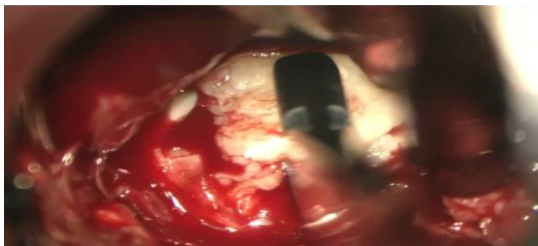


Figure 5: Intraoperative image showing disc excision during microdiscectomy

The positive femoral stretch test is known as a relatively good diagnostic method in 84 to 94% of upper lumbar disc herniation, Pain provocation by the femoral stretch test is believed to be caused by stretching of the femoral nerve. Because the L2, L3, or L4 spinal nerve roots are the main components of the femoral nerve, cases with symptomatic upper lumbar disc herniation may have more opportunities to show positive results for the femoral stretch test compared to cases with lower lumbar disc herniations. Location of the conus medullaris in association with a high lumbar disc herniation may be a cause of urinary affection [3].

MRI helps reveal the location of the conus medullaris and lesions of the upper lumbar level more clearly. Radiographic techniques, including MRI and CT, are essential for the diagnosis of the lesion and identification of the precise location. Therefore, the

preoperative careful investigation would be useful for differential diagnosis and prevention of misdiagnosis in cases of upper lumbar disc herniation [3].

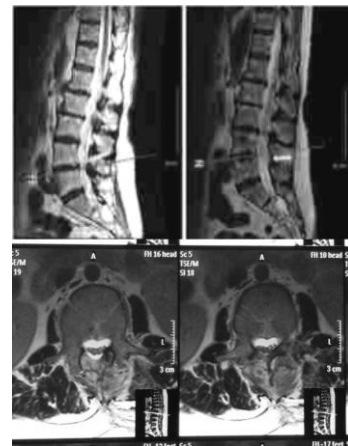

Figure 6: Postoperative MRI T2 axial and sagittal lumbar spine showing L2 hemilaminectomy and L2-3 discectomy

Compared with those of lower levels, upper lumbar disc herniations have a less favourable outcome after surgery. Spinal canals are narrower than those of lower levels, which may compromise multiple spinal nerve roots or conus medullaris. Lengths of the lamina are shorter, the location of the pain varies, and direct cord compression may occur. Because of this unique anatomy, selection of a surgical approach is difficult [4].

The choice of the surgical approach is an important issue when treating patients with disc herniation in the upper lumbar spine [5].

Factors considered important for the determination of the surgical approach include disc size, location, the extent of calcification, surgeon's experience, degree of spinal cord deformation and the general medical condition of the patient. Radiologic findings for L1-L2 and L2-L3 disc herniations are one of the important criteria for the selection of the surgical approach [4].

In the literature, we could not find reports on operation rates in large series of cases being treated by microdiscectomy or open discectomy in management of high-level lumbar disc prolapse, *Sanderson et al.'s* study [2] reported a total of 21 surgeries and *Saberi et al.'s* study [7] reported a total of 28 surgery cases. Otherwise, most papers only reported a small number of cases.

To supplement knowledge in this field, we describe here the results of 10 patients with high-level lumbar disc prolapse where managed in the neurosurgery department, Cairo University Hospitals.

The mean age of this study was 44 years which is close to the study of *Sanderson et al.'s* study [2], who reported a mean age of 46 years, lower than *Krauss et al.'s* study [6], who reported mean age of 54 years and *Choi et al.'s* study [5] who reported mean

age of 52 years.

In our study, in regard to sex distribution, there are 5 females and 5 males. In *Krauss et al.*'s study [6], there were 11 males and 7 females, in *Saberi et al.*'s study, there were 17 females, 11 males and in *Sanderson SP et al.*'s study [2], there were 8 females and 13 males.

As regards to the clinical picture, in our study we noted that femoralgia was reported in all cases, low back pain in 70%, sensory affection in 60% and motor deficit in 20% compared to the findings of *Choon et al.*, study [8] and *Summers et al.*, study [9] who reported predominance of femoralgia in 87%, back pain in 54%, neurological deficit in 40% in their cases. *Tokuhashi et al.* the study [10] reported femoralgia in 85% of cases.

Sensory manifestations were the most common neurological deficit encountered in our study, while motor deficits were reported in two cases. The indication of surgery was intractable pain in the back and legs, this coincides with *Saberi H et al.*, study [7], who reported that the most common indication for surgery was intractable pain and *AhnY et al.*, study [11], who reported that the most common indication for surgery was intractable pain.

Of 10 cases of the high-level lumbar disc, L2-3 disc prolapse was present in six cases, and L1-2 was present in four cases. *Saberi H et al.*, the study [7], reported that L2-3 disc prolapse was present in 75% of cases and *AhnY et al.*, the study [11] reported that L2-3 disc prolapse was present in 45% of cases.

The femoral stretch test was present in 70% of our cases. *Krauss WE et al.*, the study [6], reported that femoral stretch test was present in 65% of cases and *Choi et al.*, the study [5], reported that femoral stretch test was present in 70% of cases.

Five of our cases were operated with microdiscectomy and five cases with open discectomy, in *Saberi H et al.*, the study [7] eleven cases operated with microdiscectomy and In *Choi et al.*, the study [5] seven cases operated with microdiscectomy.

As regard to perioperative factors, in our study, total laminectomy was done in 100% of cases of open discectomy. Hemilaminectomy was done in 100% of cases of microdiscectomy. Total facetectomy was done in 100% of cases of open discectomy, and medial facetectomy was done in 80% of cases of microdiscectomy.

In *AhnY et al.*, study [11] total laminectomy was done in 65% of cases, hemilaminectomy was done in 35% of cases and total facetectomy was done in 40% of cases, In *Sanderson SP et al.*, study [2] total laminectomy was done in 70% of cases of open discectomy versus 60% in the study of *Choi JW et al.*, study [5].

Shin DA et al., the study [12] reported that

microdiscectomy procedure is less invasive than open discectomy, causes less muscle damage and less back pain

Our average blood loss in microdiscectomy was 190 cc versus 510 ccs in open discectomy, in *Kambin P* study [1], average blood loss in microdiscectomy was 230 cc versus 470 ccs in open discectomy, in *Kanayama et al.*, [14] study, average blood loss in microdiscectomy was 150 cc versus 320 cc in open discectomy.

Hospital stay was for our patients was 1,8 days in microdiscectomy versus 2,9 days in open discectomy, in *Ryang A et al.*, study [16] and *Kambin P* study [1], average hospital stay in microdiscectomy was less than average hospital stay in open discectomy, no significant difference was found in *German et al.*, [13] and *Porchet et al.*, [15] studies.

Average time of surgery was 127,4 minutes in microdiscectomy versus 105,2 minutes in open discectomy; this means no statistically significant difference between the two procedures, this is similar to *German et al.*, [13] and *Porchet et al.*, [15] studies.

As regard to perioperative factors, our study was different from the following studies, *Schneider C et al.*, the study [17] who reported that although minimally invasive micro discectomies are appealing to many patients; its superiority over standard open microdiscectomy has not been demonstrated.

Wu et al., the study [18] concluded in their retrospective study that minimally invasive microdiscectomy affords optimal post-operative outcomes and is superior when compared to open microdiscectomy; this is similar to our study.

Harrington and French study [19] founded that preoperative parameters were similar. In their study, the minimally invasive group had less narcotic usage and shorter length of stay, but they did not conclude that one technique was better than the other.

German et al., [13] and *Porchet et al.*, [15] studies show that there is no significant difference between minimally invasive and open micro discectomies.

In *German et al.*, [13] and *Porchet et al.*, [15] studies Forty-nine patients underwent minimally invasive discectomy, and 123 patients underwent open microsurgical discectomy. At baseline, the groups did differ significantly concerning age but did not differ concerning height, weight, sex, body mass index, level of radiculopathy, side of radiculopathy, insurance status or type of preoperative analgesic use.

No, statistically significant differences were identified in operative time, rate of cerebrospinal fluid leak, or need for a physical therapy consultation. Statistically, significant differences were identified in length of stay, estimated blood loss, post-anaesthesia care unit narcotic use, and need for admission to the

hospital [13], [14].

Kanayama et al., the study [14] reported that no significant differences between the 2 surgical procedures in the frequency of use of an analgesic agent after surgery, the pre- and postoperative Japanese Orthopaedic Association scores or postoperative Visual Analogue Scale for sciatica. Statistically significant differences were observed in the operation time, amount of bleeding, duration of hospitalisation, and postoperative VAS for lumbar pain.

Righesso O et al., the study [20], reported statistically significant differences found for size of the incision, length of hospital stays, and operative time between microdiscectomy and open discectomy.

As regard to postoperative pain improvement, in our study, average pain improvement in microdiscectomy was 2 versus 3, 2 in open discectomy according to the analogue pain scale.

Arts MP et al., the study [21] reported that both Open discectomy and microdiscectomy lead to a substantial and equivalent long-term improvement in leg pain. Adequate decompression, regardless of the operative approach used, maybe the primary determinant of pain relief — the major complaint of many patients with radiculopathy. Incidental durotomies occurred significantly more frequently during MID, but total complications did not differ between the techniques.

Pain improvement in microdiscectomy was better than open discectomy according to the analogue pain scale. This was similar to results in *Cole 4th* [22], *Ryang et al.*, [16], *Kambin P* [1] and *Shin DA et al.*, [12] studies.

Cole 4th study [22] reported that Lumbar minimally invasive discectomy is our preferred surgical technique for symptomatic disc herniations in this patient population. Decreased incision length and a trend toward reduced infectious complications are the primary reasons. We feel that, given the comorbidities often found in this patient population, a minimally invasive technique will supplant open approaches shortly.

Kambin P study [1] found that advantages of microdiscectomy include: 1) two-hour operative time; 2) negligible blood loss; 3) avoidance of significant scarring in the spinal canal; and 4) anterolateral fenestration of the annulus for continuing relief of intradiscal pressure and nerve root decompression.

Shin et al., the study [12] reported that microdiscectomy procedure is less invasive than open discectomy, and causes less muscle damage and less back pain.

Schizas et al., the study [23] reported that microdiscectomy is at least as effective as open discectomy for the treatment of uncontained or large contained disc herniations, although the advantages

over the open technique are short-lived and did not reach significance. Nonetheless, microdiscectomy seems to be a safe procedure.

In our study, the only complications were two cases of a dural tear in two cases of open discectomy; those two complications were managed with the closure of the tear intraoperative, tight closure of the fascia and placement of a drain in the two cases there was no leak postoperatively. This was different from *Ryang et al.*, the study [16].

Ryang et al., the study [16] reported that 107 patients (67 males, 40 females) underwent microdiscectomy for the prolapsed lumbar intervertebral disc. Follow up ranged from 2 to 40 months with a mean follow up 12.9 months. Seventy-six patients had an excellent outcome, 22 patients had a good outcome, 5 patients had a fair outcome, and 3 patients had a poor outcome. One patient with a long dural tear required conversion to a standard microdiscectomy and was excluded from outcome assessment. Complications included dural puncture with K-wire (1), dural tear (2), superficial wound infection (3), discitis (4) and recurrent disc prolapse (5).

Righesso et al., the study [20] reported that in microdiscectomy complications were less than those in open discectomy as regard to the occurrence of wound infection and postoperative back pain.

From the above studies our results were close to these in *Ryang A et al.*, study [16], *Shin DA et al.*, study [12], *Kambin P* study [1], *Righesso O et al.*, study [20], *Cole 4th* study [22] and *Wu X et al.*, study [18] as regard to hospital stay, postoperative pain, postoperative recovery, blood loss and time of surgery.

In conclusion, clinical features of upper lumbar disc herniations were different from those of lower lesions. Due to unexpectedly large differences in neurologic findings and clinical manifestations among the herniated disc levels, an accurate workup is needed to avoid misdiagnosis. In our series, a discectomy was successfully performed by hemi or total laminectomy. In upper lumbar disc herniation, favourable clinical outcomes can be expected by adequate selection of surgical methods in consideration of each herniated disc nature such as consistency, direction, and distribution.

We found a significant difference between minimally invasive microdiscectomy and open discectomy for lumbar disc herniation in perioperative factors and outcomes with regards to blood loss, neurological function, complication rate and length of stay in hospital or pain improvement.

Microdiscectomy allows good surgical visualisation and is less traumatic to the involved tissues. Interestingly, the results of this study indicated that microsurgery reduces hospitalisation time, improves the overall surgery-related outcome.

The main differences between the two procedures were the length of the incision and blood loss. We found that lumbar microdiscectomy allows patients earlier return to work and normal life with less reliance on postoperative narcotic analgesic agents.

References

- Kambin P, Savitz MH. Arthroscopic microdiscectomy: an alternative to open disc surgery. *The Mount Sinai journal of medicine, New York*. 2000; 67(4):283-7.
- Sanderson SP, Houten J, Errico T, Forshaw D, Bauman J, Cooper PR. The unique characteristics of "upper" lumbar disc herniations. *Neurosurgery*. 2004; 55(2):385-9. <https://doi.org/10.1227/01.NEU.0000129548.14898.9B> PMID:15271245
- Lee SH, Choi S. L1-2 Disc Herniations: Clinical Characteristics and Surgical Results. *Journal of Korean Neurosurgical Society*. 2005; 38(3):196-201.
- Ahn Y, Lee SH, Park WM, Lee HY, Shin SW, Kang HY. Percutaneous endoscopic lumbar discectomy for recurrent disc herniation: surgical technique, outcome, and prognostic factors of 43 consecutive cases. *Spine*. 2004; 29(16):E326-32. <https://doi.org/10.1097/01.BRS.0000134591.32462.98> PMID:15303041
- Choi JW, Lee JK, Moon KS, Hur H, Kim YS, Kim SH. Transdural approach for calcified central disc herniations of the upper lumbar spine. *Journal of Neurosurgery: Spine*. 2007; 7(3):370-4. <https://doi.org/10.3171/SPI-07/09/370> PMID:17877277
- Krauss WE, Edwards DA, Cohen-Gadol AA. Transthoracic discectomy without interbody fusion. *Surgical neurology*. 2005; 63(5):408-9. <https://doi.org/10.1016/j.surneu.2004.06.026> PMID:15883057
- Saberi H, Isfahani AV. Higher preoperative Oswestry Disability Index is associated with better surgical outcome in upper lumbar disc herniations. *European Spine Journal*. 2008; 17(1):117-21. <https://doi.org/10.1007/s00586-007-0527-3> PMID:17972115 PMCid:PMC2365528
- Choon SL, Chang JH, Sung WL, Yung TK, Dong HL, Mi YL. *Eur Spine J Volume*. 2009; 18:1637-1643. <https://doi.org/10.1007/s00586-009-1060-3> PMID:19533182 PMCid:PMC2899393
- Summers B, Mishra V, Jones JM. The flip test: a reappraisal. *Spine*. 2009; 34(15):1585-9. <https://doi.org/10.1097/BRS.0b013e3181aa1bf0> PMID:19564769
- Tokuhashi Y, Ajiro Y, Umezawa N. Follow-up of patients with delayed union after posterior fusion with pedicle screw fixation. *Spine*. 2008; 33(7):786-91. <https://doi.org/10.1097/BRS.0b013e31816956f7> PMID:18379406
- Ahn Y, Lee SH, Lee JH, Kim JU, Liu WC. Transforaminal percutaneous endoscopic lumbar discectomy for upper lumbar disc herniation: clinical outcome, prognostic factors, and technical consideration. *Acta neurochirurgica*. 2009; 151(3):199-206. <https://doi.org/10.1007/s00701-009-0204-x> PMID:19229467
- Shin DA, Kim KN, Shin HC. The efficacy of microendoscopic discectomy in reducing iatrogenic muscle injury. *Journal of Neurosurgery: Spine*. 2008; 8(1):39-43. <https://doi.org/10.3171/SPI-08/01/039> PMID:18173345
- German JW, Adamo MA, Hoppenot RG, Blossom JH, Nagle HA. Perioperative results following lumbar discectomy: comparison of minimally invasive discectomy and standard microdiscectomy. *Neurosurgical focus*. 2008; 25(2):E20. <https://doi.org/10.3171/FOC/2008/25/8/E20> PMID:18673050
- Kanayama M, Hashimoto T, Shigenobu K, Oha F, Yamane S. New treatment of lumbar disc herniation involving 5-hydroxytryptamine2A receptor inhibitor: a randomized controlled trial. *Journal of Neurosurgery: Spine*. 2005; 2(4):441-6. <https://doi.org/10.3171/spi.2005.2.4.0441> PMID:15871484
- Porchet F, Bartanusz V, Kleinstueck FS, Lattig F, Jeszenszky D, Grob D, Mannion AF. Microdiscectomy compared with standard discectomy: an old problem revisited with new outcome measures within the framework of a spine surgical registry. *European spine journal*. 2009; 18(3):360-6. <https://doi.org/10.1007/s00586-009-0917-9> PMID:19255791 PMCid:PMC2899328
- Ryang YM, Oertel MF, Mayfrank L, Gilsbach JM, Rohde V. Standard open microdiscectomy versus minimal access trocar microdiscectomy: results of a prospective randomized study. *Neurosurgery*. 2008; 62(1):174-82. <https://doi.org/10.1227/01.NEU.0000311075.56486.C5> PMID:18300905
- Schneider C, Krayenbühl N, Landolt H. Conservative treatment of lumbar disc disease: patient's quality of life compared to an unexposed cohort. *Acta neurochirurgica*. 2007; 149(8):783-91. <https://doi.org/10.1007/s00701-007-1114-4> PMID:17624490
- Wu X, Zhuang S, Mao Z, Chen H. Microendoscopic discectomy for lumbar disc herniation: surgical technique and outcome in 873 consecutive cases. *Spine*. 2006; 31(23):2689-94. <https://doi.org/10.1097/01.brs.0000244615.43199.07> PMID:17077737
- Harrington JF, French P. Open versus minimally invasive lumbar microdiscectomy: comparison of operative times, length of hospital stay, narcotic use and complications. *Minimally Invasive Neurosurgery*. 2008; 51(01):30-5. <https://doi.org/10.1055/s-2007-1004543> PMID:18306129
- Righesso O, Falavigna A, Avanzi O. Comparison of open discectomy with microendoscopic discectomy in lumbar disc herniations: results of a randomized controlled trial. *Neurosurgery*. 2007; 61(3):545-9. <https://doi.org/10.1227/01.NEU.0000290901.00320.F5> PMID:17881967
- Arts MP, Peul WC, Brand R, Koes BW, Thomeer RT. Cost-effectiveness of microendoscopic discectomy versus conventional open discectomy in the treatment of lumbar disc herniation: a prospective randomised controlled trial [ISRCTN51857546]. *BMC musculoskeletal disorders*. 2006; 7(1):42. <https://doi.org/10.1186/1471-2474-7-42> PMID:16696861 PMCid:PMC1475863
- Cole IV JS, Jackson TR. Minimally invasive lumbar discectomy in obese patients. *Neurosurgery*. 2007; 61(3):539-44. <https://doi.org/10.1227/01.NEU.0000290900.23190.C9> PMID:17881966
- Schizas C, Tsiridis E, Saksena J. Microendoscopic discectomy compared with standard microsurgical discectomy for treatment of uncontained or large contained disc herniations. *Operative Neurosurgery*. 2005; 57(suppl_4):ONS-357. <https://doi.org/10.1227/01.NEU.00000176650.71193.F5> PMID:16234685