

CASE REPORT

Thrombus aspiration without stenting in a patient with anterior STEMI: Regression and healing of an unstable plaque assessed by OCT at 24 months of follow-up

Avtandil Babunashvili¹  | Samir Pancholy²  | Tamara Babunashvili¹ | Alexander Prokhorov¹

¹Center of Endosurgery, Moscow, Russian Federation

²Geisinger Commonwealth School of Medicine, The Wright Center for Graduate Medical Education, Scranton, PA, USA

Correspondence

Avtandil Babunashvili, Center of Endosurgery, 62 shosse entuziastov, 111123, Moscow, Russian Federation.
Email: avtandil.babunashvili@gmail.com

Funding information

This article is not funding by the research award/grant or Institutional/Industry representatives

Abstract

In selected cases, when STEMI caused by mild or moderate degree lesion with a large concomitant thrombus, additional OCT-guided PCI strategy after thrombus removal allows us to defer stenting with the follow-up natural healing of the vessel wall.

KEY WORDS

acute myocardial infarction, intravascular visualization, plaque healing, primary PCI

1 | INTRODUCTION

We report a case of natural healing of a ruptured unstable coronary plaque using serial OCT examination. The stenting procedure was deferred based on the angiographic and mainly OCT findings. A healing process of ruptured plaque without foreign body was studied using OCT at 3, 14, and 24 months after PCI.

Atherosclerotic plaque instability and rupture is the underlying pathophysiology for acute coronary syndrome (ACS). Previous autopsy and clinical studies have shown that inflammation and intensive expression of metalloproteinases are key factors for vulnerability of atherosclerotic plaque.^{1,2} Some pathological studies have shown that ruptured plaques commonly spontaneously heal, and the matrix within healed

plaque contains a proteoglycan-rich mass or collagen-rich scar, depending on the healing phase.³ Moreover, it is speculated, that repeated silent plaque rupture and subsequent healing results in an increased plaque burden and percent stenosis. Therefore, an understanding of the pathology of healing process is of paramount clinical importance. The healing process of infarct-related plaque has been previously described using pathologic and angioscopic examinations,⁴ with scant data available using high-resolution luminal and transmural imaging.

Contrary to angiography, new intracoronary visualization modalities—optical coherence tomography (OCT) and intravascular ultrasound (IVUS)—allow us a deep insight in vessel wall and plaque to obtain detailed information about plaque structure and tissue composition. Given the high

The work was performed at the Center of Endosurgery.

This is an open access article under the terms of the Creative Commons Attribution-NonCommercial License, which permits use, distribution and reproduction in any medium, provided the original work is properly cited and is not used for commercial purposes.

© 2021 The Authors. *Clinical Case Reports* published by John Wiley & Sons Ltd.

spatial resolution, OCT has been widely used for coronary plaque characterization,^{5,6} including detection and detailed morphological description of thin-cap fibroatheroma (TCFA) and unstable plaque rupture.^{7,8} Nevertheless, scant data are available on the natural course of a ruptured plaque leading to acute coronary syndrome. Rioufol G. et al have used IVUS to demonstrate the evolution and healing process of spontaneously ruptured atherosclerotic plaque. The authors evaluated 28 ruptured plaques in 14 patients.⁹ According to the study findings, only half of the ruptured plaques were healed, and the remodeling index was unchanged or considerably positive with a trend toward reduction of plaque burden.

It is not known how ruptured plaque and vessel wall at the site of the culprit lesion evolve in the follow-up period. This raises concerns about treatment issues in terms of the associated risk of thrombosis. While angiography data confirm the presence of thrombus on the culprit lesion after 6 months and even up to 18 months,¹⁰ late (18–24 months) follow-up is necessary for studying the natural history of atherothrombosis.

We describe the natural course of ruptured plaque causing an anterior STEMI, treated without balloon dilatation or stent placement, using OCT examination over a 24-month follow-up. To the best of our knowledge, this is the first description of the healing process of a ruptured plaque in vivo by OCT.

2 | CASE PRESENTATION

A 41-year-old female patient was admitted with anterior STEMI diagnosis 2.5 h after symptom onset. Taking into consideration the ECG changes (ST elevation in I, aVL, and V₂–V₆ leads) and increased Troponin I level on presentation (more than 15 times the upper limit of normal), emergency cardiac catheterization was initiated. After intravenous heparin administration (70 U/kg), coronary arteriography was done through the distal right radial access. Angiography revealed single vessel disease with a thrombus containing lesion at the ostium of the left anterior descending (LAD) artery (Figure 1).

Taking into account, large thrombus burden (Thrombus burden grade (G) >2 X Reference vessel diameter (RVD)¹¹) thrombus aspiration procedure was performed using a 6F ELIMINATE catheter (Terumo corporation, Japan) with good immediate result (Figure 2A). Control angiography revealed complete disappearance of the filling defect from vessel lumen, nonsignificant residual stenosis (minimal lumen diameter by QCA =3.23 mm), and antegrade TIMI III flow. A Iib/IIIa inhibitor agent eptifibatide (Integrillin) was administered and control OCT was performed thereafter. OCT revealed arterial lumen without thrombotic mass and clear signs of a ruptured unstable plaque with disruption of fibrous cap (defect size was 3.7 × 1.2 mm) overlaying

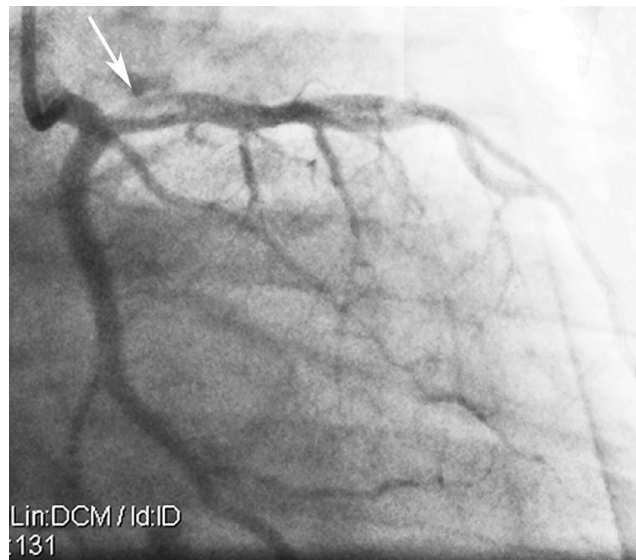


FIGURE 1 Initial arteriography revealed single vessel disease and a thrombus containing lesion at the LAD ostium (arrow)

a large necrotic core (Figure 2B). The plaque extended into the proximal part of left anterior descending artery (LAD) without involvement of its ostium and occupied nearly half of the lumen circumference (173.8°). 3D reconstruction image showed localization and size of ruptured area in LAD lumen and its 3D dimensional orientation to the circumflex artery ostium (Figure 2C). Mean Luminal Diameter (MLD) at the rupture site by OCT measurement was 3.2mm (vessel distal reference diameter (VRD) =3.8 mm) and minimal lumen cross-sectional area (CSA) 7.9 mm² (distal reference CSA – 8.6 mm²). Therefore, area stenosis calculated as distal reference CSA - minimal lumen CSA/distal reference CSA was 9%. Taking into account the geometry of the vessel lumen, absence of a thrombotic mass at the plaque rupture site and antegrade TIMI III flow, we decided not to implant stent. In postintervention period, DAPT was continued and the patient was discharged 10 days after initial admission. Due to hypercholesterolemia (cholesterol 6.25 mmol/L, LDL =3.85 mmol/L), high-intensity statin therapy (Rosuvastatin 40 mg once daily) was prescribed.

After 3 months, control angiography shown good patency of LAD and the arterial lumen at the site of plaque rupture remained without restenosis (Figure 3A). OCT revealed clear signs of an ongoing healing process of previously ruptured plaque with fibrotic transformation of the plaque, and a thin layered neointima (90–110 microns) covering its surface. Plaque burden decreased, but residual necrotic core still persisted (Figure 3B). Minimal lumen CSA was 5.97 mm². Despite the thin neointima covering the ruptured plaque surface, DAPT was continued for 12 months as recommended by the guidelines.

Angiography at 14 months revealed no restenosis (Figure 4A). OCT examination showed complete healing of

FIGURE 2 Angiography and OCT immediately after Interventional procedure: (A) arteriography after thrombus aspiration shows vessel lumen with minimal residual stenosis (“stent-like” result) and no signs of a thrombotic mass (arrow). (B) OCT examination after thrombus aspiration demonstrated unstable plaque with a large necrotic core (NC) and ruptured fibrotic cap (arrow). No concomitant thrombus seen along a ruptured plaque. (C) 3D reconstruction of the ruptured plaque area allows to see location of a rupture in LAD lumen (arrow) and its relation to the CxA ostium

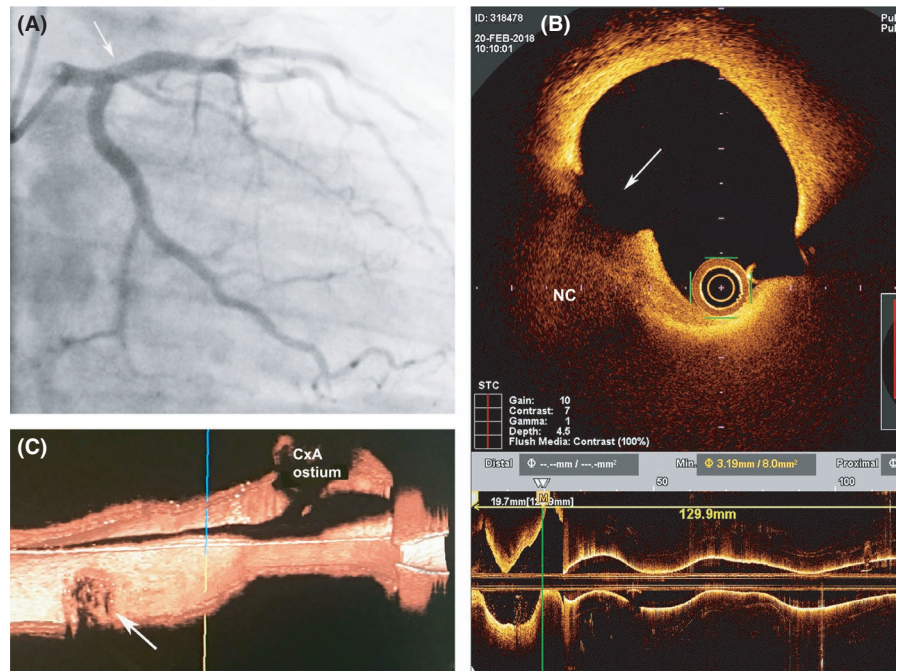
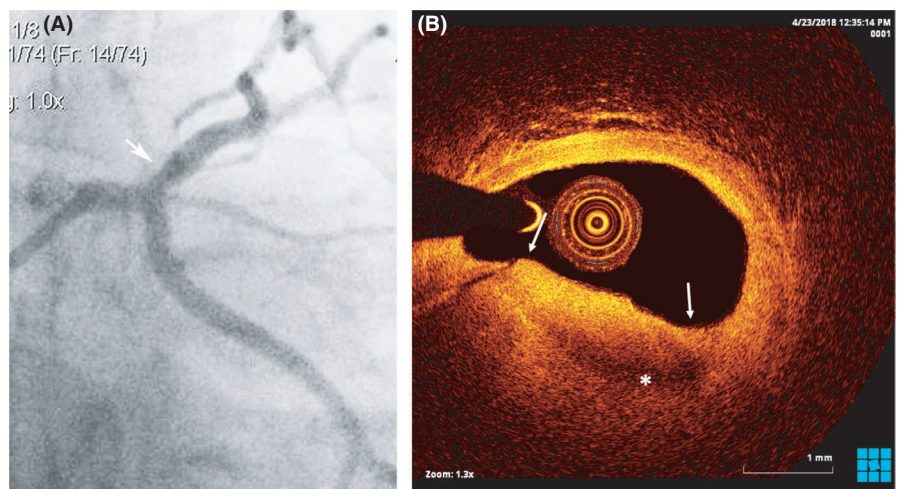


FIGURE 3 Control angiography and OCT examination after 3 months of the initial PCI procedure: (A) no restenosis was detected in LAD by angiography at the site of previous thrombus aspiration without stenting (arrow); (B) OCT examination shown complete endothelialization of a previously ruptured plaque surface (arrows), but residual necrotic core of the plaque still persisted (marked by an asterisk)



vessel wall at the site of previous plaque rupture. Plaque burden was significantly decreased and transformed into a small sized stable fibrotic plaque (Figure 4B). Minimal lumen CSA was 8.2 mm^2 , vessel wall CSA at the point of minimal lumen CSA was 10.5 mm^2 . Percent atheroma volume (PAV) and total atheroma volume (TAV) calculated as previously described¹² were 21.9% and 27.3 mm^3 , respectively. At 12-month follow-up patient had stopped DAPT, continued lipid-lowering therapy, and achieved guideline recommended target LDL and HDL levels.

24 months after initial procedure patient was admitted due to recurrent angina. Control angiography revealed no restenosis in LAD ostium at the site of thrombus aspiration (Figure 5A) and new lesion in RCA, which was stented successfully. Repeat OCT evaluation of LAD ostium revealed stable thick cap fibrotic plaque without lipid core (Figure 5B) occupying 115° (approximately 33%) of lumen circumference.

No significant vessel wall remodeling occurred in period between 14 and 24 months after primary PCI. Minimal lumen CSA and vessel wall CSA at the site of previous plaque rupture were 8.6 mm^2 and 11.0 mm^2 . Calculated PAV and TAV were 21.8% and 23.5 mm^3 , respectively.

3 | DISCUSSION

We describe the natural course of an unstable, ruptured plaque presenting as a STEMI, treated without subsequent mechanical angioplasty (instrumentation of the plaque) or stenting. Although the acute phase of the unstable plaque rupture is described comprehensively,¹³ the chronic phase or healing process of ruptured plaque has not been well defined in a live patient. Many studies describe dynamic changes of atherosclerotic plaque volume and composition using statin therapy

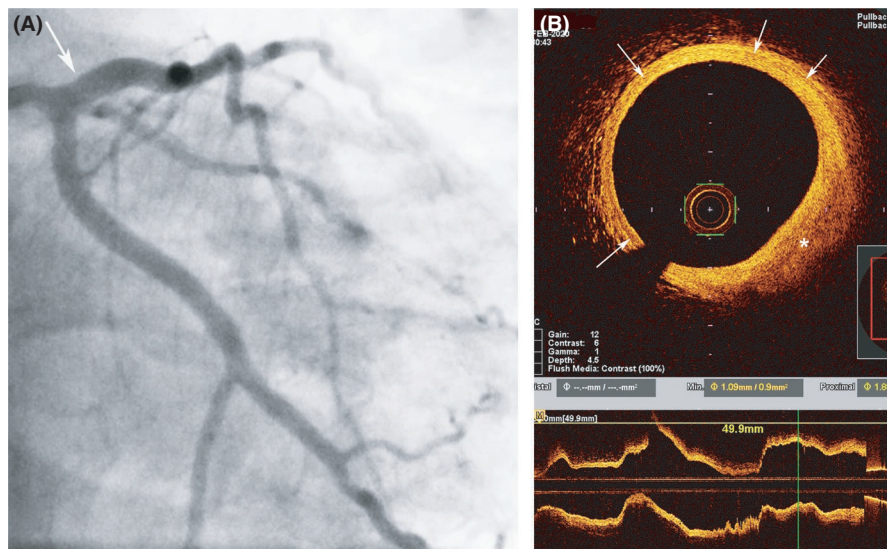


FIGURE 4 14-month follow-up result assessed by angiography and OCT: (A) control angiography shows LAD without restenosis after initial intervention (arrow). (B) OCT picture revealed small fibrotic plaque (asterisk) at the site of previously unstable and ruptured plaque

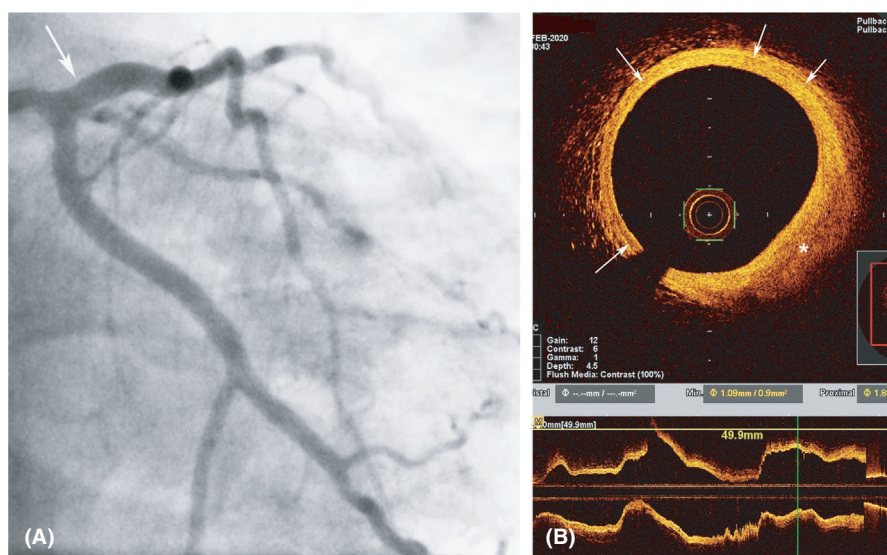


FIGURE 5 Control arteriography and OCT of the LAD 24 months later: (A) LAD without restenosis after primary coronary intervention (arrow). (B) Small stable plaque (asterisk) detected by OCT without significant changes in plaque size and tissue composition compared to 14-month follow-up result. Classic 3-layered structure of the vessel wall is clearly visible (media signed by arrows)

and subsequent serial IVUS visualization^{14–16} even in ACS patients,⁹ but none of them report changes and healing process of the ruptured unstable plaque using a high-resolution imaging modality such as OCT examination.

The role of plaque healing process in stenosis formation and progression has been determined in previous studies. Burke AP et al proposed that scar-like contraction of the healing fibrous tissue may be a cause of the negative remodeling often seen in severely stenosed arterial lumen.³ Some authors indicate the silent plaque rupture and subsequent healing as a major mechanism for plaque growth and chronic stenosis formation.¹⁷ This suggestion is based on multilayered plaque appearance consistent with a history of incorporation of organized thrombus formed on ruptured or eroded plaque.³

Minimal positive remodeling of vessel lumen was detected in our case between 16 and 24 months of follow-up period. Complete endothelialization of a ruptured plaque occurred 3 months after initial PCI, but residual mass of necrotic core

was still observed. Moreover, significant regression of a plaque burden was confirmed by OCT up to 24 months after coronary intervention and concomitant high-intensity lipid-lowering therapy. No significant changes were noted in plaque burden, atheroma composition, vascular geometry and atheroma percent or total volume between 12 and 24 months after PCI. This could imply that at 12 months, the ruptured plaque had stabilized and did not change significantly morphologically in the subsequent period. Interestingly, the classical three-layered OCT sign of the arterial wall appeared in follow-up accompanied by the process of atherosclerotic plaque regression.

Several studies have shown that lipid-lowering therapy with statins is associated with plaque stabilization and a considerable number of studies demonstrated plaque regression with statins or non-statin lipid-lowering therapy.^{18,19} However, in all these studies IVUS was used as the only intravascular visualization technique for measuring the atheroma percent or total volume changes in the follow-up period,

as well as for assessment of plaque composition changes. Some authors studied the plaque healing process using OCT examination¹⁶ but in published articles using both imaging modalities only non-culprit segments were included in the analysis.²⁰ Therefore, characteristics of the healing process of a clinically manifested ruptured unstable plaque *in vivo* remained unknown. To our best knowledge, this is a first report of the serial OCT examination for detailed *in vivo* assessment of the plaque regression and a vessel wall regeneration up to 24 months after initial primary PCI without plaque/stenosis dilatation or stenting.

Indeed, emergency PCI with stent implantation is the centerpiece of guideline-directed therapy in STEMI patients. Nevertheless, F. Prati et al support the idea of a “stent-free” treatment strategy after thrombectomy, if OCT and angiography reveal plaque erosion with intact fibrous cap and hemodynamically insignificant residual stenosis after thrombus aspiration.²¹

As in our case, Prati et al stated that in thrombectomy only group patients <30% residual stenosis revealed after thrombus removal and in almost all cases post-aspiration coronary flow grade was TIMI III. We used the same potent antiplatelet therapy, as prescribed by the authors in cases of thrombectomy without stenting. Remarkably, after 2 years of follow-up, there were no differences in clinical outcomes in patients treated with thrombectomy only, and in patients, who received a stent. None in the thrombectomy only group requires repeat revascularization.

Only the major difference described in our case was plaque condition, which was verified by OCT. We have found an unstable plaque with a large necrotic core and a ruptured fibrous cap. But after thrombus aspiration, minimal residual stenosis was detected, and the arterial lumen was free from thrombotic mass. It has been well studied, that in some cases (3–11%) STEMI was caused by underlying hemodynamically insignificant ruptured or eroded plaque.^{22–24} In these cases, lumen narrowing or occlusion are precipitated largely by the thrombus. Thrombus aspiration will result in only minimal residual stenosis of the vessel lumen.

Do we need a stent in such situations? It has been speculated that after thrombus aspiration, the remaining discontinuity of the fibrous cap brings platelets into contact with the highly thrombogenic necrotic plaque core, leading to thrombus formation once more.

Two main questions were raised for the treatment decision-making process:

1. Does the stent improve vessel lumen and coronary flow in case of minimal residual stenosis and TIMI III grade flow (both conditions were present in our case)?
2. Does the stent preclude contact of circulating platelets with a necrotic core of the plaque?

Supposedly, the answer to both questions is “no”. We can apparently reason that nothing might be gained by stenting with minimal residual stenosis of the lumen. Moreover, additional stenting causes unnecessary trauma of the arterial wall, which carries a risk of restenosis or thrombosis in the follow-up period.

On the other hand, combined potent antiplatelet and anticoagulation therapy (heparin, DAPT, Glycoprotein IIb/IIIa inhibitor) reliably prevents repeat thrombus formation after thrombus aspiration and allows the natural healing process of the vessel wall in the late period without a foreign body.

The guidelines recommend delayed or immediate coronary stenting as a preferable option compared to balloon angioplasty alone in patients with STEMI.²⁵ Several previous studies have investigated deferred stenting procedure as an option to preserve microcirculation option with conflicting results.^{26,27} The large (deferred vs. conventional stent implantation) multicenter DANAMI 3-DEFER trial showed no statistically significant difference in the primary clinical outcome between groups in the follow-up period.²⁸ Moreover, the results of two landmark RCTs suggest that the routine use of thrombus aspiration is not indicated.^{29,30} A safety concern highlighted in TOTAL (Trial of Routine Aspiration Thrombectomy with PCI vs. PCI Alone in Patients with STEMI) trial with an increase in the risk of stroke.³¹ Nevertheless, in the high-thrombus burden subgroup, the trend toward reduced cardiovascular death,³² mitigation of the risk of microembolization and no-reflow provides a rationale for “bail-out” thrombus aspiration procedure.

No doubt, that coronary stenting is the technique of choice during primary PCI in patients with STEMI, however, main question that arises following the described case is, can we safely defer stent implantation in STEMI patient? if yes, in which particular situation can we leave culprit lesion without a stent? Logically, vessel wall healing process without a foreign body (as a trigger of inflammation) could be closer to physiology and therefore preferable. This case shows the potential of OCT-based “stent-free” strategy with concomitant dual antiplatelet and high-intensity statin therapy to obtain a satisfactory short-term and long-term result. Moreover, OCT may be useful also to understand precise mechanism of vessel occlusion (e.g., embolism, in which after the removal of thrombus the vessel is without disease, or spontaneous coronary dissection).

Another important point is duration of dual antiplatelet therapy (DAPT) after initial PCI in ACS patients. Taking into account the complete endothelialization of ruptured plaque after 3 months, is this OCT finding sufficient basis for shorter DAPT? This case also highlights the utility of OCT imaging in studying the natural healing process after a ruptured plaque event leading to a major clinically relevant presentation.

4 | CONCLUSION

In selected cases, the OCT-based “stent-free” strategy of primary PCI may be useful to obtain short- and long-term satisfactory result in patients with STEMI. Supposedly, this approach promotes the natural healing of ruptured plaque and vessel wall without permanent foreign body in the arterial lumen.

ACKNOWLEDGEMENTS

We wish to thank all the nurses and technicians of our catheterization laboratory for their professional contribution and help. We also would like to express our appreciation to the technical personnel of the Terumo company for their involvement in this study.

CONFLICTS OF INTEREST

None declared.

AUTHOR CONTRIBUTIONS

Avtandil Babunashvili performed all the interventions (primary and follow-up), analyzed data, and prepared the text of the manuscript. Samir Pancholy read and correct the text. Tamara Babunashvili read and correct the text, assisted in the analysis of follow-up data. Alexander Prohorov assisted during the primary intervention.

PATIENT CONSENT

The authors confirm that they have obtained all appropriate patient consent forms. In these forms, the patient has given her consent for her images and other clinical information to be reported in the scientific journal. The patient fully understand that her name and initials will not be published and will be made to conceal her identity.

DATA AVAILABILITY STATEMENT

The data that support the findings of this study are available on request from the corresponding author. The data are not publicly available due to privacy or ethical restrictions.

ORCID

Avtandil Babunashvili  <https://orcid.org/0000-0003-2269-7059>

Samir Pancholy  <https://orcid.org/0000-0001-7831-0699>

REFERENCES

- Moreno PR, Falk E, Palacios IF, Newell JB, Fuster V, Fallon JT. Macrophage infiltration in acute coronary syndromes. Implications for plaque rupture. *Circulation*. 1994;90:775-778.
- Zairis MN, Papadaki OA, Manousakis SJ, et al. C-Reactive protein and multiple complex coronary artery plaques in patients with primary unstable angina. *Atherosclerosis*. 2002;164:355-359.
- Burke AP, Kolodgie FD, Farb A, et al. Healed plaque ruptures and sudden coronary death: evidence that subclinical rupture has a role in plaque progression. *Circulation*. 2001;103:934-940.
- Van Belle E, Lablanche J-M, Bauters C, Renaud N, McFadden EP, Bertrand ME. Coronary angioscopic findings in the infarct-related vessel within 1 month of acute myocardial infarction. Natural history and the effect of thrombolysis. *Circulation*. 1998;97:26-33.
- Uemura S, Ishigami K, Soeda T, et al. Thin-cap fibroatheroma and microchannel findings in optical coherence tomography correlate with subsequent progression of coronary atheromatous plaques. *Eur Heart J*. 2012;33(1):78-85.
- Tian J, Ren X, Vergallo R, et al. Distinct morphological features of ruptured culprit plaque for acute coronary events compared to those with silent rupture and thin-cap fibroatheroma: a combined optical coherence tomography and intravascular ultrasound study. *J Am Coll Cardiol*. 2014;63(21):2209-2216.
- Hu S, Yonetsu T, Jia H, et al. Residual thrombus pattern in patients with ST-segment elevation myocardial infarction caused by plaque erosion versus plaque rupture after successful fibrinolysis: an optical coherence tomography study. *J Am Coll Cardiol*. 2014;63(13):1336-1338.
- Tearney GJ, Regar E, Akasaka T, et al. Consensus standards for acquisition, measurement, and reporting of intravascular optical coherence tomography studies: a report from the international working group for intravascular optical coherence tomography standardization and validation. *J Am Coll Cardiol*. 2012;59(12):1058-1072.
- Rioufol G, Gilard M, Finet G, Ginon I, Boschat J, André-Fouët X. Evolution of spontaneous atherosclerotic plaque rupture with medical therapy: long-term follow-up with intravascular ultrasound. *Circulation*. 2004;110(18):2875-2880.
- Ueda Y, Asakura M, Yamaguchi O, Hirayama A, Hori M, Kodama K. The healing process of infarct-related plaques. Insight of 18 months of serial angioscopic follow-up. *JACC*. 2001;38(7):1916-1922.
- Sianos G, Papafaklis MI, Serruys PW. Angiographic thrombus burden classification in patients with ST-segment elevation myocardial infarction treated with percutaneous coronary intervention. *J Invasive Cardiol*. 2010;22(10 Suppl B):6B-14B.
- Gogas BD, Farooq V, Serruys PW, García-García HM. Assessment of coronary atherosclerosis by IVUS and IVUS-based imaging modalities: progression and regression studies, tissue composition and beyond. *Int J Cardiovasc Imaging*. 2011;27(2):225-237.
- Jacob FB, Fumiyuki O, Renu V, Erling F. Mechanism of plaque formation and rupture. *Circ Res*. 2014;114:1852-1866.
- Daida H, Dohi T, Fukushima Y, Ohmura H, Miyauchi K. The goal of achieving atherosclerotic plaque regression with lipid-lowering therapy: insights from IVUS trials. *J Atheroscler Thromb*. 2019;26:592-600.
- Hartmann M, Huisman J, Bose D, et al. Serial intravascular ultrasound assessment of changes in coronary atherosclerotic plaque dimensions and composition: an update. *Eur J of Echocardiography*. 2011;12:313-321.
- Hattori K, Ozaki Y, Ismail TF, et al. Impact of statin therapy on plaque characteristic as assessed by serial OCT, grayscale and integrated backscatter-IVUS. *JACC: Cardiovasc Imaging*. 2012;5(2):169-177.
- Bauters C. Silent coronary plaque rupture. *Arch Cardiovasc Dis*. 2008;101:79-80.

18. Banach M, Serban C, Sahebkar A, et al. Impact of statin therapy on coronary plaque composition: a systematic review and meta-analysis of virtual histology intravascular ultrasound studies. *BMC Med*. 2015;13:229-249.
19. Tang X, Yang Y, Luo S, et al. The effect of statin therapy on plaque regression following acute coronary syndrome: a meta-analysis of prospective trials. *Coron Artery Dis*. 2016;27(8):636-649.
20. Vergallo R, Porto I, D'Amario D, et al. Coronary atherosclerosis phenotype and plaque healing in patients with recurrent coronary syndromes compared with patients with long-term clinical stability. An in vivo optical coherence tomography study. *JAMA Cardiol*. 2019;4(4):321-329.
21. Prati F, Uemura S, Souteyrand G, et al. OCT-based diagnosis and management of STEMI associated with intact fibrous cap. *JACC Cardiovasc Imaging*. 2013;6(3):283-287.
22. Little WC, Constantinescu M, Applegate RJ, et al. Can coronary angiography predict the site of a subsequent myocardial infarction in patients with mild-to-moderate coronary artery disease? *Circulation*. 1988;78(5):1157-1166.
23. Kilic S, Kocabas U, Can LH, Yavuzgil O, Zoghi M. The severity of coronary arterial stenosis in patients with acute ST-elevated myocardial infarction: a thrombolytic therapy study. *Cardiology Res*. 2018;9(1):11-16.
24. Tian J, Dauerman H, Toma C, et al. Prevalence and characteristics of TCFA and degree of coronary artery stenosis. An OCT, IVUS, and angiographic study. *J Am Coll Cardiol*. 2014;64(7):672-680.
25. Neumann F-J, Sousa-Uva M, Ahlsson A, et al. ESC/EACTS guidelines on myocardial revascularization. *Eur Heart J*. 2018;2019(40):87-165.
26. Carrick D, Oldroyd KG, McEntegart M, et al. A randomized trial of deferred stenting versus immediate stenting to prevent no- or slow-reflow in acute ST-segment elevation myocardial infarction (DEFER-STEMI). *J Am Coll Cardiol*. 2014;63:2088-2098.
27. Belle L, Motreff P, Mangin L, et al. Comparison of immediate with delayed stenting using the minimalist immediate mechanical intervention approach in acute ST-segment-elevation myocardial infarction: the MIMI study. *Circ Cardiovasc Interv*. 2016;9:e003388.
28. Kelbaek H, Hofsten DE, Kober L, et al. Deferred versus conventional stent implantation in patients with ST-segment elevation myocardial infarction (DANAMI 3-DEFER): an open-label, randomized controlled trial. *Lancet*. 2016;387:2199-2206.
29. Frobert O, Lagerqvist B, Olivecrona GK, et al. Thrombus aspiration during ST-elevation myocardial infarction. *N Engl J Med*. 2013;369(17):1587-1597.
30. Jolly SS, Cairns JA, Yusuf S, et al. Randomized trial of primary PCI with or without routine manual thrombectomy. *N Engl J Med*. 2015;372(15):1389-1398.
31. Jolly SS, Cairns JA, Yusuf S, et al. Stroke in the TOTAL trial: a randomized trial of routine thrombectomy vs. percutaneous coronary intervention alone in ST elevation myocardial infarction. *Eur Heart J*. 2015;36:2364-2372.
32. Jolly SS, James S, Džavík V, et al. Thrombus aspiration in ST-segment-elevation myocardial infarction: an individual patient meta-analysis: thrombectomy trialists collaboration. *Circulation*. 2017;135(2):143-152.

How to cite this article: Babunashvili A, Pancholy S, Babunashvili T, Prokhorov A. Thrombus aspiration without stenting in a patient with anterior STEMI: Regression and healing of an unstable plaque assessed by OCT at 24 months of follow-up. *Clin Case Rep*. 2021;9:e04549. <https://doi.org/10.1002/ccr3.4549>